CEO Clinical and Experimental Otorhinolaryngology Vol. 2, No. 2: 72-77, June 2009 DOI 10.3342/ceo.2009.2.2.72

Original Article

Patterns of Post-thyroidectomy Hemorrhage

Hyoung Shin Lee, MD · Bong Ju Lee, MD[1] · Sung Won Kim, MD[1] · Young Woo Cha, MD[1] · Young Sik Choi, MD[2]
Yo Han Park, MD[2] · Kang Dae Lee, MD[1]

Department of Otolaryngology-Head and Neck Surgery, Nam-hae Hospital, Namhae; [1]Departments of Otolaryngology-Head and Neck Surgery and [2]Endocrinology, Kosin University College of Medicine, Busan, Korea

Objectives. Postoperative hemorrhage is a potentially life-threatening complication in thyroid surgery. This study was performed to review the clinical patterns of post-thyroidectomy hemorrhage, and especially as they are related to the source of bleeding.

Methods. We performed a retrospective review of 10 patients (0.96%) with post-thyroidectomy hemorrhage that required surgical evacuation. The clinical patterns such as the time interval from surgery to hemorrhage and the signs and symptoms according to the bleeding focus were evaluated.

Results. The mean time interval from surgery to symptom onset was 7 hr 52 min. Six cases showed bleeding deep to the strap muscles, while the other 4 cases showed bleeding superficial to the muscles. Ecchymosis was prominent and dark in color in 3 of the 4 cases (75%) of superficial bleeding, however it was identified in only 2 of the 6 cases (33%) of deep bleeding. Respiratory distress occurred in two cases of hematoma deep to the strap muscles, but in none of the cases with superficial bleeding.

Conclusion. The post-thyroidectomy hemorrhage had some different clinical patterns between the superficial cases and the deep cases, showing that life-threatening airway obstruction occurred from the deep hematoma. A thorough understanding of the clinical patterns of post-thyroidectomy hemorrhage between the cases of superficial and those cases of deep hematoma may provide valuable surgical tips to manage this potentially lethal complication.

Key Words. *Thyroidecotmy, Hemorrhage, Complication*

INTRODUCTION

Postoperative hemorrhage is a well known complication of thyroid surgery and it requires special attention since this may be life-threatening due to acute airway obstruction. The reported incidence of post-thyroidectomy hemorrhage has varied between 0.36 and 4.3% (1, 2). The etiology of post-thyroidectomy hemorrhage has been described as slipping of the ligature on major vessels, reopening of the veins that have been cauterized, retching and bucking of the patient during recovery, a Valsava maneuver, increased blood pressure and oozing from the cut area of the thyroid (3).

The key factors for the management of a post-thyroidectomy hemorrhage include close observation, early detection and airway management. Surgical exploration with evacuation of the hematoma is indicated for those cases of hematoma with symptoms such as stridor or hypoxia (4, 5). Although it is a serious complication of thyroid surgery that can lead to airway distress, post-thyroidectomy hemorrhage has been less frequently reported compared to vocal cord paralysis or hypocalcemia. This study was conducted to determine not only the incidence and timing of post-thyroidectomy hemorrhage, but also to review our experience and to analyze the clinical patterns of post-thyroidectomy hemorrhage according to the source of bleeding and whether it is superficial or deep to the strap muscles.

MATERIALS AND METHODS

We performed a retrospective review of 1,040 cases of thyroidectomy that were done at our institution by a single surgeon from April 1998 through October 2008. This included 111 patients who underwent concomitant lateral compartment neck dissection. Because all the surgeries were conducted by a single surgeon, several key aspects of the surgical procedure were standard-

• Received April 20, 2009
Accepted after revision May 5, 2009

• Corresponding author : **Kang Dae Lee, MD**
Department of Otolaryngology-Head and Neck Surgery, Kosin University College of Medicine, 34 Amnam-dong, Seo-gu, Busan 602-702, Korea
Tel : +82-51-990-6470, Fax : +82-51-245-8539
E-mail : kdlee@ns.kosinmed.or.kr

ized. Vessels were ligated with a classical tie and suture technique. Large vessels such as the branches of the superior and inferior thyroid artery were double-ligated. Bleeding from muscles and remnants of thyroid tissue was controlled by bipolar cauterization and suture ligation. A harmonic scalpel or tissue glue was not used for the hemostasis. Before skin closure, the strap muscles were loosely approximated so that an expanding post-operative hematoma deep to the muscles could be easily detected. A closed suction drain (Evacuator Barovac, 100 mL, Sewoon Medical Co., Korea) was routinely used. The drain tube was inserted through the skin at the lateral neck and it went through the space between the strap muscles to prevent any bleeding from injury to the muscles. The skin incision, subplatysmal dissection, drain insertion and skin closure were performed by the residents in most of the cases.

Table 1. The type of surgery and the incidence of bleeding requiring re-exploration

Procedure	Total no. of case	No. of bleeding (%)
Lobectomy	391	3 (0.77)
Subtotal thyroidectomy	79	0 (0)
Total thyroidectomy	511	7 (1.37)
Completion thyroidectomy	59	0 (0)
Total	1,040	10 (0.96)

The study was focused on the 10 patients, among the 1,040 (0.96%), with cervical hematomas that required re-exploration (Table 1). Asymptomatic patients with minimal swelling or ecchymosis that required observation only were excluded. There was no bleeding from the surgical field of the lateral compartment neck dissection. The group consisted of 2 men and 8 women with a mean age of 47.5 yr (range, 35 to 71 yr) (Table 2). With respect to the pathology, 8 patients had papillary carcinoma, 1 had follicular adenoma, and the other patient had benign thyroid nodule with parathyroid adenoma. Except for one patient who took aspirin prior to the surgery, none of the patients had a bleeding tendency nor had any patients taken any drugs that could interfere with the hemostasis. The diagnosis of the expanding hematoma was made by the medical staff during routine assessment or in response to the patient's complaints. For the case of respiratory distress from the hematoma, it is our policy to conduct an emergency evacuation of the hematoma in the hospital ward.

All the patients underwent the re-exploration under general anesthesia. The sutures approximating the skin and the platysma muscle were initially removed. The first step to identify the

Table 2. The clinical feature of the patients with post-thyroidectomy hemorrhage

Case	Age/ gender	Diagnosis	Prodedure	Time interval between surgery & hematoma	Signs and symptoms	Site of the bleeding focus
1	71/F	Papillary carcimoma	T-T c CCND	1 hr	Swelling	Sternocleidomastoid muscle
					Oozing of wound	
					Pain/pressure sensation	
2	60/F	Papillary carcimoma	T-T c CCND	18 hr	Swelling	Strap muscle
					Ecchymosis	
					Pain/pressure sensation	
3	37/M	Follicular adenoma	Lobectomy	6 hr	Swelling	Sternocleidomastoid muscle
					Ecchymosis	
					Pain/pressure sensation	
4	46/M	Papillary carcimoma	T-T c CCND	15 hr	Swelling	Unknown
					Ecchymosis	
5	35/F	Papillary carcimoma	Lobectomy	4 hr	Swelling	Cut surface of the
					Pain/pressure sensation	thyroid remnant
					Ecchymosis	
6	46/F	Papillary carcimoma	T-T c CCND	4 hr	Swelling	Branch of superior
					Ecchymosis	thyroid artery
7	36/F	Papillary carcimoma	T-T c CCND	4 hr	Swelling	Branch of the superior
					Pain/pressure sensation	thyroid artery
8	59/F	Parathyroid adenoma	Lobectomy,	11 hr 30 min	Swelling	Cricothyroid artery
			parathyroidectomy		Respiratory distress	
9	37/F	Papillary carcimoma	T-T c CCND	10 min	Swelling	Branch of the inferior
						thyroid artery
10	48/F	Papillary carcinoma	T-T c CCND	15 hr	Swelling	Branch of the superior
					Pain/pressure sensation	thyroid artery
					Respiratory distress	
					vocal cord palsy Left	

T-T c CCND: total thyroidectomy with central compartment neck dissection.

source of the bleeding was to determine whether the hematoma was superficial or deep to the strap muscles. 'Superficial hematoma' indicates a hematoma located between the subplatysmal dissection plane and the strap muscles, while 'deep hematoma' indicates a hematoma between the strap muscles and the thyroid bed. We then began to remove the hematoma from the portion of lesser size and amount toward the largest portion of the hematoma. We tried to detect the bleeding focus as we approached toward the largest portion of the hematoma. According to our experience, it coincides with the focus and helps to detect the location of the source. The hematoma was carefully removed by using irrigation with warm saline so as not to cause any injury to the recurrent laryngeal nerve and the parathyroid gland. Hemostasis of the bleeding from soft tissues such as the muscles or the remnant thyroid tissue was performed using electrocauterization and suture ligation. We avoided any blind clamping of vessels within the hematoma. The identified arteries were all grasped with a hemostatic clamp and tied by using the double-ligation technique for secure hemostasis. The wound was drained with a closed suction drain in all cases of re-exploration. In all the cases, the larynx was examined at the recovery room by using a fiberoptic laryngoscope for any possible vocal cord paralysis. The medical records of each patient in the study group were reviewed to identify the type of the procedure performed, the time interval between surgery and the hematoma, the signs and symptoms of the hematoma and the site of the bleeding focus.

RESULTS

The initial surgical procedures of the patients with post-thyroidectomy hemorrhage included 7 cases of total thyroidectomy and 3 cases of lobectomy. All the patients with total thyroidectomy had papillary thyroid carcinoma and they underwent concomitant central compartment neck dissection. Due to the limited number of the cases, we could not analyze the relations between the bleeding incidence and the extent of surgery.

Nine patients developed wound hematoma in the ward. The wound hematoma in one patient was diagnosed during transfer from the operating room to the recovery room due to the rapidly filling closed suction drain. The patient required immediate reexploration. The mean time interval from surgery to symptom onset was 7 hr 52 min (range, 10 min to 18 hr). In six patients, the diagnosis was made within 8 hr after surgery. In the other four patients, the hematoma was observed within 8-18 hr after surgery. In one case, neck swelling was detected by the patient just after she had done some coughing, about 4 hr after the surgery. The drains placed during their initial operation were clotted except for one case that developed hematoma during transfer from the operating room to the recovery room. The amount of drainage in the clotted cases ranged from 10 to 50 mL.

We identified that hematoma was located deep to the strap muscles in 6 cases while the other 4 cases showed hematoma superficial to the strap muscles (Table 3). One case of deep hematoma with bleeding from the remnant tissue of the thyroid at the isthmus and the two other cases with bleeding from the superior thyroid artery were all accompanied by a small amount of superficial hematoma. While these 3 of 6 (50%) cases with bleeding deep to the strap muscles were accompanied with some superficial hematoma, none of the cases with superficial bleeding accompanied hematoma deep to the strap muscles (Figs. 1 and 2).

The clinical features of the patients are summarized in Table 2. Ecchymosis was identified in 3 of the 4 cases of superficial bleeding, but not in the 1 case identified just 1 hr after the surgery. Ecchymosis was most prominent at the point of skin just superficial to the bleeding focus below it. However, among the 6 cases with a bleeding focus deep to the strap muscles, only 2 cases accompanied by a small amount of superficial hematoma showed ecchymosis. However, the extent of the ecchymosis on the skin was smaller and the degree of skin discoloration was less, as compared to those of the cases of deep hematoma (Figs. 1 and 2).

Respiratory distress occurred in two of the six cases of hematoma deep to the strap muscles with bleeding from a branch of the cricothyroid artery and the left superior thyroid artery, respectively. None of the 4 cases with bleeding superficial to the strap muscles showed any symptoms of respiratory distress. Two cases of deep hematoma, in which the larynx was observed through the laryngoscope one day after the reexploration, showed diffuse swelling and bluish discoloration of the laryngeal mucosa. One patient with deep hematoma developed left vocal cord paralysis 24 hr after the initial surgery. The patient showed normal vocal cord movement at the recovery room after the initial surgery, and the paralysis was identified just before the reexploration.

The bleeding source was identified in 9 patients. In the cases with the bleeding source superficial to the strap muscles, the hematoma was easily evacuated followed by irrigation with warm saline to identify the focus of bleeding. The bleeding sources of the superficial group were the strap muscle in 1 case and the sternocleidomastoid (SCM) muscle in 2 cases. One case of bleeding

Table 3. Location of the hematoma

Case	Site of the bleeding focus	Hematoma superficial to the strap muscle	Hematoma deep muscle to the strap
1	Sternocleidomastoid muscle	Yes	No
2	Strap muscle	Yes	No
3	Sternocleidomastoid muscle	Yes	No
4	Unknown	Yes	No
5	Cut surface of the thyroid remnant	Yes	Yes
6	Branch of the superior thyroid artery	Yes	Yes
7	Branch of the superior thyroid artery	No	Yes
8	Cricothyroid artery	No	Yes
9	Branch of the inferior thyroid artery	No	Yes
10	Branch of the superior thyroid artery	Yes	Yes

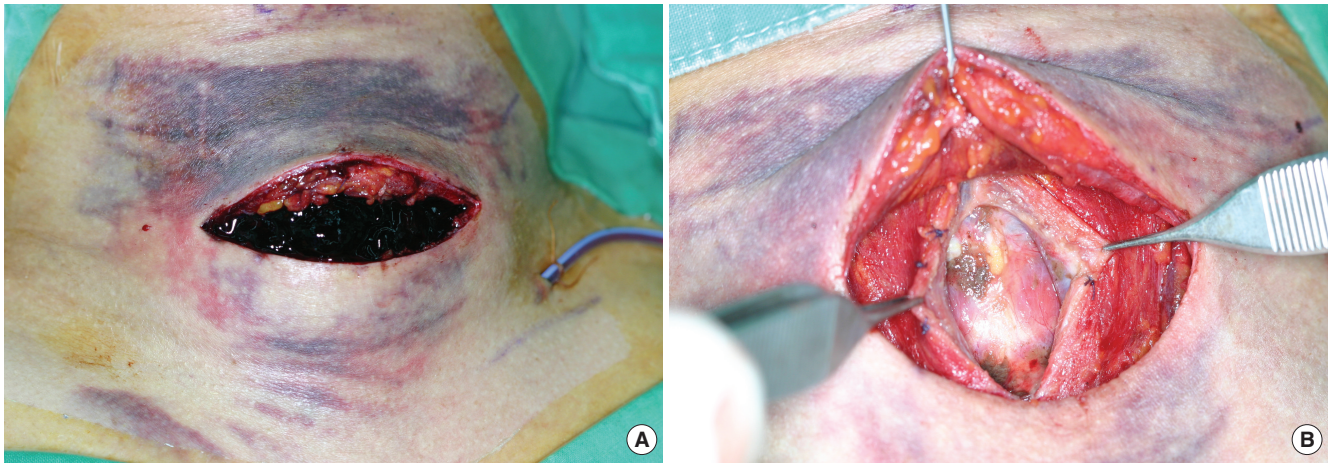

Fig. 1. Superficial hematoma. (A) Hematoma superficial to the strap muscles and prominent ecchymosis were identified. (B) Hematoma deep to the strap muscles was not detected.

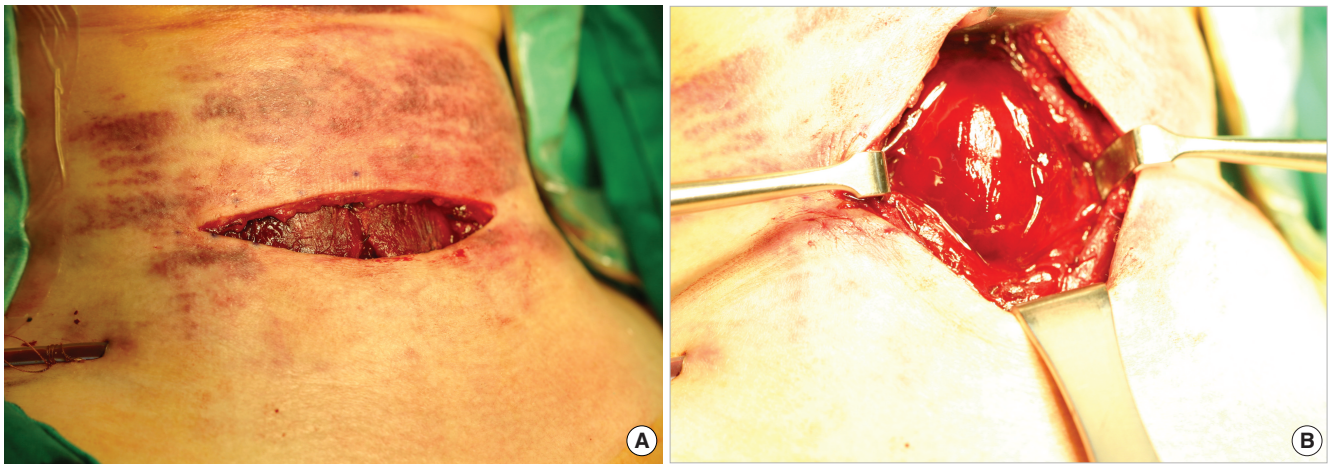

Fig. 2. Deep hematoma. (A) A significant amount of hematoma superficial to the strap muscles was not identified. The extent of the ecchymosis was smaller and the degree of skin discoloration was less, compared to those of cases of the superficial hematoma. (B) Hematoma deep to the strap muscles was identified.

from the SCM muscle developed due to tearing of an artery during the insertion of the closed suction drain. The source was unapparent in 1 case.

In the cases of bleeding deep to the strap muscles, the amount of hematoma and oozing superficial to the strap muscles was relatively insignificant. Although the strap muscles had been loosely approximated, the amount of blood leakage between the muscles did not develop significant subcutaneous hematoma as those cases with superficial bleeding. The bleeding sources deep to the strap muscles were the superior thyroid artery in 3 cases, the inferior thyroid artery in 1 case, a branch of the cricothyroid artery in 1 case and the cut surface of the thyroid remnant in 1 case. It was difficult to identify the bleeding focus in one case with hemorrhage from a branch of the left superior thyroid artery since it had been pulled superiorly toward the proximal direction after the initial ligation of the first surgery.

The airway was managed cautiously in each patient. Two patients with significant airway compromise required emergency evacuation of the hematoma in the hospital ward. However, there was no urgent need to perform intubation or tracheotomy on any of these patients. Two patients received transfusions (2 units for each patient). None of the patients developed hypoparathyroidism or vocal cord paralysis after the reexploration. All the patients improved and they recovered remarkably well after the reexploration without any cases of rebleeding.

DISCUSSION

Despite the ongoing advances of the techniques, the innovations in the surgical instruments and a better understanding of the underlying thyroid pathologies, postoperative hematoma remains a potentially serious complication of thyroid surgery (6). When fatality occurs because of this postoperative hematoma,

it is due to acute airway distress and cardiac arrest (3). Total airway obstruction may progress once the critical compression occurs in the compartment below the strap muscles. This leads to compression of the trachea and impairment of the venous and lymphatic drainage and then laryngopharyngeal edema, which may be the real site of airway obstruction (7, 8). This may explain the airway distress from two cases of deep hematoma we experienced. We can also expect that deep hematomas may more frequently lead to airway compromise. It seems to be reasonable not to close the strap muscles very tightly so that any deep hematoma that develops may become apparent in the subcutaneous region before the patient develops a major airway problem (3, 7). Some authors prefer incomplete closure of the strap muscle or no re-approximation inferiorly so that a space 3 to 4 cm in length remains to allow for decompression of the deep space of the neck (4, 9).

The time interval to the development of hematoma has been mostly reported to be within 24 hr, the same as was noted in our study (3, 4, 6, 10). The surgeons and medical staffs at the ward should pay special attention for any signs and symptoms of bleeding during the period. However, there are still some other reported cases, although only a few, in which delayed hemorrhage developed more than 24 hr after surgery (3, 9). Thus, hemorrhagic symptoms that develop after 24 hr should never be neglected.

In our cases, reopening of the veins that were cauterized could have been the cause of superficial hematoma in 3 patients. Since monopolar cautery was used for subplastymal dissection, the small veins superficial to the strap muscles and the SCM muscle could have been incompletely cauterized during the dissection. As this procedure was usually performed by the resident, thorough identification for any possible bleeding before the surgeon proceeded with dissection of the thyroid could have prevented such a complication. Harding et al. pointed out that if the strap muscles are divided, this may serve as a source of bleeding unless adequate ligation or coagulation are performed (6). They also emphasized that care should be taken when elevating the subplatysmal flaps or closing the vertically divided strap muscles to avoid injury to the anterior jugular veins. Bleeding from the SCM muscle during the drainage procedure was an exceptional case that was caused by the carelessness of the resident. It is our policy not to puncture the drain through the SCM muscle. Residents in training hospitals should be educated to pay special attention during the procedure of subplatysmal dissection, insertion of the drain and closure of the strap muscles. Minimizing any bleeding and conducting complete hemostasis during these procedures may prevent postoperative hemorrhage.

Slipping of the ligature from the major vessels could have been the main cause of the 4 cases of bleeding deep to the strap muscles. The importance of meticulous hemostasis with a skillful tying technique cannot be overemphasized. Whether the patients' retching and bucking during recovery, a Valsalva maneuver or any event of increased blood pressure caused the slipping could not be confirmed except for the one case for which the hematoma developed just after the patient began to cough. A poor tying technique for ligating the vessels should also be considered. The cause of the slipping of the ligature remains obscure since we were unable to assess the status of the patients during their recovery from anesthesia. However, we agree with Matory and Spiro (11), who believed that smooth arousal from general anesthesia is paramount for patients who have just undergone thyroid surgery. Increasing the venous pressure through a Valsalva maneuver or placing the patient in a 30° head down position before wound closure could be another method to prevent postoperative hemorrhage because these procedures will help to identify potential bleeding points (6, 12). Since the branches of the superior thyroid artery may be very difficult to identify after the slipping of ligature, special attention is required to ligate these vessels. If there is bleeding from these vessels, then surgeons should patiently try to detect the bleeding focus and avoid any blind handling during the re-exploration. One case of bleeding from the isthmus of the thyroid remnant was due to oozing from the cut surface of the thyroid. We recommend complete hemostasis of the cut surface in the remnant thyroid together with using suture ligation to prevent a hematoma.

Patients with post-thyroidectomy hematoma may present with respiratory distress, pain or a pressure sensation in the neck or dysphagia. The signs include progressive neck swelling, suture line bleeding, dyspnea or stridor and a significant amount of drain losses (6). As early recognition with immediate intervention is the key to managing this complication, the medical staff should be thoroughly aware of these signs and symptoms (9). Immediate intubation should be performed in the case of respiratory distress from airway obstruction. If this procedure is not available, then bedside decompression of the wound is the key factor for providing relief from hypoxia and the resulting cardiovascular instability (6, 7). In our study, bedside evacuation of the hematoma was required in only two patients who had bleeding from a branch of the cricothyroid artery and the left superior thyroid artery, respectively. However, for the 4 cases of superficial hematoma, none of the patients had any symptoms of airway obstruction. The strap muscles could have worked as a barrier between the hematoma and the trachea or the venous and lymphatic drainage system of the larynx and pharynx. We assume that early detection and management before the onset of any laryngopharyngeal edema contributed to the low incidence of respiratory distress at our center.

Neck swelling was identified in all the cases of our study, and this has been frequently described in the literature as a representative sign of post-thyroidectomy hemorrhage (4, 6). However, ecchymosis of the skin has rarely been mentioned as related to this complication. The ecchymosis identified in 3 of the 4 cases of superficial hematoma was the result of leakage of blood through the subcutaneous tissue from the hematoma just below and this led to skin discoloration. The case of superficial hematoma

that did not show any ecchymosis may have been due to the short time interval (1 hr) to diagnosis. The two cases of hemorrhage deep to the strap muscle and that showed ecchymosis may have been due to direct leakage of blood through the midline between the strap muscles. It may be a natural result that ecchymosis was most prominent at the point of the skin just superficial to the bleeding focus below. This may be considered as a clinical tip to identify the bleeding focus during re-exploration. The discoloration of the laryngeal mucosa identified in the two cases of deep hematoma may also be used as a clinical tip. Since hemorrhage superficial to the strap muscles never accompanied any deep hematoma, we believe that the discoloration of the mucosa could be accepted as a sign of hemorrhage deep to the strap muscles. The vocal cord paralysis in the one case of deep hematoma may have been caused by the compression from the hematoma since the vocal cord movement was intact at the recovery room after the initial surgery. Thus, movement of the vocal cords should be observed in the patients with post-thyroidectomy hemorrhage.

It has been reported that there is no significant difference in the incidence of postoperative hematoma or seroma in the patients for whom postoperative drains were or were not placed (5, 6, 13). We agree that placing a drain should never be considered as a substitute for meticulous surgical technique with careful hemostasis (7). Moreover, drains were not helpful to detect the hemorrhage, except in 1 case of immediate postoperative hemorrhage that showed a rapidly filling drain.

CONCLUSION

Post-thyroidectomy hemorrhage showed some different clinical patterns between the superficial cases and the deep cases. It could be considered that superficial hematoma may frequently cause ecchymosis, while hematoma deep to the strap muscles could lead to life-threatening airway obstruction. The clinical patterns of the signs and symptoms according to the bleeding focus (be it superficial or deep to the strap muscles), may be helpful to determine the severity and the sources of the hemorrhage.

REFERENCES

1. Lacoste L, Gineste D, Karayan J, Montaz N, Lehuede MS, Girault M, et al. Airway complications in thyroid surgery. Ann Otol Rhinol Laryngol. 1993 Jun;102(6):441-6.
2. Frick T, Largiader F. Perioperative complications in thyroid gland surgery. Langenbecks Arch Chir. 1991 Sep;376(5):291-4.
3. Shaha AR, Jaffe BM. Practical management of post-thyroidectomy hematoma. J Surg Oncol. 1994 Dec;57(4):235-8.
4. Rosenbaum MA, Haridas M, McHenry CR. Life-threatening neck hematoma complicating thyroid and parathyroid surgery. Am J Surg. 2008 Mar;195(3):339-43.
5. Sanabria A, Carvalho AL, Silver CE, Rinaldo A, Shaha AR, Kowalski LP, et al. Routine drainage after thyroid surgery: a meta-analysis. J Surg Oncol. 2007 Mar;96(3):273-80.
6. Harding J, Sebag F, Sierra M, Palazzo FF, Henry JF. Thyroid surgery: postoperative hematoma--prevention and treatment. Langenbecks Arch Surg. 2006 Jun;391(3):169-73.
7. Savargaonkar A. Post-thyroidectomy haematoma causing total airway obstruction: a case report. Indian J Anaesth. 2004 Dec;48(6):483-5.
8. Mittendorf EA, McHenry CR. Complications and sequelae of thyroidectomy and an analysis of surgeon experience and outcome. Surg Technol Int. 2004;12:152-7.
9. Burkey SH, van Heerden JA, Thompson GB, Grant CS, Schleck CD, Farley DR. Reexploration for symptomatic hematomas after cervical exploration. Surgery. 2001 Dec;130(6):914-20.
10. Abbas G, Dubner S, Heller KS. Re-operation for bleeding after thyroidectomy and parathyroidectomy. Head Neck. 2001 Jul;23(7):544-6.
11. Matory YL, Spiro RH. Wound bleeding after head and neck surgery. J Surg Oncol. 1993 May;53(1):17-9.
12. Farrar WB. Complications of thyroidectomy. Surg Clin North Am. 1983 Dec;63(6):1353-61.
13. Corsten M, Johnson S, Alherabi A. Is suction drainage an effective means of preventing hematoma in thyroid surgery: a meta-analysis. J Otolaryngol. 2005 Dec;34(6):415-7.