
The Aim of Technology During Liver Resection – A Strategy to Minimize Blood Loss During Liver Surgery

Fabrizio Romano, Mattia Garancini, Fabio Uggeri,
Luca Gianotti, Luca Nespoli, Angelo Nespoli and
Franco Uggeri

Additional information is available at the end of the chapter

<http://dx.doi.org/10.5772/54301>

1. Introduction

Liver resection is considered the treatment of choice for liver tumours. Despite standardized techniques and technological advancing for liver resections, an intra-operative haemorrhage rate ranging from 700 and 1200 ml is reported with a post-operative morbidity rate ranging from 23 and 46% and a surgical death rate ranging from 4 and 5% [1],[2],[3],[4],[5],[6].

The parameter "**Blood loss**" has a central role in liver surgery and different strategies to minimize it are a key to improve these results. Bleeding has to be considered a major concern for the hepatic surgeon because of several reasons. At first it is certainly the major intra-operative surgical complication and cause of death and historically one of the major postoperative complication together with bile leaks and hepatic failure [5],[6],[7],[8],[9].

Besides a high intra-operative blood loss is associated with higher rate of post-operative complication and shorter long-term survival [10],[11],[12],[13]. Furthermore it is associated with an extensive use of vessel occlusion techniques, directly correlated with higher risk of post-operative hepatic failure. Last, a higher value of intra-operative blood loss is associated with a higher rate of peri-operative transfusions; host immunosuppression associated with transfusions with a dose-related relationship is correlated with a higher rate of complication (in particular infections) and recurrence of malignancies in neoplastic patients [11],[12],[14],[15],[16],[17],[18],[19],[20],[21]. In order to reduce transfusions hepatic surgeon has also not to misinterpret post-operative fluctuations of blood parameter: Torzilli et al. demonstrated that haemoglobin rate and haematocrit after liver resection show a steady and significant decrease until the third post-operative day and then an increase; so this situation has to be explained as

physiological and does not justifies blood administration [22]. Although the mechanism of bleeding in surgical interventions is multifactorial, technical factors may be responsible for a significant amount of intraoperative and early postoperative bleeding. The main progress in reducing perioperative blood loss has been made through improved surgical and anesthetic techniques and through better understanding of hemostatic disorders in patients who have liver disease. developments in surgical, anesthesiologic, and pharmacologic strategies that have contributed to a reduction of blood loss during liver surgery in cirrhotic and noncirrhotic patients. The clinical relevance of different types of strategies may vary, depending on the stage of the operation. For example, topical hemostatic agents have a role in reducing blood loss from the hepatic resection surface after partial liver resection, whereas surgical techniques play a more important role during transection of the liver parenchyma (Fig. 1).

2. How can we reduce bleeding in liver surgery?

Figure 1 shows the amount of blood loss during the different phases of liver surgery. It is clear that the higher risk for bleeding and the greater amount of blood loss occur during the parenchymal transection phase of the procedure.

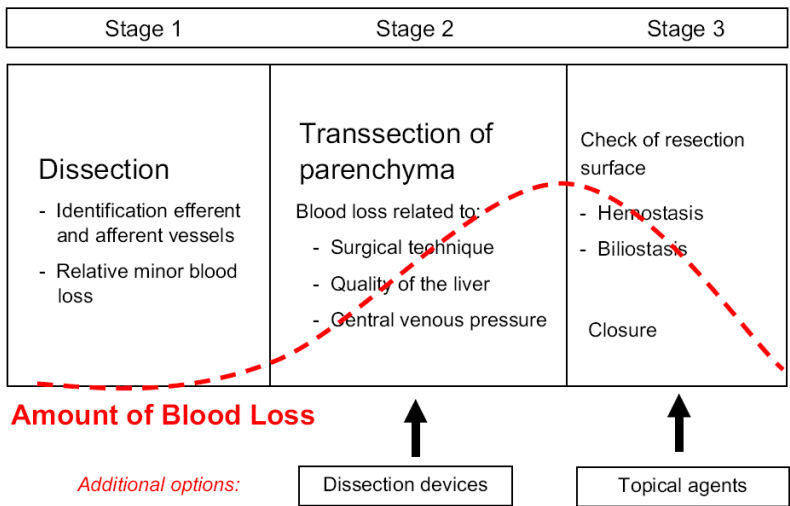


Figure 1. The mechanisms of bleeding and the relative amount of blood loss (dotted line) during the three surgical stages of partial liver resections. In general, most bleeding can be encountered during transection of the liver parenchyma. In this stage of the operation, blood loss is mainly caused by bleeding from the resection surface of the liver.

The aim of the study is to investigate the principal solutions to the problem of high blood loss in hepatic resection, considering the role of surgeons and anesthesiologists. Table 1 resume all the methods to prevent or reduce bleeding during liver surgery. Moreover we focused our

attention on the technological aspects of liver parenchima transection. We will describe each technology and instrument discussing the principle of functioning, the technical characteristics and analysed the advantages (**A**) and the disadvantages (**D**) correlated to their employment during liver transection. We divided the instruments taking into account the energy employed for their functioning.

Surgical
Vascular clamping techniques
Inflow occlusion
Continuous Pringle maneuver
Continuous Pringle maneuver after ischemic preconditioning
Intermittent Pringle maneuver
Total vascular occlusion
Dissection devices for transection of liver parenchyma
Classic methods
Scalpel
“Finger-fracture” method
Clamp crushing
Ultrasonic dissection
Hydro-jet dissection
Electro coagulation (monopolar, bipolar, Argon coagulation)
Radiofrequency ablation-based devices
Staplers
Topic hemostatic agents
Anesthesiologic
Maintaining low central venous pressure by using
Volume contraction
Phlebotomy
Vasodilatation
If needed, forced diuresis
Blood products
Use of pharmacologic agents
Antifibrinolytics
Recombinant factor VIIa

Table 1. Surgical and anesthesiologic methods used to reduce blood loss in liver surgery

Moreover we tried to compare the different instruments and technologies basing on literature data to identify the best instruments for each type of liver resection (open surgery, laparoscopic surgery, resective surgery, oncologic surgery, liver transplantation).

3. The role of the surgeon

Most blood loss during liver resection occurs during parenchymal transection. Hepatic surgeon has different ways to control bleeding:

Vessel occlusion techniques: Those technique are based on the idea that to limit the blood flow through the liver during parenchymal transection can reduce the haemorrhage. Although various forms and modified techniques of vascular control have been practiced, there are basically two main strategies; inflow vascular occlusion and total vascular exclusion²³⁻²⁴ Inflow vascular occlusions are techniques that limit anterograde blood flow with the clamping of all the triad of the hepato-duodenal ligament (*Pringle's manoeuvre, PM*), only of the vascular pedicles (selective clamping of the portal vein and the hepatic artery or *Bismuth technique*) or *intravascularportal clamping*. During Pringle's manoeuvre the hepatoduodenal ligament is encircled with a tape, and then a vascular clamp or tourniquet is applied until the pulse in the hepatic artery disappears distally. The PM has relatively little general haemodynamic effect and no specific anaesthetic management is required. However, bleeding can still occur from the backflow from the hepatic veins and from the liver transection plane during unclamping. The other concern is the ischaemic-reperfusion injury to the liver parenchyma, especially in patients with underlying liver diseases²⁵. The continuous Pringle manoeuvre (CPM) can be safely applied to the normal liver under normothermic conditions for up to 60 minutes and up to 30 minutes in pathological (fatty or cirrhotic) livers, although much longer durations of continuous clamping 127 minutes in normal livers and 100 minutes in pathological livers have been reported to be safe²⁶⁻²⁷. One way to extend the duration of clamping and to reduce ischaemia to the remnant liver is by the intermittent Pringle manoeuvre (IPM). It involves periods of inflow clamping that last for 15-20 minutes followed by periods of unclamping for five minutes (mode 15/5 or 20/5), or five minutes clamping followed by one minute unclamping (mode 5/1)²⁸⁻²⁹ IPM permits a doubling of the ischaemia time, when compared with CPM and the total clamping time can be extended to 120 minutes in normal livers and 60 minutes in pathological livers. The disadvantage of IPM is that bleeding occurs from the liver transaction surface during the unclamping period and, thus, the overall transection time is prolonged as more time is spent in achieving haemostasis. Belghiti et al (1999) revealed that there was no significant difference in total blood loss or volume of blood transfusion between CPM and IPM (mode 15/5). However, they noticed that pathological livers tolerated CPM poorly.

A newer perspective on inflow occlusion comes from the concept of ischaemic preconditioning (IP). It refers to an endogenous self-protective mechanism by which a short period of ischaemia followed by a brief period of reperfusion produces a state of protection against subsequent sustained ischaemia-reperfusion injury [30]-[31]. The IP is performed with ten minutes of ischaemia followed by ten minutes of reperfusion before liver transaction with CPM [32].

Hemihepatic clamping (half-Pringle manoeuvre) interrupts the arterial and portal inflow selectively to the right or left liver lobe that is to be resected [33]-[34]. It can be performed with or without prior hilar dissection. It can also be combined with simultaneous occlusion of the ipsilateral major hepatic vein. The advantage of this technique is that it avoids ischaemia in the remnant liver, avoids visceral congestion and allows clear demarcation of the resection margin. The disadvantage is that bleeding from the parenchymal cut surface can occur from the nonoccluded liver lobe.

Segmental vascular clamping entails the occlusion of the ipsilateral hepatic artery branch and balloon occlusion of the portal branch of a particular segment. The portal branch is identified by intra-operative ultrasound and puncture with a cholangiography needle through which a guide wire and balloon catheter is passed [35],[36].

Total vascular exclusion (TVE) combines total inflow and outflow vascular occlusion of the liver, isolating it completely from the systemic circulation. It is done with complete mobilisation of the liver, encircling of the suprahepatic and infrahepatic IVC, application of the Pringle manoeuvre, and then clamping the infrahepatic IVC followed by clamping of the suprahepatic IVC. TVE is associated with significant haemodynamic changes and warrants close invasive and anaesthetic monitoring. Occlusion of the IVC leads to marked reduction of venous return and cardiac output, with a compensatory 80% increase in systemic vascular resistance and 50% increase in heart rate and, thus, not every patient can tolerate it. TVE can be applied to a normal liver for up to 60 minutes and for 30 minutes in a diseased liver. The ischaemic time can be extended when combined with hypothermic perfusion of the liver [37]-[38]. Apart from the unpredictable haemodynamic intolerance, post-operative abdominal collections or abscesses and pulmonary complications are more common in TVE, when compared with CPM.

Inflow occlusion with extraparenchymal control of hepatic veins is a modified way of performing TVE. The main and any accessory right hepatic vein, the common trunk of the middle and left hepatic veins, or the separate trunks of the middle and left hepatic veins (15% of cases) are first dissected free and looped. It has been reported that the trunks of the major hepatic veins can be safely looped in 90% of patients [39]-[40]. The loops can then be tightened or the vessels clamped after inflow occlusion is applied, so that the liver lobe is isolated from the systemic circulation without interrupting the caval flow. It can be applied in a continuous or intermittent manner. The maximal ischaemia time is up to 58 minutes under continuous occlusion. This technique is more demanding than TVE, but it can avoid the haemodynamic drawbacks of TVE while at the same time provide almost a bloodless field for liver transection.

Instruments and technique for resections: Although a large part of improvements of these last decades in liver surgery can be correlated to a better knowledge of the surgical hepatic anatomy (Couinaud's segmentation of liver [41]), better monitoring during anaesthesia and introduction of intra-operative ultrasonography and of other imaging techniques, the choice of surgical technique for sectioning the liver has surely important repercussions on the intervention's outcome. Furthermore in the last two decades improvements in technology allowed the development of a large number of instruments with the aim to reduce blood loss during surgical procedure. The main part of these tools have been developed or applied to liver surgery. The rationale in liver transection is to employ an instrument that can selectively

eliminate parenchyma leaving vital structures intact. In other words, a resistance modulated device, able to fragment low-resistance tissue (hepatic parenchyma) preserving fibrous (high-resistance) components such as vessels and biliary ducts, successively ligated by the surgeon. To date, no single instrument has been designed to adequately satisfy both of these tasks.

There are two techniques we could define traditional: the *finger fracture method* and the *clamp crushing method*. These are the oldest techniques for hepatic transection and are still employed especially by long experienced surgeons. Techniques of liver transection gained marked attention since the introduction of the clamp-crushing technique in the 1970s.^{10,11} As a refinement of the finger fracture method, it has served as the reference technique for liver transection ever since.

The use of traditional techniques to isolate bile ducts and vascular pedicles from the surrounding parenchyma provides for employment of clips or sutures for sealing bile ducts and vascular vessels and for other haemostasis techniques to stop haemorrhage from the resection's surface. There are several studies those sustain that traditional methods are still competitive with new technique based on utilization of special devices [1],[42],[96] In a recent Metanalysis Rahbari and coll concluded that the clamp-crushing technique could be still recommended as the reference method for the transection of the parenchyma during liver surgery [12], [4].

Introduction of new devices for liver dissection surely have an important role, in particular for reduction of intra-operative blood loss. Actually the most important devices useful for liver resection are the followings, presented as they are from a technical point of view and analysed to find the advantages (A) and the disadvantages (D) correlated to their employment and divided according to the source of energy employed. There are two types of transection devices: those mainly used for dissection (e.g. the haemostatic clamps or ultrasonic dissector) and mainly used for haemostasis and coagulation (e.g. sutures, endo-staplers, sealers, etc.) (table 2). Moreover the water-jet, the ultrasonic aspirator (CUSA®) and the blunt dissection can be categorised under selective dissection techniques. Non-selective techniques cannot discriminate between duct structures and parenchyma. To mention are finger fracture and mechanical instruments as the scalpel, the scissors and with reservation the linear stapler as well as thermal instruments as the high-frequency electrocoagulator, the laser, the bipolar forceps or the scissors of the UltraCision®

Preparation	Transection
Finger fracture	ligation
crush/clamp	clips
suction knife	electrocoagulation (mono/bipolar)
CUSA	Microwave tissue coagulation
Water Jet	Ultracision
Jet-Cutter	Ligasure
Tissuelink	Gyrus
Aquamantys	

Table 2. Surgical techniques for preparation and tissue transection of the liver

Furthermore most attempts have involved use of radiofrequency ablation-based instruments in a “precoagulation strategy” in which the energy device is used to burn and seal the parenchyma before sharp dissection. In the second strategy, ultrasonic-activated instruments cut through the liver while sealing the vessels. Both methods suffer from the fact that large vessels are poorly visualized and can bleed on transection. In addition, blood or biliary vessels from adjacent parts of the liver meant to be salvaged can be inadvertently injured by this “blind” coagulation.

3.1. Tools based on ultrasound technology

Harmonic Scalpel, HS (Johnson and Johnson Medical, Ethicon, Cincinnati, USA): Also known as “Ultrasonically Activated Scalpel” or “Ultrasonic Coagulation Shears”, this instrument was introduced in the early 1990s. The ultrasound scissors system includes a generator with a foot switch, the reusable handle for the scalpel and the cutting device with scissors. The scissors are composed by a moveable blade and by a fixed longitudinal blade that vibrates with an ultrasonic frequency of 55.5 kHz (55,500 vibrations per second). HS can simultaneously cut and coagulate causing protein denaturation by destroying the hydrogen bonds in proteins and by generation of heat in vibrating tissue. This generated heat denatures proteins and forms a sticky coagulum that covers the edges of dissection. Although the heat produces no smoke and thermal injury is limited, the depth of marginal necrosis is greater than incurred by either the water jet or CUSA. The lateral spread of the energy is 500 micrometers.

A: HS is the only instrument that can simultaneously cut and coagulate (it can coagulate vessel until 2-3 mm of diameter [43]); it’s useful on cirrhotic liver [44]; no electricity passes through the patient and there’s no smoke production (especially useful in laparoscopic surgery); it can be used in laparoscopic and laparotomic surgery. **D:** The instrument results in a continuous bleeding risk related to the blind tissue penetration to coagulate vessels hidden into the hepatic parenchyma. Studies demonstrate that HS is not capable to reduce blood loss and operating time compared to traditional techniques [45]-[46], cannot coagulate vessel over 2-3 mm of diameter which have to be clipped, ligated or sealed with other instruments; HS is not easy to use as a blunt dissector and have substantially demonstrated its usefulness only during the resection of the superficial part of liver (2, 3 cm) free from large vessels and bile ducts; besides some studies have demonstrated that HS increases the rate of post-operative bile leaks [47]-[48] raising concern that HS may not be effective in sealing bile ducts. This postoperative bile leakage occurred because Glisson’s sheath was not completely sealed when the HA is used blindly in the deep liver parenchymal layer. It was difficult to seal the sheath precisely in the deep liver parenchymal layer.

The use of HS in liver cirrhosis is controversial. The greatest concern with the use of the harmonic scalpel is the risk of shearing [49]. Slight errors of movement can shear parenchyma without completely coagulating vessels and/or ducts. Moreover it’s expensive (the generator costs US\$ 20,000 and the handle US\$ 250). An evolution for the harmonic Scalpel is the Harmonic FOCUS. Using this device the liver parenchyma is crushed by the nonactivated HF, which blades are similar to Kelly forceps, and the tiny areas of residual tissue are checked and completely sealed with the activated HF without changing to forceps. This device allows, after

accurate exposure, a sealing “under view” of tiny vasculatures and biliary structures and this seems to reduce bleeding and postoperative bile leakages. [125-126] This new technique has been called “fusion technique”. The attempt to accomplish both the task of division and of hemostasis is provided by a recently introduced device, which intends to crush liver parenchyma simultaneously sealing the vessels without the need to change the instrument, the so called focus-clysis or ‘fusion technique’

Functionally, the instrument should be compared to a Kelly, in which the surgeon can adjust the precision and depth of cutting by modulating blade pressure; parenchyma crushing exposes the tiny vessels that can be coagulated employing the harmonic technology provided in high power (1–2 mm vessels) and low power (up to 5 mm). Vessels larger than 5 mm in diameter should be divided and ligated in a traditional fashion. It seems that the ‘fusion technique’ could reduce blood loss and the incidence of biliary fistula, with a cost comparable to other technologies.

Cavitron Ultrasonic Surgical Aspirator, CUSA (Valleylab) (Fig 2): The use in liver surgery of this instrument, also known as Ultrasonic Dissector, was described for the first time in literature in 1979 by Hodgson [50]. CUSA is a surgical system in which a pencil-grip surgical hand piece contains a transducer that oscillates longitudinally at 23 kHz and to which a hollow conical titanium tip is attached. The vibrating tip of the instrument causes explosion of cells with a high water content (just like hepatocytes) and fragmentation of parenchyma sparing blood and bile vessel because of their walls prevalently composed by connective cells poor of water but rich of intracellular bonds. This device (together with hydrojet dissector) should be considered among that tools able to selectively divide parenchyma from vessels according to their different mechanical resistance (in which hepatocytes contain less fibrous tissue than the vessel, thus offering less resistance to crushing during parenchymal division), the so called selective dissection technique.

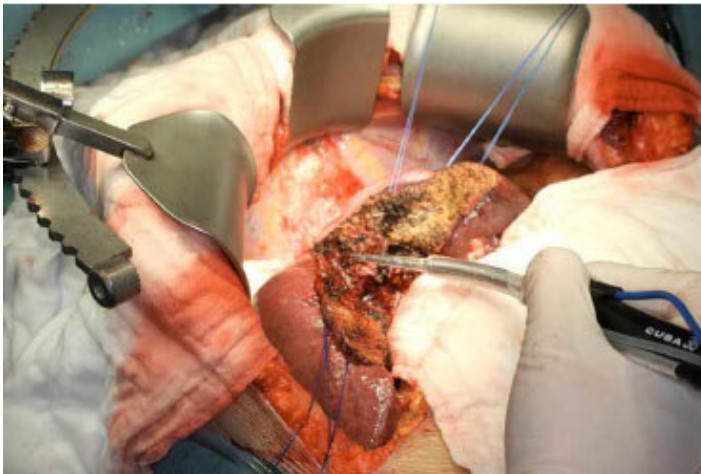


Figure 2. Parenchyma transection using CUSA

The device is equipped by a saline solution irrigation system that cools the hand piece and wash the transection plane and by a constant suction system that removes fragmented bits of tissue and permits excellent visualization. **A:** CUSA is capable to dissect offering excellent visualization resulting useful in particular during non-anatomical resections and approaching the deeper portion of the transaction plane [51]-[52]. The instrument allows surgeons to see clearly blood and biliary vessels as they dissect through the liver [53], (2) use of the instrument allows them to avoid prolonged extrahepatic vascular control, and (3) the operation actually takes less time because the vessels are continuously controlled during the dissection and there is little need for a prolonged search for bleeding or biliary vessels after the specimen has been removed.

A previous retrospective study from Fan showed that the ultrasonic dissector resulted in lower blood loss, lower morbidity, and lower mortality compared with the clamp crushing technique [54] Furthermore, ultrasonic dissection resulted in a wider tumor-free margin because of a more precise transection plane.

D: CUSA can't coagulate or realize haemostasis so it need to be used in couple with an other instruments to achieve hemostasis and biliostasis. Even if some studies sustain it to be capable to reduce intra-operative blood loss, operating time and duration of vessel occlusion [55], important studies demonstrate that CUSA can't offer these advantages if compared with traditional techniques; a prospective trial by Rau et al. showed no statistical difference in reduction of blood loss with the use of CUSA as compared to conventional methods [56]; and another trial by Takayama et al. [52], in fact, noted a greater median blood loss. CUSA causes more frequent tumour exposure at the surgical margin than traditional techniques[1] and it's less useful for cirrhotic livers because the associated fibrosis prevents easy removal of hepatocytes [57]; besides some authors found using CUSA method (compared to clamp crushing method) an increase of venous air embolism without evidence of hemodynamic compromise but with increased risk of paradoxical embolism in cirrhotic patients [58]. Moreover CUSA should be used in association with other devices which are able to perform hemostasis. The instrument seems cumbersome and complicated to inexperienced operating room personnel. Therefore, it is easy for the instrument to malfunction. The fact that the instrument works by removing a margin of liver tissue makes it, by nature, less attractive for harvesting liver for living-donor transplantation.

3.2. Tools based on radiofrequency technology

Tissuelink Monopolar Floating Ball, TMFB (Floating Ball, TissueLink medical, Dover, NH, USA) (Fig 3): This new instrument put on the market in 2002 is a linear device that employs Radiofrequency energy focused at the tip to coagulate target tissue. The tip is provided with a low volume (4-6 ml/min) saline solution irrigation that makes easier the conduction of RF in surrounding tissue and cools the tip itself avoiding formation of chars. TMFB can seal vascular and bile structures up to 3 mm in diameter by collagen fusion. These qualities makes this device an excellent instrument for achieving haemostasis and in particular for pre- coagulating (with a painting movement) parenchyma and vessels prior to transection, preventing blood loss.

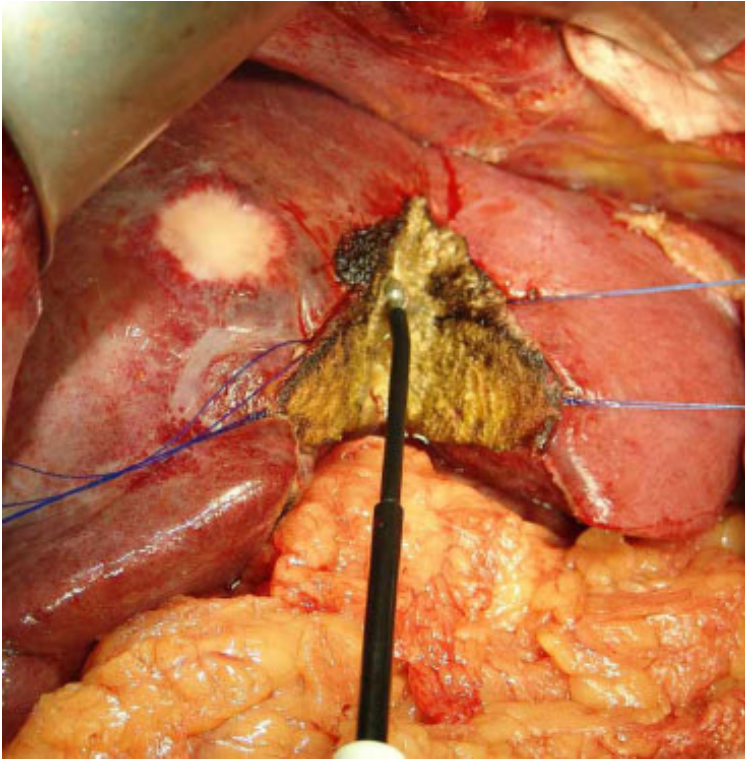


Figure 3. The Tissue Link working performing a liver resection

Otherwise continuously heating tissue underneath a cool layer, however, causes a build up of steam that can result in tissue destruction. The latter phenomenon is known as steam popping [59].

There are two models on the market, the DS3.0 with blunt tip that simply coagulates and the DS3.5-C Dissecting Sealer that is provided with sharp tip that can also dissect. A: The instrument is, in a sense, “friendlier” to most surgeons. In other words, surgeons, who are usually adept at using cautery, can easily understand this mechanism of action and use it accordingly. TMFB can coagulate (and the Dissecting Sealer can also cut) tissues and seals blood and bile ducts up to 3 mm in diameter, is able to reduce blood loss and the recourse to vessel occlusion techniques if compared to traditional techniques [60],[61],[62], offers good results also in cirrhotic livers and cystopericystectomy [63] and has a saline irrigation that avoids production of smoke, chars and sticky coagulum to which the device could stick causing new bleeding when it’s moved away. TMFB, used on the cut liver surface after dissection, destroys eventual additional cancer cells at the margin of resection; in order to assure sterile margins, extra tissue destruction at the margins of resection may be desirable for tumor excisions. Otherwise this could be a disadvantage in case of living donor liver transplantation. It’s available for both

laparotomic and laparoscopic surgery and it's quite cheap and compatible with most electro-surgical generator currently available.

D: TMFB is not able to coagulate vessel over 2-3 mm of diameter which have to be clipped, legated or sealed with other instruments [64]. So the instrument should be used in combination with other instruments or clips or ties. Moreover studies do not demonstrate it's efficacy to reduce operating time if compared with traditional techniques [65].

Bipolar Vessel Sealing Device, BVSD (LigaSure, Valleylab Inc. Boulder, Colorado, USA) (fig 4): The use in liver surgery of this instrument was described for the first time in literature in 2001 by Horgan [67]. The LigaSure System includes a generator with a foot switch and a clamp-form hand piece that can be used for parenchymal fragmentation and isolation of blood and bile structures just like in clamp crushing technique before application of energy; it employs RF to realize permanent occlusion of vessels or tissue bundle. The LigaSure generator has a Valleylab's Instant Response technology, a feedback-controlled response system that diagnoses the tissue type in the instrument jaws and delivers the appropriate amount of energy to effectively seal the vessel: when the seal cycle is complete, a generator tone sound, and output to the handset is automatically discontinued. BVSD is capable to obliterate the lumen of veins and arteries up to 7 mm in diameter by the fusion of elastin and collagen proteins of the vessel walls; that makes BVSB the only safe and real alternative to sutures and clips for sealing vessel [68],[69],[70].

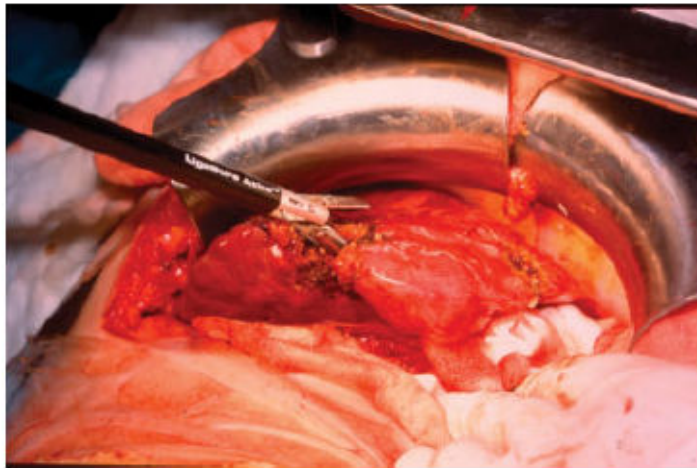


Figure 4. The Ligasure Atlas during parenchyma transection

A: BVSD coagulates sealing vessels up to 7 mm in diameter with minimal charring, thermal spread or smoke, it's capable to reduce blood loss and the need for vessel occlusion techniques if compared to traditional techniques [8],[71],[72], A recently published randomized controlled

trial demonstrated that the use of Ligasure in combination with a clamp crushing technique resulted in lower blood loss and faster transaction speed in minor liver resections compared with the conventional technique of electric cautery or ligature for controlling vessels in the transection plane [73]. Otherwise a more recent randomized trial from the same team was not able to show a real difference between the traditional techniques and the Ligasure vessel sealing system [74]. The instrument is available for both laparotomic and laparoscopic surgery [75]. Furthermore the use of Ligasure System is not correlated with an increase of the rate of post-operative bile leaks and in some study bile leakage was nihil [76]-[127] and that proves his effectiveness in obliterate also bile vessel. **D:** after the application the coagulated tissue often sticks to the instrument's jaws causing new bleeding when the device is moved away; BVSD seems to be less effective in presence of cirrhosis for two reasons: first the portal hypertension correlated with cirrhosis causes thinning of the dilate portal vein's walls and makes their obliteration less effective; second cirrhosis makes crushing technique difficult and the hepatic tissue between the blades may disperse the power applied causing vessel to bleed [128]; moreover it seems to be ineffective in cystopericystectomy [77] (even if some surgeons sustain his effectiveness in this surgery [78]). Ligasure vessels sealing system has been widely use during liver transection in a "blind" way [70]-[71], achieving parenchymal fracture and vessel sealing in the same time without identification of tiny vasculatures and bile ducts. This could be considered a limits of this tools which do not allow the surgeon to clearly check the structures which are going to be sealed. To overcome this limit a technique similar to the "fusion technique" used with Harmonic FOCUS has been developed for the Ligasure vessel sealing system [130]., using the Ligasure precise. With this technique using LigaSure itself, the hepatic parenchyma was widely and gently crushed and confirmed that the remnant vessels and tiny vessels (2mm in diameter) were divided by the LigaSure under direct vision. This allow to coagulate only vessels appropriate for sealing with this instrument and imprtant vascular pedicles to adjacent segments can be visualized and protected. Larger vessels (3mm in diameter) were tied by absorbable braid. This approach seems to reduce transection time and is the so called "postcoagulation technique" [138].

Habib's technique: This technique, invented by Habib in 2002, is also known as Bloodless Hepatectomy Technique [10],[88]. Resection is conducted using cooled tip RadioFrequency probe those contain a 3 cm exposed tip to coagulate liver resection margins. Once a 2 cm-wide coagulative necrosis zone is created by multiple applications of the probes in adjacent zones and at different depths, the division of the parenchyma with a surgical scalpel is possible without any bleeding. Both the remnant liver and the removed specimen have on the margin of resection a portion of necrotic coagulated liver 1 cm thick.

A: The primary problem with each of the previous devices is that whilst small vessels can be coagulated during transection, larger vessels are often left patent and injured, which can result in considerable blood loss requiring tedious clipping and suturing in order to achieve haemostasis.

Habib's Technique allows hepatic resections with marginal blood loss, without any vessel occlusion technique or intra or post-operative transfusions, coagulating each vessel encountered in the field of energy application; In a preliminary study of 15 cases of mainly segmental or wedge resection reported by Weber et al., the mean blood loss was only 30 ± 10 ml, and no complications such as bile leakage were observed [88]. Another group also reported low blood loss

using this technique in liver resection [89]. Haemostasis is obtained only by RF thermal energy: no additional devices like stitches, knots, clips or fibrin glue are needed [10],[88],[90],[91]; it's effective also in the cirrhotic liver and the 1-cm-thick of burned coagulated surface assures margins free from tumour. The technique has the advantage of simplicity compared with the aforementioned transection techniques. As the RF assisted technique allows parenchymal sparing during the first resection, this in turn results in more repeat liver resections being possible for recurrences. It also enables nonanatomical resections during these repeat resections.

D: Habib's technique cannot be applied near the hilum or the cava vein for fear of damaging this structures and because the blood flow of large vessels subtracts RF energy and involves an incomplete coagulative necrosis [92],[93] (up to now the technique has been experienced only for segmental resection); the 1-cm-thick of burned coagulated layer in the surface involves the loss of part of healthy parenchyma and a higher rate of post-operative abdominal abscesses [91],[94]. Moreover one potential disadvantage of this technique is the sacrifice of parenchymal tissue in the liver remnant, with a 1 cm wide necrotic tissue at the transection margin, which may be critical in cirrhotic patients who require major liver resection or in case of liver resection for living donor liver transplantation. An evolution of the Habib probe is the Habib 4X [92] which address the problem of time consuming and the risk of skin burns from the grounding pad related to previous device. The device was introduced perpendicularly into the liver, abutting the transection line (Figure 5). The generator was programmed to produce an alert signal when energy delivery had been automatically stopped, thus avoiding over coagulation and carbonation. The probe was gently moved to and fro in its vertical axis for 3e5 mm throughout the coagulation process to avoid adherence of the probe to the liver parenchyma. The probe was then reintroduced adjacent to the last coagulated area in a serial fashion, until the area to be transected was fully ablated. The number of applications required to create a complete zone of desiccation was related to the size of the cut surface of the resection margin.

1. A second line of ablation, parallel to the first line and closer to the tumour edge, was then done to ensure complete tissue coagulation and perfect haemostasis prior to transection
2. The Habib 4X was then applied perpendicularly to the previous two lines of ablation, so as to ensure complete coagulation of any residual normal liver parenchyma. This allowed a margin of coagulated liver parenchyma to remain; ensuring vessels and bile ducts remained sealed. For deeper tumours the device was applied at an angle of 45 degrees to the surface. This technique allow to achieve a very low rate of blood transfusion in a very large series [88]

Gyrus plasmakinetic pulsed bipolar coagulation device: Gyrus /Gyrus medical inc., Maple Groves, Mn, USA) is a bipolar cautery device which seals the hepatic parenchyma using a combination of pressure and energy that results in the fusion of collagen and elastin in the walls of the hepatic vasculature and bile ducts [98]. The device can reliably seals vessels up to 7 mm in diameter minimizing the amount of blood loss during the transection of the liver. Thermal spread and sticking to tissues is reduced by a cooling period after each pulse as the

impedance of the coagulated tissue increased. This instrument has been previously widely used in gynaecological procedures and its use in liver surgery is relatively new.

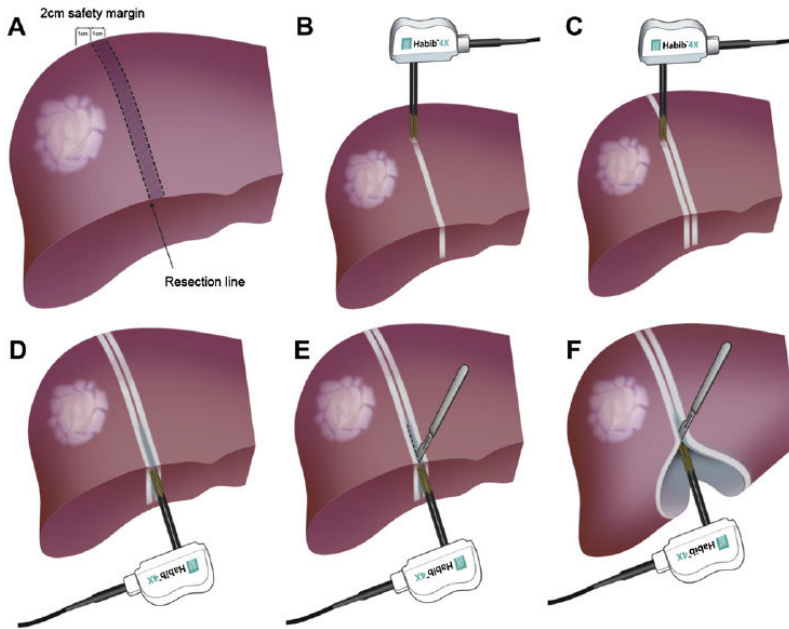


Figure 5. Habib technique for liver resection

A: It could be used in a similar manner to the clamp-crush technique to transect hepatic parenchyma. After incising the hepatic capsule with bovie the instrument is inserted into the liver in an open manner and bipolar energy is applied as the forceps are slowly closed over the parenchyma. The cauterized liver is subsequently transected with Metzenbaum scissors. The device was used for the entire hepatic parenchymal transection; only named vascular and biliary structures required additional attention and were stapled or suture ligated. The device exhibits a minimal thermal spread of 2–3 mm and was frequently used for parenchymal transection abutting the hepatic hilum. With the exception of large, named vascular and biliary structures which were routinely stapled or ligated, excellent haemostasis and biliary duct fusion were achieved uniformly.

In a recent series median blood loss rate compare favourably with those in several large series using the traditional clamp-crush technique [99]. Moreover blood loss and transfusion rates were comparable with those cited in recent report of alternative parenchymal transection, as showed by results of Tan et Al [100]. In this study Gyirus compared favourably with Harmonic scalpel in term of Bile leakage and the author underlined the concorrential cost of the device. Moreover it seems to be useful even in case of cirrhotic patients. Corvera et al. [98] have also reported the use of the Gyirus device in cirrhotic livers comparing it to the clamp and crush

technique. They evaluated five patients in each group showing similar results between the two groups in terms of operating time, blood loss and major post-operative complications.

D: as the ligasure vessel sealing device one of the limit of this device is the “blind” use without clear identification of vascular and biliary structures before sealing

The Aquamantis System: The Aquamantys System employs Transcollation[®] technology (fig 6) to simultaneously deliver RF (radiofrequency) energy and saline for haemostatic sealing and coagulation of soft tissue and bone at the surgical site. Transcollation technology is used in a wide variety of surgical procedures, including orthopaedic joint replacement, spinal surgery, orthopaedic trauma and surgical oncology. Transcollation technology simultaneously integrates RF (radiofrequency) energy and saline to deliver controlled thermal energy to the tissue. This allows the tissue temperature to stay at or below 100°C, the boiling point of water. Unlike conventional electrosurgical devices which operate at high temperatures, Transcollation technology does not result in smoke or char formation when put in contact with tissue. Blood vessels contain Type I and Type III collagen within their walls. Heating these collagen fibers causes radial compression, resulting in a decrease in vessel lumen diameter. Using the Aquamantys generator with patented bipolar and monopolar sealers, surgeons can achieve broad tissue-surface haemostasis by applying Transcollation technology in a painting motion, or it can be used to spot-treat bleeding vessels. This is capable of sealing structures 3–6 mm in diameter without producing high temperature or excessive charring and eschar. Structures more than 6 mm in diameter should be divided in conventional manner with clips or ties. Constant suction is required to clear the saline used for irrigation.

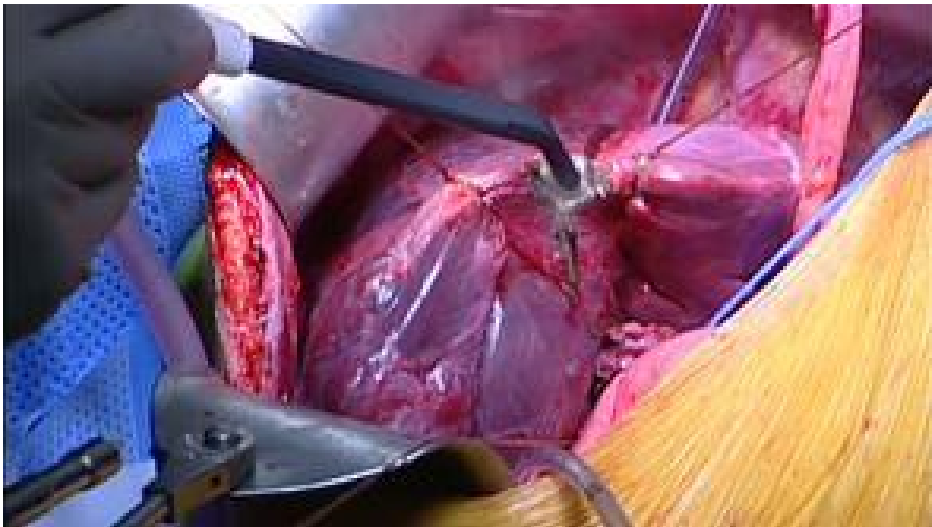

Figure 6. Aquamantys transcollation technology performing liver resection

A: its use is “friendlier” to most surgeons, easy to learn most surgeons are comfortable after 5–6 procedures. It seals blood and bile ducts up to 6 mm in diameter, is able to reduce blood loss and the recourse to vessel occlusion techniques. Moreover it offers good results also in cirrhotic livers [66] and destroys eventual additional cancer cells at the margin of resection.

D: it is expensive and pace of liver transection could be low. Moreover there is a lack of data reported in literature due to the relative novelty of this device.

Coolinside: The new Coolinside® device (Apeiron Medical, Valencia, Spain) is a hand-held device which simultaneously coagulates (using RF) and cuts (by means of a cold scalpel) the liver. This device and its manipulation is built for both laparotomic and laparoscopic procedures. Coagulation is performed by a blunt tip metallic electrode positioned at the distal edge, which is electrically connected to a Cosman CC-1 coagulator system (Radionics, Burlington, MA, USA) operating at a maximum power of 90W. The liver tissue is cut using a thin blade at the distal edge. Inside it the active electrode has a closed hydraulic circuit containing saline solution at a temperature of 0 °C, which is propelled to the distal edge by a Radionics continuous perfusion pump (Burlington, MA, USA) at a speed of approximately 130 mL/min. The cold liquid keeps the surface of the tissue below 100 °C by refrigerating the active electrode. The feedback system for the warm saline solution means that it can never come into contact with the patient (as in the case of the Tissuelink® device).

A: The key to the performance of the device is in the fact that the depth of hepatic parenchymal transection is adapted to the coagulation effect achieved by the proximal edge of the active electrode, that part which first comes into contact with the tissue. In this way, every time the surgeon moves the device over the surface of the liver, the parenchyma is cut and coagulated simultaneously [132]. In this study 11 hepatic resection were performed entirely with coolinside without the need for ligature or clips or pringle manouver, with no bile leak complication and high transection speed. This device combines coagulation and transection capacity and it does not need to be combined with other devices (not even stitches or clips). Moreover, it is not necessary to perform vascular occlusion, parenchymal coagulation is homogeneous and, lastly, there is the possibility of using it in laparoscopic surgery.

D: As with other RF devices, tissue pre-coagulation can change structures so that it can be difficult to identify the main hepatic vessels or conduits. Moreover, the amount of hepatic tissue that is sacrificed may be greater than in the case of other techniques, given that with this device the coagulated area may be up to 5 mm, which might limit but not contraindicate this technique in cirrhotic patients. Moreover this could be considered a disadvantages in case of liver resection during living donor liver transplantation

3.3. Others source of energy

Water Jet Scalpel, WJS: The WJS was introduced in 1982 by Papachristou [79]. This tools could achieve, as well as CUSA, a selective dissection.

The dissection modalities which take advantage of the anatomic conditions are called selective. The water-jet effects hereby like an intelligent knife and separates the more resistant duct- and

vessel structures automatically from the parenchyma which thus become visible. When visible they can be closed easily under controlled conditions.

The device consists of a pressure generating pump and a flexible hose connected to the hand piece. The liquid (saline solution) flows at a steady stream and is projected through the nozzle at the tip of the hand piece. The jet hits the liver at the desired line of transection and washes away the parenchyma, leaving the intra-hepatic ducts and vessel undamaged; then the vascular and bile structures can be ligated and the transection plane coagulated. The tip is reinforced by a suction tube which removes excess fluid; besides splashing is avoided by covering the area of dissection with a transparent sheet or a Petri dish. Compared to the CUSA, the water jet leaves a smoother cut surface and little hepatic degeneration or necrosis at the borders.

A: WJS can dissect offering excellent visualization and is effective also in the cirrhotic liver. In the only available prospective randomized trial of water jet in the literature, in which 31 patients underwent liver resection using water jet and another 30 patients underwent liver resection using CUSA, water jet transection reduced blood loss, blood transfusion, and transection time compared with CUSA [80]. water jet techniques is quite good for dissecting out major hepatic veins when tumors are in proximity. This allows for delineation of hepatic veins, particularly at the junction with the inferior vena cava, and prevents positive margin. It allow the so called selective dissection technique.

D: WJS can't coagulate or realize haemostasis and some study demonstrate that it cannot achieve a reduction of intra-operative blood loss and operating time if compared with traditional techniques [81],[82]; using this technique is possible cancerous seeding of the healthy abdominal organs and infection of the operators by hepatic viruses. Moreover in literature some cases of gas embolism are described using this device [83]. Furthermore the instrument may be more effective than the CUSA with respect to operating in the presence of cirrhosis. Papachristou and Barters [79] initially reported that the water jet was likely to be ineffective when there is increased fibrotic tissue. Later papers, however, describe successful resections with cirrhosis by using higher jet pressures. Une et al. [80] report that one does not need to use higher water jet pressures to dissect cirrhotic tissue effectively; instead, the same pressures as for normal parenchyma just need to be applied longer. The major concern of surgeons using the water jet is the associated splash. The latter effect is caused by solution bouncing off tissues. Besides the obvious infectious concerns of the possibility of contaminating operating room personnel, the splash brings up the notion of the possibility of cancerous seeding. This possibility must be considered in operations for malignancy and one needs to take additional care not to expose the gross tumor during the dissection.

Staplers (fig 7): Since the nineties vascular staplers to divide hepatic veins and portal branches during hemihepatectomy are considered an achievement that aids in minimizing blood loss and thereby reduces the need for inflow occlusion. Further, staplers seem to be advantageous in the unroofing of hepatic cysts since any inadvertently injured bile duct or blood vessel is sealed [84].

Staplers can be used in liver surgery for control of inflow and outflow vessels, or to divide liver parenchyma [84],[85]. The stapler is rarely used as the principal instrument in hepatic resection. The device can add speed to the operation in open or laparoscopic surgery. Its primary use is for achieving control of hepatic vasculature, particularly the hepatic veins. The use of vascular staplers to divide hepatic veins and portal branches is considered an achievement that has aided in minimizing blood loss and thereby reduced the need for inflow occlusion. Recent publications reporting a number of techniques using stapling devices in liver surgery showed them to be extraordinarily useful in the safe ligation of inflow and outflow vessels.

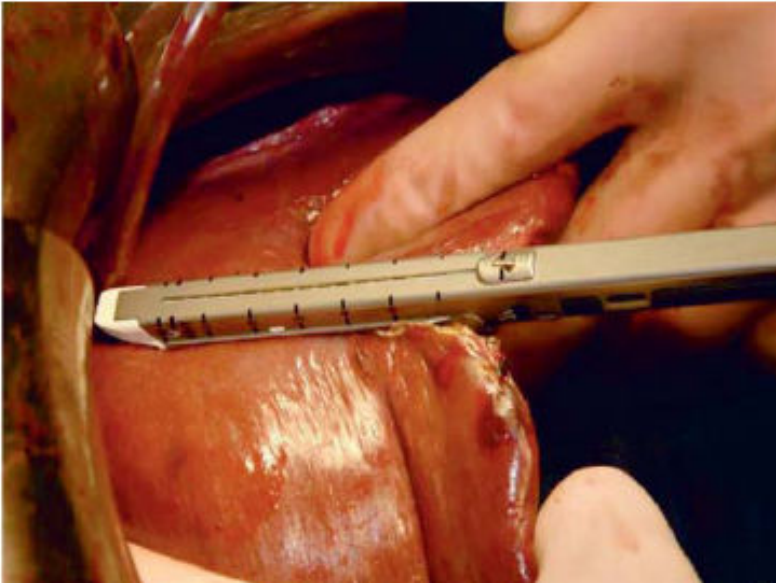


Figure 7. Parenchyma transection performed using a Stapler

Biliary radicals can be incorporated efficiently into the staple line. Division of the hepatic veins with a stapler as opposed to direct ligation proffers several advantages. First, it eliminates the risk of dissecting the hepatic veins and minimize the risk of slipped ligation. Furthermore the stapler simultaneously divides multiple venous branches, especially on the right side, that are too short to allow for a safe and rapid more traditional ligation.

A: It is particularly useful in dividing the major trunk of hepatic veins or the middle hepatic vein deep in the transaction. Vascular staplers also can be used to divide the hepatic duct pedicle in right or left hepatectomy [7]. The procedure starts by dividing the liver capsule by diathermy the use of a stapler for transection of the liver parenchyma following by fracturing the liver tissue with a vascular clamp in a stepwise manner and subsequently divided with an EndoGIA vascular stapler. In a large series of 300 stapler hepatectomies, including 193 major

hepatectomies, mortality of 4% and morbidity of 33% were reported which is comparable with conventional liver resection techniques. Vascular control was necessary in only 10% of the series, with an overall median blood loss of 700 mL [86]. The rate of biliary leakage seems to be very low, with a 8% reported in the largest series [86]. Moreover the transection speed is the highest among all the techniques employed. Most recently, an ultrasound-directed transparenchymal application of vascular staplers to selectively divide major intrahepatic blood vessels before the parenchymal phase of liver resection has been shown to minimize blood loss, warm ischemia time, and operative time [131]¹

More to the point, in cases of difficult parenchymal transection with ongoing bleeding, the stapler device offers faster specimen removal giving the surgeon the opportunity to control the loss of blood from the raw liver surface

D: Although the technique appears attractive, the financial cost is a serious drawback. One problem associated with the use of a stapler for liver transection is increased risk of bile leak, since the stapler is not very effective in sealing small bile ducts [87]. Otherwise other studies report a very low rate of biliary injury and leakage. Moreover the surgeon must also be selective in the use of a stapler for the treatment of tumors particularly near the hilum in order to obtain sufficient margin. In case of stapler malfunction the surgeon should be ready with a back up technique to achieve vein control in case of sudden hemorrhage. Serious blood loss can theoretically occur when the stapler has sealed only half the diameter of the vessel or after misfire of the device.

Chang's needle technique: This technique presented by Chang in 2001 [95] is based on the utilization of a special instrument equipped with a 18 cm straight inner needle with an hook near its top; Chang needle can be applied repeatedly to make overlapping interlocking mattress sutures with N° 1 silks along the inner side of the division line. After this phase liver parenchyma can be divided directly by scissors, electrocautery or traditional resection methods applying new suture only for tubular structures of significant size.

A: Chang's needle technique can be performed without application of any vessel occlusion techniques, without any other haemostatic technique and reducing blood transfusions; this method seems to be capable to reduce both intra-operative blood loss and resection time; besides it's surely cheap and is reported to be simple too [96].

D: It can't be applied if the lesion is too close to inferior cava vein [97]

3.4. Combined techniques

In the last decades a combined use of the devices previously analyzed has been reported in literature to increase the efficacy of each device, based on consideration that we have 2 different kind of instruments (as shown in table 3): those that allow a preparation of vascular structures achieving a selective dissection and those that allow a non-selective dissection (with a blind coagulation of the vasculature and biliary structures). Efficient and safe liver parenchymal transection is dependent on the ability to simultaneously address 2 tasks: parenchymal division and hemostasis. Because no single instrument has been developed that is adequate

for both of these tasks, most hepatic parenchymal transections are performed using a combination of instruments and techniques.

Aloia *et al.* developed a 2-surgeons technique which combine saline-linked cautery and ultrasonic dissection [133]. This techniques allowed a reduction in the operative time when compared to ultrasonic dissection alone. Moreover blood loss and lenght of operation seems to be reduced.

Reference	Patients	Technique	Blood loss/ transfused patients	Operative time, min	Transection speed, cm ² /s
Takayama <i>et al.</i> [8]	132 (66 vs. 66)	Clamp-crush technique	452 ^a /NA	54 ^b	1.0
		Cavitron ultrasonic surgical aspirator	515 ^a /NA	61 ^b	1.1
Rau <i>et al.</i> [9]	61	Hydrojet dissector	NA/1.5	28 ^b	NA
		Cavitron ultrasonic surgical aspirator	NA/2.5	46 ^b	
Koo <i>et al.</i> [22]	50 (25 vs. 25)	Clamp-crush technique	792 ^a /NA	119	NA
		Cavitron ultrasonic surgical aspirator	875 ^a /NA	139	
Lesurtel <i>et al.</i> [16]	100 (4 groups, 25 each)	Clamp-crush technique	1.5 ^c NA	NA	3.9
		Cavitron ultrasonic surgical aspirator	4 ^c /NA		2.3
		Hydrojet dissector	3.5 ^c /NA		2.4
		Radiofrequency dissecting sealer	3.4 ^c /NA		2.5
Arita <i>et al.</i> [21]	80 (40 vs. 40)	Clamp-crush technique	733 ^a /0	80	0.89
		Radiofrequency dissecting sealer	665 ^a /2	79	0.99
Smyrniotis <i>et al.</i> [20]	82 (41 vs. 41)	Clamp-crush technique	460 ^a /15	211	NA
		Sharp transection	500 ^a /13	205	
Lupo <i>et al.</i> [23]	50 (26 vs. 24)	Clamp-crush technique	NA/8	292	NA
		Radiofrequency dissecting sealer	NA/13	278	

Only randomized trials are reported. NA = Not available in the study.

^a Blood loss is expressed in ml.

^b Value refers only to transection time.

^c Blood loss is expressed in ml/cm². The number of patients transfused is expressed as a mean only in the trial by Rau *et al.* [9].

^a Blood loss is expressed in ml.

^b Value refers only to transection time.

^c Blood loss is expressed in ml/cm². The number of patients transfused is expressed as a mean only in the trial Rau *et al.* [9].

Table 3. Only randomized trials are reported. NA= Not available in the study.

In January 2004, Sakamoto *et al.* retrospectively compared their experience with 16 liver resections in which SLC was used in combination with a bipolar vessel-sealing device and a matched set of 16 patients undergoing liver resections in which a crush-clamp technique was used.[134] They found that fewer patients in the SLC group required inflow occlusion and that blood loss was reduced. Differences in total operative time were not reported, but liver transection time was prolonged in the SLC group. Aldrighetti *et al.* [135] published a relatively larger series comparing clamp-crushing with ultrasonic plus harmonic scalpel dissection. The latter resulted in longer operative time, but with a reduced blood loss (and consequently a lower transfusion rate) and with a lower rate of biliary fistula. However, the retrospective method of the study, and the relatively long period of inclusion may have biased these results against the clamp-crush technique. Lesurtel and Tanai combined ultrasonic dissection with

bipolar coagulation [136-137]. They concluded that UD associated with efficient bipolar forceps cautery is probably one of the safest and the most efficient device for liver transection, even if its superiority over the clamp crushing technique has not been well established. In a recent paper Yokoo et coll [139] combined the use of ultrasonically activated scalpel with a saline linked radiofrequency dissecting sealer versus bipolar cautery with a saline-irrigation system and ultrasonically activated. Scalpel. The first technique resulted in shorter operative time and lower postoperative complication rate. Moreover Gruttaduria and coll developed a combination of ultrasonic surgical aspirator in association with a monopolar floating ball in elderly patients. This new technique reduced length of stay, procedure length, and use of perioperative blood in a cohort of patients [140]. Nagano and coll evaluated the efficacy of combination of CUSA plus argon beam coagulator in comparison with CUSA plus bipolar coagulation, and showed that the first approach allowed to a shorter transection time and lower blood loss [141]

Haemostasis techniques: Coagulation of vessels over 1 mm of diameter can be achieved positioning clips or sutures before division, or using devices like LigaSure, TMFB or HS for their target vessels or staplers for the largest veins. Clips and sutures are used especially during transection through traditional techniques.

During and after liver's transection haemostasis of the vascular structures under 1 mm of diameter is another important concern of the surgeon: first because the continuous bleeding from the little vessels in the parenchyma represents a considerable part of intra-operative blood loss, and second because it makes hard for the surgeon the visualization of the surgical field. The stop of tearing small vessels that causes oozing from the cut surface can be achieved with normal monopolar or bipolar electrocoagulator, better if equipped with saline irrigation that makes them less traumatic and avoids formation of sticky coagulum. An alternative is represented by employment of Argon Beam Coagulator or TMFB that probably is the best device for stopping tearing of small vessels on the cut surface of the liver.

After the resection other two precautions can be taken: application of mattress sutures for providing to a mechanical compression of the bare surface and application of biological glue for realizing complete haemostasis through a chemical/biological action.

Choice of surgical strategy: The choice of surgical strategy is based on the pre-operative evaluation and on the now indispensable Intra-Operative Ultrasonography (IOUS); in fact several studies have demonstrated that the IOUS is capable to change surgical strategy in over 40% of cases finding new lesions or diagnosing as inoperable lesions those were thought operable at the previous evaluation [101-104]. The kind of surgical strategy chosen for the intervention on the base of affects strongly influences the operative outcome and the amount of operative blood loss. The most considerable aspect is the amplitude of the resection: a large resection like a right hemi-hepatectomy (or another typical resection) involves a higher bleeding and risk of complications. From this point of view the choice of segmental or wedge limited resections, when they are possible in respect of radical oncology standards, has to be considered the best option [105,106]. Usual surgical margins for removal of liver tumours are 1 cm of healthy parenchyma surrounding the lesion. Kokudo et al. in 2002 demonstrated that for colorectal metastases the surgical margin can be, in particular situations, lowered to 2 mm

with increase of the pathology recurrence rate from 0% for 5 mm margin to 6% for 2 mm margin [107].

This finding, combined with a contrast-enhanced IOUS during the resection, could be a rationale incentive for practising limited resections [108-110], and the possibility of an accurate investigation of the remnant liver through the IOUS

Drug administration for reducing intra-operative blood loss: Liver resection may cause a variable degree of hyperfibrinolytic states; this phenomenon occurs in the days immediately after hepatectomy and is more pronounced in patients with a diseased liver or in patients who have undergone to a wider hepatectomy extent [111-116]. So some authors propose the utilization of drugs with antifibrinolytic effect like Aprotinin that is reported to be capable to reduce intra-operative blood loss (especially during liver resection time) and transfusions [117-119]. Other authors propose utilization of the cheaper Tranexamic acid reporting similar results [120]. Although a theoretical risk of thromboembolic complications is present, no adverse drug effects like deep venous thrombosis, pulmonary embolism or other circulatory disturbances were detected in both these studies.

3.5. Comparison of different liver transection techniques

The choice of transection techniques is currently a matter of preference of surgeons, as there are few data from prospective randomized trials that compared different techniques. It has been shown in small prospective randomized trials that clamp crushing or water jet may be preferable to CUSA in terms of quality of transection or speed of transection [1],[122]. Moreover Water-jet dissection.

Seems to be considerably faster than CUSA® or blunt dissection and Pringle-time and blood loss can be reduced by using this device [83]. However, the results of these trials remain to be validated by larger-scale trials. CUSA dissection is still a widely used technique worldwide.

Several studies have been addressed to clarify these critical points, underlining the advantages and the drawbacks of each device. One of the first randomized studies [52] comparing the ultrasonic dissector versus the clamp-crush technique showed that the ultrasonic dissector is more frequently associated with tumor exposure at the resection margin and with incomplete appearance of landmark hepatic veins on the cut surface. The authors did not find any difference in postoperative morbidity and blood loss, concluding that clamp-crushing technique resulted in a higher quality of hepatectomy, thus being the option of choice.

Aldrighetti et al. [135] published a relatively larger series comparing clamp-crushing with ultrasonic plus harmonic scalpel dissection. The latter resulted in longer operative time, but with a reduced blood loss (and consequently a lower transfusion rate) and with a lower rate of biliary fistula. However, the retrospective method of the study, and the relatively long period of inclusion may have biased these results against the clamp-crush technique. The study performed by Takayama and colleagues found no difference in transection speed between the crush/clamp technique and ultrasonic dissection. This same study also demonstrated that the crush/clamp technique resulted in increased precision and improved quality of hepatectomy according to a grading system considering such factors as positive surgical margins, appear-

ance of landmark hepatic veins on the cut hepatic surface, and postoperative morbidity. Koo and colleagues also demonstrated that no difference existed with blood loss, transfusion requirements, speed of resection, or total operative time between crush/clamp and the ultrasonic dissector

A randomized study [73] comparing LigaSure with the conventional method, demonstrated no statistical difference ($p = 0.185$) in blood loss and mortality rate between the two groups. But, LigaSure was slightly superior in terms of transection speed, number of ties per cm² and hemostasis time. The resulting total operating time decreased by 27 min, and hospital stay was shortened by 2 days in the LigaSure group. The authors performed also a cost analysis which found a highly cost-effective ratio in favor of LigaSure due to shorter operative time, hospital stay and low capital cost of the disposable device. They considered 3 mm as the range of maximal effectiveness in sealing portal triads (without increasing the rate of biliary fistula). A more recent randomized study [74] did not demonstrate this difference in blood loss, operating time and hospital stay, failing to find a superiority of one technique over the other. In this particular situation, the cost-effectiveness of LigaSure in the clamp-crush method was not confirmed, favoring once again the latter. Radiofrequency-assisted hepatic transection has also been studied in a randomized, controlled fashion. The results of this study indicated that postoperative morbidity, including abscesses and biliary complications, was significantly higher with the use of radiofrequency-assisted resection compared to crush/clamp.

As recently described in non-randomized settings [85]-[86], liver transection could be also performed with the stapling technique. As reported, the technique appears to be safe and quicker. Commonly, staplers are considered to be expensive tools, but they increase only the total material cost. However, owing to decreased blood loss, transfusion rate, shorter operative time and in-hospital stay, the global cost for a hepatectomy (especially for the major ones) has considerably decreased especially in high-volume centers. It should also be noticed that the stapling technique [142] can reduce the time of vascular control (i.e. Pringle). This fact turns out to be relevant when the resection is conducted in injured parenchyma due to prolonged chemotherapy (hepatic steatosis, sinusoidal obstruction syndrome, steatohepatitis, etc.). Cataldo et al [143] comparing stapler, crush/clamp and dissecting sealer demonstrate that liver transection with stapler was quicker, but mean blood loss and oncological margin were similar for the three techniques. A recent study of clearly demonstrate that there is no benefit of any alternative method that has so far been compared with the clamp-crushing technique within a RCT regarding morbidity, mortality, and transfusion rates. Moreover, available RCTs failed to show an advantage of these novel devices to reduce blood loss, parenchymal injury, operation time, and hospital stay. Recently, a randomized trial compared four methods of liver transection, namely clamp crushing, CUSA, Hydrojet, and dissecting sealer, with 25 patients in each group [121]. In that study, clamp crushing was associated with the fastest transection speed, lowest blood loss, and lowest blood transfusion requirement. Furthermore, clamp crushing was the most cost-effective technique. However, in that study, clamp crushing was performed with the Pringle maneuver, whereas the other techniques were performed without the Pringle maneuver. This might have resulted in bias in favor of clamp crushing. An other recent comparative study between clamp crushing technique (CRUSH), ultrasonic dissection

(CUSA) or bipolar device (LigaSure), failed to show any difference between the three techniques in terms of intraoperative blood loss, blood transfusion, postoperative complications and mortality [72]. Further prospective randomized studies are needed to determine which transection technique is the best. Moreover a recent review of the Cochrane conclude that Clamp-crush technique is advocated as the method of choice in liver parenchymal transection because it avoids special equipment, whereas the newer methods do not seem to offer any benefit in decreasing the morbidity or transfusion requirement. Otherwise in the comparison of different techniques, apart from the efficacy in transaction with low blood loss, the relative speed of transection and the potential complications are other parameters to be considered. [122] Furthermore, the use of special instruments for transection is costly, especially when two instruments are used in combination for transection and hemostasis. It is difficult to compare the relative cost of different transection instruments because some are reusable whereas others are designed for single use, and the cost of the same instrument varies substantially in different countries. The clamp-crush and sharp dissection techniques do not involve any additional instruments. A cost comparison between the clamp-crush technique and other techniques revealed that clamp-crush is two to six times cheaper than other methods, depending on the number of surgeries performed each year. Nonetheless, the cost of these various techniques should play a part in the surgeon's decision as to whether to use them or not.

Besides reduction of blood loss and perioperative complications, radical resection with tumor-free margins is a major goal in surgery for malignant hepatic lesions. Disease-positive resection margins are a strong prognostic factor for local tumor recurrence and overall survival. Unfortunately, pathohistological data on resection margins were only available for two trials. Takayama et al. demonstrated comparable resection margins in their comparison of the clamp-crushing to the ultrasonic dissector technique. [52] However, Smyrniotis et al. reported far greater length of the narrowest tumor-free margin in their sharp transection group. [144] The question of whether any alternative transection technique provides a benefit in longterm survival of cancer patients needs further evaluation within clinical trials.

4. The role of the anaesthesiologist

Patients those are subjected to liver surgery are usually pre and intra-operatorially treated with infusion of liquids, plasma expanders and blood products: normally hepatic resections are in fact conducted in condition of euvolaemia or hypervolaemia to protect patients from the risk of consistent haemorrhage and haemodynamic's instability.

Despite this idea several studies have demonstrated that a condition of Low Central Venous Pressure (LCVP) can reduce bleeding, recourse to vessel occlusion techniques and transfusions during resection [111,112,113]. It has been scientifically demonstrated that intra-operative blood loss is correlated with inferior retro-hepatic vena cava pressure [114].

Mendelez obtained very low blood loss results in major hepatic resections managed keeping the CVP under 5 mmHg: this is possible with abstention from practising any infusion but intra-operative liquid infusion at the low speed of 75 ml/h and without any drug administration but

employing hypotensive effects of normal anaesthetics (like Isoflurane, morphine and Fentanyl). It's obvious that LCVP technique needs a strict monitoring of several parameters: in particular systolic arterial pressure has constantly to be kept over 90 mmHg and diuresis over 25 ml/h. After the specimen is removed and after the realization of complete haemostasis starts the infusion of liquids, and if necessary of plasma expanders and blood products until euvolaemia is obtained and haemoglobin value is over 8-10 g/dl [115].

LCVP has to be abandoned in case of uncontrollable haemorrhage (over 25% of total blood volume) or application of total vascular exclusion technique. Mendelez using LCVP reports a 0,4% rate of gas embolism [116]. This illustrates the importance of collaboration between surgeons and anaesthetists for a successful hepatectomy.

5. Conclusions

Improvement in the techniques of liver transection is one of the most important factors for improved safety of hepatectomy in recent years. The use of intraoperative ultrasound aids delineation of the proper transection plane and allow to transect tumor close to main vessels without bleeding. Clamp crushing and ultrasonic dissection are currently the two most popular techniques of liver transection. The role of new instruments such as ultrasonic shear and RFA devices in liver transection remains unclear, with few data available in the literature.

The role of vascular exclusion including Pringle's manouever seems to be decreasing with improved transection technique. However, it remains a useful technique in reducing bleeding from inflow vessels, especially for surgeons with less experience in liver resection, and recent results show safety of this technique even for prolonged total time of ischemia. Maintenance of low central venous pressure remains an important adjunctive measure to reduce blood loss in liver transection.

As clear data for comparison of various liver transection techniques are lacking, currently the choice of technique is often based on the individual surgeon's preference. However, certain general recommendations can be made based on existing data and the author's experience. Clamp crushing is a lowcost technique but it requires substantial experience to be used effectively for liver transection, especially in the cirrhotic liver. CUSA can be used in both cirrhotic and non-cirrhotic liver, is associated with low blood loss and it has a well established safety record, with low risk of bile leak. It is particularly useful in major hepatic resections when dissection of the major branches of the hepatic veins is required, or in cases where the tumor is in close proximity to a major hepatic vein, as it allows clear dissection of the hepatic vein from the tumor. This could be the preferred

5.1. Technique in oncological resection

5.1.1. *The main disadvantage of the CUSA technique is slow transection*

Newer instruments such as the Harmonic Scalpel, Ligasure and TissueLink Dissector enhance the capability of hemostasis and allow faster transection. However, they lack the preciseness

of CUSA in dissection of major hepatic veins, and, HS more than others may be associated with increased risk of bile leak. Moreover they are particularly useful in laparoscopic liver resection. They can also be used in combination with CUSA for sealing of vessels, but this increases the cost substantially. RFA-assisted transection is probably the most speedy liver transaction technique. However, the risk of thermal injury to major bile duct is a serious concern and its use is probably restricted to minor resection. Gyrus and Aquamantis are relatively new instrument and literature do not allow to draw any conclusion about their efficacy and safety.

The experience of the surgeon in practising hepatic surgery, whatever is the method to perform it, is still a factor of primary importance. In spite of that, the advent of new diagnostic instruments, new devices for resection and coagulation, a better knowledge of the liver's anatomy and pathology and a closer collaboration with the anaesthetist make the hepatic surgery a kind of surgery more defined and rational. From this point of view new studies based on the use of different surgical strategies, association of different devices and employment of different diagnostic and anaesthetic techniques is desirable.

5.2. Summary of advantages and disadvantages of the parenchymal-division instruments (table 4)

Table 4 lists the primary advantages and disadvantages of five instruments used for parenchymal division during liver resection. The CUSA has the principal advantage of precise identification of both vascular and biliary vessels so that they may be controlled by ligature or other methods. In addition, the CUSA provides some haptic feedback to the surgeon so that dissection planes may remain clear. The principal disadvantages of the CUSA are threefold: (1) While the instrument permits removal of a large margin around tumors, the proof of adequate margins ends up in the suction container; (2) due to its mechanism of action, the CUSA is not very good for dissection through the fibrotic tissues found in cirrhotic livers; (3) without considerable education of the operating room personnel, the complexity of the mechanism may be cause for delays or malfunctions during procedures. The water jet affords many of the same advantages as the CUSA. Additionally, it produces minimal marginal necrosis, making it an ideal instrument in certain scenarios. The most important concern with this instrument, however, is the splash, for reasons described above. The harmonic scalpel's primary advantage is its ability to simultaneously cut and coagulate. The associated coagulum, however, may cause delayed complications. Originally devised for laparoscopic use, the harmonic scalpel's design is not particularly advantageous for open cases. Used as an adjunctive instrument, the stapler provides the possibility for speedier dissections. On the other hand, the stapler is a relatively imprecise instrument that also has the potential to malfunction during procedures. The floating ball is a surgeon-friendly instrument, particularly for the novice liver resectionist. Its mode of action may be particularly helpful in cirrhosis. The instrument acts by "controlled" burning and therefore is, by nature, an imprecise instrument; plus, there are concerns both for delayed complications related to the coagulum and for steam popping.

5.3. Ranking the clinical usefulness of the five instruments (table 5)

Table 2 subjectively ranks the five instruments according to perceived usefulness in various clinical scenarios. For resection of malignancies, we rank the CUSA number one because of its ability to stay within tissue planes during resections while preserving vessels for ligation. The water jet was second due to concerns about the splash. Third on the list is the floating ball because of its user friendliness. The harmonic scalpel lands fourth on our list because we expect laparoscopic liver resections to increase. We find the water jet to be the most useful instrument for living-donor resections because of the minimal necrotic margin. After the water jet, we advocate the more traditional, fine instrument (e.g., mosquito clamp) dissections. We rank the CUSA third because with experience, the surgeon may minimize the disadvantage of tissue removal.

Instrument	Advantages	Disadvantages
CUSA	permits identification of vessels; tactile feedback	pathologic confusion, use difficult in cirrhosis mechanically complicated do not coagulate, need a combined technique
Water Jet	selective dissection minimal marginal necrosis	splash; possible electrolyte imbalances
Harmonic scalpel	cut and coagulate simultaneously	coagulum precoagulation technique; blind dissection
Ligasure	cut and coagulate simultaneously	coagulum precoagulation technique; blind dissection
Gyrus	cut and coagulate simultaneously	coagulum precoagulation technique; blind dissection
TissueLink	friendliness to novices	imprecision, steam popping precoagulation technique
Aquamantys	Friendliness	precoagulation technique
Stapler	speed	imprecision, malfunction
Habib technique	coagulate large vessels	speed

Table 4. Advantages and disadvantages of most common devices

The harmonic scalpel tops the instruments for laparoscopic surgery, primarily because the scalpel is designed for laparoscopic surgery. Another reason the scalpel is particularly useful here is that the principal tumors being removed now via the laparoscope are small benign ones.

Therefore, the imprecision of this instrument is not so much of a disadvantage. The CUSA comes in second primarily because its suction competes with insufflation. Staplers are number three because of their ability to gain quick control over vessels during laparoscopic dissections. Finally, because laparoscopic hepatic surgery is rapidly evolving, we

believe there will soon be new uses for old instruments or development of new instruments that will be particularly useful for this approach. For cirrhotic livers, we rank the floating ball number one due to its effective burning of fibrotic tissue. The harmonic scalpel may also be effective. Because of their relative precision, we rank the water jet and CUSA lower than the other two. Staplers do also have a role here.

Scenario	Instrument ranking
resection of malignancies	Cusa
	Water Jet
	Habib
	Tissuelink
	HS and Ligasure
Living donor resections	Tissuelink and Aquamantis
	Water jet
	CUSA
	HS and Ligasure and Gyrus
	Habib
Laparoscopic procedures	HS and Ligasure
	CUSA
	Stapler
Cirrhosis	Tissuelink and Aquamantis
	Habib
	HS and Gyrus
	Water Jet
	CUSA

Table 5. Instrument ranking in various clinical scenarios based on perceived usefulness

Author details

Fabrizio Romano, Mattia Garancini, Fabio Uggeri, Luca Gianotti, Luca Nespoli, Angelo Nespoli and Franco Uggeri

Department of Surgery, University of Milan Bicocca, San Gerardo Hospital Monza, Milan, Italy

References

- [1] Poon RT, Fan ST, Lo CM, et al. Improving perioperative outcome expands the role of hepatectomy in management of benign and malignant hepatobiliary diseases: analysis of 1222 consecutive patients from a prospective database. *Ann Surg.* 2004;240:698–708

- [2] Rees M, Plant G, Wells J et al; One hundred and fifty hepatic resections: evolution of technique towards bloodless surgery. *British Journal of Surgery* 1996; 83:1526-1529
- [3] Doci R, Gennari L, Bignami P et al. Morbidity and Mortality after Hepatic Resection of Metastases from Colorectal Cancer. *Br L Surg* 1995;377-381
- [4] Belghiti J, Hiramatsu K, Benoist S, et al. Seven Hundreded Hepatectomies in tehe 1990s: an update to evaluate the actual risk of Liver Resection. *Journal of American Surgeon* 2000,19138-46
- [5] Gozzetti G, Mazziotti A, Grazi L et al: Liver Resection without Blood Transfusion. *Br J Surg* 1995;82:1105-1110
- [6] Cunningham JD, Fong Y, Shriver C et al: One Hundred consecutive Hepatic Resections: Blood Loss, Transfusion and Operative Technique. *Archives of Surgery* 1994;129:1050-1056
- [7] Descottes B, Lachachi F, Durand-Fontanier S et al: Right hepatectomies without vascular clamping: report of 87 cases. *Journal of Hepatobiliary Pancreatic Surgery* 2003; 10:90-94
- [8] Romano F, Franciosi C, Caprotti R, Uggeri F, Uggeri F. Hepatic surgery using the Ligasure Vessel System. *World Journal of Surgery* 2005; 29:110-112
- [9] Jamagin WR, Gonen M, Fong Y, et al: Improvement in Perioperative Outcome after Hepatic Resection: Analysis of 1803 consecutive cases over the past decade. *Annals of Surgery* 2002;236:397-406
- [10] Navarra G, Spalding D, Zacharoulis D, Nicholls JP, Kirby S, Costa 1, Habib NA. Bloodlcss Hcpatectomy Technique. *HPB Surg* 2002;4:95-97
- [11] Rosen CB, Nagomey DM, 1`aswell HF, I-Iegelson S, Ilstrup D, Van Heerden JA. Perioperative blood trasfusion and determinants of survival after liver resection for metastatic colorectal carcinama. *Annals of Surgery* 1992: 216:493-505
- [12] Stephenson KR, Steinberg SM, Hughes KS, Vetto JT, Sugarbaker PH, Chang AE. Perioperative blood trasfusions are associated with decreased time to recurrence and decreased survival after resection for colorectal liver metastases. *Annals of Surgery* 1988; 208: 679-687
- [13] Torzilli G, Makuuchi M, Midorikawa Y et al: Liver Resection Without Total Vascular Exclusion: Hazardous or Benfcuical? An analysis of our Experience. *Annals of Surgery* 2001; 233:167-175
- [14] Kooby DA, Stockman J, Ben-Porat L, Gonen M, Jamagin WR, Dematteo RP, Tuorto S, Wuest D, Blumgart LH, Fong Y. Influence fo Trasfusions on Perioperative and Long-Term Outcome in Patients Following Hepatic Resection for Colorectal Metastases. *Annals of Surgery* 2003; 237:860-870

- [15] Fujimoto J, Okamoto E, Yamanaka N et al: Adverse Effect of Perioperative Blood Transfusions on Survival after hepatic Resection for Hepatocellular Carcinoma. *Hepato- Gastroenterology* 1997; 44:1390-1396
- [16] Ohio M, Contini P, Mazzei C et al; Soluble HLA class I, HLA class II and FAS Ligand in Blood Components. A possible key to explain the Immunomodulatory Effects of Allogenic Blood Transfusions. *Blood* 1999; 93:1770-1777
- [17] Tait BD, d'Apice AJF, Morrow L, Kennedy L. Changes in suppressor cell activity in renal dialysis patients after blood transfusion. *Transplant Proc* 1984; 16:995-997
- [18] Kaplan J, Samaik S, Levy J. Transfusion-induced immunologic abnormalities not related to the AIDS virus. *N Engl J Med* 1985; 313:1227
- [19] Donnelly PK, Shenton BK, Alomran AM, Francis DM, Proud G, Taylor RM. A new mechanism of humoral immuno-depression in chronic renal failure and its importance to dialysis and transplantation. *Proceedings of the European Dialysis and transplant Association* 1983; 20:297-304
- [20] Lenliard V, Gemsa D, Opelz G. Transfusion-induced release of prostaglandin E2 and its role in the activation of T suppressor cells. *Transplant Proc* 1985; 17:2380-2382
- [21] Lawrence RJ, Cooper AJ, Lozidou M, Alexander P, Taylor I. Blood transfusion and recurrence of colorectal cancer: the role of platelet-derived growth factors. *British Journal of Surgery* 1990; 77:1106-1109
- [22] Torzilli G, Gambetti A, Del Fabbro D, Leoni P, Olivari N, Donadon M, Montorsi M, Makuuch M. _Techniques for Hepatectomies Without Blood Transfusion, Focusing on Interpretation of Postoperative Anemia. *Archives of Surgery* 2004; 139:1061-1065
- [23] Abdalla EK, Noun R, Belghiti J. Hepatic vascular occlusion: which technique? *Surg Clin North Am* 2004; 84; 563-85.
- [24] Smyrniotis V, Farantos C, Kostopanagiotou G, Arkadopoulos N. Vascular control during hepatectomy: Review of methods and results. *World J Surg* 2005; 29: 1384-96.
- [25] Kim YI. Ischemia-reperfusion injury of the human liver during hepatic resection. *J Hepatobiliary Pancreat Surg* 2003; 10: 195-9.
- [26] Smyrniotis VE, Kostopanagiotou GG, Contis JC, Farantos CI, Voros DC, Kannas DC, Koskinas JS. Selective hepatic vascular exclusion (SHVE) versus Pringle manoeuvre in major liver resections: A prospective study. *World J Surg* 2003; 27: 765-9.
- [27] torzilli
- [28] Belghiti J, Noun R, Malafosse R, Jagot P, Sauvanet A, Pierangeli F, et al. Continuous versus intermittent portal triad clamping for liver resection: a controlled study. *Ann Surg* 1999; 229: 369-75.

- [29] Capussotti L, Muratore A, Ferrero A, Massucco P, Ribero D, Polastri R. Randomized clinical trial of liver resection with and without hepatic pedicle clamping. *Br J Surg* 2006; 93:685-689
- [30] Clavien PA, Yadav S, Sindram D, Bentley RC. Protective effects of ischaemic preconditioning for liver resection performed under inflow occlusion in humans. *Ann Surg* 2000; 232: 155-62
- [31] Nuzzo G, Giuliante F, Vellone M, De Cosmo G, Ardito F, Murazio M, et al. Pedicle clamping with ischemic preconditioning in liver resection. *Liver transpl* 2004; 10: S53-S57.
- [32] Clavien PA, Selzner M, Rudiger HA, Graf R, Kadry Z, Rousson V, Jochum W. A prospective randomized study in 100 consecutive patients undergoing major liver resection with versus without ischemic preconditioning. *Ann Surg* 2003; 238: 843-52.
- [33] Makuuchi M, Mori T, Gunven P, Yamazaki S, Hasegawa H. Safety of hemihepatic vascular occlusion during resection of the liver. *Surg Gynecol Obstet* 1987; 164: 155-8.
- [34] Horgan PG, Leen E. A simple technique for vascular control during hepatectomy: The half-Pringle. *Am J Surg* 2001; 182: 265-7.
- [35] Castaing D, Garden OJ, Bismuth H. Segmental liver resection using ultrasound-guided selective portal venous occlusion. *Ann Surg* 1989; 210: 20-23.
- [36] Goseki N, Kato S, Takamatsu S, Dobashi Y, Hara Y, Teramoto K, et al. Hepatic resection under the intermittent selective portal branch occlusion by balloon catheter. *J Am Coll Surg* 1994; 179: 673-8.
- [37] Huguet C, Addario-Chieco P, Gavelli A, Arrigo E, Harb J, Clement RR. Technique of hepatic vascular exclusion for extensive liver resection. *Am J Surg* 1992; 163: 602-05.
- [38] Eyraud D, Richard O, Borie DC, Schaup B, Carayon A, Vezinet C, et al. Hemodynamic and hormonal responses to the sudden interruption of caval flow: Insights from a prospective study of hepatic vascular exclusion during major liver resections. *Anesth Analg* 2002; 95: 1173-8.
- [39] Torzilli G, Makuuchi M, Midorikawa Y, Sano K, Inoue K, Takayama T, Kubota K. Liver resection without total vascular exclusion: hazardous or beneficial? An analysis of our experience. *Ann Surg* 2001; 233: 161-75.
- [40] Elias D, Dube P, Bonvalot S, Debanne B, Plaud B, Lasser P. Intermittent complete vascular exclusion of the liver during hepatectomy: Technique and indications. *Hepatogastroenterology* 1998; 45: 389-95.
- [41] Couinaud C; *Le foie: etudes anatomique et chirurgicales*. Paris: Masson, 1957
- [42] Meyers WC, Shekherdimian S, Owen SM, Ringe BH, Brooks AD. Sorting through methods of dividing the liver. *European Surgery* 2004; 36:289-295

- [43] Schmidbauer S, Hallfeldt KK et al: Experience with Ultrasound Scissors and Blades (UltraCision) in open and laparoscopic liver resection. *Annals of Surgery* 2002; 235(1): 27-30
- [44] H Sugo, Y Mikami, F Matsumoto et al: Hepatic resection using Harmonic Scalpel. *Surgery Today* 2000; 30:959-962
- [45] Kim J, Ahamad SA, Lowy AM et al: Increased biliary fistulas after liver resection with the Harmonic Scalpel. *The American Surgeon* 2003; 69(9):815-819
- [46] Okamoto T, Nakasato Y, Yanagisawa S et al: Hepatectomy using the Coagulating Shears type of Ultrasonically Activated Scalpel. *Digestive Surgery* 2001; 18(6):427- 430
- [47] Fun ST, Lai ECS, Lo CM et al. Hepatectomy with an Ultrasonic Dissector for hepatocellular carcinoma. *British Journal of Surgery* 1996; 83:117-120
- [48] Nakayama H, Masuda H, Shibata M, Amano S, Fukuzawa M. Incidence of bile leakage after three types of hepatic parenchymal transection. *Hepatogastroenterology* 2003; 50:1517-1520
- [49] W. Schweiger, A. El-Shabrawi, G. Werkgartner, H. Bacher, H. Cerwenka, M. Thalhammer and H. J. Mischinger Impact of parenchymal transection by Ultracision® harmonic scalpel in elective liver surgery. *Eur Surg* 2004;36:285-288
- [50] Hodgson WJB, Aufses A Jr. Surgical ultrasonic dissection of liver. *Surgical Rounds* 1979; 2:68
- [51] Fusulo F, Giori A, Fissi S et al:-Cavitron Ultrasonic Surgical Aspirator'(CUSA) in liver resection. *International Surgery* 1992; 77:64-66
- [52] Takayama T, Makuuchi M, Kubota K, Harihara Y, Hui AM, Sano K, et al. Randomized comparison of ultrasonic vs clamp transection of the liver. *Arch Surg* 2001; 136: 922-8.
- [53] E Felekouras, E Prassas, M Kontos, I Papaconstantinou, E Pikoulis, A Giannopoulos, C Tsigris, M Tzivras, C Bakogiannis, M Safioleas, E Papalambros, E Bastounis. Liver Tissue Dissection: Ultrasonic or RFA Energy? *World J Surg* 2006;30:2210-2216
- [54] Fan ST, Lai EC, Lo CM, Chu KM, Liu CL, Wong J. Hepatectomy with an ultrasonic dissector for hepatocellular carcinoma *Br J Surg.* 1996:117-20.
- [55] Yamamoto Y, Ikai I, Kume M et al: New simple technique for hepatic parenchymal resection using a Cavitron Ultrasonic Surgical Aspirator and Bipolar Cautery Equipped with a Channel for Water Dripping. *World Journal of Surgery* 1999; 23:1032-1037
- [56] Rau HG, Wichmann MW, Schinkel S, Buttler E, Pickelmann S, Schauer R, et al. Surgical techniques in hepatic resections: Ultrasonic aspirator versus Jet-Cutter. A prospective randomized clinical trial. *Zentralbl Chir* 2001;/126:/586_90.
- [57] Wrightson WR, Edwards MJ, McMasters KM. The role of the ultrasonically activated shears and vascular cutting stapler in hepatic resection. *Am Surg* 2000;66:1037-1040.

- [58] Koo BN, Kil HC, Choi JS, Kim JY, Chun DH, Hong YW. Hepatic resection by the Cavitron Ultrasonic Surgical Aspirator increases the incidence and severity of venous air embolism. *Anesth Analg* 2005; 101:966-970
- [59] Topp SA, McClurken M, Lipson D, Upadhya GA, Ritter JH, Linehan D, Strasberg SM (2004) Saline-linked surface radiofrequency ablation: factors affecting steam popping and depth of injury in the pig liver. *Ann Surg* 239: 518–527
- [60] Sakamoto Y, Yamamoto J et al: Bloodless liver resection using the Monopolar Floating Ball plus Ligasure Diathermy: preliminary results of 16 liver resections. *World Journal of Surgery*
- [61] Di Carlo I, Barbagallo F, Toro A et al. Hepatic resection using a water-cooled, high-density, Monopolar Device: a new technology for safer surgery. *Journal of gastrointestinal surgery* 2004; 5 596-600
- [62] Aloia TA, Zorzi D, Abdalla EK, Vauthey JN. Two surgeon technique for hepatic parenchymal transection of the non-cirrhotic liver using a saline-linked cautery and ultrasonic dissection. *Ann Surg* 2005;242;172-177
- [63] Torzilli G, Donadon M, Marconi M, Procopio F, Palmisano A, Del Fabbro D, Botea F, Spinelli A, Montorsi M. Monopolar floating ball versus bipolar forceps for hepatic resection: a prospective trial. *J Gastrointest Surg.* 2008 Nov;12(11):1961-6
- [64] Arita J, Hasegawa K, Kokudo N. Randomized clinical trial of the effect of a saline-linked radiofrequency coagulator on blood loss during hepatic resection. *Br J Surg.* 2005;92:954–959.
- [65] Sandonato L, Soresi M, Cipolla C, Bartolotta TV, Giannitrapani L, Antonucci M, Galia M, Latteri MA. Minor hepatic resection for hepatocellular carcinoma in cirrhotic patients: kelly clamp crushing resection versus heat coagulative necrosis with bipolar radiofrequency devices *Am Surg.* 2011;1490-5
- [66] Geller DA, Tsung A, Maheshwari V, et al. Hepatic resection in 170 patients using saline-cooled radiofrequency coagulation. *HPB* 2005;7:208.
- [67] Horgan PG: A novel technique for parenchymal division during hepatectomy. *The American Journal of Surgery* 2001; 181: 236-237
- [68] Strasberg SM, Drebin JA, Linehan D. Use of Bipolar Vessel-Sealing Device for Parenchymal Transection During Liver Surgery. *Journal of Gastrointestinal Surgery* 2002;6:569-574
- [69] Nanashima A, Tobinaga S, Abo T, Nonaka T, Sawai T, Nagayasu T. Usefulness of the combination procedure of crash clumping and vessel sealing for hepatic resection. *J Surg Oncol.* 2010 Aug 1;102:179-83
- [70] Tepetes K, Christodoulidis G, Spyridakis EM. Tissue Preserving Hepatectomy by a Vessel Sealing Device *Journal of Surgical Oncology* 2008;97:165–168

- [71] Patrlj L, Tuorto S, Fong Y. Combined blunt-clump dissection and Ligasure ligation for hepatic parenchyma dissection: postcoagulation technique. *J Am Coll Surg*. 2010;210:39-44
- [72] Doklestić K, Karamarković A, Stefanović B, Stefanović B, Milić N, Gregorić P, Djukić V, Bajec D. The Efficacy of Three Transection Techniques of the Liver Resection: A Randomized Clinical Trial. *Hepatogastroenterology*. 2011 ;59:117-121.
- [73] Saiura A, Yamamoto J, Koga R, Sakamoto Y, Kokudo N, Seki M, et al. Usefulness of LigaSure for liver resection: analysis by randomized clinical trial. *Am J Surg* 2006;192:/41-45.
- [74] M Ikeda, K Hasegawa, K Sano, H Imamura, Y Beck, Y Sugawara,, N Kokudo, M Makuuchi. The Vessel Sealing System (LigaSure) in Hepatic Resection. A Randomized Controlled Trial *Ann Surg* 2009;250:199-203
- [75] Slakey DP. Laparoscopic liver resection using a bipolar sealing device: Ligasure. *HPB* 2008;10:253-5.
- [76] S Evrard, Y Bécouarn, R Brunet, M Fonck, C Larrue, S Mathoulin-Pélissier. Could bipolar vessel sealers prevent bile leaks after hepatectomy? *Langenbecks Arch Surg*; 392: 41–44
- [77] Andoh H, Sato Y, Yasui O et al: Laparoscopic right hemihepatectomy for a case of polycystic disease with right predominance. *Journal of Hepatobiliary Pancreatic Surgery* 2004; 11:116-118
- [78] Garancini M, Gianotti L, Mattavelli I, Romano F, Degrate L, Caprotti R, Nespoli A, Uggeri F. Bipolar vessel sealing system vs. clamp crushing technique for liver parenchyma transection. *Hepatogastroenterology*. 2011 Jan-Feb;58:127-32
- [79] Papachristou DN, Barters R: Resection of the liver with a waterjet. *British journal of Surgery* 1982; 69:93-94
- [80] Une Y, Uchino J, Shimamura T et al: Water Jet Scalpel for liver resection in Hepatocellular Carcinoma with or without Cirrhosis. *International Surgery* 1996; 81:45-48
- [81] Izumi R, Yabushita K, Yagi M et al: Hepatic resection using a water jet dissector. *Surgery today* 1993; 23:31-35
- [82] Rau HG, Wichmann MW, Schinkel S, Buttler E, Pickelmann S, Schauer R, Schildberg FW. Surgical techniques in hepatic resections: Ultrasonic aspirator versus Jet-Cutter. A prospective randomized clinical trial]. *Zentralbl Chir*. 2001 Aug;126:586-90..
- [83] Rau HG, Duessel AP, Wurzbacher S. The use of water-jet dissection in open and laparoscopic liver resection. *HPB* 2008;10:275-80
- [84] Fong Y, Blumgart LH. Useful stapling techniques in liver surgery. *J Am Coll Surg* 1997;/185:/93 -100.

- [85] Kaneko H, Otsuka Y, Takagi S, Tsuchiya M, Tamura A, Shiba T. Hepatic resection using stapling devices. *Am J Surg* 2004;/ 187:/280 4.
- [86] P Schemmer, H Friess, U Hinz, A Mehrabi, T W. Kraus, K Z'graggen, J Schmidt, W Uhl, MW. Buchler. Stapler hepatectomy is a safe dissection technique. Analysis of 300 patients. *World J Surg* 2006;30;419-430
- [87] Wang WX, Fan ST. Use of the Endo-GIA vascular stapler for hepatic resection. *Asian J Surg* 2003;/26:/193 6.
- [88] Weber JC, Navarra G, Jiao NR, Nicholls JP, Jensen SL, Habib NA. New technique for liver resection using heat coagulative necrosis. *Annals of Surgery* 2002,236: 1-4
- [89] Stella M, Percivale A et al: Radiofrequency-assisted liver resection. *Journal of Gastrointestinal Surgery* 2003; 7:797-801
- [90] Haghghi KS, Wang F, King J, Daniel S, Morris DL. In-line radiofrequency ablation to minimize blood loss in hepatic parenchymal transection. *Am J Surg* 2005;/190:/43 7.
- [91] Pai M, Frampton AE, Mikhail S, Resende V, Kornasiewicz O, Spalding DR, Jiao LR, Habib NA. Radiofrequency assisted liver resection: analysis of 604 consecutive cases.. *Eur J Surg Oncol.* 2012;38:274-80
- [92] Pai M, Jiao LR, Khorsandi S, et al. Liver resection with bipolar radiofrequency device: Habibtrade mark 4X. *HPB* 2008;10: 256–60.
- [93] A Ayav, L Jiao, R Dickinson, J Nicholls, M Milicevic, R Pellicci, P Bachellier, N Habib. Liver Resection With a New Multiprobe Bipolar Radiofrequency Device. *Arch Surg* 2008;143:396-401
- [94] Ayav A, Bachellier P, Habib NA, et al. Impact of radiofrequency assisted hepatectomy for reduction of transfusion requirements. *Am J Surg.* 2007;193:143-148.
- [95] Chang YC, Nagasue N, Lin XZ et al: Easier hepatic resection with a straight needle. *American Journal of Surgery* 2001; 182:260-264
- [96] Chang YC, Nagasue N, Chen CS, Lin XZ. Simplified hepatic resection with the use on Chang's Needle. *Annals of Surgery* 2006; 243:169-172
- [97] Y. C. Chang, N. Nagasue. Blocking intrahepatic inflow and backflow using Chang's needle during hepatic resection: Chang's maneuver. *HPB* 2008;10:244-248
- [98] CU Corvera, SA Dada, JG Kirkland, BS Ryan, D Garrett, BA Lawrence, W Way, L Stewart. Bipolar Pulse Coagulation for Resection of the Cirrhotic Liver. *Journal of Surgical Research* 2006;136, 182-186
- [99] MR Porembka, MB Majella Doyle, NA Hamilton, PO Simon, SM Strasberg, DC Linehan, WG Hawkins. Utility of the Gyrus open forceps in hepatic parenchymal transection. *Hpb* 2009;11:258-263
- [100] J Tan, A Hunt, R Wijesuriya, L Delriviere, A Mitchell. Gyrus PlasmaKinetic bipolar coagulation device for liver resection *ANZ J Surg* 2010;80:182-185

- [101] Shukla PJ, Pandey D, Rao PP, Shrinkhande SV, Thakur MH, Arya S, Ramani S, Mehta S, Mohandas KM. Impact of intra-operative ultrasonography in liver surgery. *Indian Journal of Gastroenterology* 2005; 24(2):62-65
- [102] Bismuth H, Castaing D, Garden OJ. The use of operative ultrasound in surgery of primary liver tumors. *World Journal of Surgery* 1987;11:610-614
- [103] Staren ED, Gambla M, Deziel DJ et al: Intraoperative ultrasound in the management of liver neoplasm. *American Surgeon* 1997;63:591-596
- [104] Parker GA, Lawrence W Jr, Florsley JS et al. Intraoperative ultrasound of the liver affects operative decision making. *Annals of Surgery* 1989;209:569-577
- [105] DeMatteo RP. Anatomic segmental hepatic resection is superior to wedge resection as an oncologic operation for colorectal liver metastases. *Journal of Gastrointestinal Surgery* 2000; 4:178-184
- [106] Kokudo N. Anatomical Major resection versus nonanatomical limited resection for liver metastases from colorectal carcinoma. *American Journal of Surgery*; 181:153-159
- [107] Kokudo N, Miki Y, Sugai S, Yanagisawa A, Kato Y, Sakamoto Y, Yamamoto J, Yamaguchi T, Muto T, Makuuchi M. Genetic and histological assessment of surgical margins in resected liver metastases from colorectal carcinoma: minimum surgical margins for successful resection. *Archives of Surgery* 2002; 137:833-840
- [108] Torzilli G, Del Fabbro D, Olivari N, Calliada F, Montorsi M, Makuuchi M. Contrast-enhanced ultrasonography during liver surgery. *British Journal of Surgery* 2004; 91:1165-1167
- [109] Torzilli G, Olivari N, Del Fabbro D, Gambetti A, Leoni P, Montorsi M, Makuuchi M. Contrast-enhanced intraoperative ultrasonography in surgery for hepatocellular carcinoma in cirrhosis, *Liver Transplantation* 2004; 10:534-38
- [110] Torzilli G, Del Fabbro D, Palmisano A, Donadon M, Bianchi P, Roncalli M, Balzarini L, Montorsi M. Contrast-enhanced intraoperative ultrasonography during hepatectomies for colorectal cancer liver metastases. *Journal of Gastrointestinal Surgery* 2005; 9:1148-1153
- [111] Melendez JA, Arslan V, Fischer ME, Wuest D, Jarnagin WR, Fong Y, Blumgart LH. Perioperative Outcomes of Major Hepatic Resection under Low Central Venous Pressure Anesthesia: Blood Loss, Blood Trasfusion, and the Risk of Postoperative Renal Dysfunction. *Journal of American College of Surgeons* 1998; 187:620-625
- [112] Terai C, Anada H, Matsushima S et al: Effect of mild Trendelenberg on Central Hemodynamics and Intenal Jugular velocity, cross sectional area, and Flow. *American Journal of Emergency Medicine* 1995; 13:255-258
- [113] Hughson RL, Maillet A, Gauquelin G, et al: Investigation of hormonal effects during 10-h head-down tilt on heart rate and blood pressure variability. *Journal of Applied Physiology* 1995; 78:583-596

- [114] Smymiotis V, Kostopanagiotou G, Theodoraki K, Tsantoulas D, Contis JC. The role of central venous pressure and type of vascular control in blood loss during major liver resections. *American Journal of Surgery* 2004; 187:398-402
- [115] Chen H, Merchant NB, Didolkar MS. Hepatic resection using intermittent vascular inflow occlusion and low central venous pressure anesthesia improves morbidity and mortality. *Journal of Gastrointestinal Surgery* 2000; 4:162-167
- [116] Johnson M, Mannar R, Wu AVO. Correlation between Blood Loss and Inferior Vena Cava Pressure during Liver Resection. *British Journal of Surgery* 1998; 85:188-190
- [117] Paputheodoridis GV, Burroughs AK. Hemostasis in hepatic and biliary disorders. In: Blumgart LH, Fong Y, eds. *Surgery of the liver and biliary tract*, 3rd ed. London: Saunders, 2000:199-213
- [118] Oguro A, Taniguchi H, Daidoh T et al. Factors relating to coagulation, fibrinolysis and hepatic damage after liver resection. *Hepatobiliary Pancreatic Surgery* 1993; 7:43-49
- [119] Lentschener C, Benhamou D, Mercier FJ, Boyer-Neumann C, Naveau S, Smadja C, Wolf M, Franco D. Aprotinin reduces blood loss in patients undergoing elective liver resection. *Anesth Analg* 1997; 84:875-881
- [120] Wu CC, Ho WM, Cheng SB, Yeh DC, Wen MC, Liu TJ, P'eng FK. Perioperative parenteral Tranexamic Acid in liver tumour resection: a prospective randomized trial toward a "blood transfusion"-free hepatectomy. *Annals of Surgery* 2006; 243:173- 180
- [121] Lersutel M, Selzner M, Petrowsky S, McCormack L, Clavien PA. How should transection of the liver be performed?: a prospective randomized study in 100 consecutive patients: comparing four different transection strategies. *Ann Surg* 2005; 242:814-22.
- [122] KS Gurusamy, V Pamecha, D Sharma, BR Davidson. *Techniques for liver parenchymal transection in liver resection*. Cochrane Library Copyright © 2009 The Cochrane Collaboration. Published by JohnWiley & Sons, Ltd.
- [123] Torzilli G, Procopio F, Donadon M, Del Fabbro D, Cimino M, Montorsi M. Safety of intermittent Pringle maneuver cumulative time exceeding 120 minutes in liver resection: a further step in favor of the "radical but conservative" policy. *Ann Surg*. 2012 Feb; 255:270-80
- [124] Rahbari NN, Koch M, Schmidt T, Motschall E, Bruckner T, Weidmann K, Mehrabi A, Büchler MW, Weitz J. Meta-analysis of the clamp-crushing technique for transection of the parenchyma in elective hepatic resection: back to where we started? *Ann Surg Oncol* 2009; 16:630-639
- [125] Jagannath P, Chhabra DG, Sutariya KR et al. (2010) Fusion technique for liver transection with Kelly-clysis and harmonic technology. *World J Surg* 34:101–105.
- [126] N Gotohda, M Konishi, S Takahashi, T Kinoshita, Y Kato, T Kinoshita. Surgical Outcome of Liver Transection by the Crush-Clamping Technique Combined with Harmonic FOCUS. *World J Surg* (2012) 36:2156–2160

- [127] Romano F, Garancini M, Caprotti R, Bovo G, Conti M, Perego E, Uggeri F. Hepatic resection using a bipolar vessel sealing device: technical and histological analysis. *HPB* 2007;9:339-44
- [128] Romano F, Franciosi C, Caprotti R, Uggeri F, Uggeri F. Hepatic surgery using the Ligasure vessel sealing system. *World J Surg.* 2005 Jan;29:110-2
- [129] Pai M, Jiao LR, Khorsandi S, et al. Liver resection with bipolar radiofrequency device: Habibtrade mark 4X. *HPB* 2008;10: 256–60.
- [130] A Nanashima, S Tobinaga, T Abo, T Nonaka, T Sawai, T Nagayasu. Usefulness of the Combination Procedure of Crash Clamping and Vessel Sealing for Hepatic Resection. *Journal of Surgical Oncology* 2010;102:179–183
- [131] Smith DL, Arens JF, Barnett CC, et al. A prospective evaluation of ultrasound directed transparenchymal vascular control with linear cutting staplers in major hepatic resections. *Am J Surg* 2005;190:23–29.
- [132] MÁ Martínez-Serrano, L Grande, F Burdío, E Berjano, I Poves, R Quesada. Sutureless hepatic transection using a new radiofrequency assisted device. Theoretical model, experimental study and clinic trial. *CIR ESP.* 2011;89:145–151
- [133] Aloia TA, Zorzi D, Abdalla EK, Vauthey JN. Two-surgeon technique for hepatic transection of the noncirrhotic liver using salinelinked cautery and ultrasonic dissection. *Ann Surg* 2005; 242: 172–177.
- [134] Sakamoto Y, Yamamoto J, Kokudo N, et al. Bloodless liver resection using the monopolar floating ball plus ligasure diathermy: preliminary results of 16 liver resections. *World J Surg.* 2004;28:166–172.
- [135] Aldrighetti L, Pulitano C, Arru M, Catena M, Finazzi R, Ferla G. “Technological” approach versus clamp crushing technique for hepatic parenchymal transection: a comparative study. *J Gastrointest Surg.* 2006;10:974–9.
- [136] Lesurtel M, Belghiti J. Open hepatic parenchymal transection using ultrasonic dissection and bipolar coagulation. *HPB*, 2008; 10: 265- 270
- [137] Taniai N, Onda M, Tajiri T, Akimaru K, Yoshida H, Mamada Y. Hepatic parenchymal resection using an ultrasonic surgical aspirator with electrosurgical coagulation. *Hepatogastroenterology* 2002;49:1649 -1651
- [138] Patrlj L, Tuorto S, Fong Y. Combined blunt clamp dissection and ligasure ligation for hepatic parenchyma dissection: postcoagulation technique. *J Am Coll Surg* 2010;210:39-44
- [139] Yokoo H, Kamiyama T, Nakanishi K, Tahara M, Fukumori D, Kamachi H, Matsushita M, Todo S. Effectiveness of using ultrasonically activated scalpel in combination with radiofrequency dissecting sealer or irrigation bipolar for hepatic resection. *Hepatogastroenterology.* 2012 ;59:831-5

- [140] Gruttadauria S, Doria C, Vitale CH, Cintorino D, Foglieni CS, Fung JJ, Marino IR. Preliminary report on surgical technique in hepatic parenchymal transection for liver tumors in the elderly: a lesson learned from living-related liver transplantation. *J Surg Oncol.* 2004 Dec 15;88:229-33
- [141] Nagano Y, Matsuo K, Kunisaki C, Ike H, Imada T, Tanaka K, Togo S, Shimada H. Practical usefulness of ultrasonic surgical aspirator with argon beam coagulation for hepatic parenchymal transection. *World J Surg.* 2005 Jul;29:899-902
- [142] Schemmer P, Bruns H, Weitz J, Schmidt J, Büchler MW. Liver transection using vascular stapler: a review. *HPB (Oxford)* 2008; 10:249-252
- [143] Cataldo ET, Earl TM, Chari RS, Gorden DL, Merchant NB, Wright JK, Feurer ID, Wright Pinson C. A clinica comparative analisys of crush/clamp, stapler and dissections sealer hepatic transection method. *HPB* 2008;10:321-326
- [144] Smyrniotis V, Arkadopoulos N, Kostopanagiotou G, Farantos C, Vassiliou J, Contis J, et al. Sharp liver transection versus clamp rushing technique in liver resections: a prospective study. *Surgery.* 2005;137:306–11

