

Expression of Protein Tyrosine Kinases in Head and Neck Squamous Cell Carcinomas

Weg M. Ongkeko, MD, PhD,^{1*} Xabier Altuna, MD,^{2*} Robert A. Weisman, MD,¹ and Jessica Wang-Rodriguez, MD³

Key Words: Head and neck squamous cell carcinoma; Tyrosine kinase; Signal transduction; Immunohistochemistry

DOI: 10.1309/BTLN5WTMJ3PCNRRC

Abstract

Protein tyrosine kinases (TKs) are overexpressed in many carcinomas and sarcomas. We studied the expression of the following TKs in head and neck squamous cell carcinoma (HNSCC): platelet-derived growth factor receptor (PDGFR), c-kit, epidermal growth factor receptor (EGFR), and a serine-threonine kinase, Akt. Formalin-fixed, paraffin-embedded tumor blocks from 44 consecutive patients with primary HNSCC and 5 specimens of benign pharyngeal and laryngeal mucosa were retrieved for immunohistochemical analysis. Of the specimens, 38 had enough material to stain for all 4 antibodies. The study included 21 pharyngeal (base of tongue, 14; tonsil, 6; soft palate, 1), 16 laryngeal, and 1 floor of the mouth carcinoma. All 4 kinases in the tumor samples were expressed highly (PDGFR, 95%-100%; EGFR, 38%-43%; c-kit, 50%-86%; p-Akt, 57%-81%), with EGFR, c-kit, and p-Akt significantly higher than in benign samples. None of the kinase expressions correlated with disease-free survival. The expression of the kinases raises the possibility of treatment of HNSCC by tyrosine and serine-threonine kinase inhibitors.

Head and neck squamous cell carcinoma (HNSCC) is the sixth most common solid cancer in the world and the most common malignant neoplasm of the upper aerodigestive tract. Despite new treatment strategies, the survival for this type of cancer has not improved significantly in the past 25 years.^{1,2} In the past years, many biologic markers have been described in HNSCC. More recently, studies have suggested potential independent prognostic values for *p53* mutations³ and overexpression of the epidermal growth factor receptor (EGFR),⁴ cyclin D1,⁵ and transforming growth factor α .⁴

An important role in the development and progression of lung, ovarian, gastric, and breast cancer has been suggested for other biologic markers such as platelet-derived growth factor receptor (PDGFR), protein kinase B, also called Akt (with homology to the viral oncogene, *v-akt*, of the acutely transforming retrovirus, AKT8, in a rodent T-cell lymphoma), and c-kit, but they have not been studied widely in head and neck cancers. PDGFR, EGFR, and c-kit are tyrosine kinases (TKs). They are transmembrane TK receptors that transduce signals from outside and inside the cell and function as relay points for signaling pathways inside the cell. They have a key role in numerous processes that affect tumor development, growth, progression, metastasis, differentiation, and modulation of apoptosis.⁶ Akt is a serine-threonine kinase that is involved in cell proliferation, has a role in inhibiting apoptosis, and has been implicated in tumor invasion.

The presence of these TKs in cancers is important because they can be targets for chemical agents or drugs that inhibit their activity. Examples of clinically targeted kinase receptors include EGFR, PDGFR, c-kit and Akt.⁶⁻⁹ One such drug (imatinib mesylate [Gleevec]) is a TK inhibitor that has been used successfully to treat chronic myelogenous leukemia

(CML) and gastrointestinal stromal tumors (GISTs). In the present study, we aimed to examine the differential expression profiles in HNSCC of the following kinases: PDGFR, EGFR, c-kit, and Akt. Although EGFR has been studied extensively, to our knowledge, this is the first study of the expression of all 4 kinases in HNSCC tissue samples.

Materials and Methods

Study Material

Formalin-fixed, paraffin-embedded pathology specimen blocks from 44 consecutive patients treated surgically for HNSCC between June 1998 and July 2003 were retrieved from the Department of Pathology and Laboratory Services, Veterans Affairs (VA) San Diego Healthcare System, San Diego, CA. All specimens were processed in the Department of Pathology and Laboratory Services, VA San Diego Healthcare System. The original H&E-stained sections from the paraffin-embedded sections were reviewed by one of us (J.W.-R.), and, subsequently, 6 tissue macroarray blocks were made from the original blocks to facilitate the efficiency and throughput of the immunostains (Figure 1). Normal histologic control specimens were derived from 5 samples each of normal tonsils, uvula, and laryngeal mucosa.

Clinical data were derived from retrospective chart reviews. Patient age, sex, primary tumor site, TNM stage, tumor grade, postsurgical adjuvant treatment, and disease-free and overall survival were recorded. Because medical records

and tissue blocks contained patient identification numbers, approval of the VA San Diego Healthcare System and University of California, San Diego institutional review boards for use of human records and tissue was obtained (approval number, 021076X).

Antibodies

Immunohistochemical studies were performed using rabbit polyclonal IgG antibodies against EGFR, β -PDGFR, and c-kit (Santa Cruz Biotechnology, Santa Cruz, CA) and mouse monoclonal antibody against p-Akt (phosphorylated Akt, Ser473; Cell Signaling Technology, Beverly, MA). All antibodies were diluted 1:100 in phosphate-buffered saline. Positive control slides for p-Akt, c-kit, PDGFR, and EGFR were from known positive cases and blocks of human colon carcinomas, GISTs, prostate carcinomas, and breast carcinomas, respectively. Negative control slides were from a different section of the same tissue and were processed with the same immunostaining as the test slides but without the addition of the primary antibodies.

Immunohistochemical Staining

The tissue samples were fixed in 10% buffered formalin and embedded in paraffin, cut in 5- μ m sections, and placed on 3-aminopropyltriethoxysilane-coated slides. They were incubated for 1 hour at 60°C, deparaffinized in xylene, and rehydrated in graduated concentrations of ethanol. Antigen retrieval was performed by steam heating with DAKO Target Retrieval solution (DAKO, Carpinteria, CA). The endogenous peroxidase was quenched by 3% hydrogen peroxide. Nonspecific binding of biotin and avidin was blocked by blocking solution (Protein Block Serum-Free, DAKO). The background staining was reduced with incubation of goat serum (dilution 1:20) for 60 minutes. Primary antibodies were placed on slides and incubated for 1 hour at room temperature for PDGFR, EGFR, and c-kit and overnight at 4°C in a humidified chamber for p-Akt. Secondary antibodies conjugated with streptavidin-horseradish peroxidase (LSAB2, DAKO) were used. The slides were washed, and the antibody complex was visualized by using 3,3'-diaminobenzidine (DAB, DAKO). The nuclei were counterstained with Gill II hematoxylin.

Evaluation of Staining

Specimens were considered positive if the tumor cells had at least moderate staining and if more than 10% of the tumor cells stained more than the negative background cells and negative control samples. All positive cases demonstrated cytoplasmic staining, and there was membranous accentuation in the majority of the intensely staining cases. Every case was reviewed and scored as positive or negative by 3 of us (W.M.O., X.A., and J.W.-R.). A negative stain was equivalent to that seen in the negative control sample.

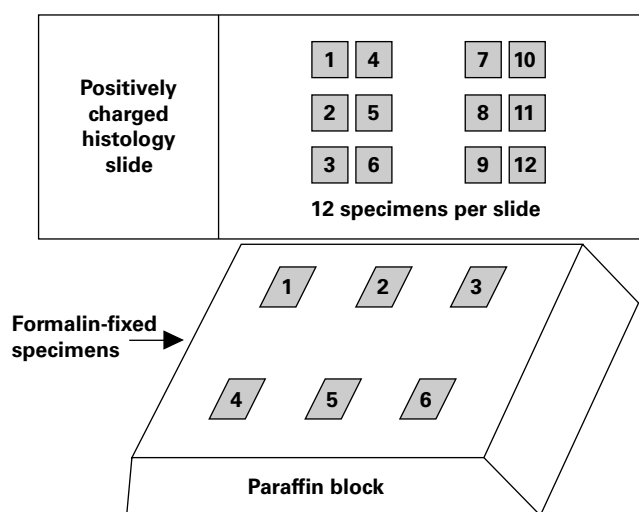


Figure 1 Schematic of tissue macroarray blocks to include 6 tissue samples per block and 12 specimens per slide. Slides with multiple specimens were prepared using custom-made paraffin blocks with 6 different tissue fragments.

Statistical Analysis

All statistical analyses used StatView, version 5.0.1 (SAS Institute, Cary, NC). Comparison of categorical data was done with χ^2 or the Fisher exact test, depending on sample size. Comparison of numeric data was done with the Student *t* test. Survival analysis was performed with Kaplan-Meier curves and significance determined by using the log-rank test for different groups of patients. The parameters significant in the log-rank univariate test were tested in stepwise regression procedures. Multivariate analysis was performed by using the Cox proportional hazards model.

Results

Table 1 is a summary of the tumor characteristics. All patients were men, reflecting the predominantly male population of the VA San Diego Healthcare System. There were 22 pharyngeal carcinomas, 18 laryngeal carcinomas, and 2 tumors from the floor of the mouth. Carcinomas of pharynx included base of the tongue (14), tonsils (7), and soft palate

Table 1
Characteristics of 44 Tumors*

	No. (%)
Location	
Pharynx	22 (50)
Larynx	18 (41)
No known primary site	2 (5)
Floor of mouth	2 (4)
Stage	
In situ	1 (2)
I	5 (11)
II	3 (7)
III	14 (32)
IV	21 (48)
Grade	
1	14 (32)
2	17 (39)
3	13 (30)

* There is a higher distribution in patients with head and neck squamous cell carcinoma in later stages (III and IV). The tumor grades seem to be distributed equally.

Table 2
Cases Stained by PDGFR, EGFR, c-kit, and p-Akt Antibodies*

Antibody	Pharyngeal (n = 21)	Laryngeal (n = 16)	Floor of the Mouth (n = 1)	P [†]	Control Samples (n = 5)	P [‡]
PDGFR	20 (95)	16 (100)	1 (100)	NS	5/5 (100)	NS
EGFR	9 (43)	6/16 (38)	1 (100)	NS	0/5 (0)	.10
c-kit	18 (86)	8 (50)	1 (100)	.04	0/5 (0)	.04
p-Akt	12 (57)	13 (81)	1 (100)	NS	0/5 (0)	.02

EGFR, epidermal growth factor receptor; NS, not significant; p-Akt, phosphorylated Akt, a serine-threonine kinase (Ser473), called protein kinase B; PDGFR, platelet-derived growth factor receptor.

* Data are given as number (percentage). There was significantly higher positive staining of EGFR, c-kit, and p-Akt in pharyngeal and laryngeal carcinomas compared with normal squamous mucosa of the oral pharynx and larynx. One case of floor of the mouth carcinoma demonstrated positive stains in all 4 proteins; there was insufficient statistical power to perform analysis for this tumor.

[†] Laryngeal vs pharyngeal carcinomas.

[‡] Both tumor types vs control samples.

(1). The mean age of the patients was 64.6 years (range, 64-85 years). There were no differences in age distribution compared with the location of the primary tumor. The mean follow-up was 18 months (range, 1-72 months). This cohort had more patients with higher stage tumors (stages III and IV) than lower stage tumors (stages I and II; *P* = .05). However, the tumor grades from well-differentiated (grade 1) to poorly differentiated (grade 3) were distributed evenly. No patients received radiotherapy before surgery, but more than 80% received radiotherapy after surgical resection.

Depending on specimen adequacy and fixation integrity, 38 of 44 cases were stained for all 4 antibodies. One case of pharyngeal (tonsil) carcinoma, 2 laryngeal carcinomas, and 1 carcinoma of the floor of the mouth were excluded owing to inadequate samples or lack of good fixation. Two cases of metastatic carcinomas involving cervical lymph nodes also were excluded owing to lack of a known primary site.

Table 2 summarizes the cases positive for each protein. PDGFR was by far the most prevalent protein, present in pharyngeal and laryngeal squamous cell carcinomas and also in all normal tissue samples. EGFR, c-kit, and p-Akt were expressed at high percentages in the tumors. However, c-kit was expressed preferentially at a higher percentage in pharyngeal tumors than in laryngeal tumors (*P* = .04). Owing to a lack of sufficient numbers in tumors of the floor of the mouth, statistical analysis was not performed. The 1 case studied was positive for all 4 antibodies. All 9 cases of c-kit-negative tumors also were EGFR-negative (*P* = .0046) **Table 3**. **Image 1** demonstrates representative positive staining characteristics of PDGFR, EGFR, c-kit, and p-Akt. Despite the various levels of kinase expression in tumor samples, the control cases were uniformly negative for EGFR, c-kit, and p-Akt.

Expression of the protein kinases studied herein did not correlate with disease-free survival. Owing to limited follow-up information, only disease-free survival was recorded. Of 22 patients with pharyngeal carcinoma, 10 died of disease (45%); of 18 with laryngeal carcinoma, 6 (33%) died of disease (*P* = .5). The mean survival periods for patients with pharyngeal and laryngeal cancer were 15.4 and 16.2 months, respectively (*P* =

not significant). Of the 4 protein kinases tested, only c-kit expression correlated with later stage ($P = .0085$), but it did not correlate with survival. In our cohort, tumor grade and stage did not correlate with disease-free survival ($P =$ not significant).

Table 3
Comparison of 37 Tumors Expressing c-kit vs EGFR

c-kit	EGFR	
	Positive	Negative
Positive	16	12
Negative	0	9*
Total	16	21

EGFR, epidermal growth factor receptor.
* $P = .0046$; Fisher exact test; all 9 c-kit-negative cases also were EGFR-negative.

Discussion

Receptor and nonreceptor TKs recently have generated intense interest as potentially clinically useful targets for new anti-cancer drugs. Of note are bcr-abl and c-kit in CML and GISTs, respectively, that are inhibited by imatinib mesylate. EGFR also is the prime target of new drugs such as gefitinib (Iressa), a small-molecule TK inhibitor, and trastuzumab (Herceptin), a chimeric antibody directed toward EGFR, erb-b2 (HER2/neu), that has been approved by the Food and Drug Administration for treatment of breast (trastuzumab) and colon cancer (gefitinib). Cetuximab (Erbix), a genetically engineered monoclonal antibody targeting EGFR, also has received Food and Drug Administration approval to treat chemotherapy-resistant or metastatic colorectal carcinomas and has been shown to reduce the tumor size significantly.

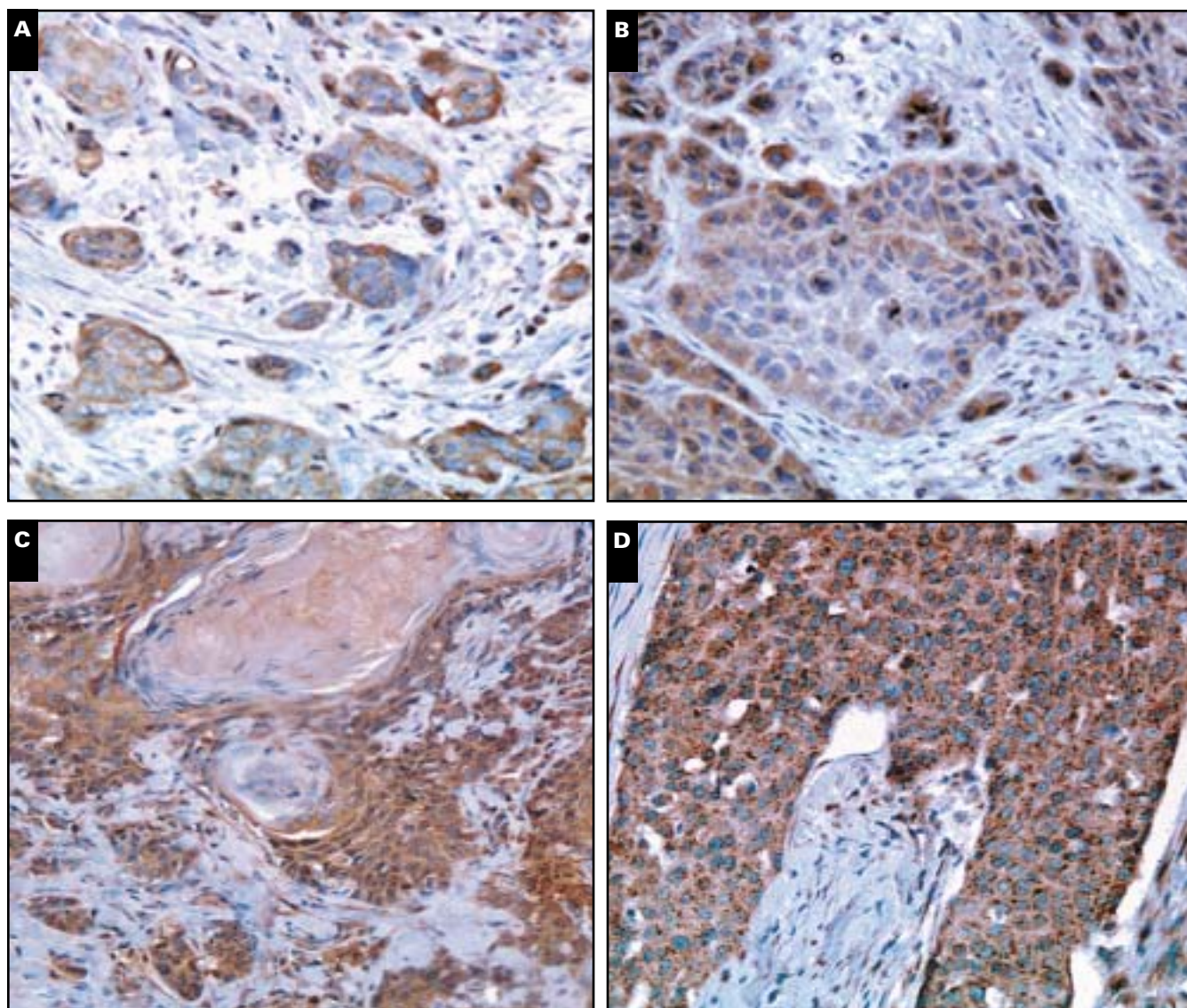


Image 1 Characteristic staining patterns of the tyrosine kinases and p-Akt in head and neck squamous cell carcinoma. **A**, Phosphorylated Akt ($\times 80$). **B**, Epidermal growth factor receptor ($\times 80$). **C**, Platelet-derived growth factor receptor ($\times 80$). **D**, c-kit ($\times 80$). Positive cases had intense membranous and cytoplasmic stains in a high percentage of carcinomas.

There are more than 90 known protein TKs in the human genome, represented by only 0.3% of the genes. However, somatic mutations or overexpression of certain TK proteins can transform them into oncogenes that are associated with a number of human cancers. Although there have been many reports of distribution of EGFR in HNSCC, to our knowledge, this is the first report detailing differential protein expression of the TKs PDGFR, c-kit, and EGFR and the expression of Akt, a serine-threonine protein kinase, in HNSCC. By using custom-designed tissue macroarray tumor and normal tissue blocks, we can achieve high throughput and uniform staining of the cases. The larger sample compared with conventional tissue microarray slides permits more extensive morphologic evaluation of different cell types in the same tissue sample.

Expression of c-kit

The c-kit protein is a receptor-type TK, structurally related to PDGFR. It has an important role in the development of hematopoietic cells, melanocytes, and germ cells. It has been described as overexpressed in several human solid tumors, including small cell lung cancer, GISTs, germ cell tumors, breast cancers, and salivary gland tumors.¹⁰⁻¹⁴ The expression of c-kit has not been studied in HNSCC. We found that the expression of c-kit was significantly higher in squamous cell carcinoma of the pharynx than of the larynx ($P = .04$). The biologic significance of this observation is unknown but could be related to the different embryologic derivatives of the larynx and pharynx. We also found that normal squamous epithelium of the pharynx and larynx has no c-kit expression compared with the cancer cases studied ($P = .04$). The presence of c-kit in HNSCC raises the possibility that a TK inhibitor such as imatinib mesylate could be used to treat HNSCC. More studies of HNSCC to examine possible mutations in the sequence of c-kit that would make it overactive, as in the case of GIST, are needed.

Expression of PDGFR

Platelet-derived growth factor (PDGF) is a potent mitogen. PDGFs bind with different affinities to 2 distinct types of surface receptors, α - and β -PDGFR.¹⁵ β -PDGFR binds all 3 PDGF isoforms. "Aberrant" expression of PDGFR has been linked to various human tumors such as small cell lung carcinoma¹⁶ and ovarian carcinoma.¹⁷ The antibody used in the present study recognizes the α and β forms of PDGFR. In Western blot analysis of PDGFR expression, both isoforms were present in 3 of 3 laryngeal squamous carcinoma cell lines that we tested (unpublished data, 2005). Because the expression of PDGFR is almost universal in the tumor and normal tissue samples we tested, the clinical significance of the presence of PDGFR expression is uncertain, and PDGFR might not provide a clinically useful target in therapy for HNSCC.

Expression of EGFR

EGFR is a TK family receptor. When activated, it promotes the activity of a number of downstream effectors involved in the PI3K/Akt,¹⁸ platelet phospholipase C- γ , and the ras/raf-1/mitogen-activated protein kinase pathways. Overexpression of EGFR has been described in a number of solid tumors and is present in 42% to 80% of HNSCCs studied.¹⁹ The present study confirmed previous reports of EGFR expression. However, of the 4 proteins for which expression is reported herein, EGFR was the least frequently expressed in HNSCC specimens. Nevertheless, EGFR expression in tumors was much greater than that in the normal tissue samples, a difference that approached statistical significance ($P = .1$). It is interesting that all c-kit-negative tumors also were EGFR-negative.

Expression of Akt

In addition to the aforementioned TKs, we also studied the expression of Akt, a serine-threonine protein kinase also known as protein kinase B, with homology to protein kinases A and C. Akt has been shown to have a role in cell cycle progression,²⁰ differentiation,¹⁵ angiogenesis, inhibition of apoptosis,^{20,21} and cell growth.¹⁵ Akt needs to be phosphorylated (p-Akt) to be active, so Akt activation by growth factors such as epidermal growth factor or PDGF requires PI3K activity.^{15,21} Akt has been shown to be overexpressed and amplified in ovarian, pancreatic, breast, non-small cell lung, prostate, and follicular thyroid cancers.²²⁻²⁴ In our study, we specifically stained for the phosphorylated form of Akt. p-Akt was expressed in 12 (57%) of 21 pharyngeal and 13 (81%) of 16 laryngeal tumors but in none of the normal cases, a significant difference ($P = .02$) suggesting high involvement of p-Akt in tumor development in the pharynx and larynx. This pattern of expression in the larynx and pharynx is the opposite of that seen with c-kit.

A recent study suggested that p-Akt is observed frequently in HNSCCs and that the staining pattern in human HNSCCs correlates with progression from metaplastic, dysplastic, and in situ to invasive tumors.²⁵ The staining pattern varied from nuclear stains in few metaplastic nuclei in the basal or parabasal layers to strong nuclear staining in cells of carcinoma in situ and to predominantly cytoplasmic stains in the invasive carcinoma cells. Our study confirmed this finding; the p-Akt-positive cases of invasive squamous cell carcinoma all had strong cytoplasmic expression in pharyngeal and laryngeal carcinomas.

There are many upstream pathways that eventually converge to the activation of Akt. Phosphatases, such as phosphatase and tensin deleted on chromosome 10 (PTEN), have been shown to be tumor suppressor proteins that dephosphorylate PI3K and, subsequently, lead to Akt phosphorylation. Once phosphorylated, Akt functions as a phosphatase, which plays a role to inhibit apoptosis. A recent study showed that inactivation or mutation of PTEN led to increased levels of PI3K and increased Akt activity.²⁶ It further showed that the

down-regulation of PTEN protein in HNSCC correlated significantly with activation of p-Akt. This finding further supports Akt as a potential target for therapeutic intervention in HNSCC.

We report expression profiles of the TK proteins PDGFR, EGFR, and c-kit and the serine-threonine kinase p-Akt in HNSCC. Expression of these proteins was high regardless of tumor grade, stage, or patient survival. Recently, many specific small-molecule TK inhibitors have been developed that are effective in inhibiting the proliferation of tumor cells expressing the target TKs. One of the well-characterized tyrosine kinase inhibitors, imatinib mesylate, effectively inhibits cellular proliferation of certain carcinomas, CML, and sarcomas that overexpress these markers. Long-term remissions of CML and GIST have been achieved with imatinib mesylate. Gefitinib and cetuximab, which target EGFR, have shown clinical activity against HNSCC, alone and in combination with radiation therapy. Based on the present study, it seems that in addition to EGFR, p-Akt and c-kit are expressed frequently in HNSCC but not in normal mucosa and could be considered potential molecular targets for drugs that inhibit their activity. PDGFR is expressed highly in normal upper aerodigestive tract mucosa and in HNSCC, and does not seem to be a useful drug target in HNSCC. Preclinical studies of molecules that block p-Akt and c-kit are the logical extension of the present study.

From the ¹Department of Surgery, Division of Head and Neck Surgery, University of California, San Diego; ²Otorhinolaryngology Service, Donostia Hospital, San Sebastián, Spain; and ³Department of Pathology, University of California, San Diego and VA San Diego Healthcare System, San Diego.

Supported by an Academic Senate Grant at the University of California, San Diego, and the Bell Foundation, San Diego.

Address reprint requests to Dr Wang-Rodriguez: Dept of Pathology, University of California, San Diego, VA San Diego Healthcare System, 3350 La Jolla Village Dr (113), San Diego, CA 92161.

*These authors contributed equally to the article.

References

- Vokes E, Weichselbaum RR, Lippman SM, et al. Head and neck cancer. *N Engl J Med*. 1993;328:184-194.
- Adjuvant chemotherapy for advanced head and neck squamous cell carcinoma: final report of the Head and Neck Contracts Program. *Cancer*. 1987;60:301-311.
- Overgaard J, Sorensen S, Stausbol-Gron B, et al. TP53 mutation is an independent prognostic marker for poor outcome of radiotherapy in squamous cell carcinoma of the head and neck [abstract]. *Int J Radiat Oncol Biol Phys*. 1998;42:43.
- Rubin Grandis J, Melhem MF, Gooding WE, et al. Levels of TGF- α and EGFR protein in head and neck squamous cell carcinoma and patient survival. *J Natl Cancer Inst*. 1998;90:824-832.
- Pignataro L, Pruneri G, Carboni N, et al. Clinical relevance of cyclin D1 protein overexpression in laryngeal squamous cell carcinoma. *J Clin Oncol*. 1998;16:3069-3077.
- Blume-Jensen P, Hunter T. Oncogenic kinase signalling. *Nature*. 2001;411:355-365.
- Levitzki A, Gazit A. Tyrosine kinase inhibition: an approach to drug development. *Science*. 1995;267:1782-1788.
- Ford A, Grandis JR. Targeting EGFR in HNSCC. *Head Neck*. 2003;25:67-73.
- Matei D, Chang DD, Jeng MH. Imatinib mesylate (Gleevec) inhibits ovarian cancer cell growth through mechanism dependent on PDGFR and Akt inactivation. *Clin Cancer Res*. 2004;10:681-690.
- Sekido Y, Obata Y, Ueda R, et al. Preferential expression of c-kit proto-oncogene transcripts in small cell lung cancer. *Cancer Res*. 1991;51:2416-2419.
- Strohmeier T, Peter S, Hartmann M, et al. Expression of the hst-1 and c-kit proto-oncogenes in human testicular germ cell tumours. *Cancer Res*. 1991;51:1811-1816.
- Hines S, Organ C, Kornstein M, et al. Co-expression of the c-kit and stem cell factor genes in breast carcinomas. *Cell Growth Differ*. 1995;6:769-779.
- Hirota S, Isozaki K, Moriyama Y, et al. Gain-of-function mutations of c-kit in human gastrointestinal stromal tumours. *Science*. 1998;279:577-580.
- Jeng Y, Lin CY, Hsu HC. Expression of the c-kit protein is associated with certain subtypes of salivary gland carcinoma. *Cancer Lett*. 2000;154:107-111.
- Grille S, Bellacosa A, Upson J, et al. The protein kinase Akt induces epithelial mesenchymal transition and promotes enhanced motility and invasiveness of squamous cell carcinoma lines. *Cancer Res*. 2003;63:2172-2178.
- Kawai T, Hiroi S, Torikata C. Expression in lung carcinomas of PDGF and its receptors. *Lab Invest*. 1997;77:431-436.
- Henriksen R, Funa K, Wilander E, et al. Expression and prognostic significance of PDGF and its receptors in epithelial ovarian neoplasms. *Cancer Res*. 1993;53:4550-4554.
- Okano J-I, Gaslightwala I, Birnbaum MJ, et al. Akt/PKB isoforms are differentially regulated by EGF stimulation. *J Biol Chem*. 2000;275:30934-30942.
- Quon H, Liu FF, Cummings BJ. Potential molecular prognostic markers in head and neck squamous cell carcinomas. *Head Neck*. 2001;23:147-159.
- Franke TF, Cantley LC. Apoptosis: a Bad kinase makes good. *Nature*. 1997;390:116-117.
- Franke T, Kaplan DR, Cantley LC. PI3K: downstream AKTion blocks apoptosis. *Cell*. 1997;88:435-437.
- Sun M, Wang G, Paciga JE, et al. Akt1/PKB α kinase is frequently elevated in human cancers and its constitutive activation is required for oncogenic transformation in NIH3T3 cells. *Am J Pathol*. 2001;159:431-437.
- Bellacosa A, de Feo D, Godwin A, et al. Molecular alterations of Akt2 oncogene in ovarian and breast carcinomas. *Int J Cancer*. 1995;64:280-285.
- Ringel M, Hayre N, Saito J, et al. Overexpression and overactivation of Akt in thyroid carcinoma. *Cancer Res*. 2001;61:6105-6111.
- Amornphimoltham P, Sriuranpong V, Patel V, et al. Persistent activation of the Akt pathway in head and neck squamous cell carcinoma: a potential target for UCN-01. *Clin Cancer Res*. 2004;10(12 pt 1):4029-4037.
- Pedrero J, Carracedo D, Pinto C, et al. Frequent genetic and biochemical alterations of the PI 3-K/AKT/PTEN pathway in head and neck squamous cell carcinoma. *Int J Cancer*. 2005;114:242-248.