

Postoperative Tamponade and Positioning Restrictions After Macular Hole Surgery

Yuhei Hasegawa, Yasutaka Mochizuki and Yasuaki Hata
*Department of Ophthalmology,
 Graduate School of Medical Sciences, Kyushu University
 Japan*

1. Introduction

Idiopathic macular hole is a defect of the foveal retina involving its full thickness from the internal limiting membrane to the outer segment of the photoreceptor layer. According to the Gass Classification System, macular holes can be classified into four stages as shown in Table 1 (Gass, 1995).

Stage 1a	Foveal detachment. Macular cyst. Tangential vitreous traction results in the elevation of the fovea.
Stage 1b	As the foveal retina elevates to the level of the perifoveal, the yellow dot of xanthophyll pigment changes to a donut shaped yellow ring.
Stage 2	A full-thickness macular hole less than 400 μm in size.
Stage 3	A full-thickness macular hole which is greater than 400 μm in size and is still with partial vitreomacular adhesion/traction.
Stage 4	A full-thickness macular hole exists in the presence of a complete separation of the vitreous from the macula and the optic disc.

Table 1. Gass classification of idiopathic macular hole

Indications of the surgical management of macular hole are based on the presence of a full-thickness defect (stage 2 or higher). Once this defect has developed, the potential for spontaneous resolution is low. Since the initial report by Kelly NE, the surgical technique of idiopathic macular hole has been improved (Kelly & Wendel, 1991). Currently, the most standard surgical technique for the treatment of idiopathic macular hole is pars plana vitrectomy with peeling of the internal limiting membrane and intraocular gas tamponade followed by prone positioning (Schaal et al., 2006). However, the mechanisms of macular hole closure have not been fully elucidated. There are two theories accounting for the process of macular hole closure and the role of the tamponade material. One is the buoyancy theory and the other is the isolation theory (Gupta, 2009). The buoyancy theory is based on the idea that the buoyancy force 'presses' the edges of the macular hole. Thus, prone positioning is considered necessary for closure of the macular hole. On the other hand, the isolation theory, which is also called 'waterproofing', is based on the idea that the

tamponade material 'plug' the macular hole and subretinal fluid is absorbed by retinal pigment epithelium (Goldbaum et al., 1998). macular hole might thus be closed without prone positioning as long as there is adequate isolation of aqueous humor (Figure 1).

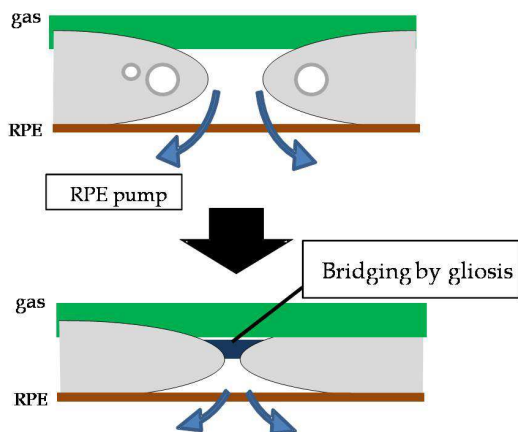


Fig. 1. Scheme of the isolation theory. RPE; retinal pigment epithelium

It has been reported that the prognostic factors of macular hole surgery were the stage of macular hole and hole diameter, but it remains unclear which is the most important factor for surgical outcome of macular hole (Ellis et al., 2000; Ullrich et al., 2002; Wells & Gregor, 1996). In our previous study, hole diameter was the most important prognostic factor among them (Hasegawa et al., 2009). And, the high closure rates were recently achieved regardless of tamponade material, so, there are many reports regarding the selection of tamponade material and the necessity of positioning restrictions after macular hole surgery. The tamponade materials have several features, and the extent of positioning restrictions vary among them. In this review, we will discuss recent advances in tamponade materials and positioning restrictions after macular hole surgery.

2. Tamponade materials after vitrectomy for macular hole

Sulfur hexafluoride (SF_6), octafluoropropane (C_3F_8), hexafluoroethane (C_2F_6), room air and silicone oil are common tamponade materials (Goldbaum et al., 1998; Park et al., 1999; Thompson et al., 1996; Tornambe et al., 1997). Although the exact mechanism of the tamponade material is controversial, it is thought that the longer the tamponade material stays in the operated eye, the surer the effect of tamponade, but, confirmation of macular hole closure and visual rehabilitation is delayed while tamponade material is covering the macular region. In addition, the residual tamponade material in the vitreous cavity impedes return to normal activity, especially in the case of long-acting gas or silicone oil. For example, patients with a gas bubble in their eyes cannot generally undertake air travel, and a refractive hyperopic shift occurs in the eyes filled with silicone oil. Additionally when using silicone oil, patients need to undergo re-operation for later removal. Frequently it takes over one week before one is able to examine the state of the macular regions through aqueous humor when using long-acting gas. Using room air, this generally becomes possible in about 3 days. There are also various opinions regarding the necessity of positioning restrictions after macular hole

surgery. Positions include prone (face-down), seated, lateral and avoid spine (not to lie flat on the back) positioning (Chignell & Billington, 1986; Krohn, 2005; Madula & Costen, 2008; Merkur & Tuli, 2007; Minihan et al., 1997; Thompson et al., 1994; Tornambe et al., 1997; Tranos et al., 2007). It has been thought that macular hole is expected to close when adequately isolated from aqueous humor (the isolation theory) (Goldbaum et al., 1998). Probably, the surest positioning for isolation of macular hole is prone positioning. However, it is better to shorten the prone positioning period as much as possible because most patients suffer from discomfort and noncompliance when continuing the such positioning for extended periods. Nevertheless, it is important to maintain adequate closure rates. There are many reports describing how long a duration of prone positioning is required (Krohn, 2005; Sato & Isomae, 2003; Takahashi & Kishi, 2000; Thompson et al., 1996; Isomae et al., 2002). Opinions range from 1day to 4 weeks. In addition, there are several reports of successful macular hole closure without prone positioning (Merkur & Tuli, 2007; Tornambe et al., 1997; Tranos et al., 2007). The selection of tamponade material has relevance to the type of positioning restrictions. That is to say, the positioning restriction could be eased when using a gas with extended duration in the operated eye. The choice of tamponade material or positioning after macular hole surgery is dependent upon many issues, such as the opinion of surgeons or the condition of patients. Which is the best tamponade material after vitrectomy for macular hole? Which positioning is the most adequate for both the treatment of macular hole and the benefit of patients? In the present issue, we will review the various points of view.

3. Usefulness of room air as a tamponade material

It was reported that a long-acting intraocular gas tamponade is a substantially higher success rate for macular hole surgery as compared with a short-acting one (Thompson et al., 1994). However, gas tamponade may cause several side effects including intraocular pressure elevation and retinal artery occlusion due to its expansion when not diluted appropriately. Although it is generally known that SF₆ should be diluted to 20 %, and that C₃F₈ to 12 %, intraocular pressure elevation actually occurred sometimes. And postoperative cataract development is also worried for phakic eyes, especially for traumatic macular holes of young patients who should not undergo cataract surgery simultaneously. On the other hand, complications were rare according to our experiences when air was used as a tamponade material because it is not expanded and is absorbed faster than long-acting gas. Indeed, the usefulness of air as a tamponade material after vitrectomy for macular hole has been recently reported (Hasegawa et al., 2009; Krohn, 2005; Sato et al., 2003). Hikichi et al. reported that macular holes closed successfully after the primary vitrectomy in all eyes using air tamponade (Hikichi et al., 2011). Their studies reported high closure rates of 91 % to 100 %. We also investigated the tamponade effect of air and the shortening of the prone positioning period (Hasegawa et al., 2009). In this study, the macular hole closure was postoperatively confirmed by optical coherence tomography once the macular area could be precisely examined through aqueous humor. At that time, prone positioning was terminated. The primary closure rate was 92.3 % after 3.83 days of prone positioning and is consistent with other tamponade materials. Thus, air may have equivalent tamponade effect after macular hole surgery compared with other tamponade materials (Da Mata et al., 2004; Haritoglou et al., 2006; Lai & Williams, 2007). Moreover, air with its short duration in the postoperative eye can result in more rapid visual rehabilitation and earlier detailed evaluation of the macular region. According to the isolation theory, the buoyancy force may not be as important for macular hole closure, and macular

hole is likely to close when isolated adequately from aqueous humor (Stopa et al., 2007). However, we request patients to maintain prone positioning for at least several hours after their operation. At this time, there is insufficient evidence to allow firm conclusions as to whether prone positioning after macular hole surgery influences closure rates. More recently, the early postoperative state of macular hole can be investigated because imaging of the macular region through gas bubble may now be obtained by advances in optical coherence tomography technology (Eckardt et al., 2008; Kasuga et al., 2000; Masuyama et al., 2009).

4. Trial to shorten prone positioning period

It is thought that prone positioning is not inherently necessary (Gupta, 2009). Many macular holes, especially small size holes, are expected to close without prone positioning according to the isolation theory. Although we think that prone positioning is the best way for optimizing isolation of macular hole, we also think that the prone positioning period should be shortened as much as possible. So, we performed a trial to shorten the prone positioning period while maintaining sufficient closure rates. Our method is to terminate the prone positioning once we can confirm anatomical closure of the hole using optical coherence tomography even under retained tamponade material. First, optical coherence tomography images were obtained 6 hours after vitrectomy. When we could not confirm that the hole was closed, optical coherence tomography images were obtained again 24 hours after operation. And, we repeated this procedure every 24 hours till the hole closure was confirmed. We present the results in this chapter. This study was approved by the Institutional Review Board and performed in accordance with the ethical standards of the 1989 Declaration of Helsinki. Written informed consents were obtained from all patients enrolled in this study. This study consists of a prospective consecutive series of macular hole patients after vitrectomy with internal limiting membrane peeling. A total of 16 eyes (5 male eyes and 11 female eyes) of 16 patients and aged 55-83 years (average 66 years) were identified. Figure 2 is the representative image of postoperative macular region in air-filled eye.

We judged the macular hole to be closed when the edges of hole were connected in all slices of spectral-domain-optical coherence tomography, and prone positioning was terminated 6 hours after operation in this case. The optical coherence tomography image in 11 eyes (68.8 %) could be obtained at the day of vitrectomy and the prone positioning was terminated in 72.8 % of them (50 % of all cases) since the hole closure was confirmed by all slices. The hole was finally judged to be closed or not to be under the presence of air in 15 eyes/ 16 eyes (93.8 %) (Table 2).

Day from operation		Closed eyes (Closure rates)
Operation's day	11/16 eyes (68.8 %)	8 eyes (50 %)
One day	13/16 eyes (81.3 %)	13 eyes (81.3%)
Two days	15/16 eyes (93.8 %)	14 eyes (87.5%)

Table 2. Cases which their macular region could be confirmed by spectral-domain-optical coherence tomography under air bubble

As shown in Figure 3, prone positioning could be terminated in less than 24 hours in 13 eyes (81.3 %).

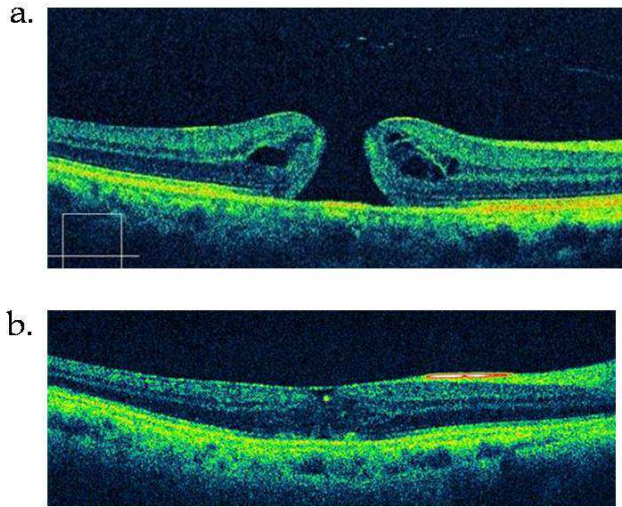


Fig. 2. Representative images of preoperative macular hole (a) and postoperative macular region in air-filled eye (b)

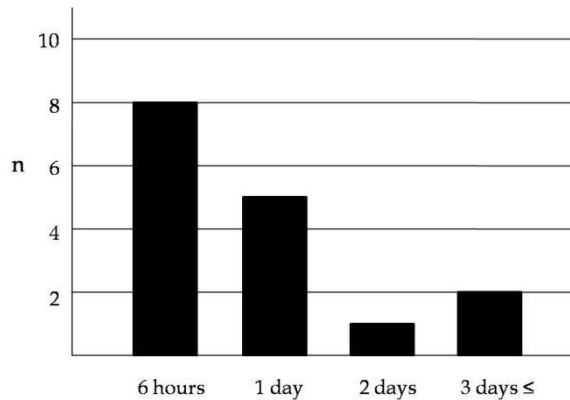


Fig. 3. Period of prone positioning

Compared with our previous report, the primary closure rate, which is 87.5 % (14 of 16 eyes), was almost equal and the mean prone positioning period, which is 2.24 days, in this study was shorter. (Hasegawa et al., 2009) One unclosed case was finally closed after the retinal stretch and the exchange of vitreous cavity by 20 % SF₆ at 5 days after operation with 1 day prone positioning after reoperation. In another unclosed case, although we once judged the hole to be closed by optical coherence tomography images and the prone positioning was terminated as shown in Figure 4, the patient restarted prone positioning next day because the hole was confirmed not to be closed.

It was finally closed without reoperation for 4 days prone positioning. Thus it appears easier to judge that macular hole is not closed than it is to determine if the macular hole is closed.

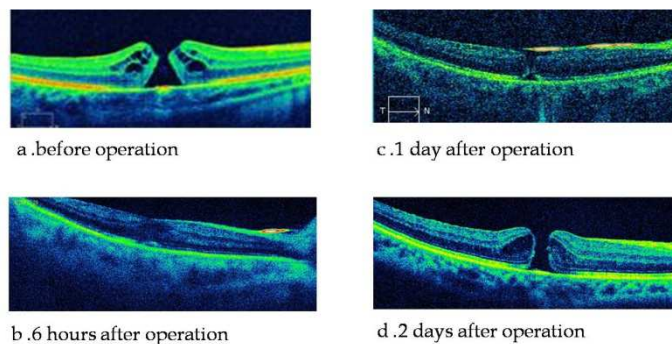


Fig. 4. A case in whom prone positioning was continued for 4 days

The thinly sliced optical coherence tomography images and re-examinations are necessary for surer confirmation of macular hole closure when using this method. The daily images of optical coherence tomography monitoring may become a help to resolve the healing procedure of macular hole. This study is limited by the few cases evaluated and further investigation is necessary.

5. Discussion

There has been no absolute generally accepted answer with regard to which is the best tamponade material after vitrectomy for macular hole. Widely used tamponade materials include SF₆, C₃F₈, C₂F₆, air and silicone oil. Silicone oil usually is not selected after macular hole surgery except in the case of macular hole with retinal detachment (Wolfensberger TJ & Gonvers M, 1999). After Tornambe et al. reported that they had achieved hole closure in 79% of their cases using a 15% C₃F₈ without prone positioning, many studies have been performed concerning tamponade materials and posturing (Tornambe et al. 1997). So far, a long-acting gas has been used more frequently than air. However, usefulness of air was recently investigated. At first, Park et al. used air tamponade with 4 days prone positioning and observed hole closure in 91% (Park et al., 1999). A closure rate over 90% has been reported using air, including our previous report (Hasegawa et al., 2009; Hikichi et al., 2011; Sato et al., 2003). The recent views concerning management after macular hole surgery can be divided into two general approaches. One is using long-acting gas with loose positioning restrictions. The other is using air with prone positioning while shortening the period as much as possible. In our current treatment for macular hole, we use air tamponade with prone positioning and terminate the prone positioning once we can confirm anatomical closure using optical coherence tomography under the presence of air. The closure rate of 87.5% was almost equal to the result of Eckardt et al. in which they used similar methods as ours (Eckardt et al., 2008). In previous studies, it has been reported that the prognostic factors of macular hole surgery were the stage of macular hole, hole diameter, age of the macular hole and axial length (Ellis et al., 2000; Suda et al., 2011; Ullrich et al., 2002; Wells & Gregor, 1996). There were two cases required prone positioning over 3 days in this study. One case was an old (5 years) and large hole (870 μm) and the other was also an old hole (15 years). In order to increase closure rates more, it might be better to use long-acting gas as tamponade material for keeping macular region dry for longer time and perform the

additional treatment such as retinal stretch in cases which have bad prognostic factors, such as large diameter or long axial length (Wells & Gregor, 1996; Suda et al., 2011). We assume hole closure once there is connection of hole edges. However, there was one case where the hole was actually not closed even though we had judged it to be closed as shown in Figure 4. Arima et al. reported the supportive usefulness of fundus autofluorescence for confirming macular hole closure (Arima et al., 2009).

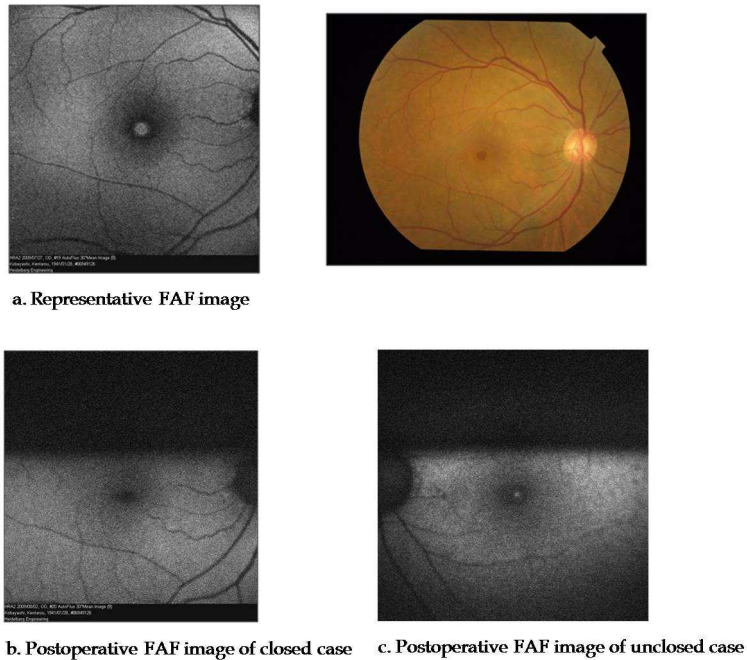


Fig. 5. Representative fundus autofluorescence (FAF) images

- Representative preoperative FAF image and Fundus Photography
- Postoperative FAF image of closed case
- Postoperative FAF image of unclosed case

As shown in Figure 5, unclosed macular hole reveals a bright hyperfluorescence spot and a tiny space of retina which can be overlooked by optical coherence tomography can be detected by fundus autofluorescence imaging. However, early closure of macular hole cannot be confirmed using fundus autofluorescence imaging because it cannot be obtained through a gas/air bubble. There are several differences such as half-life, side effects and the way of positioning restriction, between long-acting gas and air and cases of macular hole can also vary substantially. For example, there are some instances in which patients cannot maintain prone positioning due to their general conditions. In addition, the methods of macular hole treatment have been increasing because small-gauge transconjunctival vitrectomy is gaining wide acceptance recently (Fujii et al., 2002; Fujii et al., 2002). It is important for each operator to select the tamponade material and posturing which is thought to be the most suitable for each patient. The role of tamponade material has been widely debated. Gupta mentioned the

comparison of two theories, namely the buoyancy theory and the isolation theory, regarding the role of the tamponade material in his review manuscript (Gupta, 2009). The former is based on the idea that the buoyancy force (floating force) may be necessary to maintain a mechanical pressure against the hole edges. With regard to the buoyancy theory, it is by that buoyancy forces cannot be of significance in gas-filled eyes immediately after operation (Stopa et al., 2007). Indeed, many studies report equivalent macular hole closure rates using long-acting gas or silicone oil (which has very little buoyancy force) without prone posturing. This seems to support the isolation theory, but not the buoyancy theory. The latter is based on the idea that the gas bubble may provide a scaffold to support formation of a bridging preretinal membrane and that subretinal fluid will be eliminated via the retinal pigment epithelium pump when tamponade materials ensure the macula remains dry (Figure 1) (Berger & Brucker, 1998; Gupta, 2009). However, it is rather difficult to document the occurrence of the healing responses, such as a cellular migration (Charles, 2004). Recently, several reports have confirmed that holes can close as early as 1 day after surgery using optical coherence tomography images under the gas/air bubble (Jumper et al., 2000; Satchi & Patel, 2002). According to the isolation theory, prone posturing seems not to be necessary in early closed cases.

6. Conclusion

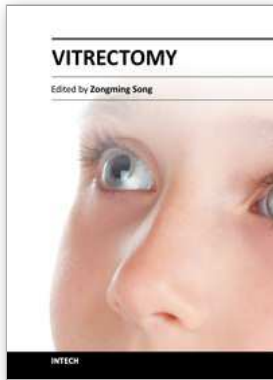There are numerous opinions concerning the selection of tamponade material and the necessity of prone positioning after macular hole surgery. Different cases may need to be approached in different ways. It is important to select the tamponade material and posturing approach in relation to each individual situation. The confirmation of early macular hole closure using optical coherence tomography imaging under the gas/air bubble can be a great help in modifying subsequent care. Further investigations are required to maximize macular hole closure rates while shortening the period of postoperative position restrictions.

7. References

- Arima, M.; Miyazaki, M.; Kohno, R.; Hata, Y. & Ishibashi, T. (2009) An early "reopening" case of idiopathic macular hole; supportive usefulness of fundus autofluorescence. *Graefes Arch Clin Exp Ophthalmol* Vol.247, No.5, pp. 711-714, ISSN 0721-832X
- Berger, JW. & Brucker, AJ. (1998) The magnitude of the bubble buoyant pressure: implications for macular hole surgery. *Retina* Vol.18, No.1, pp. 86-88, ISSN 0275-004X
- Charles S (2004) An engineering approach to vitreoretinal surgery. *Retina* Vol.24, No.3, pp. 435-444, ISSN 0275-004X
- Chignell, AH. & Billington, B. (1986) The treatment of macular holes by pars plana vitrectomy and internal air/SF6 exchange. *Graefes Arch Clin Exp Ophthalmol* Vol.224, No.1, pp. 67-68, ISSN 0721-832X
- Da Mata, AP.; Burk, SE.; Foste, RE.; Riemann, CD.; Petersen, MR.; Nehemy, MB. & Augsburger, JJ. (2004) Long-term follow-up of indocyanine green-assisted peeling of the retinal internal limiting membrane during vitrectomy surgery for idiopathic macular hole repair. *Ophthalmology* Vol.111, No.12, pp. 2246-2253
- Eckardt, C.; Eckert, T.; Eckardt, U.; Porkert, U. & Gesser, C. (2008) Macular hole surgery with air tamponade and optical coherence tomography-based duration of face-down positioning. *Retina* Vol.28, No.8, pp. 1087-1096, ISSN 0275-004X

- Ellis, JD.; Malik, TY.; Taubert, MA.; Barr, A. & Baines, PS. (2000) Surgery for full-thickness macular holes with short-duration prone posturing: results of a pilot study. *Eye* Vol.14, Jun, Pt 3A, pp. 307-312, ISSN 0950-222X
- Fujii, GY.; De Juan, E. Jr.; Humayun, MS.; Chang, TS.; Pieramici, DJ.; Chang, TS.; Awh, C.; Ng, E.; Barnes, A.; Wu, SL. & Somerville, DN. (2002) A new 25-gauge instrument system for transconjunctival sutureless vitrectomy surgery. *Ophthalmology* Vol.109, No.10, pp. 1807-1812
- Fujii, GY.; De Juan, E. Jr.; Humayun, MS.; Chang, TS.; Pieramici, DJ.; Barnes, A. & Kent, D. (2002) Initial experience using the transconjunctival sutureless vitrectomy system for vitreoretinal surgery. *Ophthalmology* Vol.109, No.10, pp. 1814-1820
- Gass, JD. (1995) Reappraisal of biomicroscopic classification of stages of development of a macular hole. *Am J Ophthalmol* Vol.119, No.6, pp. 752-759, ISSN 0002-9394
- Goldbaum, MH.; McCuen, BW.; Hanneken, A.; Burgess, SK. & Chen, HH. (1998) Silicone oil tamponade to seal macular holes without position restrictions. *Ophthalmology* Vol.105, No.11, pp. 2140-2148
- Gupta, D. (2009) Face-down posturing after macular hole surgery: a review. *Retina* Vol.29, No.4, pp. 430-443, ISSN 0275-004X
- Haritoglou, C.; Reiniger, IW.; Schaumberger, M.; Gass, CA.; Priglinger, SG. & Kampik, A. (2006) Five-year follow-up of macular hole surgery with peeling of the internal limiting membrane: update of a prospective study. *Retina* Vol.26, No.6, pp. 618-622, ISSN 0275-004X
- Hasegawa, Y.; Hata, Y.; Mochizuki, Y.; Arita, R.; Kawahara, S.; Kita, T.; Noda, Y. & Ishibashi, T. (2009) Equivalent tamponade by air compared with SF₆ after macular hole surgery. *Graefes Arch Clin Exp Ophthalmol* Vol.247, No.11, pp. 1455-1459, ISSN 0721-832X
- Hikichi, T.; Kosaka, S.; Takami, K.; Ariga, H.; Ohtsuka, H.; Higuchi, M.; Matsushita, T. & Matsushita, R. (2011) 23- and 20-gauge vitrectomy with air tamponade with combined phacoemulsification for idiopathic macular hole: a single-surgeon study. *Am J Ophthalmol* Vol.152, No.1, pp. 114-121, ISSN 0002-9394
- Isomae, T.; Sato, Y. & Shimada, H. (2002) Shortening the duration of prone positioning after macular hole surgery comparison between 1-week and 1-day prone positioning. *Jpn J Ophthalmol* Vol.46, No.1, pp. 84-88, ISSN 0021-5155
- Jumper, JM.; Gallemore, RP.; McCuen, BW. 2nd. & Toth, CA. (2000) Features of macular hole closure in the early post-operative period using optical coherence tomography. *Retina* Vol.20, No.3, pp.232-237, ISSN 0275-004X
- Kasuga, Y.; Arai, J.; Akimoto, M. & Yoshimura, N. (2000) Optical coherence tomography to confirm early closure of macular holes. *Am J Ophthalmol* Vol.130, No.5, pp. 675-676, ISSN 0002-9394
- Kelly, NE. & Wendel, RT. (1991) Vitreous surgery for idiopathic macular holes. Results of a pilot study. *Arch Ophthalmol* Vol.109, No.5, pp. 654-659, ISSN 0003-9950
- Krohn, J. (2005) Duration of face-down positioning after macular hole surgery: a comparison between 1 week and 3 days. *Acta ophthalmol Scand* Vol.83, No.3, pp. 289-292, ISSN 1395-3907
- Lai, MM. & Williams, GA. (2007) Anatomical and visual outcomes of idiopathic macular hole surgery with internal limiting membrane removal using low-concentration indocyanine green. *Retina* Vol.27, No.4, pp. 477-482, ISSN 0275-004X
- Madula, IM. & Costen, M. (2008) Functional outcome and patient preferences following combined phaco-vitrectomy for macular hole without prone posturing. *Eye* Vol.22, Jun, pp. 1050-1053, ISSN 0950-222X

- Masuyama, K.; Yamakiri, K.; Arimura, N.; Sonoda, Y.; Doi, N. & Sakamoto, T. (2009) Posturing time after macular hole surgery modified by optical coherence tomography images: a pilot study. *Am J Ophthalmol* Vol.147, No.3, pp. 481-488, ISSN 0002-9394
- Merkur, AB. & Tuli, R. (2007) Macular hole repair with limited nonsupine positioning. *Retina* Vol.27, No.3, pp. 365-369, ISSN 0275-004X
- Minihan, M.; Goggin, M. & Cleary, PE. (1997) Surgical management of macular holes: results using gas tamponade alone, or in combination with autologous platelet concentrate, or transforming growth factor beta 2. *Br J Ophthalmol* Vol.81, No.12, pp. 1073-1079, ISSN 0007-1161
- Park, DW.; Sipperley, JO.; Sneed, SR.; Dugel, PU. & Jacobsen, J. (1999) Macular hole surgery with internal-limiting membrane peeling and intravitreal air. *Ophthalmology* Vol.106, No.7, pp. 1392-1398
- Satchi, K. & Patel, CK. (2002) Posterior chamber compartments demonstrated by optical coherence tomography, in silicone filled eyes, following macular hole surgery. *Clin Experiment Ophthalmol*. Vol.33, No.6, pp.619-622, ISSN 1442-6404
- Sato, Y. & Isomae, T. (2003) Macular hole surgery with internal limiting membrane removal, air tamponade, and 1-day prone positioning. *Jpn J Ophthalmol* Vol.47, No.1, pp. 503-506, ISSN 0021-5155
- Schaal, KB.; Bartz-schmidt, KU. & Dithmar, S. (2006) Current strategies for macular hole surgery in Germany, Australia and Switzerland. *Ophthalmologie* Vol.103, No.5, pp. 922-926, ISSN 1433-0423
- Stopa, M.; Lincoff, A. & Lincoff, H. (2007) Analysis of forces acting upon submacular hemorrhage in pneumatic displacement. *Retina* Vol.27, No.3, pp. 370-374, ISSN 0275-004X
- Suda, K.; Hangai, M. & Yoshimura, N. (2011) Axial length and outcomes of macular hole surgery assessed by spectral-domain optical coherence tomography. *Am J Ophthalmol* Vol.151, No.1, pp. 118-127, ISSN 0002-9394
- Takahashi, H. & Kishi, S. (2000) Tomographic features of early macular hole closure after vitreous surgery. *Am J Ophthalmol* Vol.130, No.2, pp. 192-196, ISSN 0002-9394
- Thompson, JT.; Glaser, BM.; Sjaarda, RN.; Murphy, RP. & Hanham, A. (1994) Effects of intraocular bubble duration in the treatment of macular holes by vitrectomy and transforming growth factor-beta 2. *Ophthalmology* Vol.101, No.7, pp. 1195-1200
- Thompson, JT.; Smiddy, WE.; Glaser, BM.; Sjaarda, RN. & Flynn, HW. Jr. (1996) Intraocular tamponade duration and success of macular hole surgery. *Retina* Vol.16, No.5, pp. 373-382, ISSN 0275-004X
- Tornambe, PE.; Poliner, LS. & Grote, K. (1997) Macular hole surgery without face-down positioning. A pilot study. *Retina* Vol.17, No.3, pp. 179-185, ISSN 0275-004X
- Tranos, PG.; Peter, NM.; Nath, R.; Singh, M.; Dimitrakos, S.; Charteris, D. & Kon, C. (2007) Macular hole surgery without prone positioning. *Eye* Vol.21, No.6, pp. 802-806, ISSN 0950-222X
- Ullrich, S.; Haritoglou, C.; Gass, C.; Schaumberger, M.; Ulbig, MW. & Kampik, A. (2002) Macular hole size as a prognostic factor in macular hole surgery. *Br J Ophthalmol* Vol.86, No.4, pp. 390-393, ISSN 0007-1161
- Wells, JA. & Gregor, ZJ. (1996) Surgical treatment of full-thickness macular holes using autologous serum. *Eye* Vol.10, No.5, pp. 593-599, ISSN 0950-222X
- Wolfensberger, TJ. & Gonvers, M. (1999) Long-term follow-up of retinal detachment due to macular hole in myopic eyes treated by temporary silicone oil tamponade and laser photocoagulation. *Ophthalmology* Vol.106, No.9, pp. 1786-1791



Vitrectomy

Edited by Dr. Zongming Song

ISBN 978-953-51-0546-6

Hard cover, 96 pages

Publisher InTech

Published online 20, April, 2012

Published in print edition April, 2012

This book is a comprehensive and systematic introduction to the basic theory, surgical techniques and the latest advances in vitrectomy. It focuses on vitreoretinal surgical indications and contraindications, surgical and operating techniques, surgery-related complications and their prevention, post-operation evaluation and prognosis. The book is divided into 6 chapters and has abundant content as well as a strong scientific and practical value. This book will be a valuable reference to ophthalmologists on all levels, especially vitreoretinal surgeons and researchers.

How to reference

In order to correctly reference this scholarly work, feel free to copy and paste the following:

Yuhei Hasegawa, Yasutaka Mochizuki and Yasuaki Hata (2012). Postoperative Tamponade and Positioning Restrictions After Macular Hole Surgery, Vitrectomy, Dr. Zongming Song (Ed.), ISBN: 978-953-51-0546-6, InTech, Available from: <http://www.intechopen.com/books/vitrectomy/postoperative-tamponade-and-positioning-restrictions-after-macular-hole-surgery>

INTECH

open science | open minds

InTech Europe

University Campus STeP Ri
Slavka Krautzeka 83/A
51000 Rijeka, Croatia
Phone: +385 (51) 770 447
Fax: +385 (51) 686 166
www.intechopen.com

InTech China

Unit 405, Office Block, Hotel Equatorial Shanghai
No.65, Yan An Road (West), Shanghai, 200040, China
中国上海市延安西路65号上海国际贵都大饭店办公楼405单元
Phone: +86-21-62489820
Fax: +86-21-62489821