

Original Article

Preliminary effect of posterolateral ankle arthroscopy for ankle fractures in elderly patients

Tao Ge, Ming Chen, Mingqing Zheng, Xinliang Wang, Jianwei Wang, Guangming Zhang

Department of Orthopedics and Trauma, Guangzhou First People's Hospital, Guangzhou Medical University, Guangzhou, China

Received March 11, 2017; Accepted April 7, 2017; Epub June 15, 2017; Published June 30, 2017

Abstract: Objective: To investigate the therapeutic effect of posterolateral approach to ankle arthroscopy in management of ankle fractures. Methods: Between March 2014 and May 2016, 68 patients with ankle fractures treated in our hospital were enrolled as subjects and randomly assigned to receive either standard open reduction (the control group, n=34) or the posterolateral approach to ankle arthroscopy (the experimental group, n=34). Therapeutic effect, operative time, intraoperative bleeding and postoperative recovery time were compared between the two groups. Ankle joint functions before and after surgery were assessed using the McGuire scoring system; and the patients' pain recovery was assessed using the pain visual analog scale (VAS). Results: The differences in good-excellent results (73.5% vs 35.3%) and qualified results (91.2% vs 70.6%) between the two groups were statistically significant ($P=0.000$); and the operative time, intraoperative bleeding and postoperative recovery time were significantly reduced in the experimental group as compared with the control group (52.1 ± 9.8 min vs 74.1 ± 9.2 min, 60.7 ± 14.5 ml vs 210.8 ± 54.2 ml, 6.6 ± 1.3 d vs 10.9 ± 1.5 d, respectively). After surgery, the amplitude of improvement in McGuire score of ankle joint function was significantly greater in the experimental group than in the control group (35.3 ± 2.8 vs 22.6 ± 2.5 , $P=0.000$), and the VAS scores in the experimental group were superior to those of the patients in the control group (2.8 ± 1.05 vs 4.1 ± 1.2 , $P=0.000$). Conclusion: The posterolateral approach to ankle arthroscopy for management of ankle fractures is advantageous over standard open reduction in the following aspects: better therapeutic effect, shorter operation time, less intraoperative bleeding, shorter postoperative recovery time. Thus, it is worthy of extensive clinical application.

Keywords: Ankle fracture, arthroscopic surgery, posterolateral approach, postoperative recovery

Introduction

The ankle joint, one of the large load-bearing joints in human body, has important function of load-bearing and movement of the lower limbs and is directly correlated with the motor function of a patient. Due to the complex physiological structure of the ankle joint, an event of ankle fracture is usually associated with joint dislocation, ligaments and cartilage injury, which greatly reduces the quality of life of the patients [1, 2]. The open reduction and internal fixation (ORIF) alone for treatment of ankle fractures can ensure the recovery of the normal alignment, but it cannot manage the articular cartilage and ligament lesions. Consequently, it fails to effectively restore the physiological structure of the ankle joint, mostly leading to frequent postoperative chronic lesions, arthritis and other complications.

With the advances of arthroscopic technique and its application in orthopedic surgeries, arthroscopic minimally invasive procedure for ankle fractures has been gradually accepted by orthopedic surgeons [3, 4]. Ankle arthroscopy has the advantages of small trauma, convenient access and high accuracy, provides complete intra-articular visualization of the joint surface and joint space, and allows careful examination of the dynamic stress of the ligaments during the operation [5, 6]. The posterolateral approach is one of the conventional approaches for ankle arthroscopy. Studies have reported that with the posterior approach, the mean distance from the incision, which is made with the patient in the supine position, to the small saphenous vein, the sural nerve, the tibial nerve and the posterior tibial artery can effectively avoid neurovascular injury, so the surgery can be performed successfully [7]. However,

Posterolateral ankle arthroscopy for ankle fractures

few reports have been involved in the therapeutic effect of posterolateral approach to ankle arthroscopy for the treatment of ankle fractures in elderly patients. In order to validate the clinical efficacy of the posterolateral approach to ankle arthroscopy is significantly superior to that of open surgery in the treatment of ankle fractures in elderly patients, from March 2014 to May 2016, we selected a total of 68 elderly patients with ankle fracture as subjects to observe and compare the clinical effects of the posterolateral approach to ankle arthroscopy and conventional open surgery. This study will provide experimental basis and evidence for clinical application of the posterolateral approach to ankle arthroscopy in the treatment of ankle fractures in elderly patients.

Materials and methods

General information

Between March 2014 and May 2016, 68 patients with ankle fractures treated in our hospital were enrolled as subjects and randomly assigned to receive either standard open reduction (the control group, n=34) or posterolateral ankle arthroscopy (the experimental group, n=34). This trial was approved by the ethics committee of the hospital, and all the patients or their relatives provided the informed written consents before surgery.

Inclusion criteria: elderly patients (>60 years old) with ankle fractures affecting the articular surface, MRI revealed ankle fractures with injured articular cartilage and ligaments, but no operative contraindications.

Exclusion criteria: patients associated with such basic diseases as hepatic and renal dysfunction or cardiopulmonary dysfunction, old chronic ankle lesions, those having refused to sign the informed written consents or ineligible for the ethical criteria.

Operation methods

All the patients were treated with continuous epidural anesthesia and did affected limb function exercise at an early stage of post-operation. The patients in the control group underwent conventional ORIF: for medial malleolus fracture, the larger bone fractures were fixed with Kirschner wire and screws of Kirschner wire, the smaller ones were fixed with crossed Kirschner wire or medial tension band wiring;

for lateral malleolus fractures at the ankle joint level, after anatomic reduction, a reconstruction plate or a circular plate were used to fix.

The patients in the experimental group were treated by the posterolateral approach to ankle arthroscopy. The pneumatic tourniquet was used to stop bleeding, and the patient was placed in the supine position under general anesthesia. A posterolateral approach was performed. Saline (30 ml) was injected into the articular cavity for inflation. After creation of the arthroscopic channel, the anatomical relationship among the internal structures including the talus joint, talus neck, lateral sulcus, the medial sulcus, the deltoid ligament, and posterior compartments were inspected under the arthroscope. Meanwhile, the blood clots and synovial edema were debrided. The rough articular surface was cut down for planned treatment. In case of cartilage stripping, stripped cartilages were debrided and taken out, leaving no residual fragments in the articular cavity. If chondral damage was present, vertical bore-hole micro fracturing was used to treat the exposed area of cartilage; for the patients with injured joint ligaments, reconstructive surgery was required. The reduction procedure was performed under the arthroscope to restore the smoothness of the ankle articular surface and normal occlusion of the ankle joint. The fractures were fixed using hollow nails, screws or plates.

Outcome measures

The outcomes of therapeutic effect, operative time, intraoperative bleeding and postoperative recovery time were observed between the two groups. The improvements in the ankle joint functions after surgery were assessed based on the McGuire scoring criteria. The McGuire scoring system for ankle joint covers total scores of 100 points, including the components of pain (50), full range of motion (5), maximum walking distance (20), stair climbing (10), support (5), lameness (5) and walking on uneven road (5). The grading criteria are excellent, ≥ 80 ; good, ≥ 70 but < 80 ; moderate, ≥ 60 but < 70 ; and poor, < 60 . The patient's pain recovery was evaluated using the pain visual analogue scale (VAS). The VAS scoring criteria: pain intensity is expressed on a scale of 0-10 integers: 0 indicates no pain; less than 3, mild pain which is tolerable; 4-6, the pain affects the patient's sleep but still is endurable; 7-10,

Posterolateral ankle arthroscopy for ankle fractures

Table 1. Comparison of the general information between the two groups

Groups	Gender (M/E)	Age (Age)	Onset Time (h)	Injury type (n)	
				Fall	Violence
Experimental group	20/14	65.8 ± 4.6	13.9 ± 9.1	18	16
Control group	18/16	66.5 ± 5.2	14.9 ± 7.5	17	17

Table 2. Comparison of therapeutic effects between the two groups

Group	n	Excellent (n)	Good (n)	Good-excellent	Qualified
Experimental group	34	10	15	73.5%*	91.2%*
Control group	34	5	7	35.3%	70.6%

Note: *P<0.05 for the comparison with the control group.

Table 3. Comparison of operative time, intraoperative bleeding and postoperative recovery time between the two groups

Group	n	Operative time (min)	Intraoperative bleeding (ml)	Postoperative recovery time (d)
Control group	34	74.1 ± 9.2	210.8 ± 54.2	10.9 ± 1.5
Experimental group	34	52.1 ± 9.8*	60.7 ± 14.5*	6.6 ± 1.3*
T		25.78	22.49	30.93
P		0.000	0.000	0.000

Note: *P<0.05 for the comparison with the control group.

the gradually intense pain which is unendurable and affects appetite and sleep of the patient.

Statistical analysis

All the data were analyzed using the SPSS statistical software, version 17.0. The measurement data were expressed as mean ± standard deviation, and the between-group comparison were made by the t-test. The McGuire scores and the VAS scores before and after surgery among the patients in both groups were assessed using the analyses of variance of repeated measurement data and post hoc Bonferroni tests. The between-group differences in qualitative data were compared by the chi-square test. P<0.05 was considered as statistically significant.

Results

Comparison in general data between the two groups

The patients in the experimental group included 20 males and 14 females (mean, 65.8 ± 4.6

years); the period from the onset of fractures to surgery was 6 h-22 h (mean, 13.9 ± 9.1 h); the causes for injuries were falls (n=18) or violence (n=16). By contrast, the patients in the control group included 18 males and 16 females (mean, 66.5 ± 5.2 years); the period from the onset of fractures to surgery was 5 h-21 h (mean, 14.9 ± 7.5 h); and the causes for injuries were falls (n=17) or violence (n=17). There was no significant difference between the two groups in gender, age, time of onset and injury causes (P>0.05, **Table 1**).

Comparison of the therapeutic effects between the two groups

The therapeutic effect of the two groups was determined based on the McGuire scoring system. Among the 34 patients in the experimental group, 10 had excellent effect, 15 had good effect, with a good-excellent rate of 73.5% and a qualified rate of 91.2%; whereas in the control group, 5 had excellent effect, 7 had good effect, with a good-excellent rate of 35.3% and a qualified rate of 70.6%. The differences in the good-excellent rate (P=0.000) and the qualified rate (P=0.000) between the two groups were statistically significant (**Table 2**).

Comparison of the operation time, intraoperative bleeding and postoperative recovery time between the two groups

As compared with the control group, the operation time (52.1 ± 9.8 min), intraoperative bleeding (60.7 ± 14.5 ml) and postoperative recovery time (6.6 ± 1.3 d) of the experimental group were significantly reduced (P=0.000, **Table 3**).

Comparison of the difference in the McGuire scores before and after surgery between the two groups

Compared with those before surgery, the McGuire scores were significantly higher after surgery in both the experimental group and the control group (P=0.008, P=0.016). The improvement in the McGuire scores after sur-

Posterolateral ankle arthroscopy for ankle fractures

Table 4. Comparison of the McGuire score pre-and after surgery between the two groups

Group	n	Before surgery	After surgery	Difference	F	P
Control group	34	48.9 ± 2.8	71.5 ± 3.2 [#]	22.6 ± 2.5	5.951	0.016
Experimental group	34	51.2 ± 2.7	86.5 ± 3.7 [#]	35.3 ± 2.8 [*]	7.538	0.008
T				17.991		
P				0.000		

Note: [#]P<0.05 for the comparison with before surgery; ^{*}P<0.05 for the comparison with the control group.

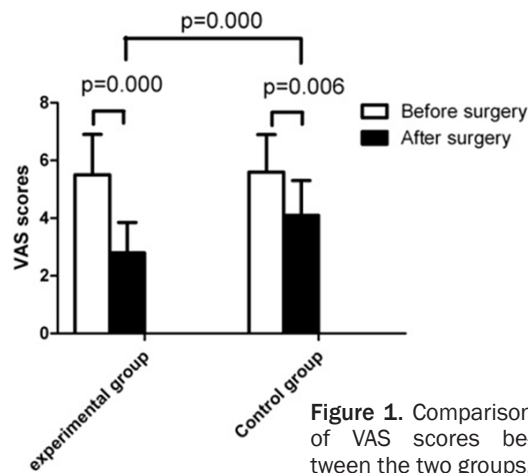


Figure 1. Comparison of VAS scores between the two groups.

gery was significantly greater in the experimental group than in the control group (P=0.000, Table 4).

Comparison of VAS scores between the two groups

The difference in the VAS scores before surgery showed no significant difference between the two groups. For the patients in the control group, the VAS scores were significantly lower after surgery than before surgery (F=2.864, P=0.006). Among the patients in the experimental group, the VAS scores (2.8 ± 1.05) were significantly higher after surgery than before surgery (5.5 ± 1.4) and also higher than those of the patients in the control group (4.1 ± 1.2) (F=80.228, P=0.000; F=41.118, P=0.000), as shown in Figure 1.

Discussion

The incidence of ankle fractures increases with the aging of the population, and the fall injury is the major mechanism for ankle fractures [8, 9]. Ankle fracture is mostly associated with dam-

ages to joint capsule, ligament and cartilage, which may make local lesions complicated and increase the difficulty in treatment [10]. The common symptoms for ankle fractures include hematoma, pain, cyanosis, ecchymosis in the ankle joint and poor walking ability, exerting detrimental influence on

the patients' quality of life [11]. Currently, surgical treatment is the preferred option for the treatment of ankle fractures, and it can achieve anatomical reduction in the fracture site, and restore normal biological alignment, leading to better recovery of joint function after surgery [12, 13]. However, no consensus has been achieved with regard to the surgical protocol of ankle fractures, and the indications for surgery also remain controversial. Studies have demonstrated that open reduction and internal fixation (ORIF) alone for ankle fracture is associated with ineffective management of the damages to ligaments and cartilages on the joint surface, incomplete recovery of the ankle joint structures, and secondary chronic lesions in the ankle joint [14, 15]. Therefore, it is of great significance to select optimal surgical procedures for the treatment of ankle fractures in elderly patients.

Ankle arthroscopy is characterized by smaller trauma, less complications and higher safety, complete intra-articular visualization of the joint interspace and surface, and careful examination of the dynamic stress of the ligament structures during the operation [16, 17]. It is thus evident that, in the setting of ankle fracture in elderly patients, ankle arthroscopy can improve the diagnosis and treatment of the lesions of synovium, cartilage and ligaments, and can effectively avoid violations of soft tissue and neurovascular structures around the ankle joint cavity, achieving better clinical effect than conventional surgical procedures. To validate this point, in the present study, we randomly assigned the enrolled patients to receive standard open reduction (the control group) or ankle arthroscopy with minimally invasive surgery (the experimental group) and then compared the differences between the two groups in the composite outcomes of operation time,

Posterolateral ankle arthroscopy for ankle fractures

intraoperative bleeding and postoperative recovery time. The results showed that the elderly patients with ankle fractures who had undergone ankle arthroscopy with minimally invasive surgery had shorter operation time and postoperative recovery time, and less intraoperative bleeding than those who had undergone standard open reduction, and the differences were statistically significant ($P < 0.05$). It is indicated that strengths of ankle arthroscopy with minimally invasive surgery over standard open reduction are smaller trauma, shorter time and quicker recovery after operation. They are consistent with the results of previous studies [18, 19].

Nowadays, the routine approaches to ankle arthroscopy are anteromedial and posterolateral. As the patient is placed in the supine position, an anteromedial approach brings easier surgery and smaller risks of damages to the surrounding neurovascular structures than a posterolateral one [20]. However, few studies have reported the posterolateral approach to ankle arthroscopy for management of ankle fractures, as mostly are involved in the anteromedial approach. In our trial, the patients in the experimental group received ankle arthroscopy with posterolateral approach, and the incision made strictly based on the anatomical position effectively avoided damages to the surrounding neurovascular structures. The postoperative good-excellent rate (73.5%) and the qualified rate (91.2%) were significantly higher in the experimental group than in the control group, with the clinical efficacy in favor of the experimental group, and the difference was statistically significant. Additionally, the improvements in the primary clinical outcomes including operative time, postoperative recovery time and intraoperative bleeding were significant greater in the experimental group than in the control group. This shows that arthroscopic surgery contributes to simple operation, small trauma, rapid postoperative recovery, but it is partly dependent on the operating skills of the surgeons. In the arthroscopic procedures, the surgeons need to be fully aware of the narrow interspace on the articular surface, closely overlapping nerves and blood vessels and other soft tissues. They should confirm the proper approach, trying not to make damages to important soft tissues. In addition, the cartilage injuries on the tibial articular surface are

required to be treated with proper traction, avoiding inadvertent damage to the rest of the articular surface. Arthroscopy requires the surgeon expert in operation skills, as the planing system should be applied in expanding the operative field in case of extremely narrow joint space. Furthermore, the improvements in the McGuire scores and VAS scores after surgery were significantly greater in the experimental group than in the control group, suggesting that the posterolateral approach to ankle arthroscopy can improve the therapeutic effect of ankle fractures.

In conclusion, the posterolateral approach to ankle arthroscopy is more effective in improving the therapeutic effect of ankle fractures than the conventional open procedures. Ankle arthroscopy allows clear visualization of the injuries in the articular cavity, shorter operation duration, less intraoperative bleeding and faster postoperative recovery, so it is worthy of extensive clinical application. However, there are still some limitations in this trial: a small sample size and the uni-center trial. Additional studies are needed to collect more cases, and prospective, multicenter follow-up controlled trials are required for further demonstration.

Disclosure of conflict of interest

None.

Address correspondence to: Guangming Zhang, Department of Orthopedics and Trauma, Guangzhou First People's Hospital, Guangzhou Medical University, No. 1, Panfu Road, Yuexiu District, Guangzhou 510180, China. Tel: +86-020-8104-8245; Fax: +86-020-81048630; E-mail: guangmingzha2018xm@163.com

References

- [1] Gauthe R, Desseaux A, Rony L, Tarissi N and Dujardin F. Ankle fractures in the elderly: treatment and results in 477 patients. *Orthop Traumatol Surg Res* 2016; 102: S241-244.
- [2] Yeung DE, Jia X, Miller CA and Barker SL. Interventions for treating ankle fractures in children. *Cochrane Database Syst Rev* 2016; 4: Cd010836.
- [3] Gonzalez TA, Macaulay AA, Ehrlichman LK, Drummond R, Mittal V and DiGiovanni CW. Arthroscopically assisted versus standard open reduction and internal fixation techniques for the acute ankle fracture. *Foot Ankle Int* 2016; 37: 554-562.

Posterolateral ankle arthroscopy for ankle fractures

- [4] Chan KB and Lui TH. Role of ankle arthroscopy in management of acute ankle fracture. *Arthroscopy* 2016; 32: 2373-2380.
- [5] Fuchs DJ, Ho BS, LaBelle MW and Kelikian AS. Effect of arthroscopic evaluation of acute ankle fractures on PROMIS intermediate-term functional outcomes. *Foot Ankle Int* 2016; 37: 51-57.
- [6] Chen XZ, Chen Y, Liu CG, Yang H, Xu XD and Lin P. Arthroscopy-assisted surgery for acute ankle fractures: a systematic review. *Arthroscopy* 2015; 31: 2224-2231.
- [7] Song B, Li C, Chen Z, Yang R, Hou J, Tan W and Li W. Combined anterior and dual posterolateral approaches for ankle arthroscopy for posterior and anterior ankle impingement syndrome. *Foot Ankle Int* 2016; 37: 605-610.
- [8] Bugler KE, Clement ND, Duckworth AD, White TO, McQueen MM and Court-Brown CM. Open ankle fractures: who gets them and why? *Arch Orthop Trauma Surg* 2015; 135: 297-303.
- [9] Koval KJ, Lurie J, Zhou W, Sparks MB, Cantu RV, Sporer SM and Weinstein J. Ankle fractures in the elderly: what you get depends on where you live and who you see. *J Orthop Trauma* 2005; 19: 635-639.
- [10] Ovaska MT, Madanat R, Honkamaa M and Makinen TJ. Contemporary demographics and complications of patients treated for open ankle fractures. *Injury* 2015; 46: 1650-1655.
- [11] Park JC and McLaurin TM. Acute syndesmosis injuries associated with ankle fractures: current perspectives in management. *Bull NYU Hosp Jt Dis* 2009; 67: 39-44.
- [12] Strauss EJ and Egol KA. The management of ankle fractures in the elderly. *Injury* 2007; 38 Suppl 3: S2-9.
- [13] Zaghoul A, Haddad B, Barksfield R and Davis B. Early complications of surgery in operative treatment of ankle fractures in those over 60: a review of 186 cases. *Injury* 2014; 45: 780-783.
- [14] Regan DK, Gould S, Manoli A and Egol KA. Outcomes over a decade after surgery for unstable ankle fracture: Functional recovery seen 1-year postoperatively does not decay with time. *J Orthop Trauma* 2016; 30: e236-41.
- [15] White TO, Bugler KE, Appleton P, Will E, McQueen MM and Court-Brown CM. A prospective randomised controlled trial of the fibular nail versus standard open reduction and internal fixation for fixation of ankle fractures in elderly patients. *Bone Joint J* 2016; 98-b: 1248-1252.
- [16] Braunstein M, Baumbach SF, Regauer M, Bocker W and Polzer H. The value of arthroscopy in the treatment of complex ankle fractures- a protocol of a randomised controlled trial. *BMC Musculoskelet Disord* 2016; 17: 210.
- [17] Sherman TI, Casscells N, Rabe J and McGuigan FX. Ankle arthroscopy for ankle fractures. *Arthrosc Tech* 2015; 4: e75-79.
- [18] Manandhar RR, Lakhey S, Panthi S and Rijal KP. Arthroscopically assisted evacuation of brodie's abscess of distal femur. *Cureus* 2017; 9: e959.
- [19] Scholten PE and van Dijk CN. Combined posterior and anterior ankle arthroscopy. *Case Rep Orthop* 2012; 2012: 693124.
- [20] Lijoi F, Lughì M and Baccarani G. Posterior arthroscopic approach to the ankle: an anatomic study. *Arthroscopy* 2003; 19: 62-67.