

Spotlight on Clinical Response

***p53* therapy in a patient with Li-Fraumeni syndrome**

Neil Senzer,^{1,2} John Nemunaitis,^{1,2}
 Michael Nemunaitis,^{1,2} Jeffrey Lamont,²
 Martin Gore,³ Hani Gabra,⁴ Rosalind Eeles,⁵
 Nayanta Sodha,³ Frank J. Lynch,⁶
 Louis A. Zumstein,⁷ Kerstin B. Menander,⁷
 Robert E. Sobol,⁷ and Sunil Chada⁷

¹Mary Crowley Medical Research Center; ²Sammons Cancer Center, Baylor University Medical Center, Dallas, Texas; ³The Royal Marsden Hospital NHS Foundation Trust; ⁴Imperial College London Hammersmith Campus, London, United Kingdom; ⁵Institute of Cancer Research, Sutton, United Kingdom; ⁶Qualtek, Inc., Newtown, Pennsylvania; and ⁷Introgen Therapeutics, Inc., Houston, Texas

Abstract

Li-Fraumeni syndrome is an autosomal dominant disorder that greatly increases the risk of developing multiple types of cancer. The majority of Li-Fraumeni syndrome families contain germ-line mutations in the *p53* tumor suppressor gene. We describe treatment of a refractory, progressive Li-Fraumeni syndrome embryonal carcinoma with a *p53* therapy (Advexin) targeted to the underlying molecular defect of this syndrome. *p53* treatment resulted in complete and durable remission of the injected lesion by fluorodeoxyglucose-positron emission tomography scans with improvement of tumor-related symptoms. With respect to molecular markers, the patient's tumor had abnormal *p53* and expressed coxsackie adenovirus receptors with a low HDM2 and *bcl-2* profile conducive for adenoviral *p53* activity. *p53* treatment resulted in the induction of cell cycle arrest and apoptosis documented by *p21* and cleaved caspase-3 detection. Increased adenoviral antibody titers after repeated therapy did not inhibit adenoviral *p53* activity or result in pathologic sequelae. Relationships between these clinical, radiographic, and

molecular markers may prove useful in guiding future application of *p53* tumor suppressor therapy. [Mol Cancer Ther 2007;6(5):1478–82]

Introduction

Li-Fraumeni syndrome is an inherited genetic disorder characterized by familial clustering of multiple malignancies predominantly including sarcomas, breast cancers, brain tumors, and other diverse neoplasms (1–3). In this syndrome, patients often develop multiple primary cancers typically with initial occurrence at a young age. The genetic basis of this syndrome is a germ-line mutation in the *p53* gene (2, 4). In addition to pathogenesis, defects in *p53*-mediated apoptotic pathways contribute to the resistance of these tumors to conventional treatment. These tumors invariably become refractory to standard therapies and result in early death (2, 3). Hence, treatment of Li-Fraumeni tumors with *p53* gene transfer represents a novel, prototypical targeted cancer therapy for these neoplasms. Somatic mutations in *p53* occur in the majority of sporadic, nonfamilial tumors (5). The following report describes the treatment of a Li-Fraumeni patient with Advexin adenoviral *p53* gene therapy and the relationships between treatment response, radiographic findings, and molecular markers associated with *p53* mechanisms of action.

Materials and Methods

Patient History, Family History, and *p53* Germ-line Mutation

The patient is a 25-year-old woman from a Li-Fraumeni family (Fig. 1). The paternal grandfather died of cancer at the age of 38 years. The patient's father had two siblings (of four) who died of sarcoma and uterine/cervical cancer at ages 24 and 34 years, respectively. The patient's father died of breast cancer at age 52 years. Of the patient's three siblings, one died at age 12 years of sarcoma and another was diagnosed with breast cancer at age 31 years. The patient presented at age 21 years with abdominal pain, anorexia, and vomiting leading to the diagnosis of granulosa cell cancer (inhibin positive). Analyses of the *BRCA1/BRCA2* genes and immunohistochemistry for the mismatch repair genes were uninformative, indicating that these genes are unlikely to be involved. *p53* sequencing of DNA obtained from peripheral blood revealed the presence of a heterozygous germ-line *p53* abnormality with a nucleotide 151ΔG frameshift mutation (c.151delG; p.Glu51AsnX71) in exon 4 resulting in a truncated protein containing only 51 amino acids of wild-type *p53* protein.

Received 2/23/07; accepted 3/30/07.

Grant support: Introgen Therapeutics, Inc.

The costs of publication of this article were defrayed in part by the payment of page charges. This article must therefore be hereby marked advertisement in accordance with 18 U.S.C. Section 1734 solely to indicate this fact.

Note: R.E. Sobol and S. Chada contributed equally to this work.

Requests for reprints: John Nemunaitis, Mary Crowley Medical Research Center, 60th Floor, 1717 Main Street, Dallas, TX 75201. Phone: 214-658-1964; Fax: 214-658-1992. E-mail: jnemunaitis@mcmrc.com
 Copyright © 2007 American Association for Cancer Research.

doi:10.1158/1535-7163.MCT-07-0125

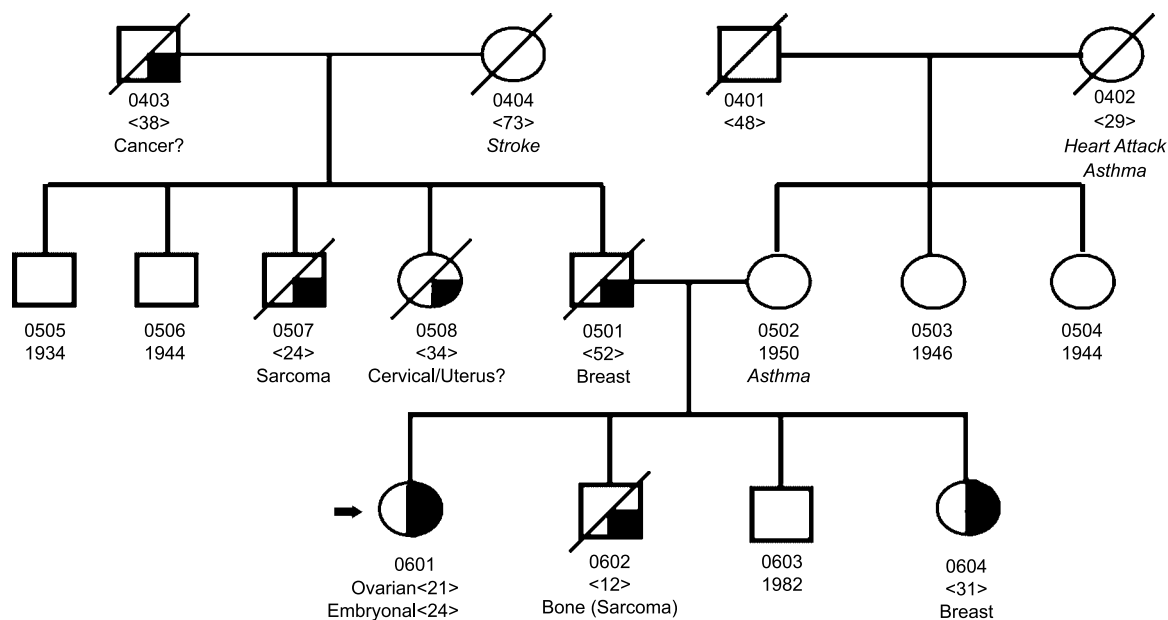


Figure 1. Family history of the Li-Fraumeni patient. □, male; ○, female. Shaded symbols indicate cancer; cross-hatch indicates deceased members; <number> indicates age at diagnosis or death; tumor type is indicated. The Li-Fraumeni syndrome patient (no. 0601) described in this report is indicated by the arrow.

The patient was initially treated with oophorectomy followed by five cycles of bleomycin, cisplatin, and vinblastine. She subsequently developed embryonal carcinoma of the vagina (inhibin negative) 2 years later and was treated with cisplatin, etoposide, and ifosfamide initially and then switched from ifosfamide to Taxol after development of encephalopathy. She experienced progressive disease with bone invasion after three cycles of treatment and received pelvic radiotherapy (45 Gy) and whole brain radiation on development of central nervous system metastases.

The patient's pelvic disease continued to progress resulting in development of lower extremity edema and pain. Other disease sites (adrenal, brain, and mediastinum) were nonsymptomatic. Because she had exhausted all conventional chemotherapy, radiation, and surgical options, she was referred for experimental treatment with Advexin p53 therapy under a single-patient (compassionate) use protocol approved by the Food and Drug Administration and the local Institutional Review Board.

Evaluation of Molecular Markers

Immunohistochemistry was done to evaluate pretreatment and posttreatment expression of molecular markers associated with p53 function using an automated immunostainer (TechMate 500, Ventana Medical Systems) as described (6). Cell cycle arrest and proliferation were evaluated by antibodies specific for p21 (MS-230, Lab Vision) and Ki-67 (Mib-1, Dako). Markers relevant to the induction of apoptosis were detected by antibodies to cleaved caspase-3 (Cell Signaling) and terminal deoxynucleotidyl transferase-mediated dUTP nick end labeling staining using the Frag EL kit (QIA33) from EMD Biosciences. Negative regulators of p53 activity, HDM2

(clone 1F2, EMD Biosciences), and bcl-2 (clone 124, Dako) were also evaluated. Expression of the coxsackie adenovirus receptor was also determined (CAR, Santa Cruz Biotechnology). Endogenous mutated p53 expression was detected with an antibody specific for the p53 NH₂ terminus (DO7, Lab Vision) whereas expression of wild-type p53 delivered by Advexin was determined with an antibody specific for the COOH terminus (ICA.9, Lab Vision) that was not present in the mutated germ-line p53 gene sequence. Photo images were taken using a Dage video camera on an Olympus BX60 microscope using a 40× or 60× objective lens.

Results and Discussion

The patient had three pelvic tumors of which only one was accessible for intraliesional injection. The patient's pelvic neoplasm, contiguous with the vaginal primary, was treated by intratumoral injection of Advexin. Advexin is a replication-defective adenoviral vector containing the wild-type human p53 cDNA under the control of the cytomegalovirus immediate-early promoter (5). The patient received intratumoral Advexin at a dose of 2×10^{12} viral particles per injection twice weekly on days 2 and 4 of week 1, then every 28 days for two additional treatments. Consistent with previous reports, Advexin p53 therapy was well tolerated (5, 7, 8) and side effects were limited to grade 1 pain at the injection site and transient fever. There were no significant differences related to Advexin treatment between pretreatment and posttreatment complete blood counts, serum chemistries, or urinalyses. Needle penetration resistance changed from firm to soft after two injections, concomitant with reduction in edema and pain.

A fusion fluorodeoxyglucose (FDG)-positron emission tomography (PET)/computed tomography (CT) scan done at 2 months, following four intratumoral injections of Advexin therapy, showed complete resolution of 2,3-FDG uptake in the treated tumor compared with the pretreatment evaluation (Fig. 2). The standardized uptake value of the injected lesion 2 months after Advexin administration was 1.1 compared with a baseline value of 5.3, whereas CT scans of the lesion showed stable disease for >4 months. FDG-PET/CT of a nontreated pelvic lesion in the same transverse plane showed progression with an increased standardized uptake value from 5.0 to 11.5 (Fig. 2). A repeat fusion FDG-PET/CT done 4 months later revealed continued complete remission by FDG uptake in the treated tumor with further progression in the untreated lesions. These observations are consistent with the clinical trial results of other agents that mediate antitumor effects through cell cycle arrest and apoptosis induction wherein PET scans indicated significant tumor responses when CT scans showed stable disease (9, 10). In multiple studies wherein the two methods were compared to evaluate treatment response, FDG-PET/CT scans were shown to be superior and provided better correlation with clinical outcomes than CT scans (10, 11). An important implication of these observations is that p53 therapy may be best evaluated by fusion FDG-PET/CT scans and that CT findings of durable stable disease may reflect meaningful therapeutic activity. In this regard, a CT angiogram done 5 months after Advexin treatment showed that the treated lesion was avascular, consistent with the complete metabolic response by fusion PET/CT scan and confirmed progression in the nontreated lesion that increased in size and vascularity.

The adenoviral antibody titer was 1:32 before treatment and increased to 1:2,048 on day 28 after four adenoviral p53 treatments. Consistent with previous findings, the antibody response did not correlate with any pathologic sequelae and did not seem to inhibit Advexin activity (8).

Successful treatment of patients with the Li-Fraumeni syndrome is problematic due to the frequency of multiple malignancies that share a common p53 genetic defect fundamental to cancer progression and the development of treatment resistance. A major paradox in the treatment of Li-Fraumeni syndrome tumors is that conventional cytotoxic

therapies (chemotherapy and radiotherapy) that induce DNA damage also contribute to the high incidence of treatment related secondary malignancies in these patients (3, 12–14). It is likely that the p53 abnormalities in Li-Fraumeni syndrome tissues mediate defects in repair of DNA damage following conventional cancer treatments, thus promoting mutations that result in secondary tumor development (12–14). Hence, novel, nongenotoxic therapies for Li-Fraumeni syndrome tumors are clearly needed. Adenoviral p53 is a targeted molecular therapy that addresses the fundamental genetic defect of Li-Fraumeni syndrome and does not induce DNA damage in normal tissues (5, 15).

As a prototypical tumor suppressor gene, p53 is a transcription factor that controls several biological processes important for tumor growth control including regulation of the cell cycle, angiogenesis, and apoptosis (16, 17). This investigation identified the correlation of molecular markers of p53 tumor suppression with radiographic findings and treatment response and extended the results of previous clinical studies of p53 tumor therapy.

Molecular markers of p53 tumor suppression were evaluated by immunohistochemistry using samples from the Li-Fraumeni syndrome embryonal tumor taken before treatment and 7 days after Advexin injection. Immunostaining with an antibody directed against the NH₂ terminus of p53 (amino acids 37–45) present in the mutated p53 germline sequence showed constitutive mutant p53 protein expression in the nuclei of the patient's normal skin and Li-Fraumeni syndrome tumor cells (Fig. 3A). These observations are consistent with previous immunohistochemical studies showing overexpression of abnormal p53 compared with normal tissues wherein p53 is tightly regulated and undetectable by standard immunohistochemical assays (18). As expected, tumor levels of wild-type p53 increased after adenoviral p53 treatment, reflecting exogenous delivery of high levels of therapeutic wild-type p53 (Fig. 3A). The presence of increased Advexin-derived p53 was confirmed with an antibody directed to the COOH terminus of p53. This region (amino acids 388–393) is not present in the truncated mutant Li-Fraumeni syndrome p53.

The induction of cell cycle arrest and apoptosis is an important mechanism of p53-mediated tumor suppression in model systems, and activation of these pathways was

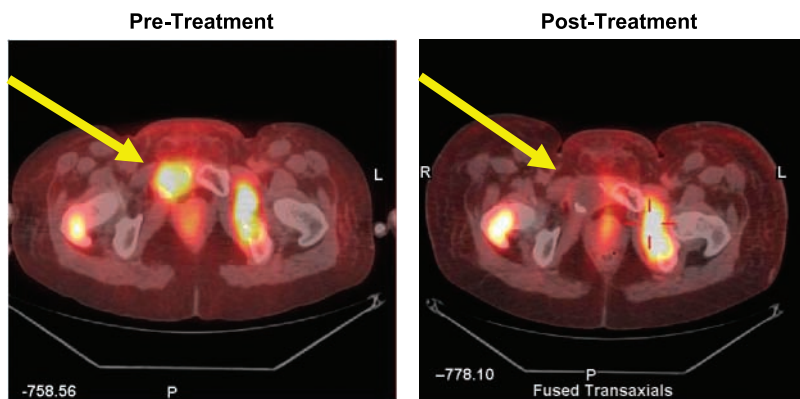
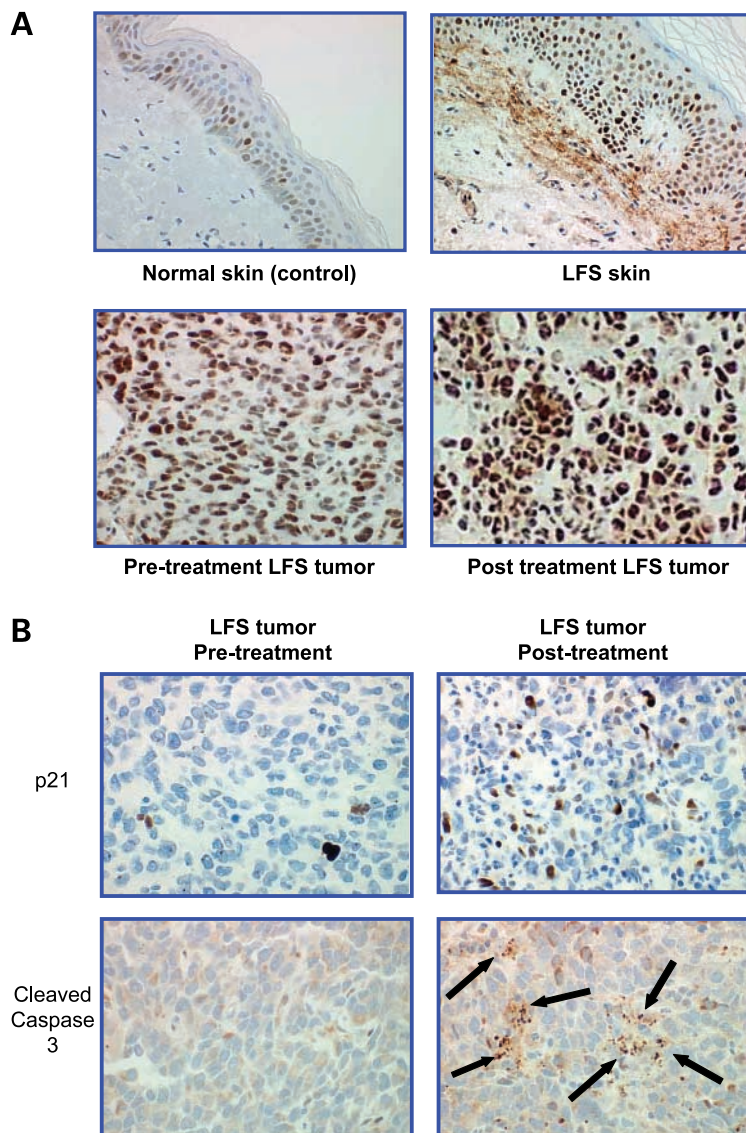


Figure 2. Fusion PET/CT scan of the treated pelvic tumor (arrow) before (left) and after four intratumoral injections of Advexin depicting complete resolution of 2,3-FDG uptake at 2 mo (right) and progression of the untreated lesion (cross-hairs).

Figure 3. A, high-level p53 expression in Li-Fraumeni patient. Immunohistochemistry with antibody directed to NH₂ terminus (epitope 37–45) of p53 shows high-level expression in both Li-Fraumeni syndrome (LFS) normal skin and pretreatment tumor (embryonal lesion) compared with the normal skin control. Levels of p53 in the posttreatment tumor were increased as expected following adenoviral p53 therapy, which was indicated by the increased intensity of nuclear staining. The presence of increased treatment-derived normal p53 was also confirmed with an antibody directed to the COOH terminus region (amino acids 388–393) that is not present in the truncated mutant Li-Fraumeni syndrome p53. Images were taken with $\times 40$ objective lens. **B**, activation of p53 molecular markers in Li-Fraumeni patient tumor. Li-Fraumeni syndrome embryonal tumor biopsies before and after p53 treatment indicating increased posttreatment (day 7) expression of the cell cycle arrest molecular marker p21 and of the apoptosis marker cleaved caspase-3. Images were taken with $60\times$ objective lens.



shown by the expression of molecular markers in the patient's tumor. p21 is a critical mediator of cell cycle arrest (19) and expression of this marker was increased from $<1\%$ positively stained cells in the pretreatment tumor to 20% positive staining after Advexin treatment (Fig. 3B). Activation of apoptosis was shown by the detection of increased cleaved caspase-3 in posttreatment tumor samples with 20% positivity after Advexin treatment compared with $<5\%$ staining before therapy (Fig. 3B). These results were confirmed by terminal deoxynucleotidyl transferase-mediated dUTP nick end labeling staining that detects fragmented DNA, which is another marker of apoptosis. Staining of Advexin-derived p53 corresponded to regions of positive staining for p21 and apoptosis markers in the posttreatment samples. Consistent with the induction of cell cycle arrest and increased apoptosis, staining for the cellular proliferation marker Ki-67 was decreased from 55% in pretreatment tumor samples to 35% after Advexin

treatment. Staining of the antiapoptotic marker bcl-2 was low in both pretreatment and posttreatment samples and decreased from 20% to 10% after Advexin treatment. Overall, these molecular analyses indicate that the p53 signaling pathway was intact in the Li-Fraumeni syndrome tumor and that p53 gene transfer resulted in the induction of cell cycle arrest and apoptosis.

Another mechanism of p53 tumor suppression shown in tumor models is antiangiogenesis. p53 has been shown to down-regulate the expression of vascular endothelial growth factor and to activate the transcription of secreted inhibitors of angiogenesis (20, 21). The results of the posttreatment CT angiogram showing avascularity of the treated tumor and increased vascularity of a nontreated lesion are consistent with this mechanism of p53 action.

Additional molecular markers associated with the regulation of p53 activity were also evaluated. HDM2 is a negative regulator of p53 activity whereas bcl-2 is an

inhibitor of p53-mediated apoptosis (17). The Li-Fraumeni syndrome tumor expressed low levels of HDM2 and bcl-2 (10–20% positivity), representing a marker profile conducive to p53 activity. Additional studies will be required to determine whether these markers are predictive of p53 treatment response in other patients.

Another interesting finding was the increased expression of coxsackie adenovirus receptors after p53 treatment. This observation suggests that adenoviral p53 may enhance its own activity by up-regulating the receptor that mediates its cellular binding and entry. Corroboration of this phenomenon and further evaluation in a larger number of patients may optimize future adenoviral p53 treatment schedules to coincide with maximum coxsackie adenovirus receptor expression.

In summary, our findings show important relationships between treatment response, radiographic findings, and molecular markers of p53 tumor suppression. Improvement of the patient's tumor-related symptoms after adenoviral p53 treatment was associated with a durable complete response by PET scan and durable stable disease by CT scan. This important result implies that, like other agents which induce cell cycle arrest and apoptosis, p53 treatment responses may be better monitored by fusion PET/CT scans rather than by CT scans alone (9–11). The absence of tumor vascularity in treated versus nontreated tumors by CT angiography was consistent with the induction of p53-mediated antiangiogenic mechanisms. Molecular markers of p53 tumor suppression documented the induction of cell cycle arrest and apoptosis by p21 and cleaved caspase-3 detection, respectively, in posttreatment tumor samples. In regard to regulators of p53 activity, the patient's tumor expressed a low HDM2 and bcl-2 marker profile predictive of p53 activity. In conclusion, our findings indicate that evaluation of additional Li-Fraumeni syndrome tumors with adenoviral p53 treatment is warranted. Corroboration of the identified relationships between treatment response, radiology findings, and molecular markers identified in this study should be assessed in a larger number of patients to guide further development of p53 therapy for both familial and nonfamilial cancers with p53 abnormalities.

Acknowledgments

We thank Drs. Guillermina Lozano, Louise Strong, and Martha French for their review of the manuscript and Wesley Gage and Dr. Hector Battifora for assistance with the immunohistochemistry studies.

References

- Li FP, Fraumeni JF, Jr. Soft-tissue sarcomas, breast cancer, and other neoplasms. A familial syndrome? *Ann Intern Med* 1969;71:747–52.
- Malkin D, Li FP, Strong LC, et al. Germ line p53 mutations in a familial syndrome of breast cancer, sarcomas, and other neoplasms. *Science* 1990;250:1233–8.
- Hisada M, Garber JE, Fung CY, Fraumeni JF, Jr., Li FP. Multiple primary cancers in families with Li-Fraumeni syndrome. *J Natl Cancer Inst* 1998;90:606–11.
- Varley JM, McGown G, Thorncroft M, et al. Germ-line mutations of TP53 in Li-Fraumeni families: an extended study of 39 families. *Cancer Res* 1997;57:3245–52.
- Roth JA. Adenovirus p53 gene therapy. *Expert Opin Biol Ther* 2006;6:55–61.
- Ladner RD, Lynch FJ, Groshen S, et al. dUTP nucleotidohydrolase isoform expression in normal and neoplastic tissues: association with survival and response to 5-fluorouracil in colorectal cancer. *Cancer Res* 2000;60:3493–503.
- Swisher SG, Roth JA, Komaki R, et al. Induction of p53-regulated genes and tumor regression in lung cancer patients after intratumoral delivery of adenoviral p53 (INGN 201) and radiation therapy. *Clin Cancer Res* 2003;9:93–101.
- Nemunaitis J, Swisher SG, Timmons T, et al. Adenovirus-mediated p53 gene transfer in sequence with cisplatin to tumors of patients with non-small-cell lung cancer. *J Clin Oncol* 2000;18:609–22.
- Goldstein D, Tan BS, Rossleigh M, Haindl W, Walker B, Dixon J. Gastrointestinal stromal tumours: correlation of ¹⁸F-FDG gamma camera-based coincidence positron emission tomography with CT for the assessment of treatment response—an AGITG study. *Oncology* 2005;69:326–32.
- Kelloff GJ, Hoffman JM, Johnson B, et al. Progress and promise of FDG-PET imaging for cancer patient management and oncologic drug development. *Clin Cancer Res* 2005;11:2785–808.
- Vansteenkiste J, Fischer BM, Doooms C, Mortensen J. Positron-emission tomography in prognostic and therapeutic assessment of lung cancer: systematic review. *Lancet Oncol* 2004;5:531–40.
- Nutting C, Camplejohn RS, Gilchrist R, et al. A patient with 17 primary tumours and a germ line mutation in TP53: tumour induction by adjuvant therapy? *Clin Oncol (R Coll Radiol)* 2000;12:300–4.
- Limacher JM, Frebourg T, Natarajan-Ame S, Bergerat JP. Two meta-chronous tumors in the radiotherapy fields of a patient with Li-Fraumeni syndrome. *Int J Cancer* 2001;96:238–42.
- Hwang SJ, Lozano G, Amos CI, Strong LC. Germline p53 mutations in a cohort with childhood sarcoma: sex differences in cancer risk. *Am J Hum Genet* 2003;72:975–83.
- Frederickson RM, Carter BJ, Pilaro AM. Nonclinical toxicology in support of licensure of gene therapies. Arlington, VA, USA, March 13-14, 2003. *Mol Ther* 2003;8:8–10.
- Lane DP. Cancer. p53, guardian of the genome. *Nature* 1992;358:15–6.
- Lozano G, Zambetti GP. What have animal models taught us about the p53 pathway? *J Pathol* 2005;205:206–20.
- Hall PA, Lane DP. p53 in tumour pathology: can we trust immunohistochemistry?—Revisited! *J Pathol* 1994;172:1–4.
- El-Deiry WS, Tokino T, Velculescu VE, et al. WAF1, a potential mediator of the p53 tumor suppression. *Cell* 1993;75:817–25.
- Dameron K, Vopert OV, Tainsky MA, et al. Control of angiogenesis in fibroblast by p53 regulation of thrombospondin-1. *Science* 1994;265:1582–4.
- Nishizaki M, Fujiwara T, Tanida T, et al. Recombinant adenovirus expressing wild-type p53 is antiangiogenic: a proposed mechanism for bystander effect. *Clin Cancer Res* 1999;5:1015–23.

Molecular Cancer Therapeutics

p53 therapy in a patient with Li-Fraumeni syndrome

Neil Senzer, John Nemunaitis, Michael Nemunaitis, et al.

Mol Cancer Ther 2007;6:1478-1482. Published OnlineFirst May 4, 2007.

Updated version Access the most recent version of this article at:
doi:[10.1158/1535-7163.MCT-07-0125](https://doi.org/10.1158/1535-7163.MCT-07-0125)

Cited articles This article cites 21 articles, 9 of which you can access for free at:
<http://mct.aacrjournals.org/content/6/5/1478.full#ref-list-1>

Citing articles This article has been cited by 7 HighWire-hosted articles. Access the articles at:
<http://mct.aacrjournals.org/content/6/5/1478.full#related-urls>

E-mail alerts [Sign up to receive free email-alerts](#) related to this article or journal.

Reprints and Subscriptions To order reprints of this article or to subscribe to the journal, contact the AACR Publications Department at pubs@aacr.org.

Permissions To request permission to re-use all or part of this article, contact the AACR Publications Department at permissions@aacr.org.