

Duplex Kidney – An Anatomical and Clinical Insight

*Kate. Deepali . R¹, Shinde. Reshma.B²

Associate Professor¹, Assistant Professor²

Department of Anatomy, B. J. Govt. Medical College and Sassoon Hospitals, Pune, Maharashtra, India.

Abstract: The present report describes a rare case of isolated bifid ureter with duplex kidney. The possible embryological and genetic grounds for the formation of this anomaly are considered. Duplication of the ureter in adults is often symptomless, however urinary tract infections, pyelonephritis occur more commonly due to vesicoureteric or ureteroureteric reflex. They are often seat of calculi formation and ureterocele that can impede drainage.

Keywords: Bifid Ureter, Metanephros, Duplex kidney, Pelvicalyceal system.

I. Introduction

The human ureters are a pair of muscular tubes that transport urine from renal pelvis to the posterior surface to the urinary bladder. Duplications of the ureter represent one of the most common anomalies of the urinary tract, they may be complete or incomplete and can be associated with functioning renal moieties with orifices that open into the bladder. Duplications are often completely asymptomatic and often come to light only in the course of investigations for other reasons. Clinical problems are the result of obstruction, reflux, or ectopic openings, giving rise to hydronephrosis, infection and incontinence

II. Material And Methods

A rare case of unilateral bifid ureter was detected on the right side in a male cadaver aged 65 years during routine cadaveric dissection in the Department of Anatomy, B. J. Govt. Medical College. Coronal section of the kidney was taken and pelvicalyceal system was studied. Any other associated anomalies were looked for and the specimen was photographed.

III. Case Report

In the present case, duplex kidney with unilateral incomplete bifid ureter was encountered on the right side in male cadaver. At the commencement two separate limbs of the ureter could be distinguished. The two limbs coursed down over posterior wall and later united. The upper limb measured 7.5 cm while lower limb measured 6 cm from the hilum to the point of junction, beyond this point the ureter was seen crossing the pelvic brim and piercing the urinary bladder wall by single orifice and measured 17.5cm. This represents a partial duplication of the ureter (Fig-1and 2)

Coronal section of kidney (Fig-3) revealed duplication of pelvicalyceal system. Three major calyces drained into upper and lower pelvis each continued into upper and lower limbs of ureter respectively. In the upper set of pelvicalyceal system; upper major calyx divided into three minor calyces while middle and inferior major calyx turned into minor calyx each. While in the lower pelvicalyceal system upper and middle major calyx branched into two minor calyces each while lower major calyx extended into minor calyx. Duplication of pelvicalyceal system was symmetrical. Interior also revealed a single cyst close to lower pole Single normal ureter measuring 23.5 cm from hilum to bladder wall was noted on left side.

Blood vessels: Renal artery about 5 cm prior to its entrance into hilum divided into larger anterior division and smaller posterior division. Anterior division further split into four branches two ascended in front of renal vein and two behind renal vein Thus the anterior division branches can be nomenclature as; upper anterior, lower anterior, upper posterior and lower posterior. Upper set of branches accompanied the upper limb of ureter while lower set of arteries coursed with the lower limb of ureter (Fig-4) the smaller undivided posterior division of renal artery was in proximation to upper limb of ureter and gave a twig to suprarenal gland at its commencement.

Renal vein- Single large renal vein was formed by fusion of two tributaries at the hilum which accompanied the two limbs of the ureter.

Arrangement of structures at hilum: Anterior to posterior (Fig-5)

- Upper and lower anterior branches of anterior divisions of renal artery
- Two tributaries of renal vein
- Upper and lower posterior branches of anterior division of renal artery.

- Most posterior- from above downwards- Posterior undivided division of renal artery; upper limb of ureter, lower limb of ureter.

The surrounding pelvic and abdominal structures appeared to be morphological normal.

IV. Figures

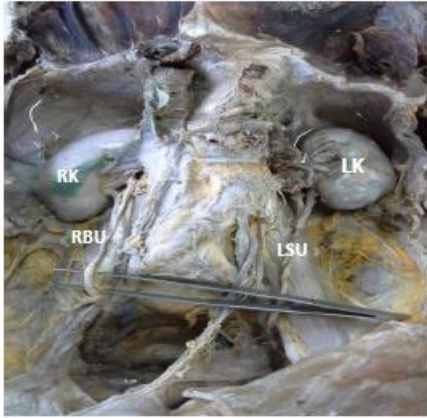


Figure -1
Anterior view of Kidneys in situ:
Right Kidney (RK) with incomplete Bifid Ureter (RBU), Left Kidney (LK) with single normal ureter (LSU)

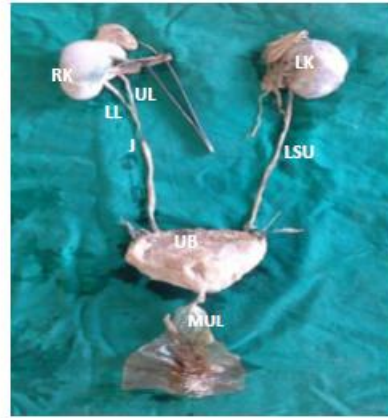


Figure -2
Showing more clear view of bifid ureter:
RK-right kidney, UL-upper limb, LL-lower limb, J-Junction, LK- Left Kidney, LSU-single left ureter, UB-urinary bladder, MUL-median umbilical Ligament

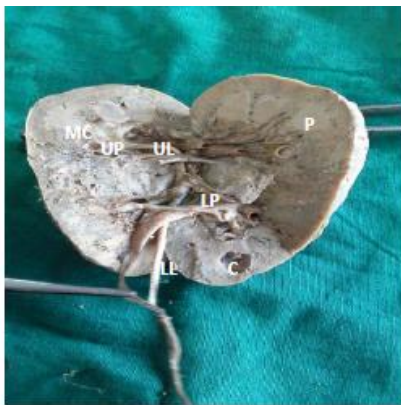

Figure-3
Coronal section of Right Kidney showing Duplex pelvicalceal system: UL-upper limb, UP-upper pelvis, MC-major calyx, LL-lower limb, LP-lower pelvis, P-pyramid, C-cyst

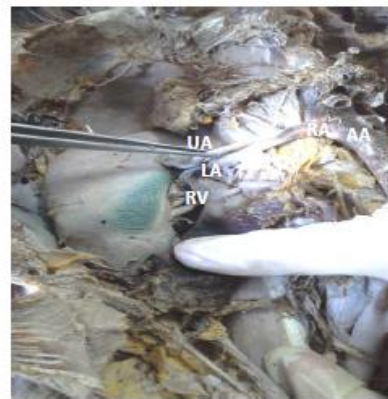

Figure-4
Structures at Right hilum-Anterior view:
AA-Abdominal aorta, RA-Renal artery dividing into Upper Anterior (UA) branch and Lower Anterior (LA)branch, Renal vein



Figure -5

Figure-5

Structures at Right hilum-Posterior view:

PD - Posterior division of renal artery

UP - upper posterior branch of anterior division of the renal artery.

LP - lower posterior branch of anterior division of renal artery

UL-upper limb of ureter, LL- lower limb of ureter.

V. Discussion

Embryological and Genetic basis

A duplex kidney or duplicated system describes a renal unit in which the kidney has two pelvicalyceal systems. It may include a kidney with single or bifid ureters or two ureters that drain separately into the bladder. The kidney is formed when the ureteric bud, arising from the mesonephric duct, meets the metanephros, and by a process of reciprocal induction brings about the formation of the kidney. The distal part of the ureteric bud eventually incorporates into the bladder to form the trigone. At the cranial end branching of the ureteric bud gives rise to the ureter, renal pelvis, calyces and collecting ducts. Premature branching of the ureteric bud results in an incomplete duplex with ureters that meet before the bladder, or a bifid renal pelvis. If more than one bud develops and migrates to the metanephros a duplex kidney with two separate ureters forms¹ When the buds are close to each other, the ureteric orifices are in the bladder in the normal position. When the buds are widely separated, the orifices may be ectopic.

Genes involved in the differentiation of the kidney are WT1 which is expressed by the mesenchyme enables the metanephric tissue to respond to induction by ureteric bud. GDNF and HGF produced by the mesenchyme interact with the RET and MET receptors in the ureteric bud to stimulate growth of the bud and maintain interactions. WNT9B and WNT6 secreted by branches of ureteric bud epithelium causes up regulation of PAX2 and WNT4 in the surrounding mesenchyme. In turn these genes cause the mesenchyme to epithelialize (PAX2) and to form tubules (WNT4) Mutations in the WNT genes may lead to variations in the differentiation of urinary tract.²

Duplicated collecting systems are kidneys with two pelvicalyceal systems, according to the nomenclature established by the committee on terminology, Nomenclature, and Classification of the Section on Urology of the American Academy of Pediatrics, these may be subdivided into partial or complete³ bifid ureters fall into the first category, and may be defined as duplicated systems where two proximal branches drain the same pelvis, but join together distally to form one common ureteric branch prior to emptying into the bladder. However, complete duplicated systems are those where two ureters arise from the same kidney and drain separately into the bladder. Based on data published by Dahnert et al using urograms, partially duplicated systems are three times more common than complete ones.⁴ Similar findings were obtained by Prakash and colleagues in a recent study involving the use of intravenous pyelograms in 50 cadavers. Partially duplicated systems were found in three subjects, whereas complete duplication was present in one subject.⁵ Siomou et al found that duplicated collecting systems are two times more common in women compared with men. In their study on population of 774 children aged below 6 years with a history of urinary tract infections confirmed this. Approximately 11% of girls in the study were found to have duplicated systems compared with 5% of boys. In addition, of the 63 children with duplicated systems, 19% had them bilaterally.⁶ These results are comparable with those obtained by Whitaker and Danks who found unilateral duplication to be six times more common than bilateral duplication. It was also found that there was a one in eight possibility that a child with duplicated ureters would have a parent or sibling who was similarly affected. The investigation of families of children with a duplex urinary tract, suggested that the inheritance of this anomaly was by an autosomal dominant gene⁷ J. D. Atwell has reported total of 21 cases of Bifid pelvicalyceal system and 11 cases of double and/or system bifid ureters among 101 relatives of index patients when investigated with intravenous pyelography⁸

The most common complication of a duplicated collecting system is reflux. The exact nature depends on the type of system involved. Complete systems are usually associated with vesicoureteric reflux. Bisset and Strife found that the incidence of reflux associated with complete duplicated systems was sixty nine percent⁹ which is comparable with that brought out by Fehrenbaker and colleagues of seventy two percent¹⁰ The lower pole was

much more commonly affected. On the other hand, reflux associated with partially duplicated systems tends to be ureteroureteric. The incidence of reflux found by Bisset and Strife in partially duplicated systems (22%) was similar to that found in individuals with non duplicated systems⁹

VI. Conclusion

The anatomical variations and anomalies of the renal collecting system should be considered by clinicians and surgeons; though duplex kidneys are clinically silent may be associated with ureterocele, ectopic ureter insertion or vesicoureteric reflux posing to various complications

Acknowledgement

Authors acknowledge the immense help received from the scholars whose articles are cited and included in references of this manuscript.

Conflict of Interest: Authors declare that we have no competing interests

References

- [1]. Keith L. Moore, T.V.N Persaud. *The Developing Human: Clinically Oriented Embryology*, 6th ed. Saunders 1998
- [2]. Langman, T.W.Sadler. *Medical Embryology*, 11th ed. Lippincott Williams & Wilkins; 2009
- [3]. Glassberg KI, Braren V, Duckett JW, et al. Suggested terminology for duplex systems, ectopic ureters and ureteroceles. *J Urol*. 1984;132:1153–1154
- [4]. Dahnert W. *Radiology Review Manual*. 6th ed. Philadelphia: Lippincott Williams & Wilkins; 2007.
- [5]. Prakash RT, Venkatiah J, Bhardwaj AK et al. Double ureter and duplex system: a cadaver and radiological study. *J Urol*. 2011;8:145–148.
- [6]. Siomou E, Papadopoulou F, Kollios KD, et al. Duplex collecting system diagnosed during the first 6 years of life after a first urinary tract infection: a study of 63 children. *J Urol*. 2006; 175:678–681.
- [7]. Whitaker J, Danks DM. A study of the inheritance of duplication of the kidneys and ureters. *J Urol*. 1966;95:176–178.
- [8]. J. D. Atwell, P. L. Cook, C. J. Howell et al , Familial incidence of bifid and double ureters *Archives of Disease in Childhood*, 1974, 49, 390.
- [9]. Bisset GS 3rd, Strife JL. The duplex collecting system in girls with urinary tract infection: prevalence and significance. *AJR Am J Roentgenol*. 1987; 148:497–500.
- [10]. Fehrenbaker LG, Kelalis PP, Stickler GB. Vesicoureteral reflux and ureteral duplication in children. *J Urol* 1972; 107(5):862-864.