

## MINI-REVIEW

# Current Progress in the Treatment of Metaplastic Breast Carcinoma

Qing Hu<sup>1</sup>, Wei-Xian Chen<sup>2</sup>, Shan-Liang Zhong<sup>3</sup>, Jian Li<sup>2</sup>, Zhou Luo<sup>2</sup>, Jin-Hai Tang<sup>2\*</sup>, Jian-Hua Zhao<sup>3\*</sup>

### Abstract

Metaplastic breast cancer (MBC) is a rare type of breast carcinoma, characterized by various combinations of mesenchymal, adenocarcinoma and other epithelial components. MBC often manifests as a large mass, with low axillary lymph node involvement and poor prognosis. Knowledge and treatment patterns about MBC demographics, presentation and tumor characteristics are very limited. In clinical practice, MBC is usually treated based on the guidelines developed for infiltrating ductal carcinoma (IDC). The ideal treatment paradigm for MBC is unknown due to its low incidence and pathological variability, so potential predictors of treatment efficacy need to be explored. This review summarizes the current models and strategies for MBC according to the published literature.

**Keywords:** Metaplastic breast cancer - therapy - systematic review

*Asian Pac J Cancer Prev*, 14 (11), 6221-6225

### Introduction

Breast cancer is the most frequently diagnosed cancer in women worldwide. Metaplastic breast carcinoma (MBC) is a rare form and only occurs in between 0.02% and 5% of breast carcinoma patients (Oberman, 1987; Al Sayed et al., 2006; Pezzi et al., 2007). MBC has epithelial or mesenchymal components, and two to three different components may exist within the tumor simultaneously. MBC normally manifests as a rapidly growing and palpable large mass ( $\geq 5$  cm), indicating a high potential for distant metastases. It is frequently lymph node negative (Oberman, 1987; Pitts et al., 1991; Gutman et al., 1995; Chao et al., 1999; Rayson et al., 1999). MBC is an aggressive disease which is more likely to be negative for estrogen receptor (ER), progesterone receptor (PR) and human epidermal growth factor receptor 2 (HER2) (Wargotz and Norris, 1989; Bae et al., 2011). It is usually treated with mastectomy, radiotherapy and chemotherapy. The prognosis is worse (Rayson et al., 1999), so early detection and treatment is the key factor to improve the cure rate. Although there are several reports, knowledge about MBC is still limited. The treatments of MBC are comprehensive, however, the optimal treatment strategies are still unclear due to its rarity and heterogeneous histological presentation. The aim of this review is to illustrate the current progress on the treatment and new research strategies for MBC.

### Surgical therapy

Surgical therapy is always a momentous approach to breast cancer including mastectomy (simple or modified radical mastectomy (MRM)), lumpectomy, breast-conserving surgery (BCS). Due to a rapidly growing and palpable large mass ( $\geq 5$  cm) in MBC patients, MRM was the main surgical procedure in most series (Pitts et al., 1991; Gutman et al., 1995; Chao et al., 1999; Rayson et al., 1999; Al Sayed et al., 2006; Pezzi et al., 2007). However, BCS could not be precluded for appropriate MBC patients who had absolute or relative indications. When ignoring the size of tumor, the rates of BCS and MRM were similar. Moreover, the overall survival (OS) or disease-free survival (DFS) was also similar (Dave et al., 2006; Pezzi et al., 2007; Tseng and Martinez, 2011). Likewise, when known prognostic factors (eg, histological subtype and tumor grade) were controlled, MBC patients treated with MRM or lumpectomy had similar OS or DFS (Sneige et al., 2001; Tseng and Martinez, 2011; Nonnis et al., 2012). It appears that the prognosis is not affected by the type of surgical treatment. In addition, current treatment guidelines of invasive ductal carcinoma (IDC) are appropriate for MBC patients. The use of radiotherapy parallels that of BCS, as will be anticipated. An adequate margin ( $\geq 3$  cm) was important to reduce local relapse and distant metastasis when performing local excision or quadrantectomy (Pezzi et al., 2007; Tseng and Martinea,

<sup>1</sup>Department of General Surgery, Xuzhou Medical College, Xuzhou, <sup>2</sup>Department of General Surgery, <sup>3</sup>Clinical Laboratory Center, Jiangsu Cancer Hospital, Nanjing, China \*For correspondence: doctangjinhai@163.com, jhzhao2838@sina.com

2011; Nonnis et al., 2012). Sneige et al. proposed a lumpectomy with wide margins or even a simple mastectomy relative to the tumor size (Sneige et al., 2001). Some cases with local recurrences had been successfully salvaged by surgery +/- radiotherapy and had a median survival of 47 months (Gutman et al., 1995; Rayson et al., 1999; Al sayed et al., 2006). Taking into account the large mass and poor prognosis, we choose MRM as an optimal surgical treatment, but BCS, lumpectomy, local excision with cancer-free margins cannot be precluded in some eligible patients.

Axillary lymph node (ALN) involvement or metastases was found in about 20% of MBC patients (Pezzi et al., 2007; Tseng and Martinez, 2011), and axillary staging had traditionally been performed with axillary lymph node dissection (ALND). Axillary lymph node involvement was consistently absent in spindle cell carcinoma (SCC) patients who underwent ALND, and no axillary node invasion was documented in patients with local recurrence (Bauer et al., 1984; Oberman, 1987; Sneige et al., 2001), which suggests that ALND is not necessary in patients with SCC. Similarly, carcinosarcoma with malignant mesenchymal component had not clinical or pathological ALN involvement. Unlike IDC, ALN metastases in MBC patients were low risky and did not correlate with clinical outcome (Bauer et al., 1984; Oberman, 1987; Gutman et al., 1995; Rayson et al., 1999). It seems that blood transfer is the main route of transmission, not the lymphatic metastasis. Why MBC shows a lower rate of axillary lymph node involvement in spite of large mass, the reason may be that tumor proliferation mechanism of MBC is somewhat different from that of a typical ductal original tumor. In consideration of these observations, we recommend ALND is cautions in MBC patients undergoing MRM, at least not necessary in SCC and carcinosarcoma. In view of similar accuracy in the detection of regional metastasis, ALND could be replaced by sentinel lymph node biopsy (SLNB).

## Radiation Therapy

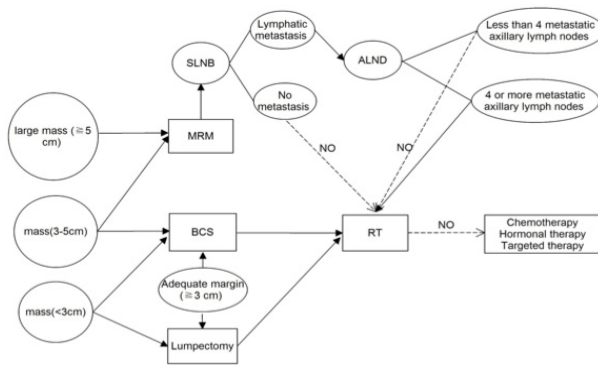
Other than a lower rate of lymph node metastases, MBC displays poorer prognostic features relative to IDC. It is important to prompt us to examine the use of adjuvant radiation therapy (RT). However, data were limited regarding the role of RT for MBC (Gutman et al., 1995; Dave et al., 2006). Recently, utilizing the Surveillance, Epidemiology, and End Results (SEER) database, the findings from Tseng and Martinez (Tseng and Martinez, 2011) supported that adjuvant RT improved both OS and DFS for all MBC patients regardless of the type of operation (lumpectomy versus MRM). According to the results of multivariate analysis, the use of RT had a better survival benefit for patients received lumpectomy compared with mastectomy. Post-lumpectomy RT was a standard component of BCS for minimizing local recurrences. Lumpectomy patients received RT who had a 49% decreased risk of death from any cause mortality, which was in accordance with the results of a meta-analysis, in which the authors demonstrated that prevention of local recurrences would improve OS and

DFS (Clarke et al., 2005). Mastectomy patients who received RT demonstrated a 33% decreased risk of all-cause mortality. Patients undergoing mastectomy with tumors  $\geq 5$  cm or 4 or more metastatic axillary lymph nodes derived a 47% and 42% decreased risk of all-cause and breast-specific mortality, respectively, but patients undergoing mastectomy with tumors  $< 5$  cm or less than 4 metastatic axillary lymph nodes derived no benefit from RT. Further, post-mastectomy RT was recommended for patients with gross extracapsular nodal extension and chest wall invasion (Fowble et al., 1988; Overgaard et al., 1997; Ragaz et al., 1997). Rosen and Emsberger suggested adjuvant RT as routine use for MBC patients (Rosen and Emsberger, 1987). BRCA1-related breast tumors were often high-grade, ER, PR and Her2 negative, and had a medullary phenotype. Basal-like tumors and BRCA1-related breast cancer were similar according to microarray and immunohistochemical analysis. MBC may be in the spectrum of basal-like breast tumors, which were commonly of higher grade and displayed more rapid growth. BRCA1 pathway, PTEN and TOP2A etc. had been shown down-regulated by genomic profiling (Tseng and Martinez, 2011). These theories may help explain the sensitivity to external beam RT. All data and theories indicate that RT should be considered as a component of multimodality therapy for MBC patients, especially patients who undergoing post-lumpectomy, BCS, tumor which is  $\geq 5$  cm or 4 or more metastatic axillary lymph nodes. But the therapeutic role of adjuvant RT is yet to be validated in a prospective clinical trial.

## Chemotherapy

The efficiency of systemic chemotherapy and optimal regimens of MBC are undefined for its rarity and heterogeneous histological characteristics. Some cases have showed a good response to chemotherapy. Takuwa et al. reported that one patient had a good response to platinum combined with taxane or anthracycline (Takuwa et al., 2011). Hennessy et al. reported that three sarcomatoid MBC patients that received doxorubicin and ifosfamide regimens had not relapse, also (Hennessy et al., 2006). However, accumulating evidences showed that chemotherapy regimens are feeble and chemo-resistant for MBC patients. Neoadjuvant chemotherapy is an important and direct way to predict chemotherapy effect. In a single-institute retrospective study, the response of MBC patients to neoadjuvant chemotherapy were quite poor, and 90% of the patients experienced disease progression while receiving neoadjuvant chemotherapy (Chen et al., 2011). Preoperative chemotherapy with anthracyclines and taxanes showed an 11–45% pathological complete response (pCR) rate for triple-negative breast cancer, but MBC patients exhibited a poorer response to chemotherapy (Rouzier et al., 2005). Hennessy et al. demonstrated a 10% pCR rate in neoadjuvant MBC patients who received four to six cycles of 5-fluorouracil/doxorubicin/cyclophosphamide (FAC) (Hennessy et al., 2006). These studies imply that the response to neoadjuvant chemotherapy is quite poor. In the same way, MBC patients also showed feeble response to

## Hormonal and Targeted Therapy



**Figure 1. Current Treatment Opinions about MBC**

postoperative chemotherapy. In a large-scale retrospective study, the data of systemic chemotherapy for MBC patients, compared with those IDC patients, supported the ineffectiveness of adjuvant chemotherapy (Pezzi et al., 2007). In Mayo clinic over 20 years, 10 MBC patients received ten different chemotherapy regimens were reported that one partial response to chemotherapy, 7 cases relapsed, which indicated ineffectiveness of adjuvant chemotherapy in this disease (Rayson et al., 1999). Moulder et al. treated patients with metastatic MBC on a phase I clinical trial with liposomal doxorubicin, bevacizumab, and temsirolimus (DAT) also shed some light on the treatment response (Moulder et al., 2011). Given the dearth of information concerning the role of chemotherapy, we sought to analyze the effect of chemotherapy on OS or DFS in MBC patients. Al Sayed et al. reported that adjuvant chemotherapy was administered to nine patients and two of them experienced distant relapse upon first disease recurrence, and the 3-year OS for these patients were worse than those who did not receive adjuvant systemic therapy, however the difference was not statistically significant (Al Sayed et al., 2006). Chao et al. found that 5 cases received adjuvant chemotherapy had a poorer OS than the patients who never take in chemotherapy (Chao et al., 1999). In the retrospective study by Bae et al., the 3-year DFS was worse than triple negative breast carcinoma for the lymphatic metastases (Bae et al., 2011). Several authors (Wargotz and Norris, 1989; Gutman et al., 1995) found no survival advantage for patients treated with chemotherapy for metastatic MBC patients and newer agents including gemcitabine, navelbine and herceptin were not encouraged. These findings imply that there is no survival advantage for patients treated with chemotherapy. For BRCA1-related breast cancer and basal-like tumors, current standard anthracycline and taxane containing chemotherapy regimens were prone to ineffectiveness (Banerjee et al., 2006). From neoadjuvant chemotherapy, postoperative chemotherapy to survival analysis, these reports will be helpful to explain the feeble or chemo-resistant response to chemotherapy. The lack of hormonal therapy, large mass, increased risk of systemic metastasis, and higher tumor grade perhaps explain the increased frequency of treatment with systemic chemotherapy in the MBC patients. Despite the advancements in chemotherapy, the response of MBC patients to systemic chemotherapy remains poor in the modern era.

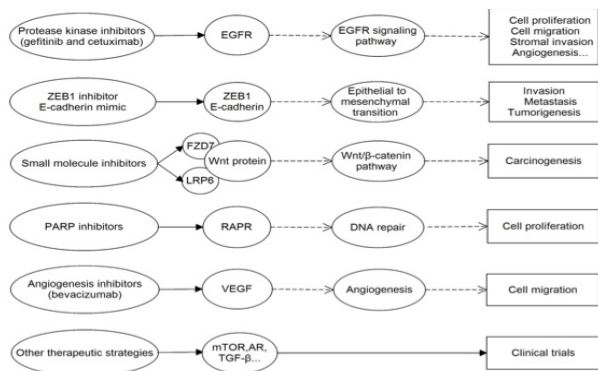
MBC is usually negative for ER, PR and HER2, which is the so called triple-negative tumors (Wargotz and Norris, 1989; Bae et al., 2011). What was worse, MBC patients had poorer 3-year DFS compared to a similar group of triple-negative IDC patients (Barnes et al., 2005; Rauf et al., 2006). Compared with IDC, the very low expressions of hormone receptor and HER2 in MBC represent another biologic difference and have obvious implications in their treatment. Rayson et al. found no response in 4 ER/PR positive patients treated with tamoxifen at time of relapse (Rayson et al., 1999). Therefore, MBC patients often show little or no response to adjuvant hormonal therapy or Her-2 targeted treatment (trastuzumab). The lack of endocrinotherapy and trastuzumab are a therapeutic option for adjuvant treatment in MBC patients. Current treatment opinions can be seen in Figure 1.

**New directions:** Researches on the molecular pathology of MBC are limited. Epidermal Growth Factor Receptor (EGFR) (Her-1) is homologous to other members of the EGFR/erbB family, including Her-2 (erbB2), Her-3 (erbB3), and Her-4 (erbB4). Aberrant signaling pathway through the EGFR can lead to neoplastic cell proliferation, migration, stromal invasion, resistance to apoptosis and angiogenesis, which will be a potential target for anticancer treatment (Dancey and Freidlin, 2003; Ellis and Hoff, 2004). Although MBC patients weakly expressed Her-2, Her-3, Her-4, encouragingly, the HER1 was high expression and may be efficient to the protease kinase inhibitors (gefitinib and cetuximab) (Leibl and Moifar, 2005). What is more, due to the absence of steroid receptors or other receptors of the EGFR family, the high expression of EGFR may be more sensitive to EGFR tyrosine kinase inhibitors, because it reflects the crucial role of this receptor for tumor progression in MBC patients. Compared with standard chemotherapy alone, patients treated with gefitinib in combination with standard chemotherapy showed no benefit in two phase 3 trials (Giaccone et al., 2004; Herbst et al., 2004), and gefitinib was only recommended to use as monotherapy. Based on these dates, MBC patients may benefit from protein kinase inhibitors such as gefitinib.

The spindle cell component of MBC exhibited over-expression of zinc finger e-box binding homeobox 1 (ZEB1) and down-regulation of E-cadherin. It was associated with breast cancer stem-cell markers aldehyde dehydrogenase-1 (ALDH-1) and cluster differentiation (CD) CD44<sup>+</sup>/CD24<sup>-</sup> which had tumor initiating properties (Zhang et al., 2012). The research indicates that the non-glandular component of MBC express biologic markers of an epithelial to mesenchymal transition. Blockading the epithelial to mesenchymal transition and/or tumor stem cells may improve patient outcome.

The Wnt signaling pathway is a significant pathway to regulate mammary gland development and carcinogenesis. Hayes et al. reported that activation of the Wnt signaling pathway was common in non-glandular MBC. Deregulation of  $\beta$ -catenin was a common feature of MBC, too (Hayes et al., 2008). Over activation of Wnt/ $\beta$ -catenin signaling pathway is thought to drive





**Figure 2. New Strategies about MBC.** A solid black arrow means “bond”, “combination” or “progress” and a dashed arrow mean “inhibition” or “repression”

breast tumorigenesis. Hence, small molecule inhibitors disrupting the Wnt/β-catenin pathway, particularly those targeting Wnt receptors lipoprotein receptor-related protein 6 (LRP6) and Frizzled 7 (FZD7), could represent a novel therapeutic treatment. Owing to many MBC patients are triple-negative breast cancer (TNBC), some novel therapeutic treatments on TNBC could be chosen to use in MBC. The poly (ADPribose) polymerase (PARP) family of proteins also played important roles in DNA repair. Importantly, PARP inhibitors and platinum agents had the same mechanisms of action (the induction of doublestranded DNA breaks that cannot be adequately repaired) in many respects. In addition, inhibition of PARP repair functions for chemotherapy-induced DNA lesions had been shown to potentiate the effect of some chemotherapy regimens (Hiller and Chu, 2012). The PARP inhibitors will hopefully improve the quality of this class of anticancer drugs and provide hope for patients. MBC had a high potential for metastasis, and the angiogenesis inhibitor bevacizumab, targeting VEGF, is being actively investigated in patients with metastatic breast cancer (Carey et al., 2010). For the lack of chemotherapy and hormonal therapy in MBC, it is encouraging. Other therapeutic strategies including mTOR, androgen receptor (AR) and TGF-β, are being evaluated in clinical trials. These potential new therapies are still too early to assess the clinical efficacy. Therefore, more efforts should be devoted to molecular cancer therapeutics and subtype research. A brief figure about new strategies can be seen in Figure 2.

## Conclusions

The standard treatment strategies for MBC are still unknown due to its rarity and heterogeneity, but the growing evidences will give us some references to choose an optimal treatment: MRM is the main surgical procedure, but BCS, lumpectomy, local excision with cancer-free margins cannot be precluded in some eligible patients. ALND might be not necessary. RT should be considered as a component of multimodality therapy for MBC patients. Chemotherapy regimens are feeble or chemo-resistant for MBC patients. The lack of hormonal therapy and trastuzumab make us change the direction of research in molecular cancer therapeutics and subtype research.

## References

- Al Sayed AD, El Weshi AN, Tulbah AM, et al (2006). Metaplastic carcinoma of the breast clinical presentation, treatment results and prognostic factors. *Acta Oncol*, **45**, 188-95.
- Bae SY, Lee SK, Koo MY, et al (2011). The prognoses of metaplastic breast cancer patients compared to those of triple-negative breast cancer patients. *Breast Cancer Res Treat*, **126**, 471-8.
- Banerjee S, Reis-Filho JS, Ashley S, et al (2006). Basal-like breast carcinomas: clinical outcome and response to chemotherapy. *J Clin Pathol*, **59**, 729-35.
- Barnes PJ, Boutilier R, Chiasson D, et al (2005). Metaplastic carcinoma: clinical-pathologic characteristics and HER2/neu expression. *Breast Cancer Res Treat*, **91**, 173-8.
- Bauer TW, Rostock RA, Eggleston JC, et al (1984). Spindle cell carcinoma of the breast: four cases and review of the literature. *Hum Pathol*, **15**, 147-52.
- Carey L, Winer E, Viale G, et al (2010). Triple-negative breast cancer: disease entity or title of convenience? *Nat Rev Clin Oncol*, **7**, 683-92.
- Chao TC, Wang CS, Chen SC, et al (1999). Metaplastic carcinomas of the breast. *J Surg Oncol*, **71**, 220-5.
- Chen IC, Lin CH, Huang CS, et al (2011). Lack of efficacy to systemic chemotherapy for treatment of metaplastic carcinoma of the breast in the modern era. *Breast Cancer Res Treat*, **130**, 345-51.
- Clarke M, Collins R, Darby S, et al (2005). Effects of radiotherapy and of differences in the extent of surgery for early breast cancer on local recurrence and 15-year survival: an overview of the randomised trials. *Lancet*, **366**, 2087-106.
- Dancey JE, Freidlin B (2003). Targeting epidermal growth factor receptor--are we missing the mark? *Lancet*, **362**, 62-4.
- Dave G, Cosmatos H, Do T, et al (2006). Metaplastic carcinoma of the breast: a retrospective review. *Int J Radiat Oncol Biol Phys*, **64**, 771-5.
- Ellis LM, Hoff PM (2004). Targeting the epidermal growth factor receptor: an important incremental step in the battle against colorectal cancer. *J Clin Oncol*, **22**, 1177-9.
- Fowle B, Gray R, Gilchrist K, et al (1988). Identification of a subgroup of patients with breast cancer and histologically positive axillary nodes receiving adjuvant chemotherapy who may benefit from postoperative radiotherapy. *J Clin Oncol*, **6**, 1107-17.
- Giaccone G, Herbst RS, Manegold C, et al (2004). Gefitinib in combination with gemcitabine and cisplatin in advanced non-small-cell lung cancer: a phase III trial--INTACT 1. *J Clin Oncol*, **22**, 777-84.
- Gutman H, Pollock RE, Janjan NA, et al (1995). Biologic distinctions and therapeutic implications of sarcomatoid metaplasia of epithelial carcinoma of the breast. *J Am Coll Surg*, **180**, 193-9.
- Hayes MJ, Thomas D, Emmons A, et al (2008). Genetic changes of Wnt pathway genes are common events in metaplastic carcinomas of the breast. *Clin Cancer Res*, **14**, 4038-44.
- Hennessy BT, Giordano S, Broglio K, et al (2006). Biphasic metaplastic sarcomatoid carcinoma of the breast. *Ann Oncol*, **17**, 605-13.
- Herbst RS, Giaccone G, Schiller JH, et al (2004). Gefitinib in combination with paclitaxel and carboplatin in advanced non-small-cell lung cancer: a phase III trial--INTACT 2. *J Clin Oncol*, **22**, 785-94.
- Hiller DJ, Chu QD (2012). Current Status of Poly(ADP-ribose) Polymerase Inhibitors as Novel Therapeutic Agents for Triple-Negative Breast Cancer. *Int J Breast Cancer*, **2012**, 829315.
- Leibl S, Moifar F (2005). Metaplastic breast carcinomas are

- negative for Her-2 but frequently express EGFR (Her-1): potential relevance to adjuvant treatment with EGFR tyrosine kinase inhibitors? *J Clin Pathol*, **58**, 700-4.
- Moulder S, Moroney J, Helgason T, et al (2011). Responses to liposomal Doxorubicin, bevacizumab, and temsirolimus in metaplastic carcinoma of the breast: biologic rationale and implications for stem-cell research in breast cancer. *J Clin Oncol*, **29**, 572-5.
- Nonnis R, Paliogiannis P, Giangrande D, et al (2012). Low-grade fibromatosis-like spindle cell metaplastic carcinoma of the breast: a case report and literature review. *Clin Breast Cancer*, **12**, 147-50.
- Oberman HA (1987). Metaplastic carcinoma of the breast. A clinicopathologic study of 29 patients. *Am J Surg Pathol*, **11**, 918-29.
- Overgaard M, Hansen PS, Overgaard J, et al (1997). Postoperative radiotherapy in high-risk premenopausal women with breast cancer who receive adjuvant chemotherapy. Danish Breast Cancer Cooperative Group 82b Trial. *N Engl J Med*, **337**, 949-55.
- Pezzi CM, Patel-Parekh L, Cole K, et al (2007). Characteristics and treatment of metaplastic breast cancer: analysis of 892 cases from the National Cancer Data Base. *Ann Surg Oncol*, **14**, 166-73.
- Pitts WC, Rojas VA, Gaffey MJ, et al (1991). Carcinomas with metaplasia and sarcomas of the breast. *Am J Clin Pathol*, **95**, 623-32.
- Ragaz J, Jackson SM, Le N, et al (1997). Adjuvant radiotherapy and chemotherapy in node-positive premenopausal women with breast cancer. *N Engl J Med*, **337**, 956-62.
- Rauf F, Kiyani N, Bhurgri Y (2006). Metaplastic carcinoma of the breast, an intriguing rarity. *Asian Pac J Cancer Prev*, **7**, 667-71.
- Rayson D, Adjei AA, Suman VJ, et al (1999). Metaplastic breast cancer: prognosis and response to systemic therapy. *Ann Oncol*, **10**, 413-9.
- Rosen PP, Ernsberger D (1987). Low-grade adenosquamous carcinoma. A variant of metaplastic mammary carcinoma. *Am J Surg Pathol*, **11**, 351-8.
- Rouzier R, Perou CM, Symmans WF, et al (2005). Breast cancer molecular subtypes respond differently to preoperative chemotherapy. *Clin Cancer Res*, **11**, 5678-85.
- Sneige N, Yaziji H, Mandavilli SR, et al (2001). Low-grade (fibromatosis-like) spindle cell carcinoma of the breast. *Am J Surg Pathol*, **25**, 1009-16.
- Takuwa H, Ueno T, Ishiguro H, et al (2011). A case of metaplastic breast cancer that showed a good response to platinum-based preoperative chemotherapy. *Breast Cancer*. [Epub ahead of print]
- Tseng WH, Martinez SR (2011). Metaplastic breast cancer: to radiate or not to radiate? *Ann Surg Oncol*, **18**, 94-103.
- Wargotz ES, Norris HJ (1989). Metaplastic carcinomas of the breast. III. Carcinosarcoma. *Cancer*, **64**, 1490-9.
- Zhang Y, Toy KA, Kleer CG (2012). Metaplastic breast carcinomas are enriched in markers of tumor-initiating cells and epithelial to mesenchymal transition. *Mod Pathol*, **25**, 178-84.