Nonpuerperal uterine inversion due to submucous leiomyoma

Hiroaki Ishida, Tomone Yano, Yutaka Yasuda, Akiko Takashima, Naoki Takeshita, Toshihiko Kinoshita

Department of Obstetrics and Gynecology, Toho University Medical-center Sakura Hospital, Chiba, Japan

Abstract

Uterine inversion is a rare complication of the postpartum period and an even rarer complication of the nonpuerperal period. A 47-year-old woman, gravid 2, para 2, was referred to our hospital with blood-stained leucorrhoea and severe anemia. Magnetic resonance imaging (MRI) scans showed a U-shaped uterine cavity and the pedicles of a tumor attached to the uterine fundi. The patient underwent an abdominal hysterectomy. The diagnosis of uterine inversion was confirmed during the operation. MRI should be performed for the diagnosis of this rare disease.

Introduction

Uterine inversion is a rare complication of the postpartum period and an extremely rare event in non-pregnant women. Only 150 cases have been reported from 1887 to 2006, with the large majority occurring in women over 45 years of age.[1] In this report, we describe our experience with a submucous leiomyoma causing uterine inversion.

Case Report

A 47-year-old woman, gravid 2, para 2, was referred to our hospital with blood-stained leucorrhoea. On speculum examination, a globular mass measuring about 6 cm in diameter as seen in the vagina. The cervix could not be visualized. On ultrasound scan, the uterus was found to measure 57×70 mm, with a 3-mm-thick endometrium and a 60-mm cervicoisthmic mass; both ovaries appeared normal. Based on these findings, we suspected a myoma protruding into the vagina. Magnetic resonance imaging (MRI) was performed. The MRI demonstrated a U-shaped uterine cavity, which made us strongly consider the possibility of uterine inversion (Figure 1). The patient's hemoglobin level was 4.0 g/dL. Before the necessary operation, a blood transfusion was given. A laparotomy was performed; the fundus of the uterus was found to be concave, and bilateral round ligaments and tubes were found to be pulled into the uterus (Figure 2). These observations confirmed the diagnosis of incomplete uterine inversion. We attempted to pull up the round ligaments, as classically described by Huntington[2] with pressure exerted from the vagina, but were unable to do so, as the constricting ring was too tight. After identifying both ureters, we performed Haultain's procedure, followed by a hysterectomy.[2] The pathology report confirmed uterine inversion resulting from a 6-cm leiomyoma attached to the uterine fundi.

Discussion

Uterine inversion in non-pregnant women is a rare occurrence. In 85% of cases, uterine inversion is caused by benign uterine pathologies, whereas in 15% of cases, it is related to malignant tumors.[1] Uterine sarcoma (leiomyosarcoma, rhabdomyosarcoma, and sarcoma of the endometrial stroma) has been more frequently reported as a cause of uterine inversion than endometrial carcinoma or carcinosarcoma.[1] Nonpuerperal uterine inversion has been reported in only 5 women under 45 years of age.[3]

The pathophysiology of uterine inversion appears to be multifactorial, seemingly involving 3 main etiologic factors: i) sudden emptying of the tumor; ii) thinning of the uterine walls by the intrauterine tumor, and iii) dilatation of the cervix. The distended myometrium becomes irritated and develops expulsive contractions, which dilate the cervix and facilitate expulsion of the tumor. The tumor passes through the weak portion of the myometrium where it is attached, thereby expediting inversion. Additional possible etiologic factors include the weight of the intrauterine mass, manual traction on the tumor, straining, coughing, and sneezing.[2]

The main clinical symptoms of uterine inversion are abnormal vaginal bleeding, lower abdominal pain or vaginal pressure, and, in rare cases, acute urinary retention by urethral compression. The clinical diagnosis of uterine inversion may be difficult if the cervix is hidden behind the tumor and the uterine fundus cannot be palpated; consequently, pelvic ultrasonography or MRI may be beneficial for diagnosis. Ultrasonography shows 2 signs: indentation of the fundic area and a depressed longitudinal groove extending from the uterus to the center of the inverted portion.[3] Evaluation by MRI has also been described; in T2-weighted MRI scans, a U-shaped uterine cavity and a thickened and inverted uterine fundus on the sagittal plane, as well as a *bulls-eye* configura-

Correspondence: Toshihiko Kinoshita, Department of Obstetrics and Gynecology, Toho University Medical-Center Sakura Hospital, 564-1 Shimoshizu Sakura City, Chiba 285-8741, Japan.
Tel. +81.434.628.811 - Fax: +81.434.628.820
E-mail: kino@sakura.med.toho-u.ac.jp

Key words: leiomyoma, nonpuerperium, uterine inversion.

Received for publication: 21 September 2011.
Accepted for publication: 21 October 2011.

Clinics and Practice 2011; 1:e105
doi:10.4081/cp.2011.e105

Figure 1. Sagittal magnetic resonance image demonstrating a pedicle of the tumor attached to the uterine fundus, extrusion of the tumor into the vagina (star), and concavity of the uterine fundus (arrow).

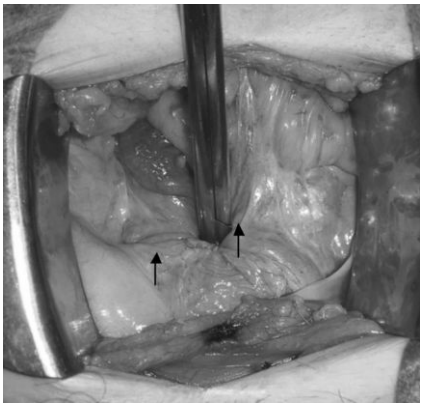

Figure 2. View obtained during laparotomy: the round ligaments were pulled into the uterus (arrows).

tion on the axial plane are signs indicative of uterine inversion.[4] In this case, we were able to identify the signs of uterine inversion by MRI, but not by ultrasonography.[5]

Uterine inversion may be classified into 4 stages: i) incomplete inversion of the uterus with the uterine fundus in the cavity; ii) complete inversion of the uterine fundus through the cervix; iii) complete inversion with the fundus protruding through the vulva; and iv) complete inversion through the vulva of both the uterus and the vagina.[1] Hysterectomy is usually the treatment of choice for nonpuerperal uterine inversion in women with no further desire to fall pregnant. Many surgical techniques have been described, including abdominal approaches like those of Huntington and Haultain and vaginal approaches like those of Kustner and Spinelli.[2] The vaginal approach requires either incision of the anterior or posterior vaginal wall or incision of the constricted cervical ring and posterior uterine wall. These procedures are not easy to perform, because the vagina is completely filled by the uterus. The abdominal approach, in which the uterus is not incised, has been defined by Huntington; the inverted portion is pulled from the uterus with Allis clamps. Unfortunately, this technique is not successful in most cases, because of the strong constriction ring. The Haultain operation is an easy and surgically safe method, which involves retroperitoneal dissection of the ureter after the tying of uterine vessels and incision of the posterior uterine wall for repositioning of the inverted fundus. Nonpuerperal inversion of the uterus is usually caused by a benign myoma, but it should be kept in mind that nonpuerperal inversion may also derive from a malignant tumor. Resection of the inverted uterus may necessitate an incision in the uterine wall; however, it is believed that this intervention does not diminish prognosis.

References

1. Lupovitch A, England ER, Chen R. Nonpuerperal uterine inversion in association with uterine sarcoma: case report in a 26-year-old and review of the literature. Gynecol Oncol 2005;97:938-41.
2. Lascarides E, Cohen M. Surgical management of nonpuerperal inversion of the uterus. Obstet Gynecol 1968;32:376-81.
3. de Vries M, Perquin DA. Non-puerperal uterine inversion due to submucous myoma in a young woman: a case report. J Med Case Reports 2010;4:21.
4. Hsieh TT, Lee JD. Sonographic findings in acute puerperal uterine inversion. J Clin Ultrasound 1991;19;306-9.
5. Lewin JS, Bryan PJ. MR imaging of uterine inversion. J Comput Assist Tomogr 1989; 13:357-9.