Original Article

Pattern of thyroid diseases in central Sudan: Nuclear medicine perspective.

Ahmed E. Elmadani[1*], Nagla Gasmelseed[2*], Dafalla Abuidris[3*], Anas A Hamdoun[4*]

Abstract:

Thyroid scintigraphy using Tc-99m pertechnetate is a frequently performed procedure in routine nuclear medicine practice in addition to thyroid hormonal assay by radioimmunoassay (RIA). There is no clear description of thyroid diseases pattern in Sudan using nuclear medicine as a diagnostic tool. The aim of this retrospective study is to determine the pattern of thyroid diseases using the nuclear medicine facilities in our institute during a period (2001-2003).

Methods: All patients referred to the department of nuclear medicine for thyroid scan from January 2001 to December 2003 were included in this study and the thyroid function test when available. Data were analyzed by SPSS software.

Results: A total of 2070 patients were referred to the department and only 1605 (77.5%) have thyroid function test results available for scan reporting. Female to male ratio is 9:1. The mean age is 34 ±13.36 (1-86 years old). The most common pattern is simple multinodular goiter 784 (37.8%) and the second is solitary thyroid nodule 506 (24.4%), followed by simple diffuse goiter 415 (20%). From a total of 1605 thyroid function test results, 1377 patients (85.8%) were euthyroid, 168 (10.5%) were having hyperthyroidism while only 60 (3.7%) were having hypothyroidism.

Conclusion: The vast majority of patients in this study were young females with simple goiter and normal radionuclide uptake. No more information gained particularly when the patient is known clinically and biochemically to have a simple goiter. A solitary cold nodule is also common.

Keywords: Thyroid scan, goiter, cold nodule, iodine deficiency, thyroid disease.

Nuclear medicine plays a crucial role in the diagnosis of thyroid diseases. Thyroid hormonal assay by radioimmunoassay (RIA) and thyroid scan and uptake, are the principal nuclear tests in thyroid disease. Thyroid scintigraphy using Tc-99m pertechnetate is a frequently performed procedure in routine nuclear medicine practice. For most patients with thyroid disease, the combination of careful history, skilled physical examination, tests of thyroid function, fine needle aspiration biopsy, and scintigraphy provide the most cost-effective means of evaluating the thyroid gland and its diseases[1]. Measurement of urine iodine concentration gives insight into iodine intake and can be used to prove iodine deficiency as a cause of goiter.

A suppressed serum TSH concentration is the earliest biochemical manifestation of hyperthyroidism[2].

The primary indication for a scan in the case of euthyroid nodular goiter with a low or suppressed TSH level, when autonomous toxic nodule is suspected[3]. Autonomously functioning thyroid nodules appear "hot" on scintigraphy because they selectively concentrate radionuclide to a greater extent than the remaining thyroid gland, which is controlled by the normal T4-TSH feedback mechanism.

1- MSc Nuclear Medicine
2- MD Molecular Biology.
3- Fc Rad Onc.
4- FRCR, MSc Nuclear medicine.
*National Cancer Institute, University of Gezira.
Correspondence E-mail: ahmedelmadani@yahoo.com

Thyroid scanning will not distinguish between benign and malignant thyroid lesions[4-6]]. Any lesion suspicious of malignancy on cytologic examination (by FNAC) may be surgically removed[4]].

Thyroid scan and uptake may be used to differentiate between different causes of hyperthyroidism. Scintigraphic characteristics also help differentiate between nodular and Graves' disease. Scintigraphy combined with ultrasound examination may be used to identify the underline cause of congenital hypothyroidism such as thyroid agenesis, dyshormonogenesis, and incomplete thyroid descent[7]. Moreover, ultrasound distinguishes cystic form solid thyroid cold nodule,

The scintigraphic findings in Hashimoto's thyroiditis are highly variable and can mimic any thyroid abnormality and most of its pattern is diffusely enlarged thyroid gland similar to toxic diffuse goiter[8]. Less common forms of thyroiditis include Riedel's struma, which is characterized by extensive fibrosis of the thyroid gland, and acute suppurative thyroiditis, which is a bacterial infection[9].

Thyroid scan can determine the retrosternal extension of a huge goiter. The cervico-thoracic CT-scan is the key examination for the assessment of a retrosternal goitre making it possible to appreciate its features, anatomic relations and tracheal involvement[10].

Material and Methods:

Nuclear medicine department in the national cancer Institute was established in 1994 and equipped with two gamma cameras (single and dual head) serving all patients in the Gezira state and nearby states and it's the second center in Sudan after radioisotope center in Khartoum (RICK).

All patients referred to the department for thyroid scan from January 2001 to December 2003 were included in this study, correlated with thyroid function tests when available.

The scintigraphies were all obtained with a 5-mm single-hole collimator-equipped gamma-scintillation camera 10-20 minutes after intravenous injection of 37-111MBq of sodium pertechnetate Tc 99m.

Data were acquired with a 128 x 128 matrix and a zoom factor of 2.67–4.0. Imaging acquisition was terminated at 100 k counts or after 900 s of imaging, whichever occurred first.

Radionuclide uptake by the thyroid gland at 10-20 min was also calculated as a percentage of the dose injected, allowing for decay and correcting for background. The normal range of radionuclide uptake applied was 0.5–5%.

Diffuse toxic goiter (Graves' disease) was diagnosed in a diffusely enlarged thyroid gland with a high uptake of tracer throughout in correlation with thyroid function test. Viral thyroiditis was diagnosed on the bases of thyroid function tests with short interval signs and symptoms compatible with thyrotoxicosis and the scan showing an inhomogeneous distribution of tracer throughout the thyroid with reduced tracer uptake. Autonomously functioning thyroid nodules show focal areas of increased uptake, with suppressed uptake in the rest of the gland. Nodularity was detected as areas of reduced and non-homogeneous in tracer uptake.

Descriptive analysis of the patients' data was done by SPSS statistical package to determine the thyroid diseases pattern in our region.

Results:

A total of 2070 patients were referred during study period for thyroid scan were included in this study. The female to male ratio is 9:1 (1861 female and 209 male). The mean age is 34 ±13.36 (1-86 years old) and about 60% of age ranges from 20 to 40 years (Fig 1).

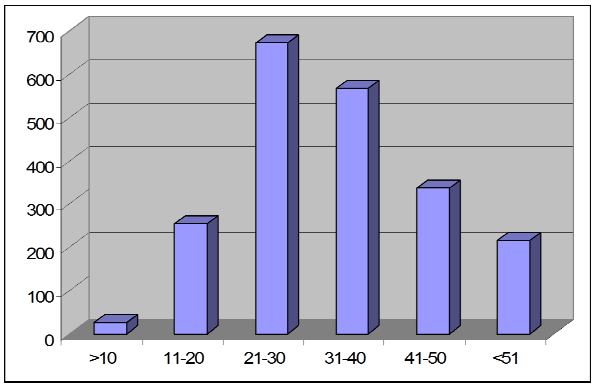

Fig (1): Shows age distribution in years.

The vast majority of our patients (about 94%) reside in central Sudan.
The most common pattern is simple multinodular goiter 784 (37.8%) as in fig 2 C, and the second is solitary thyroid nodule 506 (24.4%) as in fig 2 E, followed by simple diffuse goiter 415 (20%) as in fig 2 A.

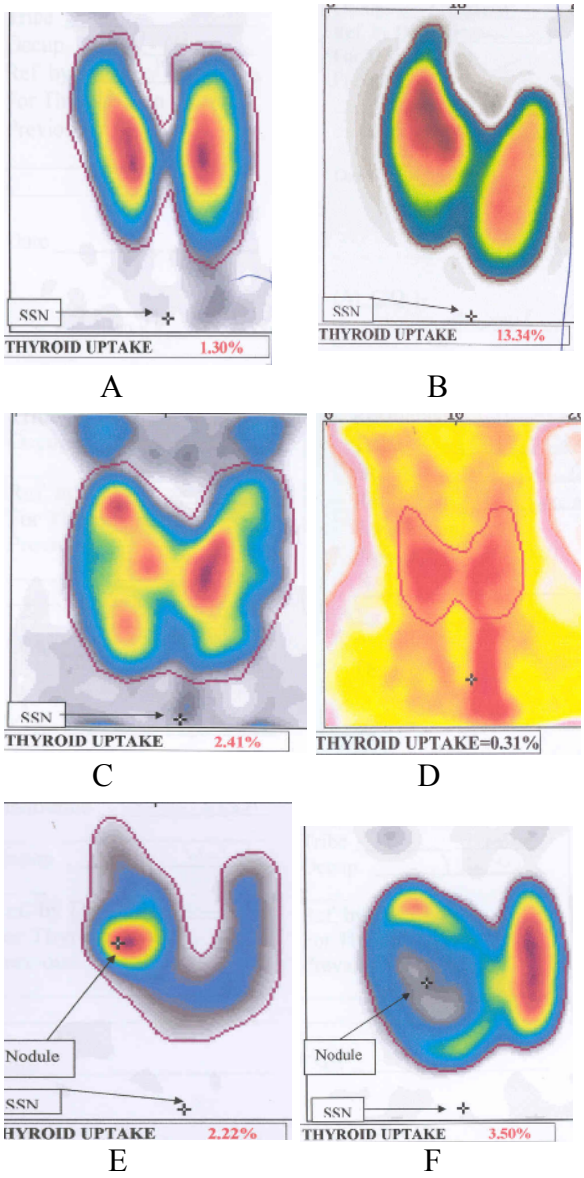

Fig (2) Different patterns of thyroid scan and uptake: (A) illustrates a simple diffuse goiter with normal radionuclide uptake (1.3%), (B) toxic diffuse goiter with increased uptake (13.34%), (C) simple multinodular goiter with normal uptake (2.41%), (D) thyroiditis with low uptake (0.31%), (E) solitary cold thyroid nodule with normal uptake (3.50%), and (F), hot thyroid nodule suppressing the rest of the gland but the uptake is not increased.

The total number of simple goiter (diffuse and/or multinodular) is about 1199 (57.8%) (Table1).

Table (1) shows the pattern of thyroid scan diagnosis.

Scan diagnosis	Frequency	Percent
Normal	65	3.1
Simple goiter	1199	57.9
Solitary cold nodule	506	24.4
Toxic diffuse goiter	69	3.3
Toxic MNG	57	2.8
Toxic thyroid nodule	134	6.5
Thyroiditis	23	1.1
Others	17	0.9
Total	2070	100.0

The number of normal cases is 65 (3.1%) and all of them have no neck swelling clinically, normal scan pattern and uptake with normal thyroid function test.
Out of 2070 patients underwent thyroid scan, only 1605 (77.5%) have thyroid function test result available for scan reporting. From a total of 1605 thyroid function test results, 1377 (85.8%) patients were euthyroid, 168 (10.5%) were hyperthyroid while only 60 (3.7%) were hypothyroid. Thyroid uptake measurements were normal in 1646 (79.5%), decreased in 30 (1.5%) and increased in 394 (19%).
Taking the euthyroid patients only (1377), the uptake were normal in 1200 (87.1), increased in 162 (11.8%) and decreased in 15 (1.1%) (Table 2).
Among the 168 hyperthyroid patients (including toxic diffuse, toxic multinodular goiter and toxic thyroid nodule) the uptake was increased in 112 (66.7%), and normal in

53 (31.5%) and 3 (1.8%) patients showed decreased uptake.

Discussion:

The first step in evaluating a patient with suspected thyroid disease is to correlate the normal or abnormal scintigraphic pattern with available biochemical data, clinical history, and physical examination[11].

Table (2): Shows the scan pattern and the corresponding uptake.

Uptake:	Scan diagnosis Normal	S G	C N	TDG	TNG	T N	Thyroiditis	others	Total
Normal	65	983	474	4	14	79	14	13	1646
Decreased	0	15	7	0	0	0	5	3	30
Increased	0	201	25	65	43	55	4	1	394
Total	65	1199	506	69	57	134	23	17	2070

The diagnosis of hypothyroidism is confirmed by a high serum TSH and low values of FT4 and T3 while hyperthyroidism is confirmed by a low serum TSH value and elevated values for the serum FT4 and/or T3[12]. As the best screening tests for hypo- or hyperthyroidism are those related to the level of circulating thyroid hormones, thyroid radionuclide uptake tests have lost much of their diagnostic value[13]. Thus, taking the scan and radionuclide in isolation, the diagnosis can be misleading and should be evaluated in conjunction with current biochemistry particularly in thyroiditis[14]. In this study only 1605 out of 2070 (77.5%) have thyroid function test results available during scan reporting, while the rest of results were not available and their scans were reported without correlation with the thyroid function test. Simple goiter is most commonly found in young women in their teens or 20s[15]. The vast majority of patients are females with simple goiter and this is in agreement with what is found in the literature[15, 16].

Nodular thyroid disease is highly prevalent in iodine deficient areas[17]. In this study two thirds of the patients had simple goiter which raises the possibility of iodine deficiency in the study area. This study also revealed that the uptake is an inaccurate way of diagnosing the thyroid function status, as 162 euthyroid patients showed increased uptake of radionuclide while 53 (31.5%) patients out of 168 hyperthyroid patients showed normal uptake. The uptake is affected by many factors e.g. thyroxin and antithyroid drugs that should be stopped for 4-6 weeks prior the test. It is also affected by the state of iodine deficiency in the area. Moreover in case of thyroiditis, the uptake can be normal, increased or decreased depending on the type and duration of the infection.

The common indications of referral for thyroid scans in decreasing order of frequency are thyroid swelling, solitary thyroid nodule thyrotoxicosis. However, in ideal situation, there are few indications for ordering a thyroid scan in a primary care setting. In suspected hyperthyroidism, a sensitive thyroid stimulating hormone (TSH) assay should be the initial test ordered. If the TSH level is low or suppressed, and the diagnosis of thyroiditis versus Graves' hyperthyroidism is not clear, a thyroid radioactive uptake test is appropriate to differentiate between the two (as shown in fig 2 B, D & F).

In the case of euthyroid nodular goiter, fine-needle aspiration is the most accurate initial test to evaluate for malignancy.

Little useful information was obtained in the evaluation of goiter when it's the only indication of the thyroid scan (as shown fig 2 A). Demena, S[18] in his study of 1037 thyroid scans concluded that thyroid scintigraphy was an unnecessary investigation in the evaluation of goiters in euthyroid patients. Its primary role was in the investigation of the solitary nodule, ectopic thyroid tissue and the retrosternal goiter. Therefore, only selected

patients should be investigated with thyroid scintigraphy[18].

Tindall H[19] and his group also concluded that thyroid scintigraphy was an unnecessary investigation in approximately 45% of cases. In all cases of goiter no additional useful information was obtained from scintigraphy. Its primary role was in the investigation of the solitary nodule and in detecting toxic nodules in thyrotoxic patients who had no evidence of Graves' disease. Greater discrimination of requests would avoid investigating patients unnecessarily and reduce costs[19].

In this study, 60.5% of patients were either simple goiter or normal and no additional information gained and hence the management will not change on the bases of the thyroid scan result.

Preoperative thyroid isotope scan would influence the operative procedure and the preoperative management in patients with nontoxic goiter only if it raises suspicion of malignancy. However, the scintigraphy shows significantly lower sensitivity and specificity in the detection and prediction of malignant nodules in the thyroid gland[20].

The study revealed that one forth of patients has solitary thyroid nodule and for all of them we suggested fine needle aspiration cytology to rule out the possibility of malignancy (as shown in Fig 2 E). Although physical examination, thyroid scan, fine-needle aspiration biopsy and measurement of serum thyroglobulin are helpful in the management of solitary thyroid nodule, fine-needle biopsy remains the best single cost effective method. When cytologic examination shows malignancy or unspecified neoplasm, surgery is indicated. For most patients with cytologically benign lesions, careful follow-up will suffice[21].

Ultrasound proved to be especially valuable for differentiating between solid and cystic nodules. This is of practical importance because completely cystic nodules are nearly always benign and may be treated by thin needle puncture with aspiration of the cyst fluid. Differentiating between benign and malignant solid nodules was not possible with ultrasound, however[22]. In addition, ultrasonically guided percutaneous fine needle biopsy is employed for emptying cysts or gaining material for cytological examination[23]. Hence adding ultrasound to the fine needle aspiration cytology (FNAC) technique will improve its specificity, accuracy and positive predictive value.

Conclusion:

The vast majority of patients in this study were young females with simple goiter and normal radionuclide uptake. No more information gained particularly when the patient is known clinically and biochemically to have a simple goiter. A solitary cold nodule is also common pattern.

Thyroid scan should not be requested as a routine for very patients with thyroid disease for two reasons: the radiation hazards and the cost.

References:

1.Nusynowitz ML. Thyroid imaging. Lippincotts Prim Care Pract 1999; 3(6): 546-55; quiz 556-8.

2. Daniels GH. Hyperthyroidism: multiple possibilities in the female patient. Int J Fertil Womens Med 1999; 44(1): 6-11.

3. Wu SY and Weiss RE. Radioiodine imaging in the primary care of thyroid disease. Postgrad Med 2006; 119(2): 70-7.

4. Gharib H, Goellner JR; Zinsmeister AR et al., Fine-needle aspiration biopsy of the thyroid. The problem of suspicious cytologic findings. Ann Intern Med 1984; 101(1): 25-8.

5. Cutfield RG and Croxson MS. A clinico-pathological study of 100 patients with solitary 'cold' thyroid nodules. N Z Med J 1981; 93(684): 331-3.

6. Gogas JG and Skalkeas GD. Thyroid nodules and thyroid carcinoma. Int Surg 1975; 60(10): 534-5.

7. Sarkar, S. Benign thyroid disease: what is the role of nuclear medicine? Semin Nucl Med 2006; 36(3): 185-93.

8. Yarman S, MUDUN A, ALAGOL F et al. Scintigraphic varieties in Hashimoto's thyroiditis and comparison with ultrasonography. Nucl Med Commun 1997; 18(10): 951-6.

9. Intenzo CM, Park CH, Kim SM et al. Clinical, laboratory, and scintigraphic manifestations of subacute and chronic thyroiditis. Clin Nucl Med 1993; 18(4): 302-6.

10. Ayache S, Mardyla N, Tramier B et al. Clinical signs and correlation with radiological extent in a series of 117 retrosternal goitre. Rev Laryngol Otol Rhinol (Bord) 2006; 127(4): 229-37.

11. Smith JR and Oates E. Radionuclide imaging of the thyroid gland: patterns, pearls, and pitfalls. Clin Nucl Med 2004; 29(3): 181-93.
12. Afschrift, M. Thyroid diseases in the elderly. Tijdschr Gerontol Geriatr 1990; 21(1): 3-6.
13. Konig MP, Bürgi H, Kohler H et al. When is a radioisotope diagnosis indicated in thyroid diseases and when is it superfluous?. Schweiz Med Wochenschr 1975; 105(12): 361-7.
14. Ramtoola S, MAISEY MN, CLARKE S et al. The thyroid scan in Hashimoto's thyroiditis: the great mimic. Nucl Med Commun 1988; 9(9): 639-45.
15. Toft, A.D. Thyroid enlargement. British Medical Journal 1985; 290: 1066-1068.
16. Tan BC, Chang CH, and Sethi VK. Thyroid scanning & the significance of the solitary cold nodule. Ann Acad Med Singapore 1981; 10(3): 293-7.
17. Fuhrer D, Mugge C and Paschke R. Questionnaire on management of nodular thyroid disease (Annual Meeting of the Thyroid Section of the German Society of Endocrinology 2003). Exp Clin Endocrinol Diabetes 2005; 113(3): 152-9.
18. Demena, S. Experience in thyroid scintigraphy with Ethiopian patients. Ethiop Med J 1993; 31(1): 1-7.
19. Tindall H GA, Penn ND. Is the current use of thyroid scintigraphy rational? Postgrad Med J 1987; 63(744): 869-71.
20. Mann B, Schmale P, Schwarz A et al. Is preoperative scintigraphy in euthyroid nodular goiter necessary?. Langenbecks Arch Chir Suppl Kongressbd 1997; 114: 1148-50.
21. Christensen SB, Bondeson L, Ericsson UB et al. Prediction of malignancy in the solitary thyroid nodule by physical examination, thyroid scan, fine-needle biopsy and serum thyroglobulin. A prospective study of 100 surgically treated patients. Acta Chir Scand 1984; 150(6): 433-9.
22. Thijs LG and Wiener JD. Ultrasonic examination of the thyroid gland. Possibilities and limitations. Am J Med 1976; 60(1): 96-105.
23. Petzoldt R., Lutz H, Grumeth M et al. Sonographic thyroid diagnosis. Fortschr Med 1975; 93(34): 1725-30.