Research in Cardiovascular Medicine
Official Journal of Rajaie Cardiovascular Medical and Research Center

Treating Refractory Hypertension: Renal Denervation With High-Resolution 3D-Angiography

Eduardo Alegria-Barrero [1,*], Rodrigo Teijeiro [1], Miguel Casares [2], Mercedes Vega [1], Marco A Blazquez [1], Ramon Martos [1], Carlos De Diego [1], Raúl Moreno [3], Miguel A San Martin [1]

[1] Department of Cardiology and Interventional Cardiology, Torrejon University Hospital, Madrid, Spain
[2] Department of Radiology and Interventional Radiology, Torrejon University Hospital, Madrid, Spain
[3] Department of Cardiology and Interventional Cardiology, La Paz University Hospital, Madrid, Spain

* *Corresponding author:* Eduardo Alegria-Barrero, Department of Cardiology and Interventional Cardiology, Torrejon University Hospital. Tel: +34-916262626, Fax: +34-914886624, E-mail: eduar.alegria@gmail.com

ABSTRACT

A 53-year-old male was referred to our Department for refractory primary hypertension. Despite high doses of 6 anti-hypertensive drugs, ambulatory monitoring of blood pressure (BP) revealed a mean BP of 160/90 mmHg. Under local anaesthesia, renal denervation with radiofrequency was performed supported by high-resolution 3D angiography, which helped confirm the position of the applications in a spiroid fashion.

Keywords: Hypertension; Cardiovascular Disease; Denervation; Angiography

1. Introduction

High blood pressure is an independent cardiovascular risk factor with high prevalence (1). Precisely, hypertension can lead to ischemic heart disease (myocardial infarction), heart failure, stroke, dementia and chronic kidney disease (2). Despite physical exercise, dietary recommendations and pharmacological therapy, up to 50% of hypertensive patients do not achieve adequate blood pressure control (2). Clinical and experimental studies have shown a sympathetic activation with positive feedback as a physiopathological mechanism leading to hypertension and contributing to maintaining high blood pressure (3-5). Endovascular treatment with low dose radiofrequency in the renal arteries (renal denervation) has shown to be effective reducing sympathetic activation of efferent nerves, involved in hypertensive responses (6-9). Moreover, this technique has been shown to have prolongued predictable effects and low incidence of complications (mainly vascular access-related) (6). Blood

▸Article type: Case Report; Received: 17 Dec 2012, Revised: 27 Dec 2012, Accepted: 27 Dec 2012.

▸Implication for health policy/practice/research/medical education:
The manuscript illustrates a renal denervation case where multiple imaging techniques helped physicians perform this novel technique. Across Europe, its use is increasing and many interventionalists are starting to learn the indications and techniques.

▸Please cite this paper as:
Alegria-Barrero E, Teijeiro R, Casares M, Vega M, Blazquez MA, Martos R, De Diego C, Moreno R, San Martin MA. Treating Refractory Hypertension: Renal Denervation With High-Resolution 3D-Angiography. *Res Cardiovasc Med*. 2013;2(2):106-8. DOI: 10.5812/cardiovascmed.9700

pressure reduction has been effective in more than 85% of the subjects treated with renal denervation, adequately selected (systolic blood pressure > 160 mmHg despite > 4 antihipertensive drugs including diuretics), obtaining a reduction > 10 mmHg in systolic blood pressure (6, 7). Imaging techniques are continuously improving to help interventionalists conduct this novel technique (6). We discuss the contribution of different imaging modalities to the success of the procedure.

2. Case Report

A 53-year-old Caucasian male was referred to our Department for refractory primary hypertension. Despite high doses of six anti-hypertensive drugs (Enalapril, Doxazosin, Hidroclorotiazide, Spironolactone, Amlodipine, Atenolol), ambulatory monitoring of blood pressure (BP) revealed a mean BP of 160/90 mmHg. Exhaustive blood tests, CT scan and renal arteries ultrasound suggested primary hypertension as the most probable diagnosis (*Figure 1*). Coronary CT scan ruled out significant coronary heart disease (*Figure 2*). Under local anaesthesia and after informed consent, renal denervation with radiofrequency was performed supported by high-resolution 3D angiography (*Figure 1*C), which helped confirm the position of the applications with Ardian´s Simplicity Catheter (Minneapolis, MN, USA) in an spiroid fashion and negotiate properly the curve of the right renal artery. 3D angiography was obtained after continuous contrast injection and 360° angiographic acquisition using a single-plane Phillips Allura Xper FD20, with XperSwing technology. Six weeks after the procedure, the patient has recovered without complications and systolic blood pressure has dropped 20 mmHg, measured by 24-hour ambulatory recording of blood pressure.

Figure 1. Multi-Modality Imaging For Renal Denervation

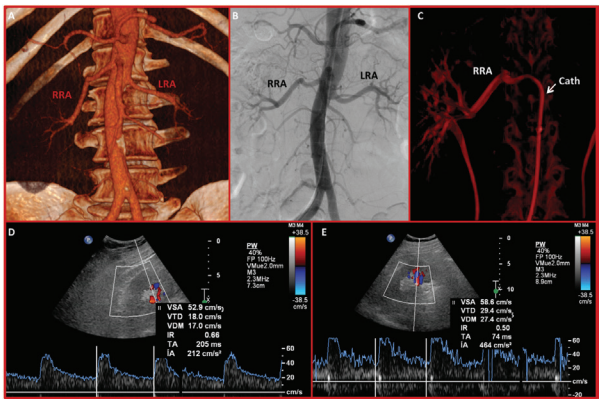

A) 3D-angio-computerized tomography (CT) showing anatomic characteristics of the right and left renal arteries (RRA, LRA, respectively); B) Angiographic appearance of the renal arteries after contrast injection; C) 3D-angiography reconstruction of the RRA showing a curvature of the mid-RRA; D) RRA and E. LRA Doppler velocity showing normal waves

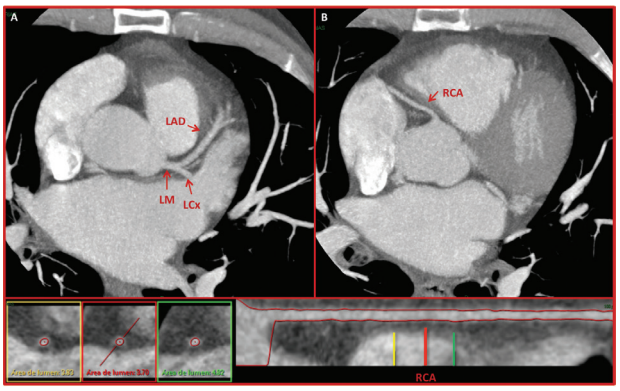

Figure 2. 64-MDCT Coronary Angiography of the Patient Showing Normal Coronary Arteries

3. Discussion

Renal denervation has been proposed as an effective treatment for refractory primary hypertension for patients with inadequate blood control despite high doses of numerous drugs (9). Simplicity Trial (6, 7) was a multicentric randomized Trial that revealed a consistent, predictable and durable reduction of blood pressure after radiofrequency ablation of both renal arteries, following a spiroid fashion aiming to reduce sympathetic hyper activation of the efferent nervous terminations located at the media layer of the artery. After renal denervation, patients experience a progressive reduction of blood pressure, up to SBP reductions of 30-40 mmHg after 2 years (10), leading to a better blood pressure control, reducing pharmacological therapy. In addition, cost-effectiveness studies have demonstrated that this percutaneous treatment is cost-effective in the long-term. Imaging modalities are essential for interventionists aiming to deliver radiofrequency in a spiroid fashion. CT renal artery scan helps physicians determine the uptake of the arteries from the aorta the anatomy of both arteries. In the reported case, 3D angiographic reconstruction (*Figure 1*C) helped understand right renal artery anatomy and was used as guidance in order to negotiate the curve of the artery, enabling us to deliver radiofrequency satisfactory.

Acknowledgments

None declared.

Authors Contribution

EA-B, MS-M: conception and design EA-B, MC, RT, MV:processing the images EA-B, CDD, RM: drafting of the manuscript EA-B, RM, MS-M: final approval of the manuscript submitted.

Financial Disclosure

None declared.

Funding/Support

None declared.

References

1. Krousel-Wood M, Muntner P, Carson A, Anderson AH, Delaune E, Cushman WC, et al. Hypertension control among newly treated patients before and after publication of the main ALLHAT results and JNC 7 guidelines. *J Clin Hypertens (Greenwich).* 2012;**14**(5):277-83.
2. Czernichow S, Zanchetti A, Turnbull F, Barzi F, Ninomiya T, Kengne AP, et al. The effects of blood pressure reduction and of different blood pressure-lowering regimens on major cardiovascular events according to baseline blood pressure: meta-analysis of randomized trials. *J Hypertens.* 2011;**29**(1):4-16.
3. DiBona GF. Functionally specific renal sympathetic nerve fibers: role in cardiovascular regulation[ast]. *Am J Hypertens.* 2001;**14**(S3):163S-170S.
4. Esler M. The sympathetic nervous system through the ages: from Thomas Willis to resistant hypertension. *Exp Physiol.* 2011;**96**(7):611-22.
5. Noll G, Wenzel RR, Schneider M, Oesch V, Binggeli C, Shaw S, et al. Increased activation of sympathetic nervous system and endothelin by mental stress in normotensive offspring of hypertensive parents. *Circulation.* 1996;**93**(5):866-9.
6. Symplicity H.T.N.I., Esler M.D., Krum H., Sobotka P.A., Schlaich M.P., chmieder R.E., et al. Renal sympathetic denervation in patients with treatment-resistant hypertension (The Symplicity HTN-2 Trial): a randomised controlled trial. *The Lancet.* 2010;**376**(9756):1903-9.
7. Krum H, Schlaich MP, Whitbourn R, Sobotka PA, Sadowski J, Bartus K, et al. Catheter-based renal sympathetic denervation for resistant hypertension: a multicentre safety and proof-of-principle cohort study. *The Lancet.* 2009;**373**(9671):1275-1281.
8. Mahfoud F, Schlaich M, Kindermann I, Ukena C, Cremers B, Brandt MC, et al. Effect of renal sympathetic denervation on glucose metabolism in patients with resistant hypertension: a pilot study. *Circulation.* 2011;**123**(18):1940-6.
9. Schlaich MP, Sobotka PA, Krum H, Lambert E, Esler MD. Renal sympathetic-nerve ablation for uncontrolled hypertension. *N Engl J Med.* 2009;**361**(9):932-4.
10. Krum H, Schlaich M, Whitbourn R, Sobotka PA, Sadowski J, Bartus K, et al. Catheter-based renal sympathetic denervation for resistant hypertension: durability of blood pressure reduction out to 24 months. *Hypertension.* 2011;**57**(5):911-7.