

Case Report

Safe Right Bundle Branch Block Pattern During Permanent Right Ventricular Pacing

Yung-Nien Yang, MD,* Wei-Hsian Yin, MD,[†] and
Mason Shing Young, MD[‡]

Abstract: It is known that an electrocardiogram (ECG) after transvenous right ventricular (RV) pacing should yield left bundle branch block (LBBB) QRS patterns. When right bundle branch block (RBBB) pacing morphology appears in a patient with a permanent or temporary transvenous RV pacemaker, myocardial perforation or malposition of the pacing lead must be ruled out, even though the patient may be asymptomatic. We report a case of a 77-year-old man who underwent permanent transvenous VDD pacemaker implantation for symptomatic heart block. The postoperative ECG revealed a RBBB pacing configuration, but his chest X-ray and echocardiographic studies confirmed uncomplicated RV pacing. We review and discuss the literature concerning the differential diagnosis of such a safe RBBB ECG pattern. **Key words:** Ventricular pacing, right bundle branch block, pacing lead.

Transvenous right ventricular pacing usually shows a left bundle branch block (LBBB) pattern. When right bundle branch block (RBBB) configurations appear after the insertion of an electrode, a complication (perforation or malposition of the pacing lead) has usually occurred (1-5). In the patient reported here, uncomplicated right ventric-

ular (RV) pacing produced a RBBB configuration. It is clinically important to determine whether or not a RBBB pattern induced by RV pacing is the result either of perforation of the right ventricle or of an abnormal lead position.

Case Presentation

A 77-year-old man was admitted for treatment of exertional dyspnea and fatigability that had been occurring over several months. He had not previously sought medical consultation for these symptoms because he considered them to be due to his severe chronic obstructive pulmonary disease. However, the symptoms had gotten worse, and he had noticed that his heart rate was low (he had

*From the *Division of Cardiology, Department of Internal Medicine, Armed Forces Sung-Shan Hospital; and †Division of Cardiology; ‡Department of Internal Medicine, Cheng-Hsin General Hospital, Institute of Clinical Medicine, National Yang-Ming University School of Medicine, Taipei, Taiwan, R.O.C.*

Reprint requests: Wei-Hsian Yin, MD, Division of Cardiology, Department of Internal Medicine, Cheng-Hsin General Hospital, 45 Cheng-Hsin St, Pei-Tou, Taipei, Taiwan, R.O.C.; e-mail: yin.wh@msa.hinet.net.

Copyright 2003, Elsevier Science (USA). All rights reserved.
0022-0736/03/3601-0009\$35.00/0
doi:10.1054/jelc.2003.50002

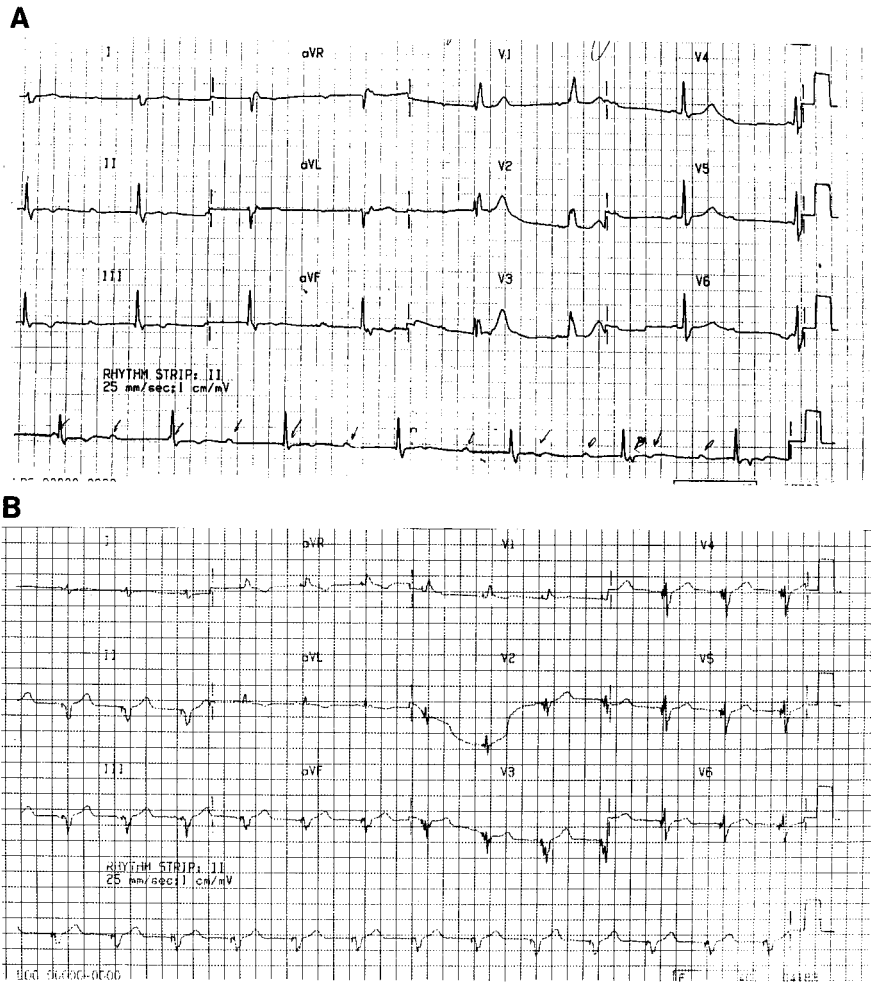


Fig. 1. (A) The initial ECG showed complete heart block with a complete RBBB pattern and an escape rhythm at a rate of 45/min. (B) The postoperative ECG showed an unusual RBBB pattern with RV1 and S1 and a frontal axis around -90° during atrial-tracking ventricular pacing.

taken his own pulse and found it to be below 50 beats per minute); this had prompted him to visit our outpatient clinic. Physical examination was unremarkable except for the presence of Canon A waves over the right internal jugular vein and diminished breathing sounds over both lung fields. The initial electrocardiogram (ECG) showed complete heart block with a complete RBBB pattern and an escape rhythm at a rate of 45/min (Fig. 1A). A transvenous single-pass VDD permanent pacemaker (THERA 8968i, Medtronic, Inc, Minneapolis, MN), using a bipolar lead (CAPSURE VDD-2 5038-58 cm, Medtronic, Inc), was implanted smoothly through the left subclavian vein. The stimulation threshold was 0.2 V at 0.5 ms, the R-wave amplitude was 15.0 mV, the P-wave amplitude was 2.6 mV, and the impedance was 772 ohms. The postoperative course was uneventful and the patient was doing well. However, an unusual RBBB pattern on follow-up ECG with RV1 and S1 and a frontal axis around -90° during ventricular pacing was shown (Fig. 1B). Chest roent-

genographic (Figs. 2A and B) studies revealed no RV free wall or septal perforation, and the echocardiogram clearly shows the VDD pacing lead going from the right atrium to the right ventricle (Fig. 3A) and lying in the right ventricular apex (Fig. 3B). The patient had been followed-up for 18 months as of this writing, and there have been no adverse cardiac events.

Discussion

The simplified view is that RV pacing should always yield a LBBB configuration (and that left ventricular (LV) pacing should always yield a RBBB configuration). The QRS complex may change from LBBB to RBBB in cases of perforation of the free RV wall or of the interventricular septum by the pacing lead (1, 2). Placement of the pacing lead in the coronary sinus may also yield a RBBB configuration (3); less commonly, malposition may occur when

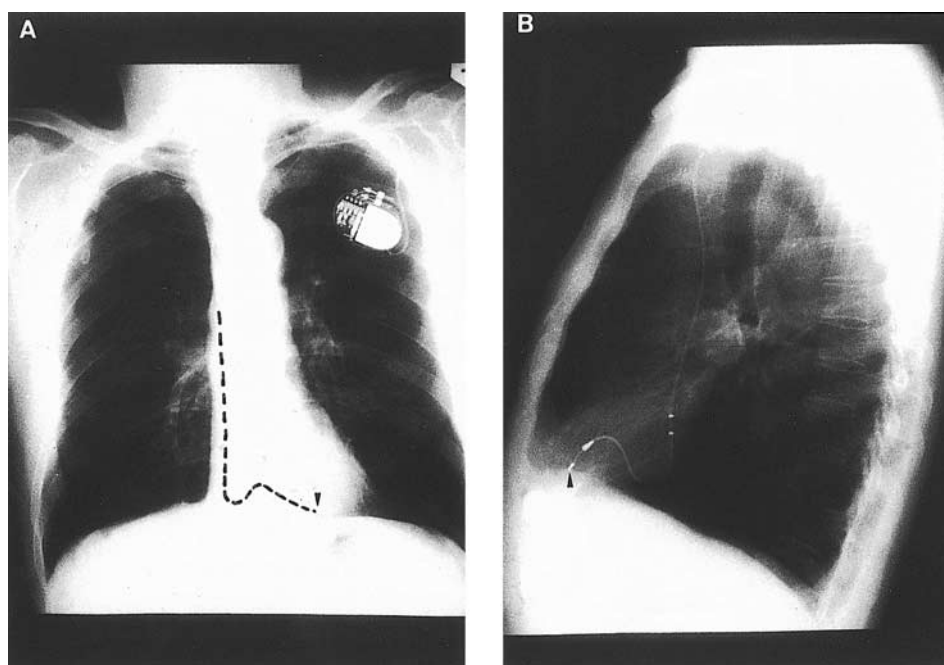


Fig. 2. Chest radiography, including (A) PA and (B) lateral views, demonstrated no RV free wall or septal perforation.

the lead perforates the interatrial septum, or is passed through an atrial septal defect inadvertently, and extends across the left atrium and through the mitral valve into the left ventricle (4). LV pacing may also develop as a result of inadvertent transarterial placement that allows the lead to cross the aortic valve and enter the LV cavity (5). On rare occasions, however, RBBB patterns may occur in RV pacing despite correct placement of the pacing lead. Patients with RBBB configurations after transvenous RV pacing require careful evaluation to differentiate between cases of correct lead place-

ment and those of malplacement or myocardial perforation, because inappropriate revision of anticoagulation may be hazardous and must be avoided.

In 1985, Klein et al. (6) reported eight patients with RBBB patterns in leads V1 and V2, left bundle branch block patterns in lead I, and pacing leads located in the RV apex. They named this the “pseudo-RBBB” pattern, and suggested that it indicates that depolarization of the right ventricle precedes activation of the left ventricle, and therefore that perforation or malposition of the pacing lead

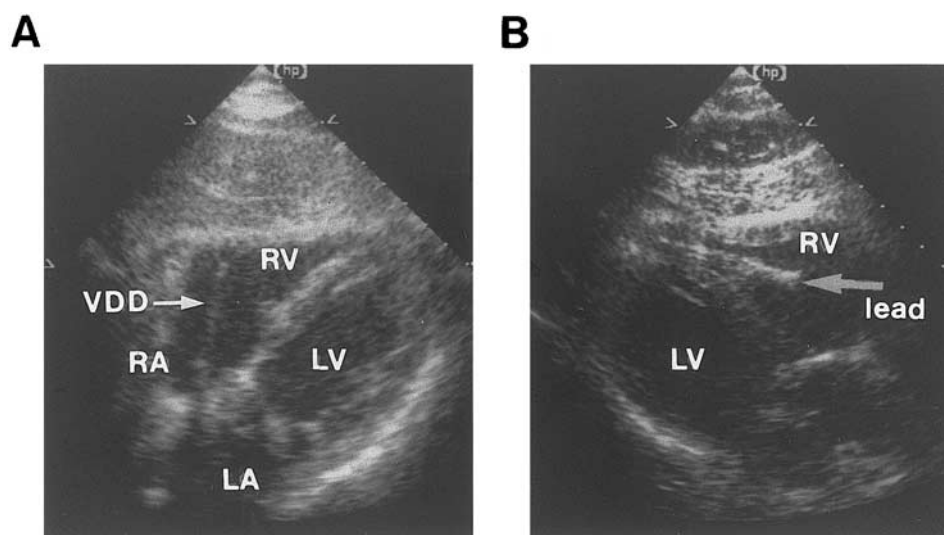


Fig. 3. Echocardiography shows (A) the pacing lead going from the right atrium to the right ventricle in a subcostal four-chamber view, and (B) the tip of the lead lying in the right ventricular apex (parasternal long axis view). RA, right atrium; RV, right ventricle; LA, left atrium; LV, left ventricle.

has not taken place. They also recognized that placement of leads V1 and V2 one interspace lower than standard will usually, as their experience shows, eliminate the RBBB appearance and result in the inscription of deep QS or rS complexes in V1-V2. On the other hand, placing the leads one space higher than the usual space will further enhance the height of the R wave (6). Coman et al reported seven similar cases; each of them had pacing leads located in the distal RV septum or apex (7). In our case, the R wave at V1 and V2 could not be eliminated by moving leads V1 and V2 one intercostal space below the standard position (data not shown). Coman et al (7) reported four patients whose RBBB pattern could not be eliminated by movement of leads V1 and V2; each of them had pacing leads located in the midseptum. Our case was different because the chest radiography and echocardiography confirmed RV apical pacing.

As Friedberg reported, a RBBB pattern in RV pacing with a maximal QRS vector oriented to the left, superior and anterior, may indicate uncomplicated RV pacing, whereas a RBBB pattern with the maximal QRS vector oriented to the right, inferior and posterior, may be a warning sign of perforation of the right ventricle (8). In 1995, Coman et al (7) developed an algorithm to separate RV and LV RBBB pacing morphologies using the aforementioned concepts and biaxial (frontal axis and precordial transition) data. They suggested that after excluding LV pacing from the proximal and mid septum, a frontal axis of 0° to -90° and precordial transition by V3 separates uncomplicated RV septal or apical pacing from all other forms of LV pacing with 86% sensitivity, 99% specificity, and 95% positive predictive value. The same frontal axis of 0° to -90° , but precordial transition after V4, indicates pacing in the middle cardiac vein or posterior and posterolateral wall of the left ventricle (sensitivity 72%, specificity 100%, positive predictive value 100%). Frontal axes between -90° and -180° or between 90° and 180° indicate other locations of LV pacing (7). In our patient, the frontal axis was around -90° and precordial transition by V3. Applying the criteria of Coman and Klein, we considered that such a borderline frontal axis calculation, and the fact that the R wave could not be eliminated by moving leads V1 and V2 as described, did not, on its own, satisfactorily determine safe RV pacing. We therefore arranged chest roentgenographic and echocardiographic studies for confirmation.

As to the mechanism of the RBBB patterns in cases where the lead is normally placed, several hypotheses have been proposed. Lister et al. (9) postulated that the left ventricle is activated first

through numerous abnormal pathways when the right ventricle is paced. Mower et al. (10) suggested that the pacemaker stimulus may enter the right bundle branch and then travel in a retrograde direction to the A-V junction and down the left bundle branch. An alternative explanation offered by Mower, based on the anatomic and septal activation time studies of Sodi-Pallares, suggested that portions of the interventricular septum which are anatomically right ventricle may behave functionally and electrically as left ventricle (10). Barold et al. (11) suggested that the RBBB pattern could be the result of a combination of RV activation delay due to severe disease of the RV conduction system and early penetration of the electrical impulse into the LV conduction system. However, not all cases with RBBB patterns in the absence of malposition of the pacing lead can be explained by these hypotheses (12). The pre-existing RBBB on the initial ECG in our case suggests that RV activation delay was present before pacemaker implantation, probably secondary to his chronic obstructive pulmonary disease. The postoperative RBBB pattern may be the result of early penetration of the electrical impulse to the left ventricle and RV activation delay due to disease of the RV conduction system, as Barold et al suggested.

In conclusion, in cases of RBBB patterns after transvenous RV pacing, one should analyze the 12-lead ECG morphologies to differentiate safe RV pacing from complications or malposition. On the other hand, chest X-rays (including PA and lateral views) and echocardiography can greatly facilitate the recognition of lead position in cases of doubt.

References

1. Ormond RS, Rubenfire M, Anbe DT, et al: Radiographic demonstration of myocardial perforation by permanent endocardial pacemaker. *Radiology* 98:35, 1971
2. Stillman MT, Richards AMD: Perforation of the interventricular septum by transvenous pacemaker catheter. *Am J Cardiol* 24:269, 1969
3. Meyer JA, Millar K: Malplacement of pacemaker catheters in the coronary sinus. *J Thorac Cardiovasc Surg* 57:511, 1969
4. Ghani M, Thakur RK, Boughner D, et al: Malposition of transvenous pacing lead in the left ventricle. *PACE* 16:1800, 1993
5. Mazzetti H, Dussaut A, Tentori C, et al: Transarterial permanent pacing of the left ventricle. *PACE* 13:588, 1990
6. Klein HO, Beker B, Sareli P, et al: Unusual QRS

- morphology associated with transvenous pacemaker. *Chest* 87:517, 1985
7. Coman JA, Trohman RG: Incidence and electrocardiographic localization of safe right bundle branch block configuration during permanent ventricular pacing. *Am J Cardiol* 76:781, 1995
 8. Friedberg HD: Evaluation of unusual QRS complexes produced by pacemaker stimuli-with special reference to the vectorcardiographic and echocardiographic findings. *J Electrocardiol* 13:409, 1980
 9. Lister JW, Klotz DH, Jomain SL, et al: Effect of pacemaker site on cardiac output and ventricular activation in dogs with complete heart block. *Am J Cardiol* 14:494, 1964
 10. Mower MM, Aranaga CE, Tabatznik B: Unusual patterns of conduction produced by pacemaker stimuli. *Am Heart J* 74:24, 1967
 11. Barold SS, Narula OS, Javier RP, et al: Significance of right bundle-branch block patterns during pervenous ventricular pacing. *Br Heart J* 31:285, 1969
 12. Bauman DJ, Lamb KC, Tsagaris TJ: Unusual QRS wave forms associated with permanent pacemakers. *Chest* 64:480, 1973