

A Rare Ocular Complication After a Heart Transplant: Toxoplasma Retinitis

Umit Kervan,¹ Yasemin Ozdamar,² Okan Yurdakok,¹ Seref Alp Kucuker,¹ Mustafa Pac¹

Abstract

Ocular infections after a heart transplant are rare; but when present, they generally appear during the first year after surgery. Ocular infections may cause significant loss of vision and morbidity if not diagnosed early. For that reason, heart transplant patients should undergo a routine visual examination during follow-up.

We report our experience regarding the follow-up and treatment of a case of toxoplasma retinitis diagnosed in one of our heart transplant recipients.

Key words: Heart transplant, toxoplasmosis, retinitis

Introduction

Heart transplant remains the criterion standard for the end-stage heart failure patients. As the number of patients undergoing heart transplants increases, the number of patients experiencing complications increases, as well. Also, the number and variety of complications increases in parallel to the variety of immunosuppressive drug protocols that have the potential for different adverse effects. Ocular complications after solid-organ transplants are generally reported to be 2% of all complications, and opportunistic infections are the leading cause (58%).¹ Toxoplasma retinitis is rare, with an incidence of 0.8%.²

Case Report

A 51-year-old man underwent an orthotopic heart transplant for dilated cardiomyopathy. Post-

operatively, he received our routine, 3-drug, immunosuppressive protocol consisting of cyclosporine, corticosteroids, and mycophenolate mofetil. Also, he received 20 mg basiliximab as induction therapy before the sternotomy, and on the fourth day after surgery. Four grams per day intravenous cephazolin sodium was administered as antibiotic prophylaxis, divided into 4 doses, and continued until all the chest tubes had been removed.

The results of preoperative *Toxoplasma gondii* serology, IgM, and IgG antibodies were negative. For the first 6 months after the transplant, he also was given prophylaxis for atypical infections; 960 mg/day trimethoprim and sulfamethoxazole (TMP-SMX) for *Pneumocystis carinii* prophylaxis, 1000 mg/day valacyclovir hydrochloride for prophylaxis of *cytomegalovirus*, and nystatin mouth rinse 3 times daily for fungal infections.

The patient was discharged 29 days after surgery. The results of his first 2 biopsies, immunosuppressive drug levels, and end-organ functions all were within the normal ranges. For the first 6 months after the transplant, the patient was called in for monthly clinic visits, and once every 3 months after that. During follow-up, a detailed physical and laboratory examination, including an electrocardiography and a transthoracic echocardiography were made, and a biopsy was obtained from the patient according to our institutional protocol. Thirteen months after surgery, the patient's cyclosporine was switched to everolimus because of deteriorating kidney functions, which resolved afterwards.

One month after the change in his immunosuppressive drug regimen, he returned complaining that his left eye had visual floaters, and there was a sudden decrease in vision. He was seen by an ophthalmologist, and the examination revealed a visual acuity of 10/20 in the left eye. A funduscopy

From the ¹Cardiovascular Surgery Clinic, Türkiye Yüksek İhtisas Education and Research Hospital; and the ²Uluçanlar Eye Education and Research Hospital, Eye Clinic, Ankara, Turkey

Acknowledgements: The authors have no conflicts of interest to declare.

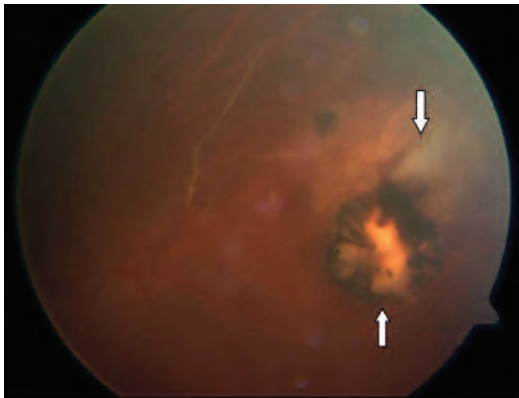
Corresponding author: Umit Kervan MD, Türkiye Yüksek İhtisas Education and Research Hospital, Cardiovascular Surgery Clinic 06100 Sıhhiye/Ankara, Turkey

Phone: +90 312 306 12 42 Fax: +90 312 310 03 78 E-mail: drukervan@yahoo.com

Experimental and Clinical Transplantation (2014) 1: 78-80

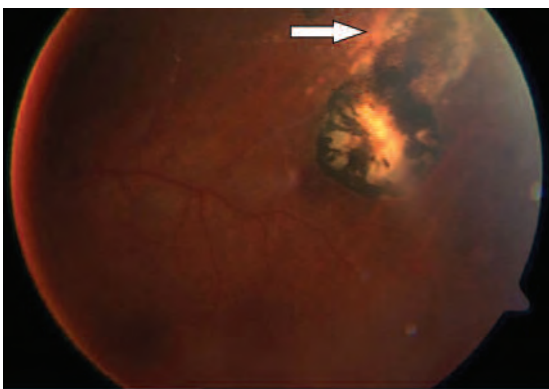
examination showed a scar, which was 2 disk areas in size in the upper peripheral retinal region, close to a focal necrotizing retinitis with vasculitis, which had a 2+ vitreous cell in the left eye. The other retinal sites of the left eye were within the normal limits (Figure 1). An examination of the right eye was also within normal limits.

Figure 1. Funduscopy Before Treatment



Upper arrow depicts active TR area. Lower arrow shows scars at the upper peripheral retinal region and a close focal necrotizing retinitis.

Figure 2. Funduscopy 2 Months After Diagnosis



Arrow showing healed chorioretinitis area.

The laboratory tests showed positive results for high serum titers of antitoxoplasma IgM antibodies, and negative results for the other opportunistic infection antibodies like *cytomegalovirus* and syphilis. He was diagnosed as having *Toxoplasma gondii* retinitis (TR) and was started on systemic antibiotics: azithromycin 250 mg/d, and trimethoprim and sulfamethoxazole 160 to 800 mg/d for 5 weeks. The patient's steroid dosage was increased from 5 mg/d to 20 mg/d, and then tapered to 5 mg/d by the end of the third week. The patient was closely followed, and his complaints began to get better after 1 month, and disappeared by the second

month. Visual acuity of the left eye went back to 20/20, and a funduscopy examination showed a healing lesion, leaving chorioretinal atrophy behind (Figure 2). At the time of this writing (28 months after the transplant), the patient is doing well on routine follow-up.

Discussion

Immunosuppressive drug regimens used after solid-organ transplants almost always consist of multiple drugs, given at high dosages, and these different immunosuppressive agents create a predisposition toward a variety of opportunistic infections. Ng and associates presented the results of 860 patients who underwent a heart, lung, heart-lung, or liver transplant, and reported their ocular complications as 2.2%.³ Ocular complications after a heart transplant are rare, but generally manifest as ocular infections that are mostly viral retinitis of the *Herpesviridae* (42%), followed by fungal chorioretinitis (11%).¹ Retinitis caused by TR is rare, as Gallino and associates reported only 1 patient (0.8%) with TR out of 121 heart transplant recipients.² Conrath and associates⁵ describe 4 patients (2.2%) with TR among 175 heart transplant recipients. The present case is the first incidence of TR in our series of 74 heart transplant patients.

The major risk factor for acquiring a TR is a transplant from a seropositive donor to a seronegative recipient.⁴ Other common causes are eating contaminated food, receiving blood bank derivatives (contaminated with TR5 corticosteroid use in the immunosuppressive protocol), and presence of a *cytomegalovirus* infection.⁶ Couvreur and associates showed that TR has an affinity for myocardial cells.⁷

Ocular infections may manifest in the next few months or years after a transplant but generally, fungal infections occur earlier than viral infections. The literature on ocular infections shows that these infections generally appear during the first 18 months after a transplant.⁸ For that reason, we believe that heart transplant patients should undergo routine ocular examination every 3 to 6 months for the first 18 months.

Our patient was diagnosed with TR 15 months after his heart transplant. The guidelines recommend TMP-SMX prophylaxis during the initial phase, when patients are under high-dose immuno-

suppressant therapy. The use of prophylactic primetamin, especially for seronegative patients, has been shown to reduce TR infections by 14% (to 57%).^{5,7,8} Extending prophylaxis for opportunistic infections up to 18 months may be helpful, but we must consider the adverse effects of the medication. Patients receiving the highest dosages of immunosuppressants during the first 6 months (where the risk of opportunistic infections are at their peak) must have their dosages tapered, until the drugs can be discontinued. The risk of opportunistic infections is lower after the first 6 months after a heart transplant, and there may be no need for prophylaxis for all the transplant patients after 6 months. We also prefer to give the prophylaxis for opportunistic infections during their highest risk, or during the first 6 months. In this patient, the TR occurred 14 months after the transplant. There was a recent immunosuppressive drug change just before this diagnosis. The increased risk of infection or rejection is a well-known phenomenon that happens frequently around switching drugs.

We believe there are 2 take-home messages from this case report. The first is that close follow-up after transplant carries great importance in preventing any permanent graft or end-organ damage. We added an ocular examination every 3 to 6 months to our follow-up protocol for the first 18 months to diagnose

any possible ocular infections. Secondly, for patients who need their immunosuppressive drugs switched to another agent, a 1-month to a 3-month course of prophylactic drug administration for opportunistic infections may be considered.

References

1. Akerele T, Lightman S. Ocular complications in heart, lung and heart-lung recipients. *Br J Ophthalmol*. 2007;91(3):310-312.
2. Gallino A, Maggiorini M, Kiowski W, et al. Toxoplasmosis in heart transplant recipients. *Eur J Clin Microbiol Infect Dis*. 1996;15(5):389-393.
3. Ng P, McCluskey P, McCaughan G, Glanville A, MacDonald P, Keogh A. Ocular complications of heart, lung, and liver transplantation. *Br J Ophthalmol*. 1998;82(4):423-428.
4. Mechain B, Garin YJ, Robert-Gangneux F, Dupouy-Camet J, Derouin F. Lack of utility of specific immunoglobulin G antibody avidity for serodiagnosis of reactivated toxoplasmosis in immunocompromised patients. *Clin Diagn Lab Immunol*. 2000;7(4):703-705.
5. Conrath J, Mouly-Bandini A, Collart F, Ridings B. Toxoplasma gondii retinochoroiditis after cardiac transplantation. *Graefes Arch Clin Exp Ophthalmol*. 2003;241(4):334-338.
6. Luft BJ, Naot Y, Araujo FG, Stinson EB, Remington JS. Primary and reactivated toxoplasma infection in patients with cardiac transplants. Clinical spectrum and problems in diagnosis in a defined population. *Ann Intern Med*. 1983;99(1):27-31.
7. Couvreur J, Tournier G, Sardet-Frismand A, Fauroux B. Heart or heart-lung transplantation and toxoplasmosis [in French]. *Presse Med*. 1992;21(33):1569-1574.
8. Del Pozo JL, van de Beek D, Daly RC, Pulido JS, McGregor CG, Patel R. Incidence and clinical characteristics of ocular infections after heart transplantation: a retrospective cohort study. *Clin Transplant*. 2009;23(4):484-489.