

cellulitis; 2 were on treatment with corticosteroids<sup>2,5</sup> and 1 with infliximab.<sup>8</sup>

The treatment of choice is intravenous amphotericin-B, with or without oral flucytosine, although fluconazole and itraconazole are also currently used as alternatives to amphotericin-B as they are equally effective but have fewer adverse effects.<sup>9</sup>

In conclusion, cellulitis caused by *Cryptococcus neoformans* is an infrequent presentation of cryptococcosis in immunosuppressed patients and is clinically indistinguishable from bacterial cellulitis. Cellulitis can be the primary manifestation of cryptococcal infection or even the first manifestation of disseminated cryptococcosis, as in our patient; we must therefore rule out hematogenous dissemination and begin immediate antifungal treatment. Cellulitis in an immunosuppressed patient with disseminated disease or involvement of several anatomic sites should suggest a possible opportunistic microorganism as the etiologic agent. Disseminated cryptococcosis is usually fatal if appropriate treatment is not administered. Thus, mycological culture and skin biopsy revealing the characteristic microorganisms will help to guide us toward the correct pharmacological treatment, leading to improvements in the patient's prognosis.

## References

1. Bauzá A, Redondo P, Rubio M. Primary cutaneous cryptococcal cellulitis secondary to insect bite in an immunosuppressed patient after liver transplantation. *Clin Exp Dermatol.* 2005;30:241-3.
2. Lu HC, Yang YY, Huang YL, Chen TL, Chuang CL, Lee FY, et al. Disseminated cryptococcosis initially presenting as cellulitis in a rheumatoid arthritis patient. *J Chin Med Assoc.* 2007;70:249-52.
3. Posada C, de la Torre C, González-Sixto B, Cruces MJ. Criptococosis cutánea primaria en paciente oncológico

siguiendo un patrón esporotricóide. *Actas Dermosifiliogr.* 2009;100:78-80.

4. Hafner C, Linde HJ, Vogt T, Breindl G, Tintelnot K, Koellner K, et al. Primary cutaneous cryptococcosis and secondary antigenemia in a patient with long-term corticosteroid therapy. *Infection.* 2005;33:86-9.
5. Moosbrugger EA, Adams BB, Kralovic SM. Cutaneous cryptococcosis in a patient on corticosteroid therapy for rheumatoid arthritis. *Int J Dermatol.* 2008;47:630-2.
6. Neuville S, Dromer F, Morin O, Dupont B, Ronin O, Lortholary O, French Cryptococcosis Study Group. Primary cutaneous cryptococcosis: a distinct clinical entity. *Clin Infect Dis.* 2003;36:337-47.
7. Sico JJ, Hughes E. Necrotising cryptococcal vasculitis in an HIV-negative woman. *Mycoses.* 2006;49:152-4.
8. Kozic H, Riggs K, Ringpfeil F, Lee JB. Disseminated *Cryptococcus neoformans* after treatment with infliximab for rheumatoid arthritis. *J Am Acad Dermatol.* 2008;58(Suppl 1):S95-6.
9. Sánchez-Albisua B, Rodríguez-Peralto JL, Romero G, Alonso J, Vanaclocha F, Iglesias L. Cryptococcal cellulitis in an immunocompetent host. *J Am Acad Dermatol.* 1997;36:109-12

C. Diaz-Sarrió,<sup>a,\*</sup> X. García-Navarro,<sup>a</sup> G. Claver-Cercós,<sup>b</sup> J.M. Baucells-Azcona,<sup>b</sup> C. Martín-Plata,<sup>c</sup> and M. Corcoy-Grabalosa<sup>d</sup>

<sup>a</sup>Servicio de Dermatología, Consorci Sanitari Garraf, Hospital Sant Camil, Sant Pere de Ribes, Barcelona, Spain

<sup>b</sup>Servicio de Medicina Interna, Consorci Sanitari Garraf, Hospital Sant Camil, Sant Pere de Ribes, Barcelona, Spain

<sup>c</sup>Servicio de Anatomía Patológica, Consorci del Laboratori Intercomarcal de l'Alt Penedès, l'Anoia i el Garraf, Barcelona, Spain

<sup>d</sup>Servicio de Microbiología, Consorci del Laboratori Intercomarcal de l'Alt Penedès, l'Anoia i el Garraf, Barcelona, Spain

\*Corresponding author.

E-mail: carmediatz@eresmas.net (C. Diaz-Sarrió).

## Rat-bite Fever: A Case in Spain With Skin Lesions

### Fiebre por mordedura de rata. Un caso en España con lesiones cutáneas características

To the Editor:

Rat-bite fever is a zoonosis of worldwide distribution produced by *Streptobacillus moniliformis* or *Spirillum minus* that colonize the rodent oropharynx. These are transmitted by percutaneous inoculation, although the *S. moniliformis* may also be transmitted by the ingestion of food contaminated with excrement, a condition known as Haverhill fever or *erythema arthriticum epidemicum*.<sup>1,2</sup> *S. minus* is only found in Asia and produces disorder known as Sodoku, with fever, inflammatory changes in the area of the bite, and regional lymphangitis.<sup>2</sup>

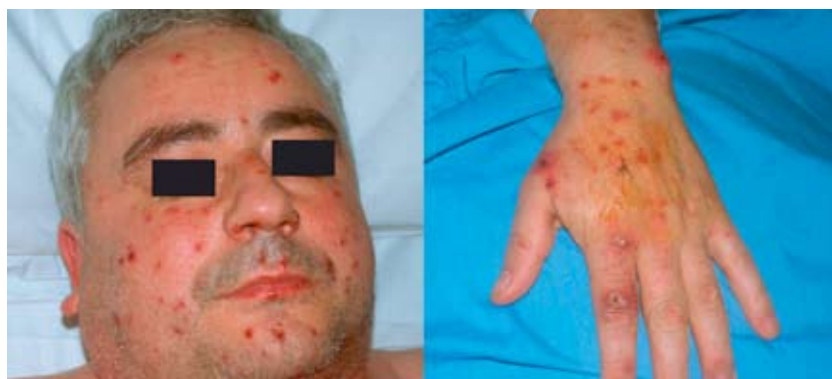In Spain the true incidence and prevalence of this illness is unknown. There are historical references to this condition

dating from 1947,<sup>3,4</sup> but only 6 cases have been documented in more recent times (3 arthritis, 1 subcutaneous abscess, and 2 bacteremias).<sup>5-7</sup>

We present the case of a 50-year-old male with mitral insufficiency secondary to subacute endocarditis, who consulted for a 10-day history of general malaise and fever, associated with diarrhea that resolved after a week. On the sixth day, lesions appeared on the hands; the lesions were initially papular and painful but progressed to pustules and also developed on the face and distal third of the legs. The patient also presented migratory arthralgias in the interphalangeal joints of the right hand and left knee, as well as odynophagia.

Elements of epidemiological interest in the past history included a visit to rural areas of Canada and Germany two months earlier, and the patient had been bitten by a wild rat 15 days earlier while working in the countryside. He reported no high-risk sexual practices.

On admission the patient presented a temperature of 39°C, he was hemodynamically stable, and there was a systolic murmur that radiated to the axilla.



**Figure 1** Polymorphic, purpuric, and necrotic lesions with pustular features, distributed in acral regions.

Dermatological examination revealed polymorphic skin lesions in an acral distribution affecting the face and the dorsum of hands and feet. The lesions both on the face and on the dorsum of the hands showed purpuric, papular, pustular, and necrotic features (Figure 1). There were a few purpuric lesions on distal third of the legs and on the feet, similar to those of septic vasculitis (Figure 2).

Blood tests revealed a leukocytosis of 11 700 (83% neutrophils) and an erythrocyte sedimentation rate of 100. Serology for Epstein-Barr virus, cytomegalovirus, varicella-zoster, herpes simplex 1 and 2, parvovirus B 19, human immunodeficiency virus, hepatitis B and C, toxoplasmosis, *Rickettsia conorii*, *Leptospira*, syphilis, *Borrelia*, and *Yersinia enterocolitica* were negative, as were tests for rheumatoid factor and antinuclear antibodies. Transesophageal echocardiogram showed no signs of active endocarditis. A skin biopsy was taken for histology and microbiology.

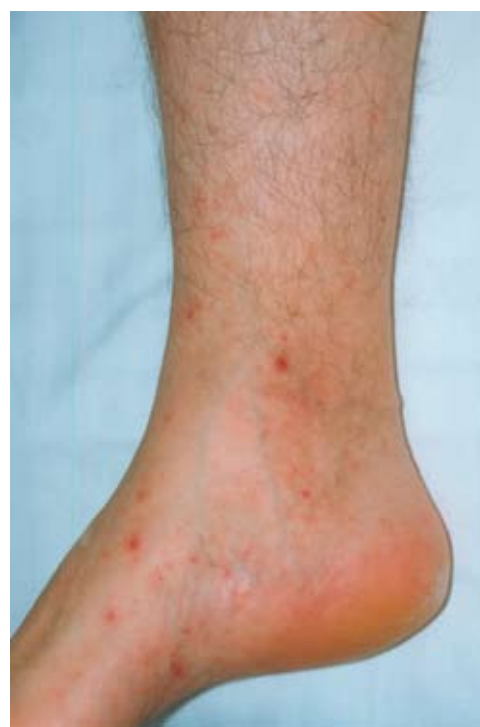Suspicious of bacteremia prompted blood cultures and empirical antibiotic treatment with cefotaxime was initiated, with remission of the condition within 48 hours.

Histology revealed abundant extravasated red blood cells in the dermis, prominent endothelial cells, and a predominantly lymphocytic perivascular inflammatory infiltrate.

The skin biopsy and the aerobic and anaerobic blood cultures produced slow growth of a small colony that showed a peculiar string of pearls growth pattern in fluid thioglycollate medium. Fried egg colonies were seen on the fifth day in trypticase soy medium enriched with bovine serum. Gram stain revealed highly pleomorphic gram negative bacilli (Figure 3).

Based on the history of a rat bite and the microbiological findings, the main etiological suspicion was *Streptobacillus moniliformis*. The National Microbiology Centre in Majadahonda, Spain, provided definitive identification of the microorganism using polymerase chain reaction.

Rat bite fever must be suspected in patients presenting fever, polyarthralgia, and polymorphic cutaneous lesions of rapid onset.<sup>1</sup> There is a possibility of underdiagnosis in Spain, as low levels of clinical suspicion mean that specific questions about prior contact with rodents are rarely included in the history.

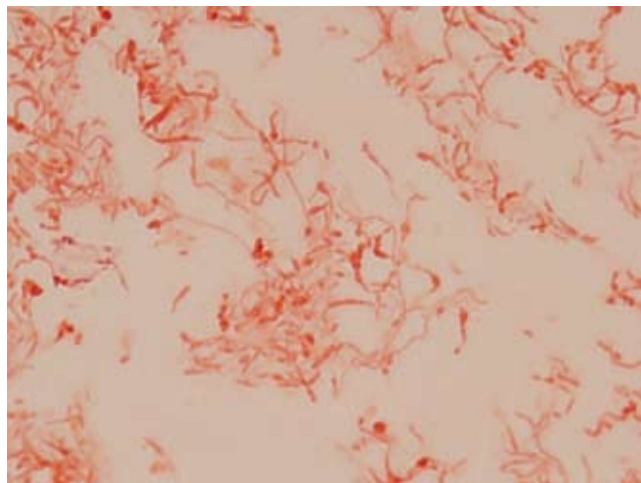


**Figure 2** Small purpuric lesions on the legs, suggestive of septic vasculitis.

*Streptobacillus moniliformis* colonizes the oropharynx of rats, mice, ferrets, squirrels, and guinea pigs.<sup>2</sup> It is transmitted by bite or exposure to saliva or excrement. In 30% of cases no contact can be proven.<sup>2</sup>

The increasing number of pet rodents has increased the prevalence of rat bite fever and it is now considered an emerging disease.<sup>8</sup> The groups most affected are children (50% of cases), laboratory technicians, farmers, and veterinarians.<sup>2,5</sup>

Clinical manifestations include high fever for 3 days to 3 weeks after the bite, accompanied by headaches, nausea, vomiting, odynophagia, and myalgia. The area of the bite has usually healed by then.<sup>1,2</sup>



**Figure 3** Gram stain revealing pleomorphic gram-negative bacilli.

The skin lesions appear a few days later, in an acral distribution in 75% of cases and with morphology similar to the case presented here.<sup>2</sup>

Migratory asymmetric polyarthralgia appears in 50% of patients and can affect any joint,<sup>2</sup> although the knees are most commonly involved.<sup>1</sup> Arthritis, when it develops, tends to be aseptic, although cases have been reported in which *S. moniliformis* has been isolated from the synovial fluid.<sup>9</sup>

Additional tests do not provide any specific data and diagnosis requires isolation and identification of the responsible microorganism using bacteriological culture of the blood, skin, and synovial fluid.<sup>6</sup>

*S. moniliformis* requires special media and conditions for culture, hence the microbiologist must be informed of the history of contact with rodents.<sup>2</sup> The result can be confirmed by gas liquid chromatography analysis of the fatty acid profile or by polymerase chain reaction-based amplification and sequencing of the 16S rRNA gene.<sup>1,6</sup>

Where there is no history of exposure to rodents, infections such as bacteremia due to gram-positive cocci, gonococemia, meningococemia, rickettsiosis, or secondary syphilis must be excluded.<sup>1,2</sup> Non-infectious diseases such as the neutrophilic dermatoses or certain toxic dermatoses can cause similar symptoms. Where there is a history of exposure, the options are reduced to leptospirosis and rat bite fever.<sup>1</sup>

When a patient is left untreated the condition can be self-limiting or recurrent; it is a cause of a fever of unknown origin.<sup>1,2</sup> Arthritis can persist, simulating a rheumatologic condition.<sup>10</sup> If left untreated, mortality ranges between 7% and 13%,<sup>2,9,11</sup> and complications such as endocarditis can occur.<sup>12</sup> In our patient, endocarditis had to be ruled out due to a history of valvulopathy.

Treatment must begin promptly with a 7-day course of intravenous penicillin G, followed by a further 7-days of oral penicillin V.<sup>2</sup> Endocarditis is treated with a 4-week

course of high-dose intravenous penicillin in combination with an aminoglycoside.<sup>10</sup> Oral tetracycline is recommended in patients allergic to beta-lactam antibiotics.<sup>1</sup> In our case, cephalosporins were administered in order to empirically cover other diagnostic possibilities.

Finally, it is important to point out this is the first documented case of rat bite fever in which the microorganism has been isolated from the skin biopsy, the third case in Spain with bacteremia, and the first documented in the Galicia region of northern Spain.

## References

1. Washburn RG. *Streptobacillus moniliformis* (rat-bite fever). In: Mandell GL, Bennett JE, Dolin R, editors. Mandell, Douglas and Bennett's principles and practice of infectious diseases 6. New York: Churchill Livingstone; 2005; 2708-10.
2. Elliott SP. Rat bite fever and *Streptobacillus moniliformis*. Clin Microbiol Rev. 2007;20:13-22.
3. Navarro Martín A, Cadiñanos JM. Un caso de Sódoku (fiebre por mordedura de ratas). Actas Dermosifiliograf. 1947;38:333-45.
4. Salva Miguel JA. Consideraciones a propósito de un caso de fiebre por mordedura de rata. Actas Dermosifiliograf. 1947;38:406-10.
5. Anglada A, Comas L, Euras JM, Sanmartí R, Vilaró J, Brugués J. Arthritis caused by *Streptobacillus moniliformis*: a case of fever induced by a rat bite. Med Clin (Barc). 1990;94:535-7.
6. Torres L, López AL, Escobar S, Marne C, Marco ML, Pérez M, et al. Bacteremia by *Streptobacillus moniliformis*: first case described in Spain. Eur J Clin Microbiol Infect Dis. 2003;22: 258-60.
7. Acha V, Jiménez E, Casas J, Torroba L. Fiebre aguda por mordedura de rata. An Sist Sanit Navar. 2002;25:205-8.
8. Graves MH, Janda JM. Rat-bite fever (*Streptobacillus moniliformis*): a potential emerging disease. Int J Infect Dis. 2001;5:151-5.
9. Dendle C, Woolley IJ, Korman TM. Rat-bite fever septic arthritis: illustrative case and literature review. Eur J Clin Microbiol Infect Dis. 2006;25:791-7.
10. Legout L, Senneville E, Mulleman D, Solau-Gervais E, Flipo RM, Mouton Y. Rat bite fever mimicking rheumatoid arthritis. Scand J Infect Dis. 2005;37:532-3.
11. Freels LK, Elliott SP. Rat bite fever: three cases reports and a literature review. Clin Pediatr (Phila). 2004;43:291-5.
12. Rupp ME. *Streptobacillus moniliformis* endocarditis: case report and review. Clin Infect Dis. 1992;14:769-72.

J.M. Barja,<sup>a,\*</sup> L. Castelo,<sup>b</sup> M. Almagro,<sup>a</sup> E. Sánchez-Vidal,<sup>b</sup> A. Fernández-González,<sup>c</sup> F. Peña-Rodríguez,<sup>c</sup> J. García-Silva,<sup>a</sup> and E. Fonseca<sup>a</sup>

<sup>a</sup>Servicio de Dermatología, Complejo Hospitalario Universitario de A Coruña, A Coruña, Spain

<sup>b</sup>Servicio de Enfermedades Infecciosas, Complejo Hospitalario Universitario de A Coruña, A Coruña, Spain

<sup>c</sup>Servicio de Microbiología, Complejo Hospitalario Universitario de A Coruña, A Coruña, Spain

\*Corresponding author.

E-mail address: juanmabarja@yahoo.es (J.M. Barja).