disease. There can be little doubt but that the cerebellar lesion preceded the vomiting attacks, which first appeared in the end of 1880, five years before death. Vomiting was an early as well as a late symptom, and, according to the description given by the patient, was of uniform character, and it latterly was of distinctly central origin; (2.) The mode of growth of the tumour, which could clinically be divided into three stages—the first, of onset, from autumn 1880 to summer 1882, corresponding to the period of tumour formation; the second, of comparative latency, to the beginning of 1884; and the third, of recurrence, from this time until death. During the third period there must have been rapid cyst formation, and consequently greatly increasing intra-cranial pressure; (3.) The severity of vomiting as a symptom of cerebellar disease, and which, together with the respiratory and vaso-motor symptoms, were doubtless the result of irritation of adjacent centres in the medulla; (4.) The almost complete absence of vertigo. In the treatment the administration of iodides, with a free use of laxatives, was often of great benefit—anti-syphilitics had no appreciable effect.

2. A CASE OF CEREBELLAR TUMOUR OF UNUSUAL CLINICAL AND PATHOLOGICAL INTEREST.

By Byrom Bramwell, M.D., F.R.C.P. (Edin.), Assistant Physician to the Edinburgh Royal Infirmary; Lecturer on the Principles and Practice of Medicine, and on Practical Medicine and Medical Diagnosis in the Extra-Academical School of Medicine, Edinburgh; Additional Examiner in Clinical Medicine in the University of Edinburgh, etc.

On the 16th of October 1884 I was asked by Dr Foulis to see a single lady (Miss A.), aged 47, suffering from headache, vomiting, and partial loss of motor power in the right arm and leg.

At the age of 12 the patient had suffered from cerebral symptoms, the exact nature of which could not be definitely ascertained, but which were said to be due to "water on the brain." From this attack she had perfectly recovered, and had been an extremely intelligent, bright, and active-minded woman.

Ten years before the present symptoms commenced she had, after severe mental trouble and anxiety, another cerebral attack—a fit of some kind or another—attended with loss of consciousness, loss of speech, and marked rigidity of the limbs; the rigidity and speechlessness lasted for five days, during which time she was confined to bed. From this attack she had also (apparently) perfectly recovered, though her friends were conscious of a distinct difference in her mental condition, and had enjoyed good health until a little more than a year before I saw her.

At the age of 45, when menstruation ceased, she became anæmic, and began to suffer every now and again from attacks of headache

and vomiting. The headache was sometimes very severe, and always limited to the left side of the head; in the earlier periods of her illness it was apparently neuralgic in character, and very definitely located over the area of distribution of the great occipital nerve. For some time before I saw her the pain was chiefly felt in the left frontal and parietal regions.

The headache often occurred without the vomiting, but the vomiting was always associated with headache.

Under treatment the anæmia improved, the headache and vomiting became less frequent and less severe; but during the next few months she had several pseudo-apoplectic attacks which resembled a deep sleep, and in which she remained insensible for many (in one instance for twenty-four) hours at a time. One of these attacks occurred when she was in her bath. When seen by Dr Foulis shortly after the commencement of the coma she was completely insensible, the eyes suffused, and the temperature 105° F. During these attacks the contents of the bladder and rectum were evacuated involuntarily. The attacks of coma were never, so far as could be ascertained, preceded by a convulsion, and were not followed by any appreciable localized loss of motor power.

Some four months before I saw the patient, distinct loss of motor power had been occasionally noticed in the right arm and leg. The paralysis was never complete; it varied in degree from time to time, and would sometimes completely disappear.

A few days before my visit there had been distinct loss of power on the *left* side of the face (*i.e.*, on the opposite side to the paralysis of the arm and leg), and considerable difficulty in swallowing and articulating.

When seen by me on October 16th, the patient looked fairly well when lying in bed, though somewhat pale and anæmic. She could stand and walk, but with difficulty. After getting out of bed she looked very shaky and very ill, and the want of attention, vacant expression, and evident want of the power of mental concentration, which were very perceptible when she was lying in bed, became now much more marked. She seemed dazed, but said she was not giddy. Her movements were markedly unsteady, apparently the result of motor weakness rather than of inco-ordination. When standing she seemed very insecure, and it was noticed that the head tended to fall to the right side; this was particularly marked when she was seated in a chair having the eyes examined.

There was very decided loss of power in the right arm and leg; and voluntary movements of these (the paralyzed) parts were attended with a marked coarse tremor, which exactly resembled the tremor of multiple cerebro-spinal sclerosis, and which, it is well known, may result from pressure on motor conducting fibres.

The *left-sided* facial paralysis which had been noticed a few days

previously had disappeared; the motor power in both cheeks seemed feeble, but I was unable to satisfy myself that there was distinct localized paralysis on either side.

The tongue was protruded in a tremulous manner, and its tip, when protruded, seemed to be slightly turned to the right side.

There was marked difficulty in swallowing both solids and liquids, but there had been no regurgitation through the nose. Speech was distinctly impaired, apparently from slowing of articulation; there did not at this time, so far as could be ascertained, appear to be any definite aphasia.

The knee-jerk was lively on the left, but very feeble on the right (paralyzed) side; the plantar reflex was lively on both sides, but more marked (extremely active) on the left.

There was no apparent loss of sensibility; sight and hearing seemed perfect; the pupils were active, small, and contracted; ophthalmoscopic examination (which was made with difficulty at the first visit, owing to the small size of the pupils and the inability of the patient to keep the head steady and in the erect position, but which was most satisfactorily accomplished on November the 8th, when the patient was a great deal better) showed that there was no optic neuritis; both discs were deeply cupped, and perhaps rather too gray in colour, the edges well defined, the vessels of normal size; the sclerotic ring on the inner side of the left disc was very prominent, and a small white patch, very like one of the white spots seen in albuminuric retinitis, but in all probability the result of a previous hæmorrhage, was present on the inner side of the right disc. (Dr Barlow, who had seen the patient some months previously, had found some changes in the right disc, to which I will presently refer in detail.)

All the cerebral functions seemed slow and dull; but, so far as could be ascertained, there were not, at the time of my visit, any positive derangements of the mental and intellectual faculties. Both Dr Foulis and the patient's relatives had, however, on several previous occasions noticed marked evidence of intellectual failure (rambling and incoherence of speech, nonsensical talk, the erroneous use of words and expressions, impairment of memory, and marked loss of the power of attention).

Percussion did not seem to cause more pain over the left parietal and frontal regions than over the other portions of the cranium.

The urine had been repeatedly examined by Dr Foulis, and had always been healthy. There was no evidence of disease in any of the thoracic or abdominal viscera.

Diagnosis.—After careful consideration it was concluded—(1.) That the patient was suffering from an organic intra-cranial lesion; (2.) That, while the symptoms might be due either to a cerebral tumour or localized and progressive softening, the balance of evidence was very strongly in favour of tumour. A decided

opinion in favour of tumour was, therefore, expressed to the patient's friends.

The exact localization of the lesion presented very considerable difficulty. The right-sided character of the paralysis showed, without doubt, that the lesion was situated on the left side of the brain; while the presence of coarse tremor in the paralyzed limbs, and the intermittent character of the paralysis and tremor, were strongly suggestive of pressure on the motor (pyramidal) tract, rather than of a lesion directly involving and destroying the motor conducting fibres or the motor centres.

The fact that the *left* side of the face had been paralyzed was very strongly suggestive of a lesion involving the left side of the pons Varolii, and pressing upon the fibres of the pyramidal tract, going to the right arm and leg above its decussation in the medulla and on the trunk or fibres of the left facial nerve after their decussation in the pons. And that the lesion was situated far back in the neighbourhood of the pons or medulla seemed further confirmed by the marked difficulty in swallowing, by the character of the articulatory disturbances which were present at the time of my first visit. Further, the fact that in the earlier stages of the case the pain was limited to the back of the head, and most distinctly localized in the course of the great occipital nerve, seemed to favour this view of the position of the tumour.

The facts did not seem sufficient to warrant an opinion as to the pathological nature of the lesion.

Accordingly, when writing the same evening to Dr Barlow, who was interested in the case, I stated that I had no doubt that there was organic disease; that I was strongly in favour of a tumour rather than of softening; that the localization of the lesion was a matter of difficulty; but that, for the reasons which have been given above, I was inclined to think that it was situated far back, and was probably exerting pressure upon the pons Varolii. At the same time I stated that the mental defects, and I should have added (but I am not sure if I mentioned this point or not), the localization of the pain to the left temple, were suggestive of a lesion of the higher cerebral centres. I therefore suggested the possibility of a double lesion.

In answer to this letter Dr Barlow wrote me:—"She must have gone down rather badly since I saw her, but your view quite coincides with mine—at least so far—that I thought the tumour was far back and low; and I thought it probable some of the pareses were indirect from pressure rather than involvement; further than that I could not venture. I satisfied myself about the right eye, that there was a little blurring of the edge of the disc and covering over of veins; but I have seen several times now an intercurrent neuritis which has cleared up, so that I am not surprised now that you find *nil* there. I must say, like your-

self, the sum total of the case very strongly seems to me in favour of tumour rather than of softening."

As regards treatment, it was agreed to give iodide of potassium in as large doses as could be satisfactorily borne.

Subsequent Progress of the Case.—For two or three days there was no improvement; in fact, the condition was worse. On 17th October Dr Foulis wrote me:—"Miss A. has been in a very sleepy state since yesterday morning. She can be roused, and will speak to you if you ask questions; but her answers are not correct, wrong words being used. The temperature yesterday was 100° F. This morning the face is flushed. She complains of choking sensations in her throat, and has more difficulty in swallowing. After two or three attempts a violent cough comes on, which gives rise to *agonizing* pain in the *left* of the head.

On the evening of the 18th a blue pill, followed by a saline draught, were prescibed by Dr Foulis; and the free purgation which was thus obtained was followed by marked improvement, which steadily continued.

When next seen by me, on 8th November, she looked very much brighter and better, and was not so pale and anæmic. She had, on the morning of my visit, had a little headache (left-sided and frontal), the first since the improvement began; it was apparently caused by getting up and walking about the room. The difficulty in deglutition had almost completely disappeared; the paralysis and tremor in the right arm and leg were scarcely perceptible; the knee-jerk was now about equal on the two sides; the mental and intellectual faculties were much clearer; the head no longer drooped to the right side; there was no evidence of left-sided facial paralysis; the tongue was slightly furred; the nurse thought the patient was thinner. To continue the iodide; to repeat the blue pill and saline draught occasionally; and to keep very quiet.

The great improvement which had resulted from the free purgation, and perhaps from the use of the iodide, was very remarkable; and although I saw no reason to modify my opinion as to the presence of an intracranial tumour, the continued absence of any left-sided facial paralysis, and the almost complete subsidence of the difficulty of swallowing, threw very grave doubts upon the localization of the lesion which seemed previously indicated; in fact, I now felt disposed to give up the view that the tumour was pressing upon the pons Varolii.

After this date I did not see the patient again during life, but I learned from Dr Foulis that the progress, though interrupted by temporary periods of improvement, was on the whole steadily from bad to worse; until, finally, death took place on March 19th, 1885.

Dr Foulis has very kindly furnished me with the following notes,

which give a much more detailed account of many of the points in the clinical history than I have been able to do:—

"Miss A. consulted me at the end of the year 1883. She complained of severe neuralgia at the back of the head, on the left side. The pain was shooting in character, and seemed to be connected with the great occipital nerve. In appearance she was pale and anæmic. Her expression was emotionless and dull. She did not complain of any want of sensation or muscular power on one side or other. The pupils were equal in size, and responded freely to the action of light. It seemed to me at the time that all her suffering was caused by her very anæmic condition. I therefore prescribed iron and arsenic, with good food and rest.

"I saw her two or three times after this at the beginning of the year, early in January 1884, and, although the anæmia was less, the pain in the region of the great occipital nerve was more intense. I noticed that the glands of the neck on the posterior border of the sterno-mastoid muscle on the left side were enlarged and tender to the touch.

"On the 22nd January 1884 I was sent for at night to see her at her own home. I found her in bed, sleeping so deeply that shouting in her ear and pinching her violently failed to waken her. The limbs that were severely pinched were drawn away slowly, and a slight frown, expressive of pain, was seen on her forehead. The eyelids were nearly closed. The eyeballs were congested, and could be freely touched without causing the eyelids to wink. The pupils were not contracted, and answered the stimulus of light. She was breathing deeply, in a sighing manner; the face was flushed, and covered with perspiration. The temperature in the mouth was over 104° F., while the pulse was 116. On hearing from her friends that she had been suffering from constipation for a few days past, and as there were no one-sided symptoms of muscular or sensory paralysis, I ordered her to have a large dose of castor oil, in the hope that its free action would relieve the cerebral congestion.

"On seeing her next day, I heard that she had slept deeply for twenty hours, and that as soon as the castor oil had acted freely she began to revive, and shortly afterwards became quite conscious, but had no recollection whatever of what had occurred the previous night. For some weeks after this I saw her frequently. The pain in the back and left side of the head never left her, day or night. She was sometimes sick and vomited her food. There was marked constipation at all times, which necessitated the use of aperient medicine. At times the pain in the head was agonizing, but was always relieved after a free action of the bowels. It was noticed that she now occasionally made use of wrong words in conversation, and she introduced persons and ideas quite unconnected with the subject of conversation; of this she was quite

unconscious. Her friends now reported to me that my patient had fallen asleep in a bath in the house of a relative, but this sleep did not last for more than a couple of hours. About this time it was observed that her right arm was deficient in muscular power, and that in walking she fell away to the right side. She could not squeeze so well with the right as with the left hand, and on raising a cup of tea to her mouth the cup shook very much and was in danger of falling. She joined in conversation on all subjects, but frequently made mistakes without being aware of it. At times there was a difficulty in swallowing, and the bladder sometimes failed to retain the urine.

"On the 5th May she had another very extraordinary sleeping fit, accompanied by fever and profuse perspiration. This comatose state lasted for quite twenty hours, and was put an end to by a large dose of aperient medicine as already described. After this, for some weeks, she decidedly improved in every respect; so much so, that she was able to accompany her friends to Moffat at the beginning of summer. On the arrival of the train at Moffat she appeared to be very drowsy, and as soon as she reached her house she fell into a deep sleep, from which she did not wake for twenty-four hours. She was seen by a local medical gentleman, who gave her the usual large dose of aperient, and it was followed by complete relief from all anxious symptoms, as on former occasions. She remained several weeks at Moffat, during which time she had two or three sleeping fits, as above described. In general condition she was not worse when she returned to Edinburgh at the end of summer. The pain in her head still continued very severe, and it was quite evident that she was duller in her mental condition. Her expression was now decidedly emotionless, but she was fairly well nourished, and her anæmia had quite disappeared.

"Towards the end of July she was seen by Dr Barlow in consultation with me. He expressed the opinion that there was a tumour growing in the brain, but did not speak definitely as to its localization. In the middle of October she was seen by Dr Byrom Bramwell with me in consultation, who examined her very carefully, and as the result of that examination he diagnosed a tumour, and stated the grounds on which he localized the new growth. To relieve the pain in the head it was decided to give her ten-grain doses of potassium iodide three times daily. This was followed with such relief to the pain in the head and to all other urgent symptoms that her friends began to hope that she was going to get better; but at the end of three weeks' trial we were obliged to give up the potassium iodide as it produced such general weakness, and it at last lost its power in relieving the headache. In one of her deep sleeping fits, I found that a blue pill followed by a saline purge in the morning gave her marked relief from all her suffering, and this treatment was continued for some weeks, but, like everything else, it at last failed, and all the symptoms got

gradually worse. The pain in the back and left side of the head was now at times quite agonizing. She frequently vomited her food. She had great difficulty in masticating and swallowing. Violent fits of coughing came on as the result of crumbs of bread or other food going down the wrong way. She suffered intense pain in her head during the fits of coughing. She was now very apathetic and listless. There was decided motor and sensory paralysis on the right side, and her urine often came away involuntarily. A bed-sore appeared on her back, and she was now placed in bed on a water-bed. She was seen by another gentleman in consultation with me, who also diagnosed a cerebral tumour, but localized it differently from the other consultants. It was now necessary to feed her on liquid food, as she could not masticate. She could speak in answer to questions, but with great difficulty, and only in a whisper. Her pulse was generally about 96, while the temperature reached about 100° F. at night-time.

"At the beginning of the year 1885 she improved in general condition so much that she was able to get out of bed, and sat in a chair, and actually received some of her friends to tea. After being in such a serious condition in December 1884, it seemed almost a miracle that she could leave her bed in January 1885. With a little support she could rise out of her chair and walk a few yards, though it was quite evident there was great muscular and sensory weakness in the right limbs. Her powers of conversation greatly improved, so that she could carry on a little chat with those around her.

"This improvement, however, did not last for more than a few days, and as the urgent symptoms gradually returned, she was replaced in bed on the water-bed. From the end of January on to the 19th March, when she died, her condition may be simply described as one of right-sided paralysis with aphasia.

"About a month before she died the pupils of her eyes were moderately dilated, and did not respond in the least to the stimulus of a strong light. Her power of mastication was now quite gone, though she gulped down liquids after they were poured into her buccal cavity. Urine and fæces escaped involuntarily. She gradually became deeply unconscious to everything around her, and day by day, as the temperature and pulse rose, she became weaker and weaker, till she died exhausted on the 19th March. For the last week or ten days the temperature varied from 100° F. to 104° F., and her dying hours were of extraordinary duration."

The post-mortem examination was made on March 20th; the head only was examined.

The scalp, skull-cap, and outer surface of the dura were natural; the internal surface of the dura was adherent over the left frontal lobe, which was markedly swollen and considerably larger than the right. There was no appearance of any general increase of the

intracranial pressure—no flattening of the convolutions, no effacement of the sulci; in fact, the convolutions of the brain generally were rather atrophied than flattened, the sulci wide, and the subarachnoid fluid in some excess.

On cutting up the brain the greater portion of the left frontal lobe, or to speak more precisely, the anterior two-thirds of the first and second, and the anterior half of the third left frontal convolutions, with the associated portions of the subjacent white matter, were completely destroyed by a new growth; while the posterior third of the first and second, and the greater part of the posterior half of the third left frontal convolutions, were softened, œdematous, and, to some extent, infiltrated by the lesion (see Fig. 1). The greater portion of the tumour consisted of a soft glioma, but embedded in its posterior end, and projecting for some distance behind it, there was a cyst as large as an average size hen's egg.

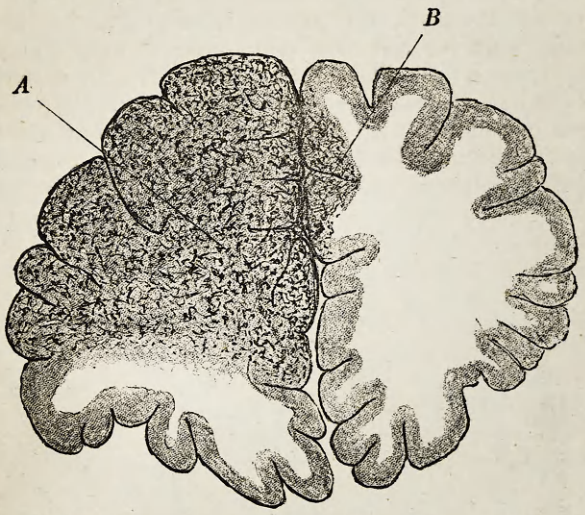

FIG. 1.—*Transverse Vertical Section through the Frontal Lobes in the case of Miss A., showing the position of the lesion.* Drawn from memory.

A points to the lesion in the left frontal lobe, and *B* to a portion of the right frontal lobe affected by the direct extension of the tumour.

This cyst, which contained a colourless but slightly turbid fluid, was bounded above and in front by the gliomatous tissue of the tumour, below and behind by the anterior cornu of the lateral ventricle, and behind by the white matter of the centrum ovale.

The posterior end of the cyst was in close contact with the lenticular nucleus and head of the corpus striatum, and must have been in a position to have exerted pressure upon those fibres of the centrum ovale which pass downwards under the name of the motor portion of the internal capsule. The wall of the cyst was formed by a tough but transparent membrane, which was the only

structure which divided the cavity of the cyst from the cavity of the lateral ventricle; in this semi-transparent partition a most beautiful network of bloodvessels was seen.

Several recent hæmorrhages, the largest about the size of a large walnut, were present in different parts of the tumour; and the pigmented remains of other hæmorrhages of old date were visible, both to the naked eye and on subsequent microscopical examination, in other parts of the new growth.

The enlarged and diseased left frontal lobe bulged across the middle line, and at one spot where it impinged upon the right frontal lobe (see B, Fig. 1), the tissue of that (the right) lobe was diseased, the result without doubt of a process of direct extension or auto-inoculation.

The other portions of the brain were free from disease. The optic nerves were to the naked eye perfectly normal.

On microscopical examination, the tumour was found to be a glioma, or perhaps more correctly a glio-sarcoma.

The cells were for the most part round or oval, and arranged in dense masses (see Figs. 7, 11, 14). In some parts, more especially in half-cleared-up carmine or picro-carmine preparations, and in sections stained with picro-carmine, teased out, and mounted in Farrant's solution, the glial threads or fibres were well shown (see Fig. 2). In those portions of the tumour into which recent

FIG. 2.—*Camera Lucida Drawing of a Microscopical Section of a portion of the Cerebral Tumour in the case of Miss A., showing Gliomatous and Sarcomatous Cells and Fine Fibres. Stained with Picro-carmine, half-cleared with Methylated Spirit and Oil of Cloves, and mounted in Zylol Balsam. (Magnified—Hartnack, oc, 3. obj. 8.)*

a, Glial cell containing three nuclei; *b*, round sarcomatous cell containing nucleus; *c*, fine glial fibres.

hæmorrhages had occurred, large round cells, which appeared to be distended with clear colourless contents, which did not stain pink with picro-carmine, were found. Some of these large swollen

cells contained a single small round nucleus, others contained red blood corpuscles which they had apparently digested (see Fig. 3). The impression left upon my mind was that the large swollen cells with colourless non-staining contents had previously contained red blood corpuscles, which had become fused into a single uniform mass.

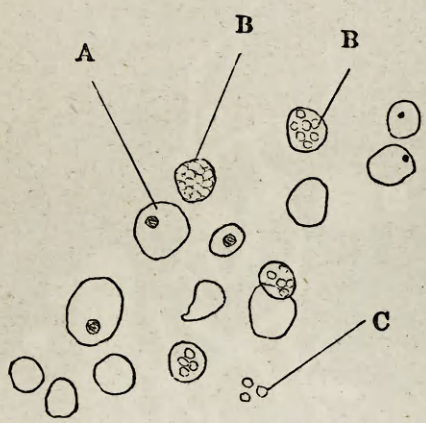

FIG. 3.—*Camera Lucida Drawing of a Microscopical Section of a portion of the Cerebral Tumour in the case of Miss A., showing large round Transparent Cells, some of which contain a single small Nucleus (? Nucleolus), others Red Blood Globules. These Cells lay in the midst of Extravasated Red Blood Corpuscles, which have been omitted from the Drawing. Stained with Picro-carmine, half-cleared with Methylated Spirit and Oil of Cloves, and mounted in Zylol Balsam. (Magnified—Hartnack, oc. 3, obj. 8.)*

A, Large cell containing a single nucleus; B, B, cells containing red blood corpuscles; C, red blood globules.

The tumour tissue was most vascular—indeed, in some places it appeared to consist of a dense network of minute vessels, in the meshes of which the glial cells were situated. Aneurismal dilatations were, in many places, seen on the minute vessels (see Fig. 4). In places, therefore, the structure of the tumour corresponded to the condition which has been termed a telangiectatic glioma.

In the midst of some of the large masses of extravasated red blood corpuscles, which were situated in different parts of the tumour, enormous crystals were situated (see Fig. 5). These crystals were of a pale yellow colour; they were seen both in preparations mounted in Farrant's solution, and in sections which had been treated with absolute alcohol and oil of cloves, and mounted in balsam. I am unable to pronounce an opinion as to their exact nature, for I have never seen anything resembling them before. I feel convinced that they were not artificial (post-mortem) productions, the result of the reagents employed in hardening and mounting the sections. Possibly they were derivatives of the red blood globules in the midst of which they lay; but whether they existed during life, or were produced during the death agony, or even after death, I feel unable to decide.

Surrounding the masses of extravasated blood in which the crystals were embedded, and in the midst of some of the other extravasations in which there were no crystals, large irregularly

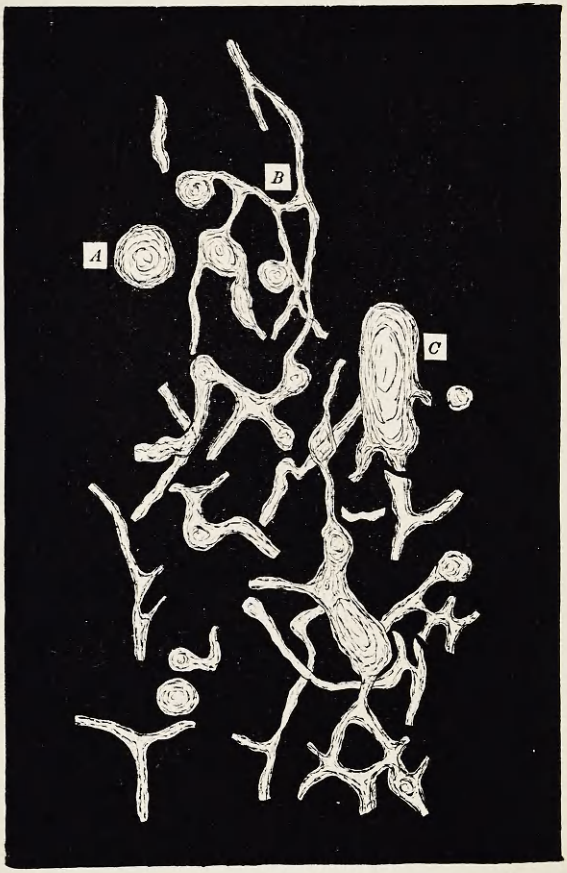

Fig. 4.—*Camera Lucida Drawing of a Microscopic Section of a portion of the Cerebral Tumour in the case of Miss A., showing Aneurismal Dilatation of the Minute Vessels. Stained with Picro-carmine, cleared with absolute Alcohol and Oil of Cloves, and mounted in Zylol Balsam. (Magnified—Hartnack, oc.* 3, *obj.* 8, *and drawing reduced from* 8 *to* 4 *inches.)*

A, Transversely divided vessel; *B*, vessel with numerous aneurismal dilatations; *C*, large aneurismal dilatation. The tissue of the tumour in the midst of which the vessels lie, and many of the vessels themselves, have been omitted from the drawing.

shaped masses, composed of a highly refractive, transparent, and structureless material, were situated. These masses were for the most part of the same pale yellow colour as the large crystals, but some of them stained pink with picro-carmine. These irregular, structureless, colloid-like masses were probably like the crystals, derivatives of the extravasated red blood corpuscles. Further, I am disposed to think, after careful examination of many different

preparations, that they represented a material in an intermediate stage between the extravasated red blood corpuscles and the hyaline material which was present in the walls of many of the bloodvessels of the tumour, and to which I will presently refer. The crystals, the irregularly shaped, transparent, yellow masses, and the hyaline material in the walls of the vessels, were present



FIG. 5.—*Camera Lucida Drawing of a Microscopical Section of a portion of the Cerebral Tumour in the case of Miss A., showing the Large Crystals described in the Text. The Blood Corpuscles, in the midst of which the Crystals lie, are not shown in the drawing, and could hardly be individually distinguished with this Magnifying Power—Hartnack, oc. 3, obj. 3, and drawing reduced from 4 to 3½ inches. The Preparation was stained with Picro-carmine and mounted in Farrant's Solution.*

in such quantities that it is hardly possible, I think, to suppose that they were derivatives of the extravasated *white* blood corpuscles. Possibly, however, the hyaline material which was present in such abundance in the walls of the bloodvessels, both in this case and in Dr Leslie's case of glio-sarcomatous tumour, which will be subsequently reported, may have been a derivative—a product so to speak—of the glial cells. But be that as it may, it is important to note that in these two cases in which the hyaline degeneration of the vessels was so extensive, the structure of the two tumours was identically the same; both were glio-sarcomatous tumours; in both there was a large cyst connected with the tumour; in both the tumour tissue contained an enormous number of minute vessels; and in both there was evidence of extensive blood extravasations.

In many parts of the tumour highly refractive, homogeneous masses, composed of hyaline material, were seen. These hyaline masses were in some places most numerous; many of them were

small, others very large; the large masses were almost invariably stained pink when treated with picro-carmine. Some of the small masses did not take on the pink stain, but remained unstained, or were stained of a pale yellow or greenish-yellow colour; in fact, they closely resembled little drops or beads of yellowish-green glass. The large hyaline masses were much more

FIG. 6.—*Camera Lucida Drawing of a Microscopical Section through a portion of the Cerebral Tumour in the case of Miss A., showing numerous Hyaline Lumps. The Tumour Tissue, in the midst of which the Hyaline Masses lie, has not been represented, for, under this magnifying power the Individual Cells of the Tumour could not be distinguished. Stained with Picro-carmine, cleared with absolute Alcohol and Oil of Cloves, and mounted in Zylol Balsam. (Magnified—Hartnack, oc. 2, obj. 3, and drawing reduced from 6½ to 4½ inches.)*

A, B, point to two of the hyaloid lumps, which are seen to be concentrically lined, and are in reality hyaline masses surrounding bloodvessels.

highly stained in sections which were treated with alcohol and oil of cloves and mounted in balsam than in sections mounted in Farrant's solution.

In completely cleared-up carmine and picro-carmine preparation

(*i.e.*, sections which had been treated with absolute alcohol), the large hyaline masses were concentrically lined; in sections half-cleared-up (*i.e.*, treated with methylated spirit), and still better in preparations mounted in Farrant's solution, one or more minute vessels, which were, as a rule, transversely divided, could be seen in the midst of the hyaline material. The concentric appearance seen in completely cleared-up preparations was evidently the result of the shrinking produced in the hyaline material by the absolute alcohol; for the concentric markings were less marked in half-cleared-up preparations, and not seen in sections mounted in Farrant's solution.

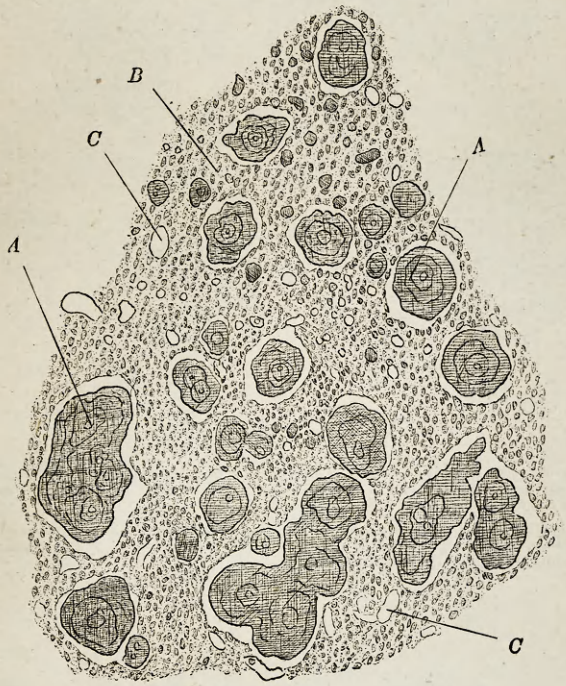

FIG. 7.—*Camera Lucida Drawing of a Microscopical Section of a portion of the Cerebral Tumour in the case of Miss A., showing large Hyaline Masses lying in the midst of Sarcomatous Tissue. Stained with Picro-carmine, cleared with absolute Alcohol and Oil of Cloves, and mounted in Zylol Balsam. (Magnified—Hartnack, oc. 3, obj. 7, and drawing reduced from 5½ to 3½ inches.)*

A, A, Large hyaline masses, concentrically lined, and containing minute bloodvessels; *B*, sarcomatous tissue; *C, C*, small vessels in the tumour, the walls of which are healthy.

The small hyaline masses were in some cases connected with vessels, but in many places this connexion was not apparent, and the little hyaline masses then appeared to be simply scattered here and there in the midst of the tissue of the tumour. The appearances just described are well seen in Figs. 6, 7, and 8. In 6 and 8 the tumour tissue is not represented, but in Fig. 7 the comparative size of the glial cells and hyaline lumps is seen.

In other sections long hyaline masses evidently surrounding minute vessels were seen (see Figs. 9 and 10). One of these

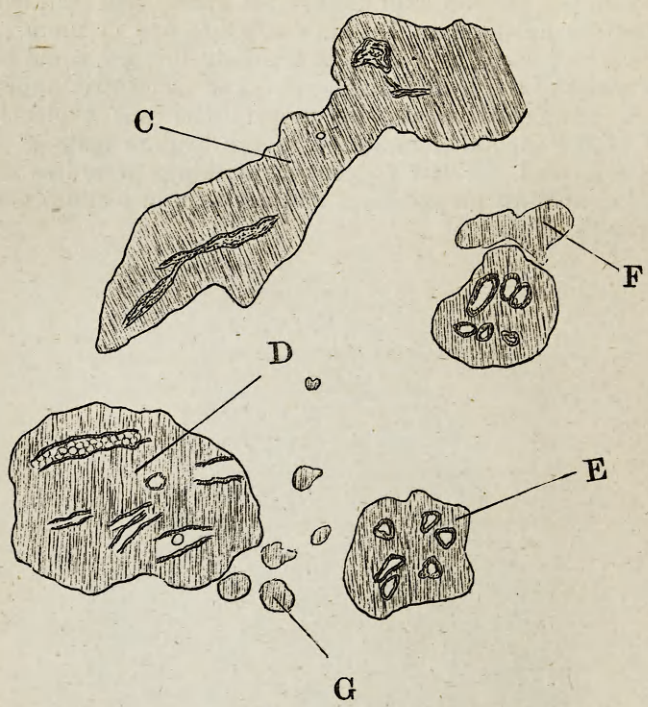

FIG. 8.—*Camera Lucida Drawing of Hyaline Masses from the Cerebral Tumour in the case of Miss A., showing numerous small Vessels in their Interior. Stained with Picro-carmine, and mounted in Farrant's Solution. (Magnified—Hartnack, oc. 3, obj. 8.)*

C, D, Hyaline lumps, containing minute vessels longitudinally and transversely divided; E, hyaloid lump, containing six minute vessels transversely divided; F and G, large and small hyaline lumps, in which there are no vessels.

FIG. 9.—*Camera Lucida Drawing of a Bloodvessel from the Cerebral Tumour in the case of Miss A., showing Enormous Thickening, due to Hyaline Infiltration of its Wall, and numerous small Hyaline Globules, which appear to have exuded from the Outer Surface of the Hyaline Sheath. Stained with Picro-carmine, cleared with absolute Alcohol and Oil of Cloves, and mounted in Zylol Balsam. (Magnified—Hartnack, oc. 3, obj. 8, and drawing reduced from 8 to 3 inches.)*

A, Hyaline sheath; *B, B*, large, and *C, C*, small masses of hyaline material adhering to the outer surface of the hyaline sheath. The small hyaline masses are concentrically lined.

hyaline masses was so cut that the minute vessel in its interior could be clearly seen; in this instance the hyaline mass seemed to

form a sheath around the vessel; between the vessel and the hyaline cylinder some delicate spindle cells and connective tissue fibres were situated.

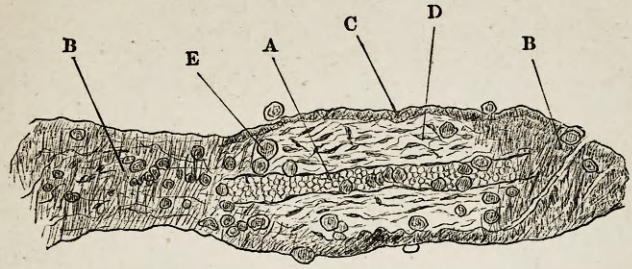

FIG. 10.—*Camera Lucida Drawing of a Minute Vessel and the Hyaline Sheath which surrounds it, from the Cerebral Tumour in the case of Miss A. The Hyaline Sheath is so cut that the Minute Vessel in its Interior is distinctly seen. Between the Vessel and the Hyaline Sheath some delicate Spindle Cells and Fibres are situated. Stained with Picro-carmine, cleared with absolute Alcohol and Oil of Cloves, and mounted in Zylol Balsam. (Magnified—Hartnack, oc. 3, obj. 8, and drawing reduced from 4¼ to 3¼ inches.)*

A, Vessel containing red blood corpuscles and some small round hyaline lumps; B, hyaline sheath surrounding the vessel; at B′ the hyaline sheath is cracked across; C, cut edge of hyaline sheath; D, spindle cells between the sheath and its contained vessel; E, hyaline globules which are adhering to, and in places appear to have exuded from, the hyaline sheath.

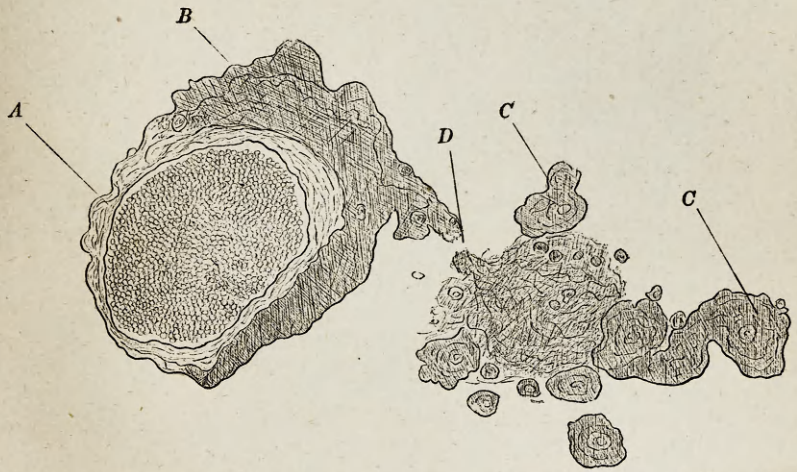

FIG. 11.—*Camera Lucida Drawing of a Section through a portion of the Cerebral Tumour in the case of Miss A., showing a Bloodvessel, the Wall of which is partly infiltrated with Hyaline Material, which is apparently continuous with Hyaline Masses in the Tissue of the Tumour surrounding it. Stained with Picro-carmine, cleared with absolute Alcohol and Oil of Cloves, and mounted in Zylol Balsam. (Magnified—Hartnack, oc. 3, obj. 8, and drawing reduced from 6 to 4 inches.)*

A, Healthy portion of vessel wall; *B*, Hyaline mass in vessel wall; *C, C*, hyaline lumps in surrounding tissue; *D*, the junction of the hyaline mass in wall of vessel and in surrounding tissue; the continuity has apparently been broken in the process of preparation. The sarcomatous tissue in which the vessel lies has been omitted from the drawing.

Adhering to the outer surface of these long hyaline sheaths were numerous small round or oval hyaline masses, which looked

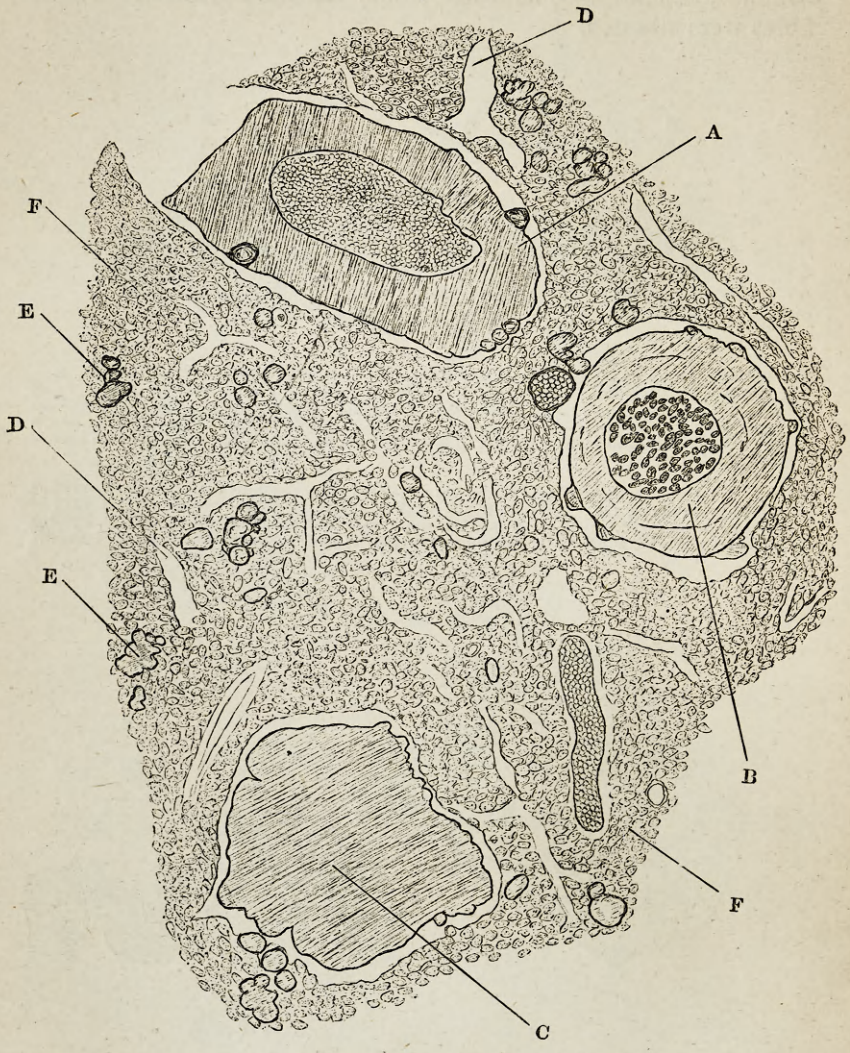

FIG. 12.—*Camera Lucida Drawing of a Microscopical Section of a portion of the Tumour in the case of Miss A., showing three Vessels, the Walls of which are enormously thickened and infiltrated with Hyaline Material. Stained with Picro-carmine, mounted in Farrant's Solution. (Magnified—Hartnack, oc. 3, obj. 8, and drawing reduced from 7 to 4¼ inches.)*

A, Vessel containing blood corpuscles—its walls are enormously thickened and infiltrated with hyaline material; B, vessel with walls affected in the same manner as A, but filled with sarcomatous cells, forming, as it were, a sarcomatous infarction; C, large mass of hyaline material, which seems to represent a former bloodvessel; D, D, small vessels in the midst of the sarcomatous tissue; E, E, small hyaline lumps in the midst of the sarcomatous tissue; F, F, point to the sarcomatous tissue, which is composed at this part of round and oval cells.

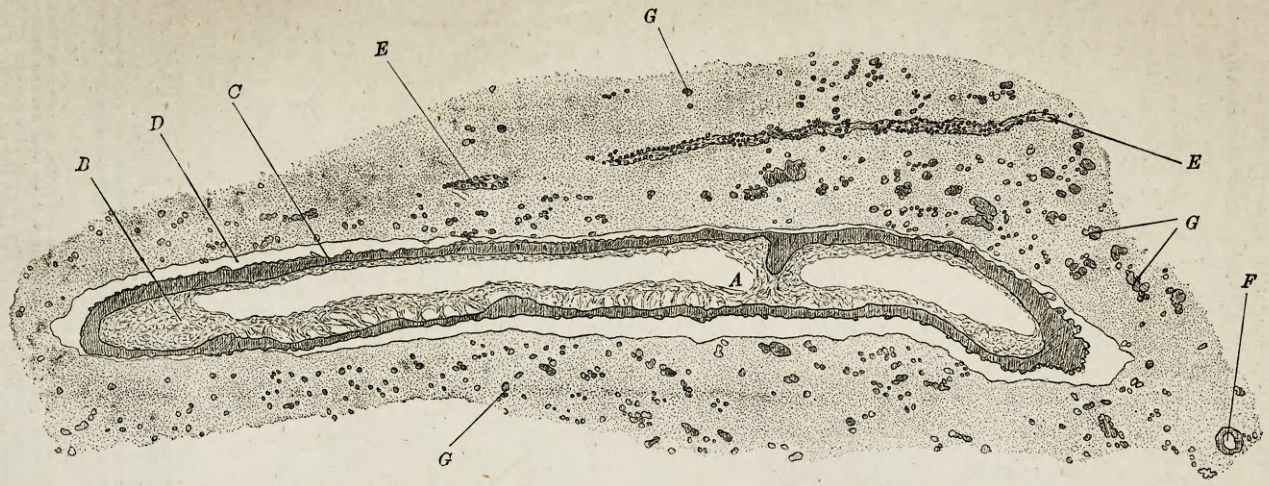

FIG. 13.—*Camera Lucida Drawing of a Microscopical Section through a portion of the Cerebral Tumour in the case of Miss A., showing a large Vessel in Longitudinal Section; the Coats of the Vessel are infiltrated with Hyaline Material, and its Canal is partly obstructed by an organizing Thrombus; numerous small Hyaline Lumps are seen in the surrounding Tissue—some of them appear to be free, others adhering to Minute Vessels. Stained with Picro-carmine, cleared with absolute Alcohol and Oil of Cloves, and mounted in Zylol Balsam.* (*Magnified—Hartnack, oc.* 3, *obj.* 3, *and drawing reduced from* 11 *to* $6\frac{1}{2}$ *inches.*)

The letter *A* is placed in the interior of the vessel, near a point where its canal is bridged across by a mass of hyaline material and by a portion of the organized thrombus (*B*); *C*, hyaline material in walls of vessel; *D*, space (? lymphatic space) surrounding the bloodvessel; *E*, *E*, minute vessel, seen longitudinally, surrounded by numerous small hyaline masses; *F*, small vessel, transversely divided, the coats of which are infiltrated with hyaline material; *G*, *G*, *G*, small hyaline lumps in the tissue of the tumour, the minute structure of which cannot be seen under this low magnifying power.

as if they had exuded in the form of drops from the main mass of hyaline substance. The same droplike appearance was also seen in transverse sections of vessels affected with the hyaline change (see Figs. 12 and 13).

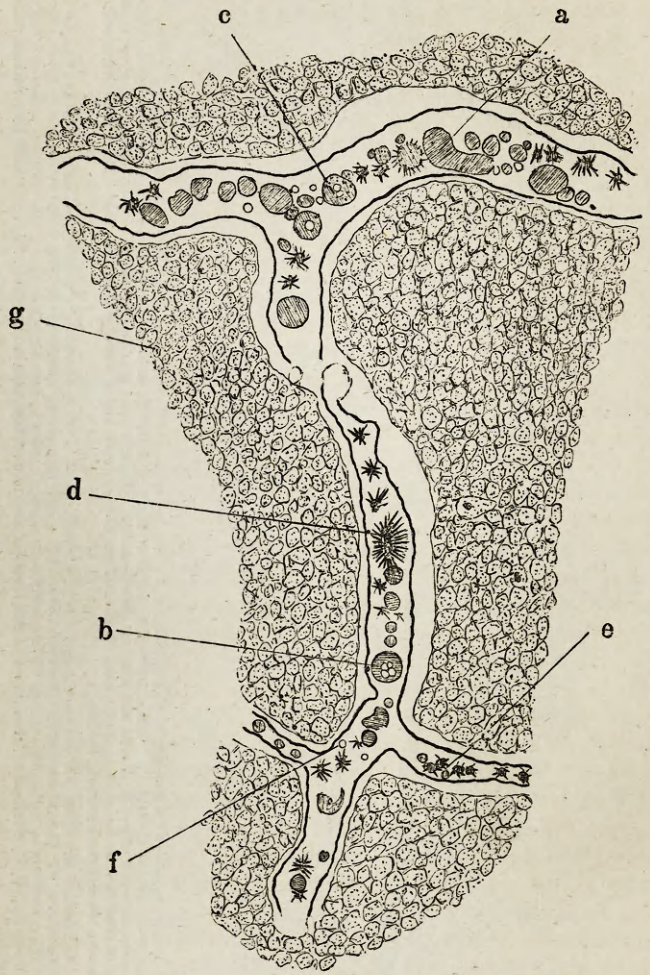

FIG. 14.—*Camera Lucida Drawing of a Section through the Cerebral Tumour in the case of Miss A., showing a Bloodvessel surrounded by Sarcomatous Tissue; in the interior of the Vessel there are numerous masses of Hyaline Material, some of them contain small round Bodies (Vacuoles, or Red Blood Corpuscles), others are bristled with Acicular Crystals. Stained with Picro-carmine, cleared with absolute Alcohol and Oil of Cloves, and mounted in Zylol Balsam. (Magnified—Hartnack, oc. 3, obj. 8, and drawing reduced from 5½ to 5 inches.)*

a, Large irregularly shaped hyaline mass, b and c, round hyaline masses containing small, clear, round bodies (? vacuoles or red blood corpuscles); d, large oval hyaline mass, bristled with acicular crystals; e, small round hyaline masses, studded with acicular crystals; f, red blood corpuscle; g, sarcomatous tissue, composed of round and oval cells. There were numerous minute bloodvessels amongst the sarcomatous cells they are not shown in the drawing.

The walls of many of the large vessels contained in the tumour were also infiltrated with hyaline material (see Figs. 11, 12, and 13). In some instances (as in Fig. 11), the hyaline infiltration was limited to one side of the vascular wall, and in many cases the hyaline material in the vascular wall appeared to be continuous with masses of hyaline material in the tissue of the tumour surrounding the affected vessel.

Some of the large vessels affected with the hyaline change were filled with blood corpuscles (see A, Fig. 12); in one instance (B, Fig. 12) the vessel contained glial cells—an infarction or thrombosis composed of cells identical in structure, though not quite so large in size, as the cells forming the adjacent portion of the tumour. In several instances, vessels, the walls of which were infiltrated with hyaline material, were partly filled up by an organizing thrombus (see Fig. 13).

In many different sections hyaline lumps, for the most part round or oval, and many times larger than red blood corpuscles, were seen in the interior of vessels, the walls of which were healthy. Some of these masses contained round, clear, colourless globules in their interior—probably vacuoles, but possibly red blood globules. The surface of the hyaline masses within the bloodvessels was in many instances bristled with fine acicular crystals; these crystals, which were stained in picro-carmine preparations of the same pink colour as the hyaline material, had probably been formed after death or during the death agony. In Fig. 14 a remarkable illustration of these intravascular, hyaline masses and crystals is faithfully represented; and it is to be observed that in the portion of the tumour surrounding this vessel no hyaline masses are to be seen.

Remarks.—This case presents several points of great clinical and pathological interest.

Diagnosis.—It could hardly, I think, be doubted, that the condition of the patient when I first saw her, and the whole previous history of the case, were indicative of an organic cerebral lesion; while the history of headache and vomiting, the pseudo-apoplectic attacks, the one-sided paralysis and tremor which varied so remarkably from time to time, and the temporary and unilateral optic neuritis observed by Dr Barlow, together with the absence of any of the ordinary causes of cerebral softening, were strongly suggestive of an intracranial tumour.

The reason which induced me, when I first saw the patient, to think that the tumour was pressing upon the pons Varolii have already been detailed. The appearances found at the autopsy showed no cause for the left-sided facial paralysis, nor of the extreme difficulty of swallowing which was such a marked symptom at the time of my first visit.

On reviewing the whole history and progress of the case, I am disposed to think that the character of the intellectual deteriora-

tion (the marked loss of the power of attention and of mental concentration), the falling of the head to the right, and the defects in speech (use of wrong words, etc.), which might be called a minor degree of aphasia, should have enabled us to localize the lesion in the left frontal lobe. It must, however, be remembered that many of the symptoms to which I have just referred were by no means prominently marked, that almost all of them were temporary and evanescent (present at times, absent at others), and that it seemed difficult to explain the unilateral paralysis and voluntary tremor, and to account for the remarkable variability of these symptoms (paralysis and tremor) by a tumour in the frontal lobe.[1]

Further, a careful review of the symptoms in the light of the conditions found at the post-mortem leads me to think that the exact pathological nature of the tumour might perhaps have been correctly surmised.

The coarse tremor, absent while the limbs were at rest, but present on voluntary movement (granting that it was due to organic and not to functional—hysterical—disease), was indicative either of cerebro-spinal sclerosis or of pressure on the motor conducting fibres.

The facts that the paralysis and tremor varied greatly in degree from time to time, and had on more than one occasion completely disappeared, excluded cerebro-spinal sclerosis (indeed that condition was never suspected, for the symptoms, taken as a whole, were in no way indicative of its presence), and ought, perhaps, to have suggested the presence of a cyst, or at all events of fluid pressure.[2]

[1] In the *British Medical Journal*, 3rd March 1876, and in the *Edinburgh Medical Journal*, December 1878, I have reported cases in which tumours with cysts were found in the frontal lobes. In both cases the mental symptoms were very prominent, and in both there were sudden but temporary attacks of hemiplegia without loss of consciousness, and without convulsions. In one case there was also some loss of power on the same side (arm and leg) as the lesion. These two cases have several points in common with the one which I am at present describing.

[2] The pressure of a cerebellar tumour on the pons or medulla is a common cause of this form of voluntary tremor. For the past ten years I have been familiar with cases of this kind, and have explained the tremor by the pressure of the tumour upon the motor conducting fibres in the pons Varolii or medulla. I have also seen two cases in which a lesion, presumably in the neighbourhood of the lenticular nucleus (for the diagnosis was not confirmed by post-mortem examination), has been attended with the same form of voluntary tremor, the result, I suppose, of pressure on the motor strands of the internal capsule. But in these cases there were marked sensory disturbances, the result no doubt of pressure on the sensory fibres of the internal capsule. I have met with no case in which a tumour of the frontal lobe by pressing upon the motor fibres of the internal capsule has caused tremor of this kind—unless such was the position of the lesion in a case which I saw some two years ago with Dr Struthers of Leith. In many respects that case bore such a close resemblance to the one (case of Miss A.) which I am now describing, that although there was no post-mortem, I will on some future occasion record its chief details.

Granting, then, as might perhaps have been conjectured, that the intermittent character of the paralysis and tremor could only have resulted from the pressure of fluid, the tension of which varied in degree from time to time, it might, I think, further have been supposed that the cause of the pressure was the presence of a cyst. The variations in the degree of pressure, as evidenced by the paralysis and tremor, were so rapid and extensive that an aneurism—another possible cause of intermittent pressure—might, I think, have been definitely excluded.

Now, if we exclude parasitic cysts (hydatids and cysticercus cellulose), which, in such a case as this, might probably be excluded—*firstly*, because of their extreme rarity; and, *secondly*, because there was no evidence of similar disease in any other part of the body—a cyst of sufficient size to produce the symptoms which have been described must in all probability have been the result of an ordinary hæmorrhagic apoplexy or of a new growth (glioma with hæmorrhage and cyst formation).

Further, ordinary cerebral hæmorrhage (hæmorrhagic apoplexy *par excellence*) might, I think, have been definitely excluded as the cause of the supposed cyst—*firstly*, because there was no evidence of any of the conditions which are usually associated with ordinary cerebral hæmorrhage (cardiac, vascular, or kidney disease); *secondly*, because the symptoms, both individually (headache, vomiting, pseudo-apoplectic attacks) and as a whole, and the whole progress and course of the case, were strongly in favour of a tumour rather than of softening, the result of hæmorrhagic apoplexy. In particular, the numerous pseudo-apoplectic attacks are easily explained by repeated small hæmorrhages in the substance of a tumour, and the disturbance of the intracranial pressure produced thereby, but would have been difficult or impossible to explain on the supposition that the supposed cyst had resulted from ordinary hæmorrhagic apoplexy. It is hardly possible to imagine so many separate hæmorrhagic extravasations, all of small size, all recovered from within a few hours, all outside the ordinary lenticulo-striate region, for none of the hæmorrhages were followed by motor or sensory paralysis.

The fact that sudden attacks of hemiplegia, rapidly passing off, were observed in two other cases of cyst in the frontal lobes, has already been referred to.

Reviewing, then, the symptoms which were observed during life in the light of the appearances found at the post-mortem, and taking into account the other two cases of tumour with cyst in the frontal lobe which I have reported, I am disposed to think that the position and exact pathological nature of the lesion might perhaps have been correctly surmised.

The effect of free purgation on the pseudo-apoplectic attacks is another point of great clinical interest, and is, I think, satisfactorily explained by supposing that the drain of water from the bowel by

reducing the general blood pressure, produced absorption of fluid, which had been effused into the tissues of the tumour, while it, perhaps, at the same time reduced the tension of the fluid in the cyst; and that in one or other or both of these ways the increased tension within the cranium was reduced, and relief afforded.

The condition of the deep reflexes is a point of considerable interest. At the time of my first visit there was marked paralysis of the right arm and leg, but the knee-jerk was diminished instead of increased, as it usually is in cases of cerebral hemiplegia. When I next saw the patient the hemiplegia had almost completely disappeared, and the knee-jerk had reappeared, and was, in fact, equal to that on the left (non-paralyzed) side.

This fact would seem to show that where paralysis results from *simple* pressure upon motor conducting fibres (*i.e.*, where there are no irritative changes in the conducting fibres as the result of that pressure) the knee-jerk is diminished rather than exaggerated—an important clinical indication of the cause of the paralysis, if it should be verified by future observations.

Further, if the effect of simple pressure is to produce diminution of the deep reflex movements, the exaggeration of the deep reflexes, which is present in ordinary hemiplegia, must evidently depend upon a process of irritation passing down the pyramidal tract to the multipolar nerve cells of the spinal cord, and not upon the simple arrest or shutting off of the cerebral control—the other theory which has been advanced to account for the exaggeration in that condition.

The character of the mental deterioration which was present in this case, and the *marked way in which the head tended to fall to the right side* (the side opposite the lesion), confirm Ferrier's observations on lesions of the frontal lobes.

The exact duration of the lesion must be a matter of speculation. It can hardly be imagined that the cerebral attack which was said to be due to "water on the head," whatever that term may mean, and which occurred at the age of twelve (thirty-five years before the patient's death), had anything to do with the condition.

Whether the well-marked cerebral attack (coma, rigidity, and speechlessness, lasting for five days) which occurred at the age of thirty-five was due to the lesion which was found at the autopsy it is impossible to say. It must, however, be observed that after this attack a distinct and permanent change was observed in the patient's mental condition; presumably, therefore, there had been some lesion which had resulted in permanent damage. It is not unreasonable to suppose that the cause of this attack was a hæmorrhage into the left frontal lobe, and that the cyst resulted from that hæmorrhage.

The condition of the optic nerve and retina.—The fact, that in this case, in which (*a*), the lesion was distinctly irritative in character

(evidenced by its microscopical characters, by the adhesion of the dura mater over the tumour, and by the direct extension—auto-inoculation—of the new growth from the surface of one to that of the other frontal lobe), and in which (*b*) there was no evidence of increased intracranial pressure at the autopsy, there was only a passing neuritis in one fundus, supports, I think, the view which I have always held, that increased intracranial pressure is a most important factor in the production of the double optic neuritis which is so frequently observed in connexion with intracranial tumours. It must, however, be remembered that Dr Hughlings Jackson has advanced the fact that, in those rare cases in which the neuritis is unilateral, it is present, as it was in this case, on the opposite side to the cerebral lesion, as an argument against the increased intracranial pressure theory.

Points of pathological interest.—The extreme vascularity of the tumour, the evidence of many separate small hæmorrhages in the tissue of the tumour, the frequent relationship of cysts with gliomatous tumours, the direct extension of the tumour by a process of auto-inoculation from the surface of the left to that of the right frontal lobe, the glio-sarcomatous infarction which was present in one of the vessels of the tumour (see Fig. 11), and the peculiar character of the large crystalline masses (see Fig. 5) which were found in some of the hæmorrhages, are points of pathological interest, which the limits of this communication do not allow me further to consider. I must, however, briefly refer to the hyaline degeneration which was such a remarkable feature both in this tumour and in a case which I saw with Dr Leslie, and which is reported on page 23.

Hyaline degeneration is met with in a great variety of different conditions. Recklinghausen, as the result of a long series of observations, concludes that the hyaline metamorphosis plays a considerable part in a great variety of different conditions, both normal and abnormal. It consists of a transformation (or infiltration) of the tissues, more especially the walls of the minute arteries, into a translucent, highly refractive material, which bears a close resemblance to the translucent material which is met with in cases of amyloid or waxy degeneration. It differs, however, in this important particular from the amyloid material, that it does not give the characteristic reactions with iodine and methy-violet.

Hyaline degeneration of the minute arteries has been observed in diphtheria, typhoid, scarlet fever, and other febrile affections; it is comparatively common in lymphatic glands; is frequently seen in the brain, more especially in the neighbourhood of caseous or hæmorrhagic foci. P. Meyer has shown that it plays an important part in the production of the minute aneurisms which are seen on the terminal branches of the pulmonary artery in cases of phthisis. The same observer has shown that true obliterative thrombi composed of hyaline material may frequently be observed in

infarctions of the spleen and kidney in cases of phthisis. In a case of chronic meningitis with caseous deposits in the pia mater, P. Meyer found at certain points, where the cerebral substance was in a state of hæmorrhagic softening, an infiltration of the walls of the vessels, and often a complete obliteration of their canals by the hyaline substance. He has also seen the afferent arterioles in the kidneys of scarlet fever completely obliterated by hyaline masses; and he records a very remarkable case, in which cerebral symptoms with high temperature developed in the course of an attack of acute rheumatism, and in which a most extensive hæmorrhagic softening of the greater part of the left occipital lobe was found after death, the cerebral lesion being apparently due to the plugging of the minute arteries with refractive hyaline masses.

The exact chemical composition of the hyaline material is unknown.

In some cases the hyaline deposits are, according to Recklinghausen, only products of the death agony, but in others, and amongst these there can be no doubt that the two cases of cerebral tumour to which I am now more especially referring must be included, the hyaline material had evidently been formed during life, and is of distinct pathological importance.

Various opinions have been expressed as to the source of this hyaline material. Almost all observers who have studied the subject seem to think that it is not simple fibrine. According to Recklinghausen, it is a derivative of cellular protoplasm. Most writers seem to think that the white corpuscles of the blood are the source from which it is usually derived, but P. Meyer and others admit that the endothelial cells of the bloodvessels, and in some cases, perhaps, all the elements of the tissues, may be transformed or fused, as it were, into hyaline material. Pitres believes that the hyaline material may be derived from the red blood corpuscles. P. Meyer does not think the evidence on this point conclusive; but I am disposed to think, for the reasons previously stated (see pages 40 and 41), that in the case related above (case of Miss A.) the large crystals, the irregular, transparent masses, and the hyaline material, were probably derivatives of the red rather than the white blood-cells.

Hyaline degeneration is seen where the conditions for satisfactory nutrition are interfered with; anything, whether a chemical or mechanical cause, or a dyscrasia, which interferes with the vitality of cell life, seems to predispose to its production. It is especially liable to occur in the neighbourhood of caseous foci, and in the cerebral arteries in cases of hæmorrhagic extravasation and red softening. Further, the two cases which we are now reporting show that an advanced degree of hyaline degeneration may be met with in cases of glio-sarcomatous tumours of the brain, and suggest the possibility of the hyaline change being a product, not merely

of the extravasated blood corpuscles, but possibly of the glial cells themselves.[1]

I regret that a microscopical examination of the blood was not made during life; and that the great viscera of the thorax and abdomen was not examined at the autopsy.

Dr M'Bride thought that although Dr Leslie laid stress on the absence of giddiness in his case, it was not so much a symptom to be expected in central as in lateral lesions of the cerebellum. Moreover, if he was right in his view that the diseases began some five or six years before death, it was possible to suppose that the other senses might, so to speak, become accustomed to the change, and act, if he might be allowed the term, vicariously. With reference to the difficulty of deglutition and of articulation apart from aphasia in Dr Bramwell's case, he thought that Krause of Berlin, in his experiments on dogs, found a cortical centre in the frontal region which so much influenced the bark as to be entitled to the name "centre for articulation." In the same region, too, Krause found a centre which governed deglutition.

Mr Cathcart remarked that the accurate observations of the effects of purgatives was of importance as throwing light on the question as to whether or not purgatives should be used in head injuries. Lately, some surgeons had objected to their use. Having himself seen benefit derived from them, he was interested to hear of their good effects in the cases described by Drs Bramwell and Leslie.

The President asked if the difficulty of articulation was due to a defective action of the lips, or of the tongue, or laryngeal movements, or a combination of these.

Dr Bramwell said the lips and tongue, not the larynx, were affected.

Dr Leslie said that he believed five years to have been the duration of his case, not quite so long as Dr M'Bride supposed. As to the suggestion that the giddiness might have been got over by habit, one would have expected to have seen some symptoms of the giddiness at first before it was got over in this way. He had recently a case under his treatment in which some of the symptoms closely resembled those of the case described by Drs Bramwell and Foulis. It was that of an old lady to whom he was called when she was in an aphasic condition, in which she stuck on the word "infective." She recovered from this attack in a few days, but during the next two years, till she died, had no less than twenty apoplectiform attacks, in which she appeared to be dying or dead. Constipation was a marked feature of her case also, but he found that extract of cascara had a wonderfully good effect.

[1] For further information as regards hyaline degeneration the reader is referred to Dr P. Meyer's paper, "De la formation et du role de l'hyaline dans les anevrisms et dans les vaisseaux" (*Archives de Physiologie normale et pathologique*, 1880, page 598 *et seq.*), to which I am indebted for many of the foregoing particulars.

Dr Bramwell was interested to hear of Krause's observations. He thought the absence of vertigo might perhaps be explained by supposing that the lesion was a "destroying" rather than a "discharging" one. The most marked case of cerebellar vertigo he had ever seen was examined last week. A secondary carcinomatous tumour occupied the same position in the right lobe of the cerebellum as the cyst in Dr Leslie's case.

Meeting III.—January 19, 1887.

Professor GRAINGER STEWART, *President, in the Chair.*

I. ELECTION OF NEW MEMBERS.

The following gentlemen were admitted Ordinary Members of the Society:—Robert S. Aitchison, M.B.; J. A. Armitage, M.B., C.M., Wolverhampton; J. Walton Hamp, L.F.P.S. Glasg., L.S.A. Lond., Wolverhampton; Wm. Hunter, M.D.; Sidney Rumboll, L.R.C.P. & S., Grangemouth; John Thomson, M.B., C.M.

II. EXHIBITION OF PATHOLOGICAL SPECIMENS.

1. *Dr Skene Keith* showed specimens of DISEASED OVARIES AND TUBES illustrative of his paper.

2. *Dr Bruce* showed A BRAIN taken from a child which had been under the care of Dr Carmichael in the Sick Children's Hospital suffering from what was diagnosed as simple meningitis. It seemed to be a perfectly typical case, and was shown as a contrast to cases of tubercular meningitis in the ward. Shortly after she was admitted she was seized with severe convulsions, and her life was saved by free bleeding from the arm. After that she made a steady recovery. She was dismissed sometime before Christmas as cured, and remained apparently perfectly well till a few days ago, when she was brought in suffering from general convulsions, and died a short time after admission. At the post-mortem an interesting condition of the membranes was discovered which fully confirmed the diagnosis. The surface of the brain was a little congested, but there was nothing remarkable in the membranes at the vertex. On exposing the base of the brain the arachnoid was found to be slightly thickened and milky over pons, sides of medulla, and cerebellum. There was a peculiar projection on the infundibulum, a little cyst with a clear colourless fluid, and on compressing the brain, the contents of this cyst could be increased. On looking at the under surface of the cerebellum and medulla, the fibrous thickening of the membranes had formed an adhesion between the two sides of the latter and amygdala,