

Role of Color Doppler Ultrasonography in Predicting Risk of Malignancy in Thyroid Nodules in Correlation with Ultrasound Guided Fine Needle Aspiration Biopsy

HAZEM H. SOLIMAN, M.D.

The Department of Radiology, Faculty of Medicine, Cairo University

Abstract

Introduction: Thyroid nodules are commonly encountered on ultrasonographic studies. Color doppler ultrasonography can be utilized to help in differentiating malignant and non-malignant nodules based on different imaging criteria.

Objective: The objective of this study is to correlate sonographic and color Doppler characteristics of thyroid nodules with the results of sonographically guided fine-needle aspiration biopsy to establish the relative importance of these features in predicting risk for malignancy.

Patients and Methods: In this study, 103 patients (81 women and 22 men with mean age of 45.2 years) were included between April 2012 and June 2013. The cases were subjected to complete U/S and Doppler examination and the results were compared to U/S guided FNAC. Certain U/S and Doppler criteria were analyzed to predict risk of malignancy including; number, size, echogenicity, structure, margin, calcifications, vascular pattern and RI of the nodules.

Results: The most significant U/S and Doppler criteria that predict malignancy in thyroid nodules are; irregular borders (sensitivity=66.6% and specificity=76.4%), numerous micro calcifications (sensitivity=16.6% and specificity=100%), exclusively central vascularity (sensitivity=50% and specificity=100%) and more central vascularity (central more than peripheral) sensitivity=88.9% and specificity=87%.

Conclusion: The presence of more central vascularity in thyroid nodules strongly suggests malignancy and these nodules should undergo FNAC and that absence of central vascularity in thyroid nodules strongly suggests benignity. Thus, we recommend adding Doppler examination in the evaluation of the thyroid nodules to increase the specificity of U/S examination and to guide the FNAC biopsy.

Key Words: Thyroid – Nodules – Doppler and fine needle.

Introduction

THYROID nodule is a common clinical finding and it is found in the autopsy of approximately 50% of individuals [1]. Ultrasonography (US) is

increasingly able to detect thyroid nodules, and the differentiation between malignant and benign nodules has been raising issues among both clinicians and patients, especially patients with non-palpable small nodules [2].

Power duplex Doppler facilitates screening of thyroid nodules at high risk for malignancy having elevated sensitivity (92.3%) and specificity (88%) [3]. Flow pattern and vascular resistive index could be used as predictors of malignancy risk in thyroid neoplasms. Resistive index values in non-neoplastic nodules were lower than in adenomas and malignant nodules [4].

The evaluation of the vascular pattern and the velocimetric parameters using pulsed and power Doppler ultrasound may provide important information that is useful in making correct differential diagnosis of malignant or benign thyroid follicular tumor preoperatively [5]. Colour Doppler sonography can be useful in differential diagnosis of unclear cases of De Quervain's subacute thyroiditis [6]. Colour Doppler sonography provide important characteristics in differentiating papillary thyroid carcinoma from benign nodules [7].

The following US characteristics were important in differentiating thyroid carcinoma from benign nodules: Location, echogenicity, echotexture, outline, presence of a halo, microcalcifications, and type of vascularization [8].

Duplex ultrasonography in combination with fine-needle aspiration biopsy are used for early diagnosis of thyroid cancer making accurate diagnosis before hospitalization and to plan treatment and surgical policy correctly [9].

Ultrasonography (US) of the thyroid gland has proved to be a useful clinical diagnostic method,

Correspondence to: Dr. Hazem H. Soliman, The Department of Radiology, Faculty of Medicine, Cairo University

and the newly developed high-resolution US with a color Doppler flow mapping function can reveal fine details of the thyroid gland and the hemodynamic features of a thyroid neoplasm. US with the color Doppler function can play an important role in the differential diagnosis of thyroid tumors [10].

All thyroid nodules that show the presence of intrinsic microcalcification should undergo biopsy [11]. Ultrasonography, color-Doppler and ultrasound-guided fine-needle aspiration biopsy have made minimally invasive thyroid surgery possible [12]. An evaluation of the peak systolic velocity proved to be very useful in the differential diagnosis between adenomas and cancers. The color Doppler ultrasonography represents a sound method for evaluating thyroid nodules [13].

Manually guided FNAB is not feasible in non-palpable nodules and not accurate in a multinodular goiter and ultrasound-guided fine-needle aspiration biopsy should be performed for accurate FNAB under these circumstances [14]. US-guided FNAB should be performed on all 8-15mm hypoechoic nodules with irregular margins, intranodular vascular spots or microcalcifications [15]. Certain sonographic risk factors are able to detect the majority of carcinoma and limit the FNAC procedures to the thyroid nodules [16].

Patients and Methods

This study was conducted on 103 cases (81 women and 22 men) referred mainly from surgical department at our institute.

Their ages ranged between 17 and 65 years (mean age 45.2 years).

All the selected patients had one or more palpable or non palpable thyroid nodules.

All patients are subjected to the following:

History:

- Personal history: Name, age and sex.
- Present history: Complaint of the patient with its duration and course e.g. neck swelling, dyspnea, dysphagia, change of voice, loss of weight, eye symptoms and nervous manifestations.
- Past history: Medical treatment, operations or irradiation.

Examination:

- General Examination: Nervous manifestations, Eye changes, Cardio vascular manifestations.

- Local examination: Swelling, mobility, fixity, scar of previous operation, size of the gland, nodularity, associated enlarged lymph nodes.

U/S and Color Doppler:

- The U/S and Color Doppler examination of the thyroid gland were carried out in the radio diagnosis department, Cairo University using a high resolution ultrasound equipped with a 12-15MHz linear probe.
- The examination was done without any preparation of the patient. Using high-resolution thyroid ultrasonography.
- The transducer was applied to the neck using adequate amount of acoustic gel, the neck was hyper extended and the chin was elevated.
- Each lobe was examined carefully in transverse and longitudinal planes. Then the thyroid isthmus was also examined.
- After completion of complete U/S examination, Color Doppler examination was done for detection of the vascularity of the thyroid nodules and calculation of the Resistive Index (RI).

B-Mode U/S analysis:

- Based on the number of nodules visualized, thyroid glands were classified as having a solitary nodule or as being multinodular. The maximum diameters of each nodule were measured, and nodule features evaluated.
- Nodule echogenicity was compared with that of normal adjacent thyroid tissue. Each nodule was classified as being hypoechoic, hyperechoic, isoechoic, anechoic (cysts with no solid components).
- Nodule structure was classified as solid, cystic or mixed (nodules with cystic and solid components).
- The margin of a nodule was categorized as well-defined smooth with completely uniform peripheral halo or ill-defined without or with non uniform peripheral halo.
- Calcification, when present, was classified as micro-calcification (hyperechoic punctuate foci <2mm in diameter, with or without posterior shadowing) or coarse macro-calcification (hyperechoic foci >2mm in diameter with posterior shadowing). Micro calcification was further divided into few/countable or too numerous to count.

Color doppler analysis:

- Color and power Doppler analysis of blood flow to the nodules revealed the following vascular patterns:
 - I- Absence of signal blood flow.
 - II- Exclusively perinodular blood flow.
 - III- Perinodular blood flow \geq central blood flow.
 - IV- Marked central blood flow and less significant perinodular blood flow.
 - V- Exclusively central blood flow.
- In addition to the qualitative analysis (color and power Doppler), arterial blood flow to nodules was quantified via spectral analysis.
- RI was calculated based on the formula $RI = \frac{PSV - MDV}{PSV}$.
- The peripheral and central nodule artery samples were selected by mapping the brightest on color Doppler ones.

U/S guided FNAC:

- Sonographically guided FNAC was then performed.
- A 22 gauge needle is used with an attached 3 ml syringe. The transducer is placed directly over the lesion. Color Doppler mapping to depict any large blood vessels in and around the nodule so that vascular injury can be avoided during the procedure. The patient is instructed not to swallow or speak during the insertion of the needle. A freehand biopsy technique is used, and the syringe attached to the needle is placed just above the transducer. The needle may be introduced parallel or perpendicular to the transducer, and the needle tip should be carefully monitored during the procedure. Aspiration and non aspiration methods are used. When the needle reaches the target, the biopsy is performed. During the procedure, all needle movements should be continuously visualized in real time. It is recommended that aspiration be performed at least twice. The collected material is placed on glass slides, smeared, and fixed in 95% ethyl alcohol. The syringe could be rinsed with normal saline solution to obtain any remaining material for use in cell blocking. After the procedure, plaster is applied, and the patient should be instructed to manually compress.
- In cases of multiple nodules, the selection criteria were based on both the dominant nodule and also were based on U/S and Doppler criteria.

- Cytology findings were classified into:

- A- Diagnostic or suggestive of malignancy, each of which was later confirmed by a pathologic specimen.
- B- Benign.
- C- Indeterminate.

- Taking into account that all nondiagnostic biopsies were repeated (if possible) until adequate cellularity was achieved for diagnosis, otherwise it was not included in our results.

Pathologic specimens:

Total, partial or hemithyroidectomy was performed in:

- All cases in which cytology was diagnostic or suggestive of malignancy.
- All cases in which cytology was indeterminate.
- Some benign cases that underwent surgery.

Results

The total number of the examined cases was 103 including 81 females and 22 males. The mean age was 45.2 years without any significance between males and females.

Tables (1-7) illustrate the U/S and doppler findings of the examined thyroid nodules.

Table (1): Illustrates outlines/borders of the thyroid nodules. It shows that the malignant cases had irregular borders in 66.7% of cases versus 23.6% of benign cases.

Outline/ Borders	Benign		Malignant		Total	
	No.	%	No.	%	No.	%
Regular	65	76.4	6	33.3	71	68.9
Irregular	20	23.6	12	66.7	32	31.1
Total	85	100	18	100	103	100

These findings were highly statistically significant ($X^2=12.91$, $DF=1$, p -value=0.000328).

Table (2): Illustrates the number of the thyroid nodules in the cases. It showed that 35.3% of benign cases had single nodule versus 83.3% of malignant cases.

Number of nodules	Benign		Malignant		Total	
	No.	%	No.	%	No.	%
Single	30	35.3	15	83.3	45	43.6
Multiple	55	64.7	3	16.6	58	56.4
Total	85	100	18	100	103	100

These differences were statistically significant ($X^2=0.23$, $DF=1$, p -value=0.05).

Table (3): Illustrates the echogenicity of the thyroid nodules. Hypo, iso and hyper echogenicity were found in 50% and 45% and 5% in malignant cases respectively.

Echogenicity	Benign		Malignant		Total	
	No.	%	No.	%	No.	%
Hypo	25	29.4	9	50	34	33
Iso	55	64.7	8	45	63	61.1
Hyper	5	5.9	1	5	6	5.9
Total	85	100	18	100	103	100

Although the percentage of hypo was higher in malignant cases (50%) than benign cases (29.4%) the differences were statistically not significant (X²=2.91, DF=2, p-value=0.2).

Table (5): Illustrates the echo structure of the nodules. The solid structure was observed in 88.9% and in 80% of malignant and benign cases respectively. Pure cystic structure was among 14.1% of benign cases and 0% in malignant cases.

Echostructure	Benign		Malignant		Total	
	No.	%	No.	%	No.	%
Solid	68	80	16	88.9	84	81.6
Cystic	12	14.1	0	0	12	11.6
Mixed	5	5.9	2	11.1	7	6.8
Total	85	100	18	100	103	100

These findings were statistically not significant (X²=3.28, DF=2, p-value=0.193).

Tables (7-9) illustrate the FNAC findings of the examined thyroid nodules.

Table (7): Illustrates the classification of cytological findings. It was classified into diagnostic (either benign or malignant) or indeterminate. Thirteen cases (12.6%) were indeterminate by cytology.

Cytological results	Diagnostic	Indeterminate	Total
Number	90	13	103
%	87.4	12.6	100

Table (8): Illustrates classification of benign cases. The majority of benign cases (63.5%) were nodular goiter.

	No.	%
Nodular goiter	54	63.5
Follicular adenoma	10	11.8
Colloid nodule/cyst	15	17.6
Thyroiditis	5	5.9
simple cyst	1	1.2

Table (4): Illustrates the presence or absence of macro/micro calcifications. It showed that numerous micro calcifications were found in 16.6% of malignant cases. No benign cases showed too numerous micro calcifications.

Calcification	Benign		Malignant		Total	
	No.	%	No.	%	No.	%
Numerous Micro	0	0	3	16.6	3	2.9
Few/countable Micro	6	7	2	11.1	8	7.8
Macro	6	7	1	5.6	7	6.8
Absent	73	86	12	66.7	85	82.5
Total	85	100	18	100	103	100

The differences were statistically significant (X²=15.59, DF=2, p-value=0.0004).

Table (6): Illustrates the vascularization of the thyroid nodules. It showed that 89% of malignant cases had central vascularity (exclusively central or central more than peripheral). While 87.1% of benign cases were avascular or had mainly peripheral vascularity (exclusively peripheral or peripheral more than central).

Vascularization	Benign		Malignant		Total	
	No.	%	No.	%	No.	%
Absent	28	33	0	0	28	27.2
Perinodular	26	30.6	1	5.5	27	26.2
Perinodular >Central	20	23.5	1	5.5	21	20.4
Central >Perinodular	11	12.9	7	39	18	17.5
Central	0	0	9	50	9	8.7
Total	85	100	18	100	103	100

These findings were highly statistically significant (X²=60.06, DF=4, p-value=0.000001).

Table (9): Illustrates classification of malignant cases. The majority of malignant cases (72.3%) were papillary carcinoma.

	No.	%
Papillary carcinoma	13	72.3
Follicular carcinoma	3	16.7
Medullary carcinoma	1	5.5
Anaplastic carcinoma	1	5.5

The most significant U/S and Doppler criteria that predict malignancy in thyroid nodules are:

- Irregular borders (sensitivity=66.6% and specificity=76.4%).
- Numerous micro calcifications (sensitivity=16.6% and specificity=100%).
- Exclusively central vascularity (sensitivity=50% and specificity=100%).
- More central vascularity (exclusively central or central more than peripheral) sensitivity=88.9% and specificity=87%.

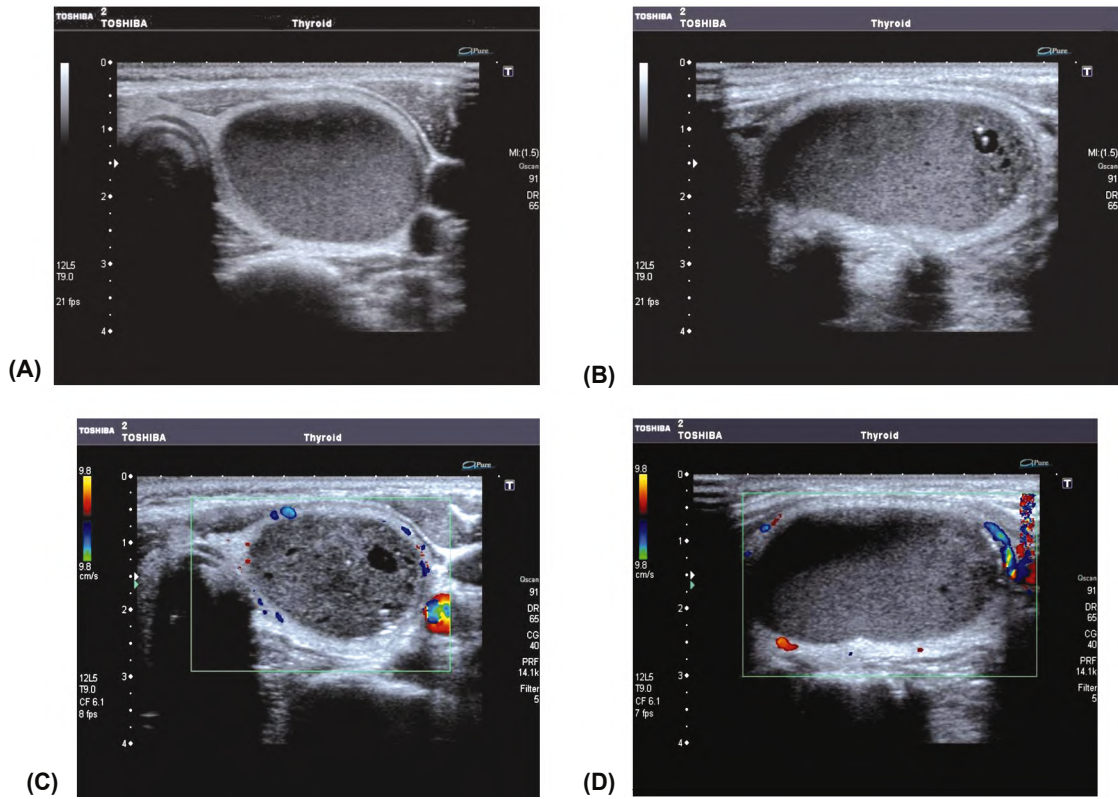


Fig. (1): A 22 year old female patient with a firm thyroid swelling of 2 month duration. (A,B) Ultrasound revealed a single, cystic, hypoechoic nodule with macrocalcifications. (C,D) Doppler demonstrated exclusive perinodular vascularization. FNAC revealed a colloid cyst.

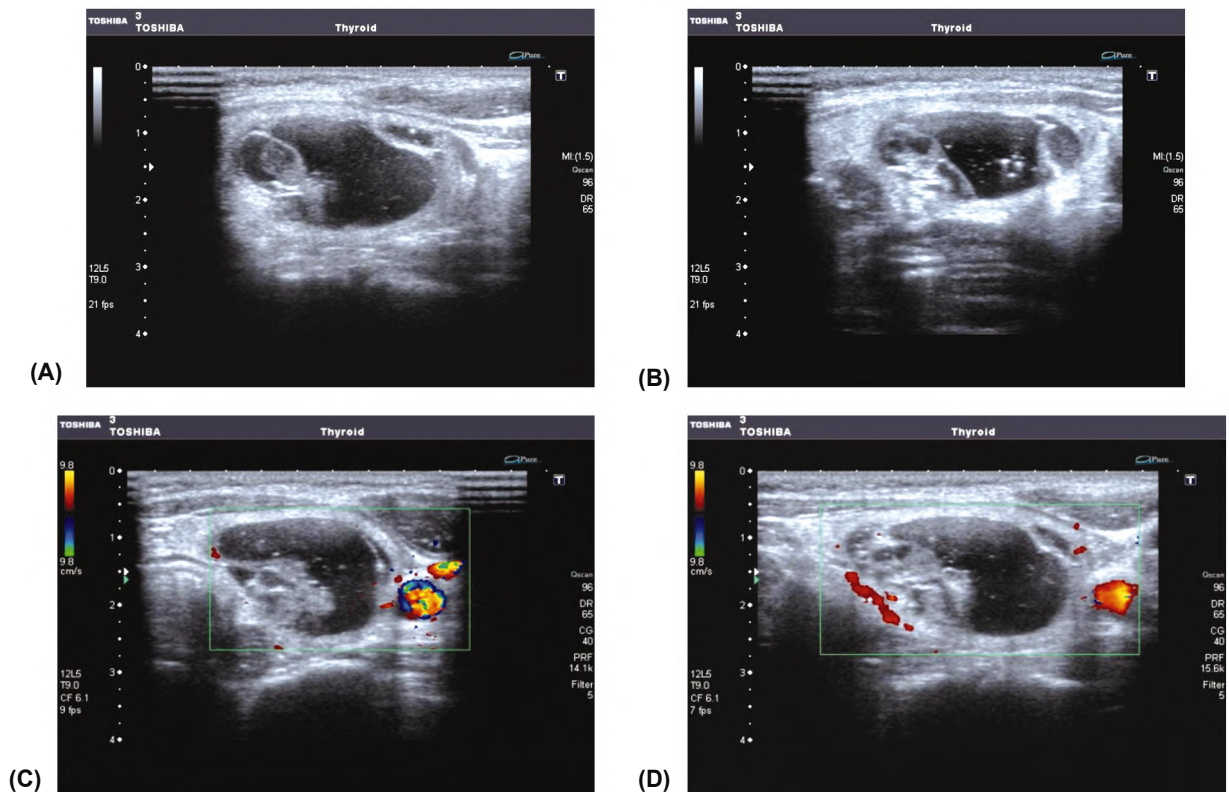


Fig. (2): A 27 year old female with a firm thyroid swelling of 1 month duration. (A,B) Ultrasound revealed a single, mixed cystic and solid, iso-hypoechoic nodule with micro and macrocalcifications. (C,D) Doppler demonstrated exclusive perinodular vascularization. FNAC revealed a colloid cyst.

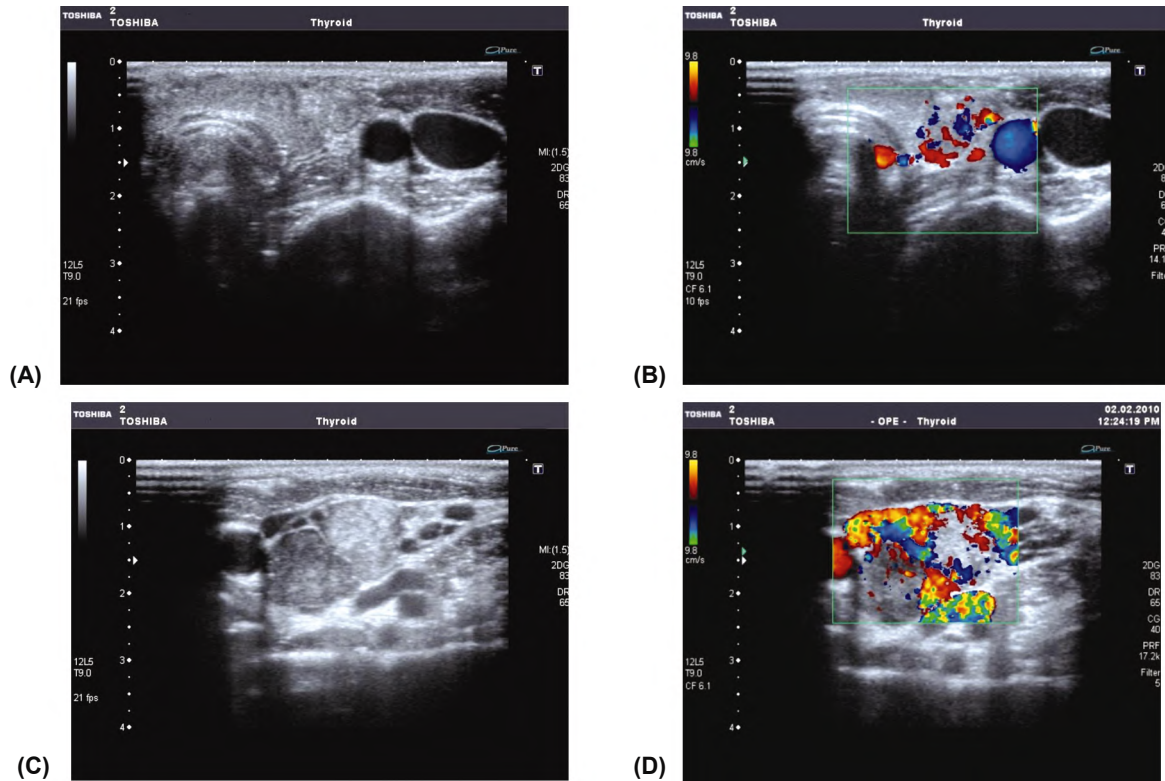


Fig. (3): A 22 year old male with a hard thyroid swelling of 1 month duration. (A,C) Ultrasound revealed two, solid, isoechoic nodules with no calcifications. (B,D) Doppler demonstrated exclusive central vascularization with enlarged vascular lymph nodes. FNAC and histopathology revealed papillary carcinoma with nodal metastases.

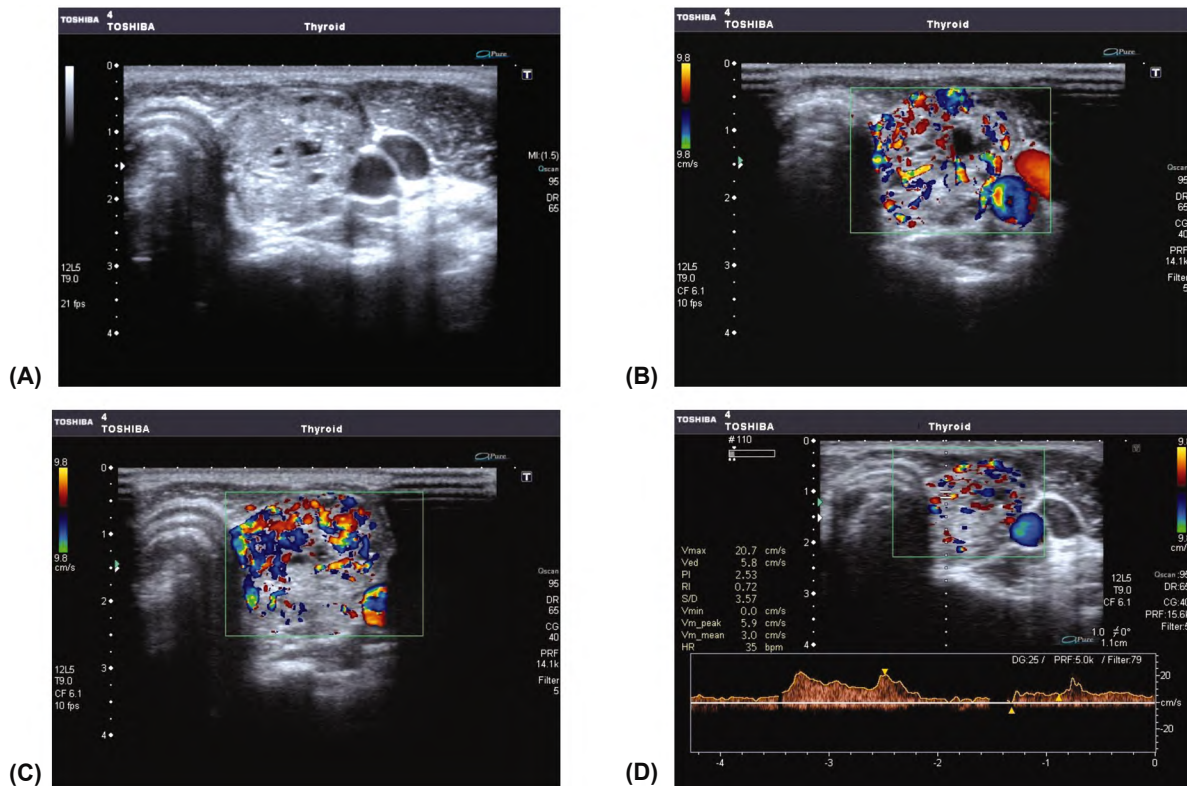


Fig. (4): A 20 year old female with a thyroid swelling of 4 months duration. (A) Ultrasound revealed a single, mixed, isoechoic nodule with irregular border and absent peripheral halo. (B,C) Doppler demonstrated central more than perinodular vascularization. (D) Doppler showed RI of 0.72. FNAC was indeterminate while histopathology revealed follicular carcinoma.

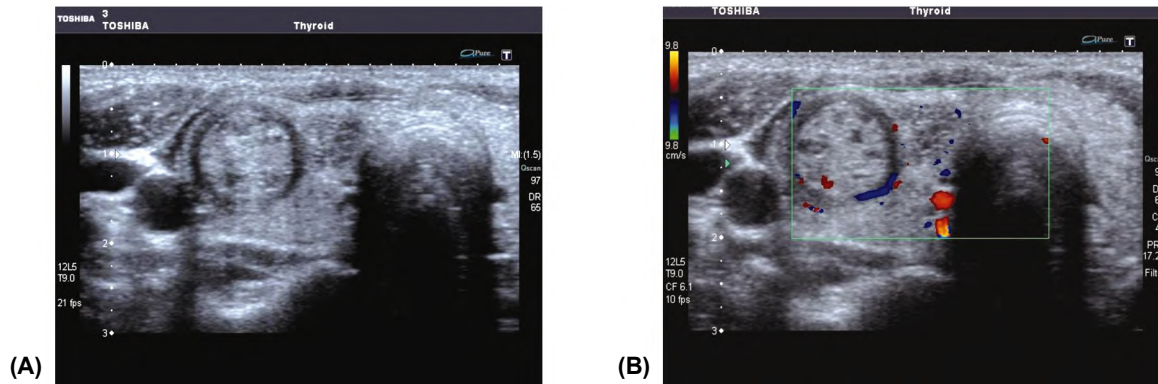


Fig. (5): A 33 year old female with a right neck swelling of 9 months duration. (A) Ultrasound revealed a two, mixed, hypoechoic nodules with regular border and peripheral halo. (B) Doppler demonstrated exclusive perinodular vascularization. FNAC was undeterminate while histopathology revealed follicular adenoma.

Discussion

Thyroid nodules are very common they are found in 4%-8% of adults by means of palpation, in 10%-41% by means of US. The prevalence of thyroid nodules increases with age. Compared with the very high prevalence of nodular thyroid disease, thyroid cancer is not common [17].

The majority (75%-80%) of new cases of thyroid cancer diagnosed will be papillary thyroid cancer. Other histologic types of thyroid cancer include follicular (10%-20%), medullary (3%-5%), and anaplastic (1%-2%) cancers [18].

The likelihood that a nodule is malignant is affected by a variety of risk factors [19]. Neck irradiation and a family history of thyroid cancer increase the risk that a thyroid nodule is malignant [20].

The most common follicular cell-derived cancer is papillary thyroid carcinoma, and it is generally accepted that the 30-year survival rate for this malignancy is approximately 95%. Most patients with papillary cancer (80%-85%) are considered to be low risk, with 99% survival at 20 years after surgery [17].

Several investigators have demonstrated that the incidence of thyroid cancer in incidentally identified or non palpable thyroid nodules is the same as that in patients with palpable nodules [21]. Several studies have sought to identify sonographic features that are both sensitive and specific for malignant versus benign disease, but currently much debate exists as to whether such features have been successfully identified [22].

This method is often insufficient for characterizing the nature of the lesion (ie, low specificity).

Therefore, FNAB has emerged as the default diagnostic test for the preoperative evaluation of intrathyroid lesions. In light of the lack of certainty present in predicting pathologic nature on the basis of sonographic features of thyroid nodules, many institutions have now adopted the practice of performing biopsy on all nodules that appear larger than 1.0cm in diameter on sonographic examination without regard to sonographic appearance. Although FNAB is almost noninvasive, it does have several disadvantages and it is not accepted to be done to every thyroid nodule [3].

Sonographically guided FNA biopsy of all incidentally detected thyroid nodules would be very costly venture and would have a very low yield in identifying the small proportion of nodules that actually represent malignant disease [11]. Thus, identifying a new method to determine which nodules should be studied by this examination (FNAC) is mandatory [3].

Thus, the purpose of this study was to further evaluate the correlation between various sonographic and doppler features of thyroid nodules and their risk of malignancy in an attempt to suggest an optimal diagnostic approach to further work up of these lesions.

In this study, 103 cases were included from which 81 cases were females (78.6%) and 22 cases were males (21.4%). Thus this study reinforce that thyroid nodules are more common in females. In Chammas et al., [3], 91.3% of the studied cases were females.

In Chammas et al., [3], the mean age of the studied cases was 50.2. In Lannuccili et al., [11], it was 45.9 and 49 in Lyshchik et al., [8]. In Moon et al., [24], it was 49.5 years. The incidence of thyroid malignancy in this study was 17.4% of the

examined cases. In Chammas et al., [3], it was 12.4% of the examined cases. In Lannuccili et al., it was 5.33%. It was 9.2%-13% in Hegedus et al., [19].

In our study, the main complaint of patients was neck swelling (63.6% and 71.6% in malignant and benign cases respectively). In our study, fixity of the gland was found only in three malignant cases. Associated significantly enlarged cervical Lymph nodes were found in significantly higher percent of malignant cases (27.7%).

In this study 58 cases had multiple thyroid nodules, we found malignancy in only three of them. Forty five cases had single thyroid nodule, we found malignancy in 15 cases of them. So, we concluded that the incidence of malignancy in cases with multiple nodules is about 5%, however it was about 33% in cases with single nodule.

Some authors have reported that the risk for malignancy of a solitary thyroid nodule ranges from 10% to 25% and that the risk for nodules associated with a multinodular gland is 1 % to 4%. However, other reports in the literature challenge the validity of these data. Solbiati et al., [23] have reported malignant rates for nodules in multinodular glands of 13% and 30%, respectively [3].

Chammas et al., [3] reported that they found that 9 (69%) of 13 malignant nodules were in multinodular glands. Chammas et al., [3] reinforce the idea that multinodularity does not mean benign disease. Frates et al., [17] stated that, in patients with multiple nodules, the cancer rate per nodule decreases, but the decrease is approximately proportional to the number of nodules so that the overall rate of cancer per patient, 10%-13%, is the same as that in patients with a solitary nodule.

Another point is the echogenicity of the nodules; we found that hypoechoic and isoechoic nodules accounted for the majority of nodules (33% and 61% respectively). In our study, 50% of malignant nodules were hypoechoic, 45% of malignant nodules were isoechoic and 5% of malignant nodules were hyperechoic. Although the percentage of hypo was higher in malignant cases (50%) than benign cases (29.4%) the differences were statistically not significant ($X^2=2.91$, $DF=2$, p -value=0.2).

Chammas et al., [3] found that (69.23%) of malignant nodules were hypoechoic. Lannuccili et al., [11], stated that 47.1 % of the malignant nodules were hypoechoic, 47.1% of malignant nodules are isoechoic and 5.8% of malignant nod-

ules were hyperechoic. Moon et al., [24] classified the nodules into markedly hypoechoic (when the nodules were more hypoechoic than the strap muscles), hypoechoic (when they were more hypoechoic than the normal thyroid), isoechoic and hyperechoic than normal thyroid. They formed 41.4%, 46.1%, 11.9% and 0.6% of malignant nodules respectively.

In our study, the solid structure was observed in most of the nodules 88.9% and 80% of malignant and benign cases respectively. Pure cystic structure was among 14.1 % of benign cases while was zero in malignant cases. Mixed structure was observed in 11.1% and 5.9% of malignant and benign cases respectively. These findings were statistically not significant ($X^2= 3.28$, $DF=2$, p -value=0.193).

Chammas et al., [3] stated that (30.77%) of malignant nodules had mixed echogenicity. Lannuccili et al., [11], stated that 85.3% and 83.3% of malignant and benign cases respectively were solid. He stated also that 11.8% and 11.1% of malignant and benign cases respectively were mixed with no statistically significant difference.

We found that malignant cases had irregular borders in 66.7% of cases versus 23.6% of benign cases. These findings were highly statistically significant ($X^2=12.91$, $DF=1$, p -value=0.000328). Chammas et al., [3] stated that the presence of regular border with uniform peripheral halo was considered significant evidence of benignity. Similarly, the absence of halo and presence of irregular borders was statistically significant evidence of a malignancy. Moon et al., [24] agreed with the previous results. He stated that 67.5% of malignant cases in the study had irregular or speculated borders.

Lannuccili et al., [11] classified the borders into four grades according to their definition and according to the degree of peripheral halo distinction. However; he stated no statistically significant difference between benign and malignant lesions. Chammas et al., [3] stated also that increased halo thickness was another significant indicator of malignancy; this point was not included in our evaluation.

Another significant point in the evaluation of the thyroid nodules is presence or absence of calcifications. We found numerous micro calcifications in 16.6% of malignant cases. No benign cases in our study showed numerous micro calcifications. The differences were statistically significant ($X^2=15.59$, $DF=2$, p -value=0.0004).

Lannuccili et al., [11] found too numerous micro calcifications in 14.7% and 0% of malignant and benign cases respectively. They conclude that presence of too numerous micro calcifications is a good predictor of malignancy. Chammas et al., [3] stated also that micro calcifications are a good predictor of malignancy.

We found in our study that 86% and 66.7% of malignant and benign cases respectively showed no calcifications. So, absence of calcification has no role in predicting benign or malignant lesions. Lannuccili et al., [11] found also that 94.4% and 64.7% of benign and malignant cases respectively show no calcification.

We found that the average largest diameter of the benign and malignant nodules was 2cm (SD=0.8) and 2.5cm (SD=0.8) respectively with no significant difference. This was accepted by Lannuccili et al., [11] who stated that the difference in size between benign and malignant nodules is statistically not significant. However, Chammas et al., [3] stated that malignant and suspicious nodules were significantly larger than benign nodules. The average width of benign nodules was 1.41cm versus 3.19cm for malignant nodules and these results were statistically significant.

We classify the vascular patterns of the thyroid nodules into:

- I: Absence of signal blood flow.
- II: Exclusively perinodular blood flow.
- III: Perinodular blood flow \geq central blood flow.
- IV: Marked central blood flow and less significant perinodular blood flow.
- V: Exclusively central blood flow.

We found that 89% of malignant cases had central vascularity (exclusively central or central more than peripheral). While 87.1 % of benign cases were avascular or had mainly peripheral vascularity (exclusively peripheral or peripheral more than central). These findings were highly statistically significant ($X^2=60.06$, $DF=4$, p -value=0.000001). We found that 9 cases had exclusively central vascularity, all of them are malignant. No benign cases had exclusively central vascularity.

Chammas et al., [3], found 5 cases had exclusively central vascularity, all of them were malignant. Lagalla et al., [25] and Solbiati et al., [23], demonstrate that exclusively central blood flow strongly suggests malignancy. Chammas et al., [3], found exclusively perinodular blood flow in 65 cases from which 59 cases were benign.

These data are in agreement with our findings. We found 27 cases had exclusively perinodular blood flow from which 26 cases were benign and only one was malignant.

In our study, there was no blood flow in 28 cases (27.2%), all of them were benign, and none of these cases were malignant. Chammas et al., [3] found no blood flow in 12 nodules, and none of these nodules were malignant. They stated that absence of signal blood flow occurs only in benign lesions.

We found perinodular more than central vascularity in 22 cases from which 21 cases were benign and one was malignant. We also found central more than peripheral in 18 cases from which 11 were benign and 7 were malignant. Chammas et al., [3] stated that the risk of malignancy increases as intra nodular blood flow becomes more dominant. Cerbone et al., [27] proposed that the predominantly intranodular blood flow observed in malignant nodules could be explained by the large cellular proliferation in this region.

We found that RI was >0.7 in 12 of 18 malignant cases (66.6%). It was <0.7 in 51 of 85 benign cases (60%). Cerbone et al., [27] reported that RI was >0.75 in 18 (85.7%) of 21 thyroid carcinomas. Holden reported a mean RI of 0.76 for thyroid carcinomas.

We conclude that the most significant U/S and Doppler criteria that predict malignancy in thyroid nodules are; irregular borders, numerous micro calcifications and more central vascularity (exclusively central or central more than peripheral).

References

- 1- RAHIMI M., FARSHCHIAN N., REZAEI E., SHAHEBRAHIMI K. and MADANI H.: To differentiate benign from malignant thyroid nodule comparison of sonography with FNAC findings. Pak. J. Med. Sci., 29 (1): 77-80, 2013.
- 2- AL-SINDI K., BUKHARI M., SABA K., ALI W., ARSHAD M. and ZAIDI N.: Evaluation of non-palpable thyroid nodules by ultra sound guided fine needle aspiration cytology. Natural science Vol. 5, No. 2: 214-20, 2013.
- 3- CHAMMAS M.C., RENE G., ILKA R., AZZO W., NESTOR D.B., MARCELO D., ALBERTO F. and GIOVANNI G.: American Academy of Otolaryngology-Head and Neck Surgery Foundation, Volume 132 Number 6, 2005.
- 4- DE NICOLA H., SZEJNFELD J., LOGULLO A.F., WOLOSKEWICZ A.M., SOUZA L.R. and CHIFERI V.: Flow pattern and vascular resistive index as predictors of malignancy risk in thyroid follicular neoplasms. J. Ultrasound Med., 24 (7): 897-904, 2005.

- 5- MEGUMI M., NORITAKA O., MIYUKI E., IZUMI F., KAZUE T., TAKAHIRO O. and TAKAO O.: Diagnosis of thyroid follicular carcinoma by the vascular pattern and velocimetric parameters using high resolution pulsed and power Doppler ultrasonography. *Endocrine Journal*. Vol. 52, No. 2: 207-12, 2005.
- 6- KUNZ A., BLANK W. and BRAUN B.: De Quervain's subacute thyroiditis. Colour Doppler sonography findings. *Ultraschall Med.* 26 (2): 102-6, 2005.
- 7- SHIMURA H., HARAGUCHI K., HIEJIMA Y., FUKUNARI N., FUJIMOTO Y., KATAGIRI M., KOYANAGI N., KURITA T., MIYAKAWA M., MIYAMOTO Y., SUZUKI N., SUZUKI S., KANBE M., KATO Y., MURAKAMI T., TOHNO E., TSUNODA-SHIMIZU H., YAMADA K., UENO E., KOBAYASHI K., KOBAYASHI T., YOKOZAWA T. and KITAOKA M.: Distinct diagnostic criteria for ultrasonographic examination of papillary thyroid carcinoma: a multicenter study. *Thyroid*, 15 (3): 251-8, 2005.
- 8- LYSCHCHIK A., DROZD V., DEMIDCHIK Y., REINERS C.: Diagnosis of thyroid cancer in children. Value of gray-scale and power Doppler US. *Radiology*, 235 (2): 604-13, 2005.
- 9- ERSHOVA G.I.: Methods of improvement of diagnosis of thyroid cancer. *Khirurgiia (Mosk)*, (12): 47-9, 2005.
- 10- FUKUNARI N., NAGAHAMA M., SUGINO K., MIMURA T., ITO K. and ITO K.: Clinical evaluation of color Doppler imaging for the differential diagnosis of thyroid follicular lesions. *World J. Surg.*, 28 (12): 1261-5, 2004.
- 11- LANNUCCILLI J.D., CRONAN J.J. and MONCHIK J.M.: Risk for malignancy of thyroid nodules as assessed by sonographic criteria: The need for biopsy. *J. Ultrasound Med.*, 23 (11): 1455-64, 2004.
- 12- TAKAMI H., IKEDA Y., MIYABE R., OKINAGA H., KAMEYAMA K. and FUKUNARI N.: Radiological and surgical management of thyroid neoplasms. *Biomed Pharmacother*, 58 (6-7): 360-4, 2004.
- 13- CASELLA C., TALARICO C., LA PINTA M., NASCIMBENI R., DI FABIO F. and SALERNI B.: The role of color flow-Doppler Ultrasonography in the diagnosis of nodular goiter. *Ann. Ital. Chir.*, 74 (5): 495-9, 499-500, 2005.
- 14- DEANDREA M., MORMILE A., VEGLIO M., MOTTA M., PELLERITO R., GALLONE G., GRASSI A., TORCHIO B., BRADAC R., GARBEROGLIO R. and FONZO D.: Fine-needle aspiration biopsy of the thyroid: Comparison between thyroid palpation and ultrasonography. *Endocr Pract.*, 8 (4): 282-6, 2002.
- 15- PAPINI E., RINALDO G., ANTONIO B., ANNA C., SILVIA T., FRANCESCO N., CLAUDIO P., ROBERTA R., VINCENZO T. and CLAUDIO M.P.: Risk of malignancy in nonpalpable thyroid nodules: Predictive value of ultrasound and color Doppler features. *The Journal of Clinical Endocrinology and Metabolism*, Vol. 87. No. 5 1941-6, 2002.
- 16- CAPPELLI C., PIROLA I., CUMETTI D., MICHELETTI L., TIRONI A., GANDOSSO E., MARTINO E., CHERUBINI L., AGOSTI B., CASTELLANO M., MATTANZA C. and ROSEI E.A.: Is the anteroposterior and transverse diameter ratio of nonpalpable thyroid nodules a sonographic criteria for recommending fine-needle aspiration cytology? *Clin. Endocrinol. (Oxf)*, 63 (6): 689-93, 2005.
- 17- FRATES M.C., BENSON C.B. and CHARBONEAU J.W.: Management of thyroid nodules detected at US: Society of Radiologists in Ultrasound consensus conference statement. *Radiology*, 237: 794-800, 2005.
- 18- JEMAL A., MURRAY T., WARD E., TIWARI R.C., FEUER E.F. and THUN M.J.: Cancer statistics, 2005. *C.A. Cancer J. Clin.*, 55: 10-30, 2005.
- 19- HEGEDUS L., BONNEMA S.J. and BENNEDBAEK F.N.: Management of simple nodular goiter: Current status and future perspectives. *Endocr. Rev.*, 24: 102-32, 2003.
- 20- SHERMAN S.I., ANGELOS P. and BALL D.: Thyroid carcinoma. *J. Natl. Compr. Canc. Netw.*, 3: 404-57, 2005.
- 21- WIENKE Jr., CHONG W.K., FIELDING Jr., ZOU K.H. and MITTELSTAEDT C.A.: Sonographic features of benign thyroid nodules: Interobserver reliability and overlap with malignancy. *J. Ultrasound Med.*, 22: 1027-31, 2003.
- 22- KANG H.W., NO J.H. and CHUNG J.H.: Prevalence clinical and ultrasonographic characteristics of thyroid incidentalomas. *Thyroid*, 14: 29-33, 2004.
- 23- SOLBIATI L., LIVRAGHI T., BALLARATI E.: Ultrasound of superficial structures: High frequencies, Doppler and interventional procedures. New York, NY: Churchill Livingstone, 1995.
- 24- MOON W.J., SO L.J., JEONG H.L., DONG G.N., JUNG-HWAN B., YOUNG H.L., JINNA K., HYUN S.K., JUN S.B. and DONG H.L.: For the Thyroid Study Group, Korean Society of Neuro-and Head and Neck Radiology Head and Neck Imaging: US of benign and malignant thyroid nodules. *Radiology*, 3: 247, 2008.
- 25- LAGALLA R., CARUSO G. and NOVARA V.: Analisi flussimetrica nella patologia tiroidea: Ipotesi di integrazione con lo studio qualitativo con color-Doppler. *Radiol. Med.*, 85: 606-10, 1993.
- 26- HOLDEN A.: The role of colour and duplex Doppler ultrasound in the assessment of thyroid nodules. *Australian Radiol.*, 39: 343-9, 1995.
- 27- CERBONE G., SPIEZI S. and COLAO A.: Power Doppler improves the diagnostic accuracy of color Doppler ultrasonography in cold thyroid nodules: Follow-up results. *Hormone Res.*, 52: 19-24, 1999.

الملخص العربي

العقيدات الدرقية هي شائعة التواجد في دراسات الموجات فوق الصوتية. يمكن أن تستخدم الموجات فوق الصوتية والدوبلر الملون للمساعدة في تمييز العقيدات الخبيثة وغير الخبيثة، استناداً إلى معايير مختلفة من التصوير.

الهدف من هذه الدراسة الربط بين خصائص الموجات فوق الصوتية والدوبلر الملون لعقيدات الغدة الدرقية مع نتائج عينات عن طريق الإبرة الدقيقة بواسطة الموجات فوق الصوتية في تحديد الأهمية النسبية لهذه الميزات في التنبؤ بخطر الإصابة بالأورام الخبيثة.

هذه الدراسة احتوت على ١٠٣ مريض تم ادراجهم ما بين أبريل ٢٠١٢ ويونيو ٢٠١٣ تم عمل الموجات فوق الصوتية والدوبلر الملون لعقيدات الغدة الدرقية في جميع المرضى ومقارنتها مع نتائج عينات عن طريق الإبرة الدقيقة بواسطة الموجات فوق الصوتية.

بعض معايير الموجات فوق الصوتية والدوبلر للتنبؤ بالأورام الخبيثة، بما في ذلك: العدد، الحجم، الهامش، الهيكل، التكتلات، نمط الأوعية الدموية وري العقيدات

وقد أبرزت نتائج الدراسة أن أهم معايير التنبؤ بالأورام الخبيثة في عقيدات الغدة الدرقية هي: الحدود غير المنتظمة (حساسية ٦٦.٦٪/ وخصوصية ٧٦.٤٪)، تكتلات صغيرة عديدة (الحساسية ١٦.٦٪ وخصوصية ١٠٠٪)، الأوعية الدموية المركزية (حساسية ٥٠٪ وخصوصية ١٠٠٪) الأوعية الدموية المركزية أكثر من طرفيه (الحساسية ٨٨.٩٪ وخصوصية ٨٧٪).

نستنتج أن الموجات فوق الصوتية والدوبلر الملون لها دور فعال في التنبؤ بوجود الأورام الخبيثة في عقيدات الغدة الدرقية وبالتالي، نوصى بإضافة فحص دوبلر في تقييم العقيدات الدرقية لزيادة حساسية وخصوصية الموجات فوق الصوتية.