

PUBLISHED BY

# INTECH

open science | open minds

World's largest Science,  
Technology & Medicine  
Open Access book publisher



**3,200+**  
OPEN ACCESS BOOKS



**105,000+**  
INTERNATIONAL  
AUTHORS AND EDITORS



**110+ MILLION**  
DOWNLOADS



**BOOKS**  
DELIVERED TO  
151 COUNTRIES

AUTHORS AMONG

**TOP 1%**  
MOST CITED SCIENTIST



**12.2%**  
AUTHORS AND EDITORS  
FROM TOP 500 UNIVERSITIES



Selection of our books indexed in the  
Book Citation Index in Web of Science™  
Core Collection (BKCI)

**WEB OF SCIENCE™**

Chapter from the book *Liver Biopsy in Modern Medicine*

Downloaded from: <http://www.intechopen.com/books/liver-biopsy-in-modern-medicine>

Interested in publishing with InTechOpen?  
Contact us at [book.department@intechopen.com](mailto:book.department@intechopen.com)

# Immunohistochemical Staining of Liver Grafts for Recurrent Hepatitis C After Liver transplantation

Hiroshi Sadamori<sup>1</sup>, Tetsuya Ogino<sup>2</sup>,  
Takahito Yagi<sup>1</sup> and Toshiyosi Fujiwara<sup>1</sup>  
<sup>1</sup>*Departments of Gastroenterological Surgery,*  
<sup>2</sup>*Departments of Pathology,*  
*Okayama University Graduate School of Medicine,*  
*Dentistry and Pharmaceutical Sciences,*  
*Japan*

## 1. Introduction

Chronic hepatitis C virus (HCV) infection is the leading reason for liver transplantation in both the USA and Europe. Also, with increasing numbers of adult recipients, HCV associated liver disease is now becoming the leading indication for liver transplantation in Japan as well. The recurrence of HCV infection in the grafted liver is inevitable and HCV re-infection precedes acute hepatitis, which is usually detected between 1 and 3 months post-transplantation. Acute HCV is characterized by a rising serum alanine transaminase level and sometimes by a moderate elevation in bilirubin levels, resulting in varying degrees of liver graft damage. Acute HCV usually evolves to chronic hepatitis, which impairs both the graft and patient survival because the progression to liver cirrhosis is faster after liver transplantation than in nontransplant patients. A biopsy of the transplanted graft is helpful in establishing a diagnosis of recurrent HCV, in aiding the decision to undertake antiviral treatment, and in assessing the treatment response. The biopsy is assessed for grade (degree of necro-inflammation) and stage (extent of fibrosis) which help predict the likelihood of disease progression.

There are still several problems with the diagnosis and treatment of recurrent HCV after liver transplantations. Especially during the first 6 months following transplantation, recurrent HCV infection frequently causes severe liver graft dysfunction. Also during this period, recurrent HCV is sometimes difficult to differentiate from other complications such as acute cellular rejection (ACR) and biliary complications because the histopathological changes of a grafted liver with recurrent HCV infection are often atypical. Thus, a definite histopathological diagnosis of recurrent HCV sometimes cannot be made solely based on the findings of hematoxylin-eosin (H&E) stained liver biopsies. The diagnosis of recurrent HCV and the decision to launch antiviral treatment is often difficult and stressful for clinicians.

The detection of HCV replicative intermediates or antigens in liver biopsies may be helpful in the diagnosis and medical management of patients with recurrent HCV. In the following section, previous reports about the immunohistochemical detection of HCV antigens in liver grafts are reviewed and our data about immunohistochemical staining using IG222 monoclonal antibody (mAb) against the HCV-envelope 2 (E2) protein are described.

## **2. Immunohistochemical analysis of liver grafts for recurrent HCV after liver transplantation**

### **2.1 Immunohistochemical detection of HCV antigens in patients with chronic HCV infection**

The identification of HCV antigens in the liver was first reported in 1990 (Krawczynski et al., 1990). Several antibodies have been induced for the detection of HCV in liver biopsies. HCV antigens were detected exclusively in the cytoplasm of hepatocytes in specimens obtained from the livers of patients with chronic HCV infection, with a detection rate of 23-100% (Roskams, 2002; Scheuer et al., 1997). According to these reports, the number of positive hepatocytes and the intensity of staining were relatively low in most of the liver specimens. Clinically, the indication and management of antiviral therapy for HCV infection is decided according to liver biochemical tests, HCV genotype, and serum HCV-RNA levels. Thus, histopathological findings from liver biopsy are not necessarily essential for managing patients with chronic HCV infection. In addition, the histopathological features of chronic HCV infection are typical and are easily assessed for the disease diagnosis and progression from H&E stained liver biopsy specimens. Therefore, immunohistochemical detection of HCV antigens doesn't necessarily seem to be valuable for the medical management of patients with chronic HCV infection.

### **2.2 Immunohistochemical detection of HCV antigens for liver transplantation**

#### **2.2.1 Problems of diagnosing and managing recurrent HCV**

In recurrent HCV infection in grafted livers, histopathological changes often exhibit from acute lobular hepatitis to chronic hepatitis in the majority of patients after transplantation. The severity of these changes, including necro-inflammatory activity and fibrosis progression, may vary depending on each case and the time after transplantation. Especially during the first 6 months following transplantation, recurrent HCV infection may cause severe liver graft dysfunction. During this period, the histopathological changes of a grafted liver with recurrent HCV infection are often atypical and difficult to differentiate from other complications, such as ACR and biliary complications. A definite histopathological diagnosis of recurrent HCV can be made when H&E stained liver biopsies show findings characteristic of recurrent HCV such as a variable degree of mononuclear portal inflammation, interface activity, lobular disarray, and spotty hepatocyte necrosis. However, in practice, the examination of H&E-stained liver biopsy is often done before a definite diagnosis of recurrent HCV hepatitis can be established. The clinical situations associated with the diagnosis and management of recurrent HCV are often stressful for clinicians.

Antiviral treatment can be initiated in the early weeks after liver transplantation, irrespective of biochemically or histologically proven recurrent HCV hepatitis. However, according to preliminary studies, the response rate is not higher than in treatment initiated after a definite diagnosis and the tolerability of treatment in these early transplant periods is limited. This pre-emptive antiviral therapy soon after liver transplantation is still under evaluation. At present, antiviral treatment after a definite diagnosis of recurrent HCV is accepted as a standard therapy. Since early recurrent HCV often causes severe liver graft dysfunction, an early definite histopathological diagnosis is essential for the early commencement of antiviral therapy. Therefore, the detection of HCV replicative intermediates or antigens in liver biopsies may be helpful for the early

diagnosis and optimal medical management of patients with recurrent HCV after liver transplantation.

### 2.2.2 Immunohistochemical detection of HCV antigens for recurrent HCV after liver transplantation

The post-transplant HCV-RNA serum levels usually reach 10-20 times the pre-transplantation levels, presumably because of immunosuppression. Although it is easy to show systemic HCV infection through serum HCV-RNA levels, it is more difficult to evaluate the actual state of HCV infection in the grafted liver. The presence of HCV-RNA in liver biopsy specimens has been shown by *in situ* hybridization (Agnello et al., 1998) or by reverse-transcriptase *in situ* polymerase chain reaction (Fragulidis et al., 1998). However, these methods have technical difficulties and have not been widely used. In contrast, the detection of HCV antigens in liver grafts is easy and sensitive enough for clinical use in the management of patients after liver transplantation. Thus, considering the above-mentioned problems of diagnosing recurrent HCV, immunohistochemical detection of HCV antigens in liver grafts could provide potentially important pathological information, making possible a correlation between viral replication in liver grafts and recurrent HCV after liver transplantation. Several studies suggested that the immunohistochemical staining of HCV antigens in liver grafts correlated with the severity of recurrent HCV after liver transplantation (Gane et al., 1996; Pessoa et al., 2008; Vargas et al., 1998; Verslype et al., 2003).

### 2.3 Immunohistochemical staining of liver grafts using IG222 mAb against HCV-Envelope 2

Several monoclonal and polyclonal antibodies against HCV antigens have been used for the immunohistochemical analysis of HCV antigens in liver biopsy specimens of hepatitis C patients. Of these antibodies, IG222 is reported to have a strong immunoreactivity to the HCV-E2 protein in both fresh-frozen tissue and paraffin-embedded tissue (Verslype et al., 2003). Verslype et al. reported that immunohistochemical staining using IG222 mAb had a sensitivity of 96%, a specificity of 91% and an overall accuracy of 94.8% in their 253 patients with chronic hepatitis C. Based on those findings, we decided to use IG222 for the immunohistochemical analysis of liver grafts. In this section, we describe our data (Sadamori et al., 2009) about the immunohistochemical staining of liver grafts using IG222 mAb in patients who underwent liver transplantation for HCV associated liver failure.

#### 2.3.1 Longitudinal immunohistochemical analysis of a case of recurrent HCV

Figure 1 summarizes the clinical course of a patient with early recurrent HCV after living donor liver transplantation (LDLT). Immunoreactivity to IG222 mAb was weakly positive on a liver biopsy specimen on postoperative day (POD) 31 showing moderate ACR (Fig. 2A and 3A). After the improvement of liver function tests by steroid pulse therapy, the liver function tests increased again around POD 55. A H&E stained liver biopsy on POD 59 showed mild portal inflammation, endothelial inflammation of portal venules, and an intra-acinar acidophilic body, leading to the diagnosis of probable recurrent HCV (Fig. 2B). At that stage, the immunoreactivity to IG222 mAb was already moderate (Fig. 3B). With further deterioration shown in liver function tests, another liver biopsy on POD 80 confirmed a definite diagnosis of recurrent HCV (Fig. 2C) accompanied by marked immunoreactivity to IG222 mAb (Fig. 3C). The findings in this case show the diagnostic usefulness of the immunohistochemical staining of liver grafts using IG222 mAb.

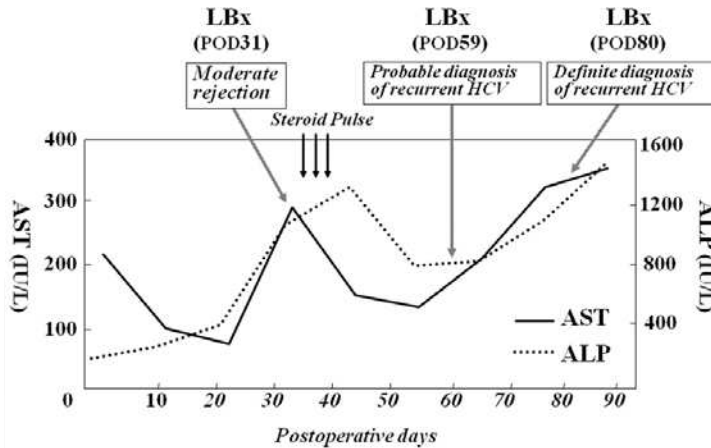


Fig. 1. Clinical course of a representative patient with post-LDLT early recurrent HCV.

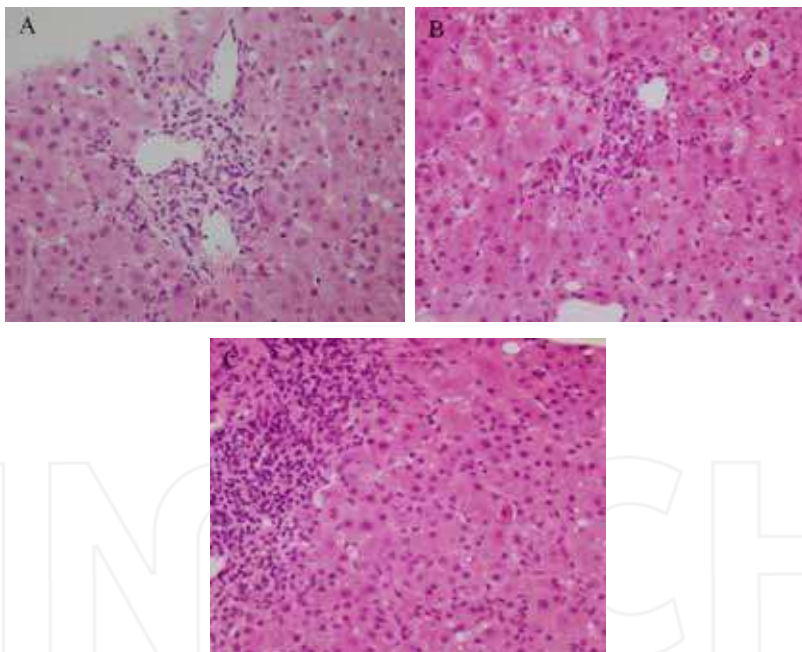


Fig. 2. Findings of H&E stained liver biopsy specimens (A) Liver biopsy specimen obtained on POD 31 showed moderate acute cellular rejection. (Original magnification  $\times 160$ ) (B) Liver biopsy specimen obtained on POD 59 showed mild portal inflammation and an intra-acinar acidophilic body, leading to the diagnosis of probable recurrent HCV. (Original magnification  $\times 160$ ) (C) Liver biopsy specimen obtained on POD 80 showed marked portal inflammation, intra-acinar inflammatory cell infiltration and intra-acinar spotty necrosis, leading to the diagnosis of definite recurrent HCV. (Original magnification  $\times 160$ )

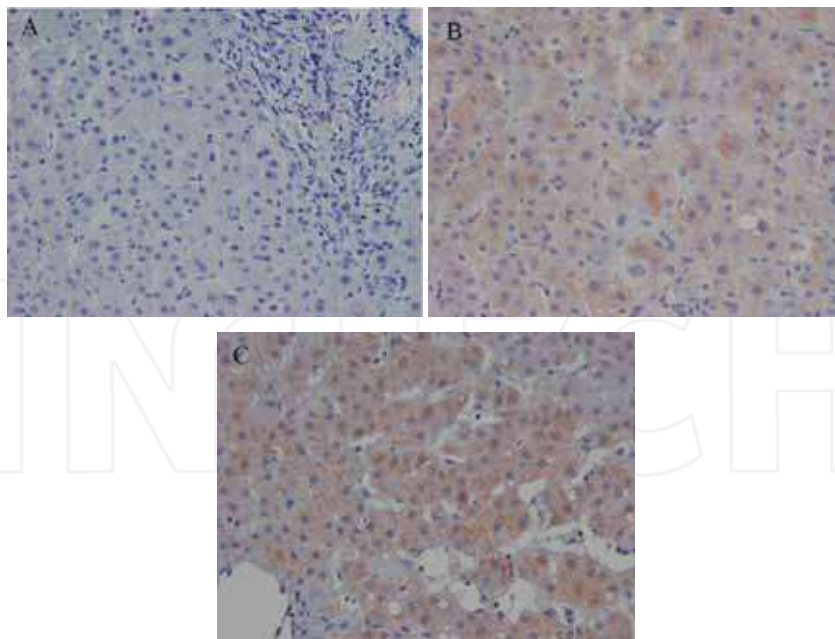


Fig. 3. Immunohistochemistry for HCV-E2 in liver biopsy specimens (A) Immunohistochemistry for HCV-E2 in a liver biopsy obtained on POD 41 based on a suspected acute rejection episode. Note the weakly positive immunoreactivity to IG222. (Original magnification x200) (B) Immunohistochemistry for HCV-E2 in liver biopsy obtained on POD 59 of a case with probable diagnosis of recurrent HCV based on the examination of H&E-stained sections. Note the moderate immunoreactivity to IG222. (Original magnification x200) (C) Immunohistochemistry for HCV-E2 in a liver biopsy obtained on POD 80, of a case with definite diagnosis of recurrent HCV based on the examination of H&E-stained sections. Note the marked immunoreactivity to IG222. (Original magnification x200).

### 2.3.2 Serial changes in immunoreactivity to IG222 mAb after LDLT

Previous study reported that HCV antigen expression in transplanted liver grafts was detected as early as 10 days post-transplantation in 25% of liver biopsy specimens and within 3 weeks in 50% of specimens (Ballardini et al., 2002). By the time histological recurrent HCV is clinically overt, HCV antigens can be detected in more than 90% of liver biopsy specimens (Ballardini et al., 2002; Gane et al., 1996; Guerrero et al., 2000). We performed immunohistochemical staining using IG222 mAb on 84 liver biopsy specimens obtained from 28 patients who underwent LDLT for HCV associated liver failure. Immunohistochemistry using IG222 mAb was performed on paraffin sections of all liver biopsies by a two-step indirect EnVision technique. To investigate serial changes of HCV antigen expression in liver grafts, the 84 liver biopsy specimens were divided into three groups according to the time elapsed from LDLT: Group POD<sub>1-30</sub> (28 specimens), Group POD<sub>31-179</sub> (34 specimens), and Group POD<sub>≥180</sub>. (22 specimens). Table 1 lists the grade of

immunoreactivity to IG222 mAb in the above-mentioned three groups classified according to the time after LDLT. Immunoreactivity to IG222 for HCV-E2 was detected in 78.6% of the liver biopsy specimens obtained during the first month after LDLT, and there were no significant differences in the grades of immunohistochemical staining between the three groups classified according to the time elapsed from LDLT. Our data shows that constant HCV antigen expression in liver grafts is observed relatively early after liver transplantation and is not associated with the time elapsed from the transplantation.

| Group                  | No. of liver specimens | No. of patients | Grade of Anti-HCV-E2 immunoreactivity | Serum HCV-RNA level (KIU/ml) |
|------------------------|------------------------|-----------------|---------------------------------------|------------------------------|
| POD <sub>1-30</sub>    | 28                     | 22              | 0+ :6<br>1+ :11<br>2+ :8<br>3+ :3     | 2124 ± 354                   |
| POD <sub>31-179</sub>  | 34                     | 24              | 0+ :4<br>1+ :19<br>2+ :9<br>3+ :2     | 3196 ± 295                   |
| POD <sub>&gt;180</sub> | 22                     | 19              | 0+ :1<br>1+ :17<br>2+ :4<br>3+ :0     | 2778 ± 381                   |

IHS: Immunohistochemical staining HCV-E2: HCV-envelope 2 POD: Postoperative days

NOTE. Comparison of IHS grades (Mann-Whitney *U* test): There were no significant comparisons among three groups.

Comparison of serum HCV-RNA levels (Mann-Whitney *U* test): There were no significant comparisons among three groups.

\*The grade of IHS from 0+ to 3+ scale (0+ : neg, 1+ : <5%, 2+ : 5-20%, 3+ : >20% positive hepatocytes).

Table 1. The grades of IHS and serum HCV-RNA levels among three groups classified according to the time after LDLT

### 2.3.3 Immunohistochemical staining with IG222 mAb for differentiating recurrent HCV from other complications

Based on our histological evaluation of H&E stained specimens, 34 liver biopsy specimens obtained from LDLT recipients were diagnosed as follows: definite recurrent HCV in 12, probable recurrent HCV in 7, definite ACR in 7 and other complications in 8. The other complications comprised of drug-induced liver injury in 1, cytomegalovirus hepatitis in 1, cholestasis due to biliary stricture in 3 and non-specific cholestasis in 3. Figure 4 shows the grade of immunohistochemical staining with IG222 mAb in the above-mentioned four different post-transplant conditions. In our study, the grade of HCV-E2 expression was significantly higher in liver grafts with definite and probable recurrent HCV compared with those with ACR and other complications (mainly biliary complications). These data suggested that strong HCV-E2 expression in liver grafts is associated with recurrent HCV after LDLT when IG222 mAb is used for the immunohistochemical staining of the liver grafts. Therefore, immunohistochemical staining of liver grafts using IG222 mAb can be an innovative approach for differentiating recurrent HCV from other complications including ACR and for aiding the decision to commence antiviral treatment.

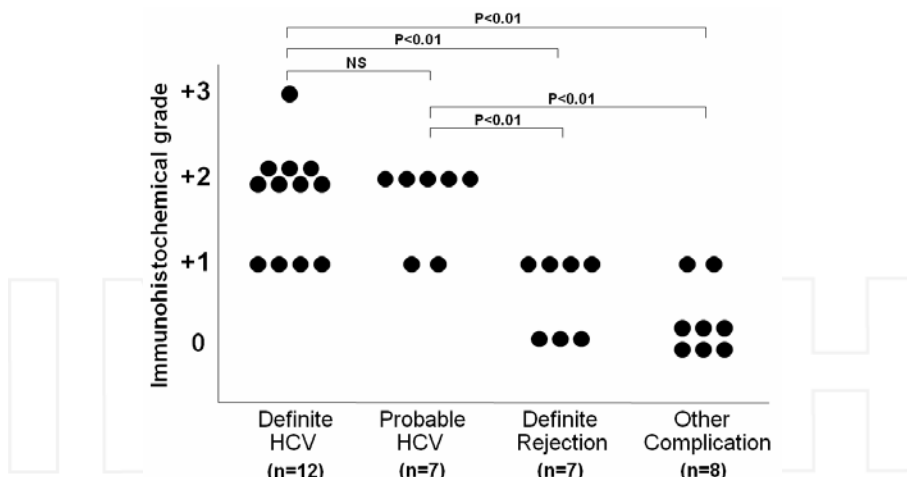


Fig. 4. IG222 immunohistochemical grading in four different post-transplant conditions.

**2.3.4 Correlation between immunohistochemical grading and serum HCV-RNA levels**

Previous reports investigated the relationship between serum HCV-RNA levels and recurrent HCV after liver transplantation. Some of these studies showed a close correlation between serum HCV-RNA levels and the presence and severity of recurrent HCV (Di Martino et al., 1997; Feray et al., 1994; Gottschlich et al., 2001). However, others groups

| Histological assessment | No. of liver specimens | Grade of Anti-HCV-E2 immunoreactivity* | Serum HCV-RNA level (KIU/ml) |
|-------------------------|------------------------|--|------------------------------|
| Definite HCV            | 12                     | 0+:0<br>1+:4<br>2+:7<br>3+:1           | 3368 ± 525                   |
| Probable HCV            | 7                      | 0+:0<br>1+:2<br>2+:5<br>3+:0           | 3671 ± 840                   |
| Definite rejection      | 7                      | 0+:3<br>1+:4<br>2+:0<br>3+:0           | 2925 ± 639                   |
| Other complications     | 8                      | 0+:5<br>1+:3<br>2+:0<br>3+:0           | 4211 ± 408                   |

IHS: Immunohistochemical staining HCV-E2: HCV-envelope 2

NOTE: Comparison of IHS grades (Mann-Whitney U test): Definite HCV v Probable HCV, P = NS, Definite HCV v Definite rejection, P = .002, Definite HCV v Other complications, P = .0001, Probable HCV v Definite rejection, P = .009, Probable HCV v Other complications, P = .002, Definite rejection v Other complications, P = NS. Comparison of serum HCV-RNA levels (Mann-Whitney U test): There were no significant comparisons among four post-transplant conditions.

\*The grade of IHS from 0+ to 3+ scale (0+: neg, 1+: <5%, 2+: 5-20%, 3+: >20% positive hepatocytes).

Table 2. The grades of IHS and serum HCV-RNA levels in four different post-transplant conditions.



found no such correlation (Chazouilleres et al., 1994; Freeman et al., 1996; Zhou et al., 1996). In our study, the serum HCV-RNA levels in the specimens with definite and probable recurrent HCV were comparable with those with definite ACR and other complications (Table 2). In addition, the expression of HCV-E2 in liver grafts did not correlate with serum HCV-RNA levels when our data of 84 liver biopsy specimens was analyzed. Previous studies indicated that HCV can replicate efficiently in extrahepatic tissues and cell types, including peripheral blood mononuclear cells, lymph nodes, and bone marrow, particularly in immunosuppressed patients (Blackard et al., 2006; Laskus et al., 1998; Radkowski et al., 1998). Extrahepatic replication of HCV may help explain the lack of correlation between serum HCV-RNA levels and HCV-E2 staining in liver grafts.

### 2.3.5 Assessment of antiviral treatment response after liver transplantation

The course of HCV recurrence after liver transplantation progresses more rapidly and more aggressively than in the immunocompetent non-transplant HCV-infected population. Chronic HCV is observed in almost 70 % of patients 3 years after transplantation (Feraÿ et al., 1994). Moreover, as the progression rate of fibrosis is faster after transplantation, the rate of cirrhosis reaches about 20% at 5 years (Berenguer et al., 2000; Gane et al., 1996). Several attempts have been made to prevent a poor prognosis due to HCV recurrence. Antiviral therapy for patients on the waiting list is attractive, but many patients do not meet the inclusion criteria and cannot receive antiviral treatment. Even if antiviral treatment is initiated despite poor hepatic reserve, many patients will withdraw due to frequent serious adverse events.

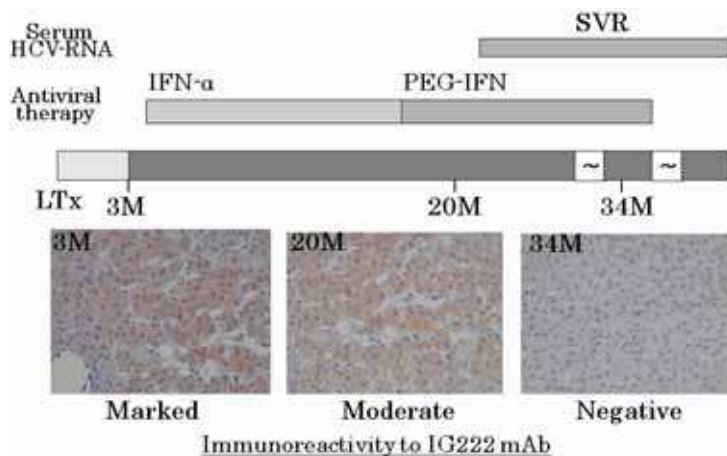


Fig. 5. Clinical course and immunohistochemical staining of liver grafts using IG222 mAb of a patient with recurrent HCV, who achieved sustained virological response (SVR) by antiviral therapy.

Antiviral therapy after transplantation can contribute to the improvement of HCV disease progression in a minority of the overall HCV liver transplant population. In studies using combination therapy with interferon (IFN)-alpha and ribavirin or, more recently, pegylated interferon-alpha (PEG-IFN) plus ribavirin, a sustained virological response (SVR) was achieved in 20-30% of patients (Carrion et al., 2007; Samuel et al., 2003). Figure 5 shows the

clinical course and immunohistochemical staining of liver grafts using IG222 mAb of a patient with recurrent HCV, who achieved SVR by antiviral therapy. The grade of HCV-E2 expression on the liver grafts decreased according to the continuation of antiviral therapy and became almost negative when SVR was achieved.

At present, there is no effective therapy for those that don't respond to antiviral therapy or patients who experience a viral relapse after antiviral therapy. For those patients, new innovative strategies to improve therapeutic efficacy and tolerability are needed for the medical management of recurrent HCV after liver transplantation. In addition, immunohistochemical staining of liver grafts with IG222 mAb, directed against HCV-E2, may be useful for the actual evaluation of new medical treatment responses especially for those that don't respond to antiviral therapy.

### 3. Conclusion

Through the immunohistochemical staining of HCV antigens using reliable antibodies we can assess the actual HCV re-infection and replication in transplanted liver grafts. According to previous studies and our data, the immunohistochemical staining of HCV antigens on liver grafts can contribute to the early and prompt diagnosis of recurrent HCV after liver transplantation. Based on our study, immunohistochemical staining of liver grafts using IG222 mAb is sensitive enough for clinical use and can be useful for differentiating recurrent HCV from other complications, including ACR, and for aiding in the decision to commence antiviral treatment. In the future, the immunohistochemical staining of HCV antigens on liver grafts should be able to contribute toward identifying patients suitable for early antiviral therapy and assessing the antiviral treatment response for recurrent HCV after liver transplantation.

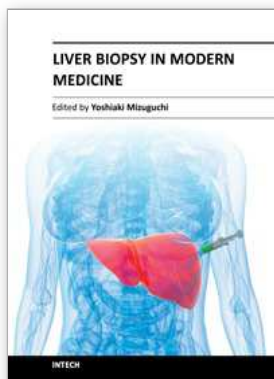
### 4. Acknowledgement

This project was supported by an unrestricted research grant from Novartis Japan Inc.

### 5. References

- Agnello V, Abel G, Knight GB, et al. (1998). Detection of widespread hepatocyte infection in chronic hepatitis C. *Hepatology*, 28, pp.573-84.
- Ballardini G, De Raffe E, Groff P, et al. (2002). Timing of reinfection and mechanisms of hepatocellular damage in transplanted hepatitis C virus-reinfected liver. *Liver Transpl*, 8, pp.10-20.
- Blackard JT, Kemmer N, Sherman KE. (2006). Extrahepatic replication of HCV: Insight into clinical manifestation and biological consequences. *Hepatology*, 44, pp.15-22.
- Berenguer M, Ferrell L, Watson J, et al. (2000). HCV-related fibrosis progression following liver transplantation: increase in recent years. *J Hepatol*, 32, pp.673-84.
- Carrion JA, Navasa M, Garcia-Retortillo M, et al. (2007). Efficacy of antiviral therapy on hepatitis C recurrence after liver transplantation: a randomized controlled study. *Gastroenterology*, 132, pp.1746-56.
- Chazouilleres O, Kim M, Combs C, et al. (1994). Quantitation of hepatitis C virus RNA in liver transplant recipients. *Gastroenterology*, 106, pp.994-9.
- Di Martino V, Saurini F, Samuel D, et al. (1997). Long-term longitudinal study of intrahepatic hepatitis C virus replication after liver transplantation. *Hepatology*, 26, pp.1343-50.

- Feray C, Gigou M, Samuel D, *et al.* (1994). The course of hepatitis C virus infection after liver transplantation. *Hepatology*, 20, pp.1137-43.
- Fragulidis GP, Citrocco RE, Wepler D, *et al.* (1998). In situ enzymatic oligonucleotide amplification of hepatitis C virus-RNA in liver biopsy specimens (reverse transcriptase in situ polymerase chain reaction) after orthotopic liver transplantation for hepatitis C-related liver disease. *Transplantation*, 66, pp.1472-6.
- Freeman RB, Tran S, Lee YM, *et al.* (1996). Serum hepatitis C RNA titers after liver transplantation are not correlated with immunosuppression or hepatitis. *Transplantation*, 61, pp.542-6.
- Gane EJ, Naoumov NV, Qian KP, *et al.* (1996). A longitudinal analysis of hepatitis C virus replication following liver transplantation. *Gastroenterology*, 110, pp. 167-77.
- Gane EJ, Portmann BC, Naoumov NV, *et al.* (1996). Long-term outcome of hepatitis C infection after liver transplantation. *N Eng JMed*, 334, pp. 815-20.
- Gottschlich MJ, Aardema KL, Burd EM, *et al.* (2001). The use of hepatitis C viral RNA levels in liver tissue to distinguish rejection from recurrent hepatitis C. *Liver Transpl*, 7, pp.436-41.
- Guerrero RB, Batts KP, Burgart LJ, *et al.* (2000). Early detection of hepatitis C allograft reinfection after orthotopic liver transplantation: a molecular and histologic study. *Mod Pathol*, 13, pp.229-37.
- Krawczynski K, Beach M, Di Bisceglie A, *et al.* (1990). Hepatocellular HCV-associated antigen and antibody: viral specificity and relation to natural history of infection. *Hepatology*, 12, pp. 905-10.
- Laskus T, Radkowski M, Wang L, *et al.* (1998). Search for hepatitis C virus extrahepatic replication sites in patients with acquired immunodeficiency syndrome: specific detection of negative-strand viral RNA in various tissues. *Hepatology*, 28, pp.1398-401.
- Pessoa MG, Alves V, Wakamatsu A, *et al.* (2008). Post-transplant recurrent hepatitis C: immunohistochemical detection of hepatitis C virus core antigen and possible pathogenic implications. *Liver Int*, 28, pp.807-13.
- Radkowski M, Wang L, Vargas H, *et al.* (1998). Detection of hepatitis C virus replication in peripheral blood mononuclear cells after orthotopic liver transplantation. *Transplantation*, 66, pp.664-6.
- Roskams T. (2002). The role of immunohistochemistry in diagnosis. *Clin Liver Dis*, 6, pp.571-89.
- Sadamori H, Yagi T, Iwagaki H, *et al.* (2009). Immunohistochemical staining of liver grafts with a monoclonal antibody against HCV-Envelope 2 for recurrent hepatitis C after living donor liver transplantation. *J Gastroenterol Hepatol*, 24, pp. 574-580.
- Samuel D, Bizollon T, Feray C, *et al.* (2003). Interferon-alpha 2b plus ribavirin in patients with chronic hepatitis C after liver transplantation: a randomized study. *Gastroenterology*, 124, pp. 642-50.
- Scheuer PJ, Krawczynski K, Dhillon AP, *et al.* (1997). Histopathology and detection of hepatitis C virus in liver. *Springer Immunopathols*, 19, pp. 27-45.
- Vargas V, Krawczynski K, Castells L, *et al.* (1998). Recurrent hepatitis C virus infection after liver transplantation: Immunohistochemical assessment of the viral antigen. *Liver Transpl*, 4, pp. 320-7.
- Verslype C, Nevens F, Sinelli N, *et al.* (2003). Hepatic immunohistochemical staining with a monoclonal antibody against HCV-E2 to evaluate antiviral therapy and reinfection of liver grafts in hepatitis C viral infection. *JHepatol*, 38, pp.208-14.
- Zhou S, Terrault NA, Ferrell L, *et al.* (1996). Severity of liver disease in liver transplantation recipients with hepatitis C virus infection: Relationship to genotype and level of viremia. *Hepatology*, 4, pp.1041-6.



## **Liver Biopsy in Modern Medicine**

Edited by Dr. Yoshiaki Mizuguchi

ISBN 978-953-307-883-0

Hard cover, 378 pages

**Publisher** InTech

**Published online** 10, October, 2011

**Published in print edition** October, 2011

Liver biopsy, first performed by Paul Ehrlich in 1883, remains an important diagnostic procedure for the management of hepatobiliary disorders and the candidate/donated organ for transplantation. The book "Liver biopsy in Modern Medicine" comprises 21 chapters covering the various aspects of the biopsy procedure in detail and provides an up-to-date insightful coverage to the recent advances in the management of the various disorders with liver biopsy. This book will keep up with cutting edge understanding of liver biopsy to many clinicians, physicians, scientists, pharmaceuticals, engineers and other experts in a wide variety of different disciplines.

### **How to reference**

In order to correctly reference this scholarly work, feel free to copy and paste the following:

Hiroshi Sadamori, Tetsuya Ogino, Takahito Yagi and Toshiyosi Fujiwara (2011). Immunohistochemical Staining of Liver Grafts for Recurrent Hepatitis C After Liver Transplantation, Liver Biopsy in Modern Medicine, Dr. Yoshiaki Mizuguchi (Ed.), ISBN: 978-953-307-883-0, InTech, Available from:

<http://www.intechopen.com/books/liver-biopsy-in-modern-medicine/immunohistochemical-staining-of-liver-grafts-for-recurrent-hepatitis-c-after-liver-transplantation>

# **INTECH**

open science | open minds

### **InTech Europe**

University Campus STeP Ri  
Slavka Krautzeka 83/A  
51000 Rijeka, Croatia  
Phone: +385 (51) 770 447  
Fax: +385 (51) 686 166  
[www.intechopen.com](http://www.intechopen.com)

### **InTech China**

Unit 405, Office Block, Hotel Equatorial Shanghai  
No.65, Yan An Road (West), Shanghai, 200040, China  
中国上海市延安西路65号上海国际贵都大饭店办公楼405单元  
Phone: +86-21-62489820  
Fax: +86-21-62489821