Radiology Case Reports

Volume 9, Issue 2, 2014

Dedifferentiated liposarcoma of the adult male breast

Sean D. Raj, MD; Samuel Rogers, BS; Gerard W. del Junco, MD; and Karla Sepulveda, MD

A 66-year-old male presented with a right breast mass, enlarging insidiously over a one-year period after trauma to the site. After the findings were attributed to glandular injury and hematoma, the patient eventually underwent mammographic and ultrasonographic evaluation that demonstrated masses in the breast and the axilla. A subsequent ultrasound- guided biopsy of the breast mass yielded a diagnosis of fibromatosis. However, the imaging features were suggestive of malignancy. Surgical resection was performed and revealed dedifferentiated liposarcoma—a neoplasm with components of well- and poorly differentiated liposarcoma as well as nonlipomatous sarcoma. This tumor type is primarily described in the retroperitoneum and limbs and is especially rare in the breast. We report an unusual case of multifocal primary dedifferentiated liposarcoma involving the breast in a man.

Case report

A 66-year-old, otherwise healthy man presented to our institution with a right breast mass (Fig. 1A) and associated right axillary fullness (Fig. 1B), steadily enlarging over a one-year period after trauma to the region after a fall. Initial examination and workup at an outside institution attributed the asymmetric, right-sided breast growth to retroareolar hematoma and glandular injury, with followup recommended. The patient arrived at our medical center several months later with continued progressive growth and axillary skin retraction without associated nipple discharge, bleeding, or associated complaints. Notably, the patient's mother was diagnosed with breast cancer in her 30s. Given the combination of significant family history of breast cancer and presentation suggestive of malignancy, the patient was immediately scheduled for mammographic evaluation.

Figure 1. 66-year-old male with dedifferentiated liposarcoma of the right breast. A. Patient's chest, demonstrating an enlarging right breast mass. B. Right axillary skin retraction and fullness increased over a prior one-year period after sustaining trauma.

Citation: Raj SD, Rogers S, del Junco GW, Sepulveda K. Dedifferentiated liposarcoma of the adult male breast. *Radiology Case Reports*. (Online) 2014;9(2);906.

Drs. Raj, Rogers, and Sepulveda are in the Department of Radiology, Baylor College of Medicine, Houston TX. Dr. del Junco is in the Department of Pathology at the Park Plaza Medical Center, Houston TX. Contact Dr. Raj at sean.raj@bcm.edu.

Competing Interests: The authors have declared that no competing interests exist.

DOI: 10.2484/rcr.v9i2.906

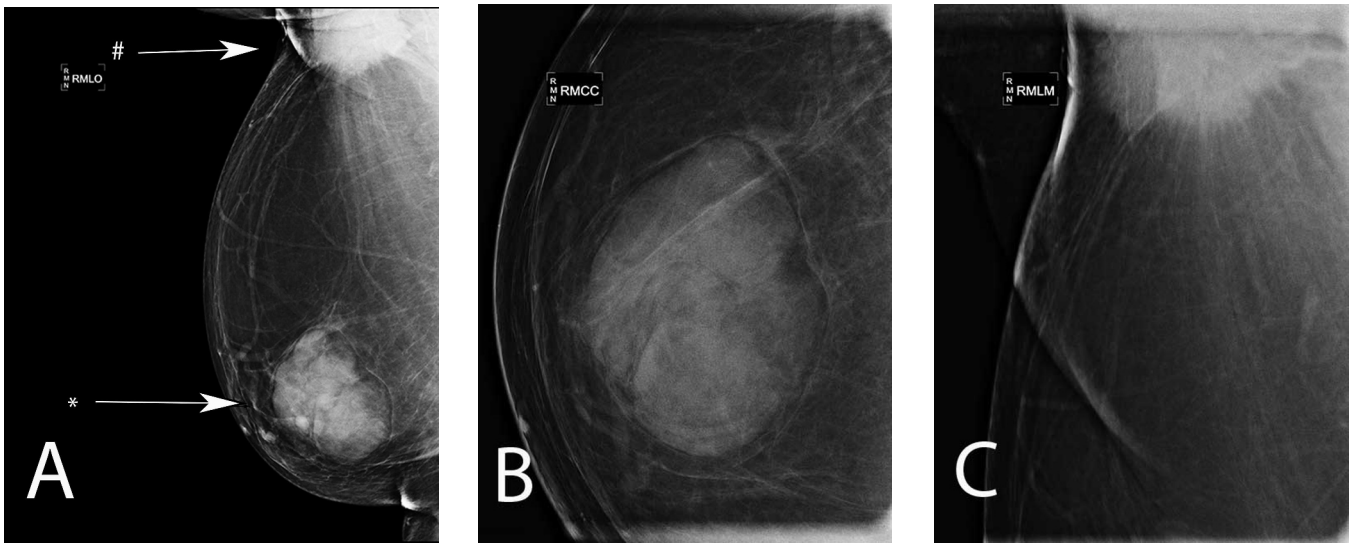

Figure 2. 66-year-old male with dedifferentiated liposarcoma of the right breast. Mammography showed a 9-cm, mixed solid and fat density, central outer right breast mass (*) with circumscribed margins and a 5-cm right axillary mass with spiculated margins (#). Both masses corresponded to palpable and mammographic findings. A. Mediolateral oblique view. B. Magnified craniocaudal view. C. Magnified lateral medial view.

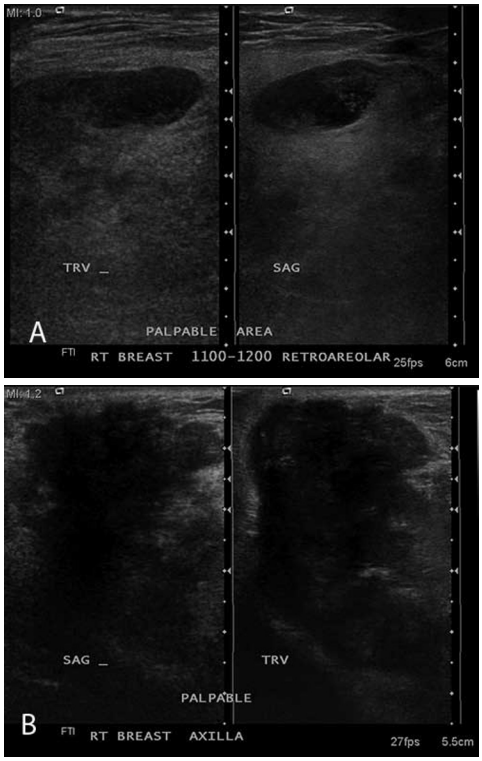

Figure 3. 66-year-old male with dedifferentiated liposarcoma of the right breast. Targeted right breast ultrasound was performed in the areas of the palpable and the mammographic abnormalities. A. Transverse and sagittal images of the right breast, 11-12 o'clock region, show a 9.2-cm isoechoic mass with a 4-cm cystic component. B. Transverse and sagittal images of the right axilla show a 3.9-cm hypoechoic mass with irregular margins, suspicious for malignancy.

Initial screening and diagnostic mammography (Fig. 2) revealed a large right breast with a 9-cm mass in the outer central aspect and a 5-cm right axillary mass.

Real-time, same-day ultrasound performed on the right breast masses (Fig. 3) revealed a 9.2-cm, well-circumscribed mass in the upper outer breast with a 4-cm internal cystic component. Right axillary ultrasound demonstrated a 3.9-cm hypoechoic mass with irregular margins. The findings in the axilla were particularly concerning for primary breast malignancy.

Ultrasound-guided, vacuum-assisted biopsies of the right breast masses and the right axillary mass were performed immediately after review of the sonographic areas of suspicion. Twelve-gauge, vacuum-assisted biopiesy of the right breast mass and the right axillary mass were performed. Initial histopathological evaluation findings were benign. Tissue from the right upper central breast mass was consistent with fat necrosis and fibrin, while the core biopsy sample from the right axillary mass was compatible with fibromatosis. Given the discordance in imaging and pathological findings, surgical consultation was recommended.

Right radical mastectomy was performed with resection of the right axillary (Fig. 4A) and central right outer (Fig. 4B) masses, with an en bloc resection of the pectoralis major muscle as well as associated lymph nodes. The two discrete masses on imaging were found to be components of a single large confluent mass that extended from the right breast to the axilla. Tissue was sampled from the masses visualized on imaging after resection. Pathology revealed a high-grade, primary dedifferentiated liposarcoma consisting of a poorly differentiated liposarcoma in the axilla and replacement of normal breast tissue with a predominantly well-differentiated liposarcoma component in the pectoralis muscle and the breast.

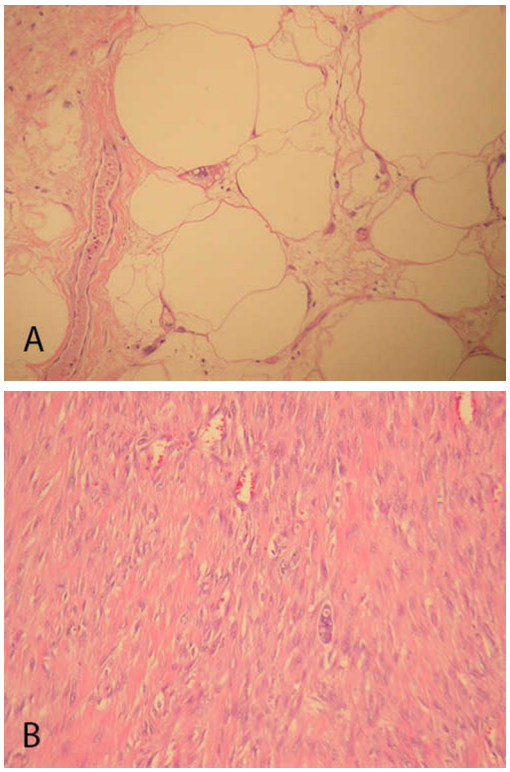

Figure 4. 66-year-old male with dedifferentiated liposarcoma of the right breast. Histology and cytogenetic analysis from these specimens were consistent with a dedifferentiated liposarcoma with a well-organized, well-differentiated component (hematoxylin and eosin, 400x). A. Poorly differentiated liposarcoma in the axilla, composed of bland, cellular, nonlipogenic spindle cells, closely resembles fibromatosis. B. Well-differentiated liposarcoma demonstrates lipoblasts, scattered enlarged atypical cells, fibrous bands, stromal sclerosis, and fat necrosis.

The final histopathologic diagnosis was dedifferentiated liposarcoma with a predominant component of well-differentiated liposarcoma in the breast and a smaller, poorly differentiated axillary mass, corresponding to the imaging findings as two masses with separate cellular constituents. The treatment plan involved four cycles of systemic therapy involving Adriamycin, Iphosphamide, and Mesna, followed by adjuvant radiation therapy.

Discussion

Liposarcomas compose 20% of all soft-tissue sarcomas and are the second most common type after pleomorphic undifferentiated sarcomas. Typically arising within the retroperitoneum and the extremities, sarcomas in the breast are rare, accounting for only about 0.06% of all breast malignancies (1, 2). While breast sarcomas are uncommon, liposarcomas of the breast are disproportionately rare; compared to the normal ratio of 20% in other soft tissues, they compose only 5% of all breast sarcomas (2, 3).

Characterization of the histologic differentiation, grade, and type of liposarcoma is critical to determining management and prognosis. Liposarcomas are currently classified into four different subclasses based on pathology: most common are well-differentiated liposarcomas (or atypical lipomatous tumor), followed by myxoid/round-cell liposarcoma, pleomorphic liposarcomas, and dedifferentiated liposarcomas (4). Dedifferentiated liposarcoma has elements of well and poorly differentiated liposarcoma as well as nonlipomatous sarcoma occurring within a single tumor entity. We present an unusual case of dedifferentiated liposarcoma with a predominant, well-differentiated component within the breast.

Breast liposarcomas have only rarely been found extending into both the stromal tissues and pectoral muscles, and have yet to be described with the dedifferentiated subtype (5-9). This patient presented with significant tumor extension into the stromal tissues and the pectoralis major muscle. Irrespective of location, liposarcomas typically present as soft, slowly growing masses that may or may not be painful, in the fifth through seventh decades (10-14). In the breast stroma, liposarcomas are usually unilateral, and may be well circumscribed or multinodular and infiltrative (10, 11). Liposarcomas in the breast may arise from pre-existing benign tumors, including lipomas, fibroadenomas, and phyllodes tumors (5,12). Previous studies have suggested that trauma can induce myxoid changes that mimic liposarcoma on pathological evaluation (10). In this patient, the diagnosis of liposarcoma was preceded by trauma, complicating imaging-pathology correlation.

The diagnosis of liposarcoma can be challenging and result in imaging-pathology discordance. In a previous report, fine-needle aspiration and ultrasound of a breast mass were both suggestive of a fibroadenoma, but pathology on resection revealed myxoid liposarcoma of the breast (12). Similarly, our patient's liposarcoma was ultimately described as a dedifferentiated variant, but a similar diagnostic pitfall occurred: initial pathology from the ultrasound-guided core biopsy of the axillary mass revealed areas of the tumor composed largely of cellular spindled fibroblastic cells, consistent with an incorrect (but mimicking) diagnosis of fibromatosis. Following mastectomy and pathologic evaluation of the excised tissue, dedifferentiated liposarcoma was identified, with elements of poorly differentiated liposarcoma in the axilla and well-differentiated liposarcoma in the right upper outer breast and underlying pectoralis muscle.

On imaging studies, liposarcoma subtypes have several common features, although there is a tremendous degree of variation similar to that found on pathological evaluation. Masses on mammography are often very dense and well circumscribed (9, 15-17). This patient's well-differentiated component in the breast had a mixed density, and the visualized extent was limited. The dedifferentiated component in the axilla had spiculated margins. Computed tomography (CT) images can show solid masses with low densities representing fat (3, 9, 18). Several findings of liposarcoma on CT have been correlated histologically; hazy amor-

phous densities usually represent spindle formation, thick streaky structures represent entrapped muscle fibers, and thinner streaks represent fibrous tissue (19).

Liposarcoma evaluation with ultrasound is highly variable, demonstrating heterogeneous or homogeneous echogenicity, depending on the pathologic subtype of liposarcoma. Due to the high degree of variability in the composition of the lesion, characterization of the mass with ultrasound has a relatively low sensitivity. Liposarcomas may be hypervascular on color Doppler imaging (9, 17). This tumor type may arise from phyllodes tumors, which can appear hypoechoic on ultrasound and disguise the lipomatous element of the liposarcoma (15). Liposarcomas may also have ultrasound features similar to fibroadenomas (12). Less frequently, liposarcomas may exhibit regions of necrosis and can incorrectly resemble an abscess (3).

MRI can be very useful in distinguishing lipomas from well-differentiated liposarcomas. Lipomas are homogeneously fatty, might have occasional muscle stranding, and have thin, uniform septa. Specifically, lipomas do not contain thickened septa or soft-tissue nodules. Well-differentiated liposarcomas are predominantly fat-attenuating masses, contain variable thickened or nodular septa, and show heterogeneous enhancement with focal areas of enhancement on T2-weighted images. A study that used these MRI features to identify liposarcoma was 100% sensitive and 83% specific. However, that study also found that a lesion that appears to be a well-differentiated liposarcoma is still more likely to be a benign lipoma variant (20). On T1-weighted images, liposarcomas are hypointense and lack normal fibrous structural elements compared to normal breast fatty tissue (15).

Large tumor size and the lack of free margins at excision are the most reliable indicators for poor prognosis of breast sarcomas (3, 21). Liposarcomas can have a high rate of local recurrence and thus are preferentially treated with wide local excision. Long-term followup is required because of the possibility of delayed dedifferentiation (20). Surgical excision is the most effective treatment, although radiotherapy and chemotherapy should be considered for some patients with positive margins (21). A review of 20 cases indicated that the axilla is not a frequent region of metastases, and axillary lymph node dissection is usually not necessary (10).

Liposarcoma of the breast is a rare entity with diverse imaging and histopathologic manifestations. Typical imaging characteristics include a well-circumscribed mass on mammography, and MRI findings may include a breast mass resembling a lipoma, but with less representative elements such as heterogeneous enhancement on the T2-weighted images and thickened or nodular septa. The ultrasound appearance is inconsistent, with the mass often appearing as a homogeneous or heterogeneous echogenic mass. Multiple biopsies and extensive pathological evaluation of the lesion may be needed to confirm the diagnosis of liposarcoma.

Liposarcoma of the breast is difficult to diagnose with imaging studies, and biopsies can be misleading. Recognizing the variability in imaging findings and associated mimicking pathology may assist radiologists and pathologists in overcoming the diagnostic challenges involved in diagnosing liposarcomas.

References

1. Dei Tos AP. Liposarcoma: new entities and evolving concepts. *Ann Diagn Pathol*. 2000; 4:252–66. [PubMed]
2. Adem C, Reynolds C, Ingle JN, Nascimento AG: Primary breast sarcoma: clinicopathologic series from the Mayo Clinic and review of the literature. *Br J Cancer*. 2004; 91:237-41. [PubMed]
3. Nandipati KC, Nerkar H, Satterfield J, Velagapudi M, Ruder U, Sung KJ. Pleomorphic liposarcoma of the breast mimicking breast abscess in a 19-year-old postpartum female: a case report and review of the literature. *Breast J*. 2010, Sep-Oct; 16(5):537-40. [PubMed]
4. Nikolaidis P, Silverman SG, Cibas ES, et al. Liposarcoma subtypes: identification with computed tomography and ultrasound-guided percutaneous needle biopsy. *Eur Radiology*. 2005; 15(2):383-9. [PubMed]
5. Jeong JY, Park HJ, Lee JH, Shin JS, Jo WM, Lee IS. Liposarcoma of the chest wall: a case potentially transformed from a recurrent lipoma. *Gen Thorac Cardiovasc Surg*. 2011 Apr; 59(4):310-1. [PubMed]
6. Urabe M, Mizobuchi N, Funabiki H, Seki E, Okada T, Sakakibara N. A case of liposarcoma originating in the chest wall. *Nihon Geka Hokan*. 1995 Nov 1; 64(6):131-8. [PubMed]
7. Wong SP, Ng CS, Wan S, Lee TW, Wan IY, Yim AP, Arifi AA. Giant metastatic myxoid liposarcoma causing cardiac tamponade: a case report. *Jpn J Clin Oncol*. 2002 Nov; 32(11):480-2. [PubMed]
8. Gonçalves L, Athanasiou A, Malhaire C. Pleomorphic liposarcoma of the pectoralis major muscle presenting as a breast lump. *Euro Rad* [serial online]. 2011; case 8794. Available at http://www.eurorad.org/case.php?id=8794. Accessed May 15, 2013.
9. Sezer A, Tuncbilek N, Usta U, Cosar-Alas R, Cicin I. Pleomorphic liposarcoma of the pectoralis major muscle in an elderly man: Report of a case and review of literature. *J Can Res Ther*. 2009; 5:315-7. [PubMed]
10. Austin RM, Dupree WB. Liposarcoma of the breast: A clinicopathologic study of 20 cases. *Hum Pathol*. 1986; 17(9):906–13. [PubMed]
11. Hummer CD, Burkart TJ. Liposarcoma of the breast: A case of bilateral involvement. *Am J Surg*. 1967; 113(4):558–61. [PubMed]
12. Pant I, Kaur G, Joshi SC, Khalid IA. Myxoid liposarcoma of the breast in a 25-year-old female as a diagnostic pitfall in fine needle aspiration cytology: report of a rare case. *Diagn Cytopathol*. 2008 Sep; 36(9):674-7. [PubMed]
13. Titius BR, Gohring UJ, Scharl A. Bilateral breast carcinoma after recurrent myxoid liposarcoma of the breast. *Pathologe*. 1995; 16:230–34. [PubMed]

14. Carpanelli JB, Lempel G, Gatta C. Report of a case of liposarcoma of the mammary gland. *Sem Med*. 1963; 123:321–2. [PubMed]
15. Diekmann F, Rudolph B, Winzer KJ, Bick U. Liposarcoma of the breast arising within a phyllodes tumor. *J Comput Assist Tomogr.* 1999 Sep-Oct; 23(5):764-6. [PubMed]
16. Charfi L, Driss M, Mrad K, et al. Primary well differentiated liposarcoma: an unusual tumor in the breast. *Breast J.* 2009; 15:206–7. [PubMed]
17. Whitsell T, Marcovis K, Ruhs S, Andres M, Beck S. High-grade pleomorphic liposarcoma of the breast. *Grand Rounds Journal*. 2011; 11:87-91. DOI:10.1102/1470-5206.2011.0022
18. Shoji T, Sonobe M, Okubo K, Wada H, Bando T, Date H. Giant primary liposarcoma of the chest. *Gen Thorac Cardiovasc Surg*. 2009 Mar; 57(3):159-61. [PubMed]
19. Nishida J, Morita T, Ogose A, et al. Imaging characteristics of deep-seated lipomatous tumors: intramuscular lipoma, intermuscular lipoma, and lipoma-like liposarcoma. *J Orthop Sci*. 2007; 12(6):533-41. [PubMed]
20. Gaskin CM, Helms CA. Lipomas, lipoma variants, and well-differentiated liposarcomas (atypical lipomas): results of MRI evaluations of 126 consecutive fatty masses. *AJR Am J Roentgenol.* 2004; 182(3):733-9. [PubMed]
21. Barrow BJ, Janjan NA, Gutman H, et al. Role of radiotherapy in sarcoma of the breast – a retrospective review of the MD Anderson experience. *Radiother Oncol.* 1999; 52:173–8. [PubMed]