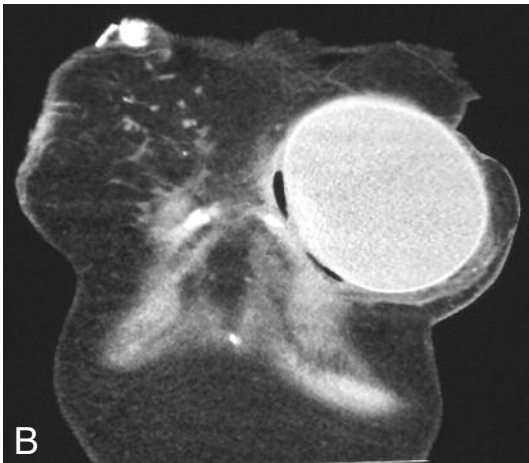
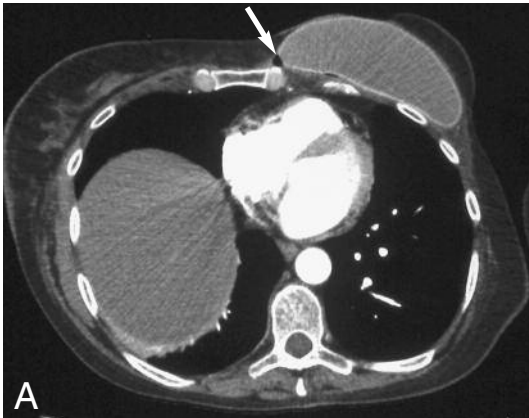


## IMAGES IN CLINICAL RADIOLOGY



### *An unusual cause of pleuritic chest pain on a CT pulmonary angiogram*

J. O'Brien, S. Barrett, W. Torreggiani<sup>1</sup>

A 41-year-old lady with a history of breast carcinoma, was admitted for investigation of pleuritic chest pain.

On examination, there were no focal abnormalities.

Her white-cell count was mildly elevated at  $12 \times 10^9$  cells/l and her biochemical profile was within normal limits.

Her chest x-ray was unremarkable.

A computed-tomography pulmonary-angiogram (CTPA) was subsequently performed which revealed no evidence of a pulmonary embolus or parenchymal abnormality.

On the anterior aspect of the examination within the soft tissues, there were pockets of air visualised, adjacent to the left prosthesis, and when the windows were adjusted, there was a defect of the overlying tissue (Fig. A, B).

A soft tissue infection in this area was suggested to the referring team, which was confirmed on examination.

This case illustrates an unusual cause of pleuritic chest pain diagnosed on CTPA and the importance of examining extra-thoracic structures on each CT examination.

---

1. Department of Radiology, Adelaide and Meath Incorporating the National Children's Hospital, Tallaght, Dublin, Ireland.