

Recombinant Soluble P-Selectin Glycoprotein Ligand-1-Ig Reduces Restenosis Through Inhibition of Platelet-Neutrophil Adhesion After Double Angioplasty in Swine

Jean-Guy Bienvenu, DVM; Jean-François Tanguay, MD; Jean-François Théorêt, MSc; Anjali Kumar, PhD; Robert G. Schaub, PhD; Yahye Merhi, PhD

Background—P-selectin mediates leukocyte recruitment to activated platelets and endothelium through its high-affinity receptor P-selectin glycoprotein ligand-1 (PSGL-1). Platelet and leukocyte activation and binding have been reported after coronary angioplasty and were correlated with restenosis. We investigated the effect of a recombinant soluble PSGL-1 (rPSGL-Ig) on the adhesion of platelets and neutrophils and the development of restenosis after double arterial injury.

Methods and Results—Four weeks after angioplasty of both carotid arteries in pigs, a second angioplasty was performed at the same sites, 15 minutes after a single administration of vehicle or rPSGL-1 (1 mg/kg IV). Animals were euthanized 1 hour, 4 hours, 1 week, or 4 weeks later. Adhesion of autologous ^{51}Cr -platelets and ^{111}In -neutrophils was quantified and histological/morphometric analyses were performed. Although rPSGL-Ig did not affect adherence of these cells 1 hour after injury, it significantly reduced the adhesion of platelets (50% at 4 hours and 85% at 1 week) and neutrophils (50% at 4 hours and 78% at 1 week) to deeply injured arteries. At 4 weeks, the residual lumen was 63% larger in rPSGL-Ig-treated arteries as compared with control arteries (6.1 ± 0.6 versus 3.8 ± 0.1 mm²; $P < 0.002$). The neointimal area was slightly reduced (0.5 in rPSGL-Ig versus 0.7 mm² in control). The ratio of the external elastic lamina of injured to uninjured reference segments was >1 in treated arteries and <1 in control arteries.

Conclusions—P-selectin antagonism with rPSGL-Ig inhibits early platelet/leukocyte adhesion on injured arteries and reduces restenosis through a positive impact on vascular remodeling. Hence, rPSGL-Ig may have potential in the prevention of restenosis. (*Circulation*. 2001;103:1128-1134.)

Key Words: restenosis ■ remodeling ■ glycoproteins ■ platelets ■ leukocytes

Restenosis after successful coronary angioplasty constitutes a significant limitation to the long-term success of this procedure. Shortly after injury to the vessel wall, elastic recoil, thrombotic and inflammatory responses, and secretion of cytokines and growth factors contribute to thrombus organization. These early reactions are followed, in turn, by neointimal hyperplasia derived from medial cell proliferation and migration toward the intima with formation of extracellular matrix and eventual reduction in vascular lumen or restenosis.^{1,2} This process also involves chronic and adaptive changes in vascular structure resulting in changes to arterial size or remodeling. These include alterations in hemodynamic conditions and locally mediated vasoactive and growth factors with production/degradation of extracellular matrix.³⁻⁶

The acute response to arterial injury induced by angioplasty involves the adhesion of platelets and leukocytes,

which react with the damaged arterial wall in proportion to the degree of injury.⁷⁻⁹ Activated platelets promote mural thrombus formation, vasoconstriction, and restenosis.^{7,10} Neutrophils are also activated after PTCA¹¹⁻¹³ and contribute to the upregulation of platelet reactivity.¹⁴ These reactions of platelets and neutrophils are also accompanied by monocyte/macrophage accumulation that amplify the inflammatory reactions leading to the progression of restenosis.¹⁵ Interactions between platelets and leukocytes are facilitated by platelet P-selectin and its high-affinity counterreceptor on leukocytes, P-selectin glycoprotein ligand-1 (PSGL-1 or CD162).¹⁶

P-selectin-mediated platelet-leukocyte interactions¹⁷⁻¹⁹ allow tethering of leukocytes by activated platelets, thus facilitating metabolic cooperation and mutual activation.¹⁹⁻²² Increased platelet-leukocyte activation and interactions have been reported in unstable angina, after myocardial ischemia,

Received July 31, 2000; revision received September 5, 2000; accepted September 8, 2000.

From the Research Center, Montreal Heart Institute (J.-G.B., J.-F. Tanguay, J.-F. Théorêt, Y.M.), Montreal, Quebec, Canada; and Wyeth/Genetics Institute (A.K., R.G.S.), Andover, Mass.

Correspondence to Yahye Merhi, Laboratory of Experimental Pathology, Montreal Heart Institute, 5000 Belanger St E, Montreal, Quebec, Canada, H1T 1C8. E-mail merhi@icm.umontreal.ca

© 2001 American Heart Association, Inc.

Circulation is available at <http://www.circulationaha.org>

and in coronary angioplasty.^{11–13,23,24} Indeed, inhibition of platelet/leukocyte binding with anti-P-selectin antibodies or a recombinant soluble form of PSGL-1 has been beneficial in animal models of deep-vein thrombosis,²⁵ myocardial ischemia-reperfusion,^{26,27} intimal hyperplasia after angioplasty,²⁸ and arterial thrombosis.^{29,30}

In this study, we sought to demonstrate that administration of rPSGL-Ig would inhibit platelet-leukocyte interactions at the sites of injury and reduce restenosis in a porcine model involving double arterial angioplasty.

Methods

Animal Preparation

Fourteen cross-bred Yorkshire swine (mean weight, 17.3±0.3 kg) were prepared according to the Canadian Council on Animal Care regulations. As described previously,^{8,9,31} the animals were sedated with an intramuscular injection of ketamine (Rogarsetic, 15 mg/kg) and azaperone (Stresnil, 3 mg/kg). They were then intubated, mechanically ventilated with medical air and O₂, and anesthetized with 0.5% to 1% halothane. Intravenous heparin (100 U/kg) was given before the angioplasty procedure.

Double Arterial Injury by Angioplasty and Experimental Groups

Carotid injury was performed with a 7F polyethylene balloon dilation catheter (8 mm×3 cm), as previously described.³¹ The balloon was positioned under fluoroscopic control into the left and right common carotid arteries. Five 30-second inflations were performed at a pressure of 6 atm, with resting intervals of 60 seconds between each inflation. Angiograms were obtained immediately before and during dilation.

The animals were allowed to recover for 4 weeks, during which time neointimal lesions developed at injury sites. They were then subjected to a second angioplasty procedure at the previously injured sites. Approximately 15 minutes before the second angioplasty, a single intravenous bolus of vehicle (formulation buffer) or rPSGL-Ig³⁰ (Wyeth/Genetics Institute), which has a half-life of 10 days in pigs, was administered at a dose of 1 mg/kg. The dose of rPSGL-Ig was chosen on the basis of our experience with this molecule in other animal studies and in cell-based *in vitro* assays. In a concentration-dependent manner, rPSGL-Ig inhibited the adhesion of thrombin-activated porcine platelets to neutrophils in a flow cytometry–based assay. The IC₅₀ was found to be 25 µg/mL. Animals were euthanized 1 hour, 4 hours, 1 week, or 4 weeks after the second injury. Before and within 10 minutes of treatment administration, heart rate, blood pressure, hematological parameters, activated clotting time (ACT), and platelet aggregation were determined in each animal, as described previously.³¹

Isolation and Labeling of Neutrophils and Platelets

Autologous blood was used for the isolation and radiolabeling of neutrophils and platelets with ¹¹¹indium-oxine (¹¹¹In) and ⁵¹chromium (⁵¹Cr), respectively, as detailed elsewhere.^{8,9,31} Briefly, a low-speed centrifuge yielded platelet-rich plasma, from which platelets were isolated and incubated with 300 µCi of ⁵¹Cr for 30 minutes. Next, the suspension was centrifuged to remove unbound ⁵¹Cr, resuspended in platelet-poor plasma, and reinjected into the animal.

Neutrophils were isolated from a leukocyte-rich suspension, obtained after red blood cell sedimentation with 4% dextran. Leukocytes were layered on Ficoll-Paque gradient and centrifuged to obtain a neutrophil-rich fraction. Next, contaminated red blood cells were lysed, and neutrophils were incubated with 250 µCi of ¹¹¹In for 15 minutes. Finally, the suspension was centrifuged to remove unbound ¹¹¹In, resuspended in platelet-poor plasma, and reinjected into the animal.

Quantification of Neutrophil and Platelet Adhesion

At the end of the experiments, the carotid arteries were fixed *in situ* under physiological pressure with 1 L of saline followed by 2 L of a buffered formalin (10%) solution. The fixed arteries were then removed and cleaned of surrounding tissue. The dilated injured areas and the reference uninjured areas were each divided into 4 segments. After length and internal area surface measurements, these segments and the reference blood samples were placed in a gamma counter equipped with a multinuclide analysis program for ¹¹¹In and ⁵¹Cr radioactivity determination. The amount of neutrophils and platelets per square centimeter adhering to arterial segments was calculated from the radioactivity of the segment and from the cellular count and radioactivity of a reference blood sample, corrected for the luminal surface of each arterial segment, as described previously.^{31,32} The results are presented as platelet and neutrophil adhesion values from injured segments minus the adhesion on uninjured distal reference segments.

Histopathology

Representative transverse sections from each arterial segment were stained with hematoxylin-phloxin-safran and Movat's pentachrome, thereby allowing for identification of both the internal elastic lamina (IEL) and the demarcation between the neointima and the media, as reported previously.³³ All specimens were evaluated microscopically for the presence of mild or deep arterial wall injury, the latter being characterized by a breached IEL and a lacerated media. Results from deeply injured arterial segments are reported.

Morphometry

Sections from the injured arterial segments and the distal (reference) segments were analyzed by computer-assisted histomorphometry and NIH Image 1.60 imaging software. The lengths of the external elastic lamina (EEL) and IEL were calculated. The areas within these laminae and the area of the residual lumen were also measured. Neointimal area was obtained by subtracting the residual lumen area from the area within the IEL.³⁴ Vascular stenosis was calculated as [(reference lumen–dilated lumen)/reference lumen]×100³. Restenotic segments were defined as those with vascular stenosis >50%. To minimize animal-to-animal variations, normalized data were obtained by dividing the measurement of the dilated injured segments by the corresponding distal, uninjured reference segment values.

Immunohistochemistry

In the 4-week group, we showed the presence of endothelial cells on the neointima of the arterial segments by using peroxidase-labeled Dolichos biflorus agglutinin (DBA) lectin.³⁵ In addition, we assessed the expression of P-selectin by the neointima in paraffin-embedded sections by immunostaining with an affinity-purified polyclonal rabbit antibody to P-selectin from Pharmingen. Using flow cytometry, we have shown that this antibody reacts with porcine P-selectin expressed on isolated activated platelets. The percentage of positive platelets expressing P-selectin increases from 5% at baseline to 45% on thrombin-activated porcine platelets.

Statistical Analysis

Results are reported as mean±SEM. Intragroup and intergroup differences were compared by means of paired and unpaired Student's *t* tests, respectively, and followed, when applicable, by 1-way ANOVA with Bonferroni comparisons. A value of *P*<0.05 was considered statistically significant.

Results

Animal Characteristics

Both control and rPSGL-Ig–treated animals had similar initial body weight (17.6±1.9 and 16.9±0.4 kg, respectively). Their hematological and hemodynamic parameters were within the normal range both before and after the injection of either rPSGL-Ig or the vehicle.

TABLE 1. Characteristics of Arteries in Control and rPSGL-Ig-Treated Animals at 1 Hour, 4 Hours, 1 Week, or 4 Weeks After Second Angioplasty

	1 h		4 h		1 wk		4 wk	
	Vehicle	rPSGL-Ig	Vehicle	rPSGL-Ig	Vehicle	rPSGL-Ig	Vehicle	rPSGL-Ig
Animals, n	8	4	6	5	4	3	5	5
Redilated arteries, n (total)	12 (16)	8 (8)	12 (12)	10 (10)	7 (8)	6 (6)	9 (10)	10 (10)
Occluded arteries at time of death, n	0	0	1	0	1	0	1	0
Balloon-artery ratio	1.3±0.07	1.3±0.06	1.4±0.06	1.3±0.04	1.1±0.04	1.1±0.03	1.3±0.04	1.3±0.04
Deeply injured segments, n (%)	18 (39)	15 (47)	25 (57)	20 (50)	15 (65)	12 (50)	21 (66)	28 (70)
Fracture/IEL length, %	18.1±2.4	23.5±2.4	29.7±1.0	26.2±1.7	18.9±2.2	19.4±2.5	45.3±3.5	42.6±4.2

Values are mean±SEM.

As shown in Table 1, which summarizes the characteristics of the dilated arteries in each group, 1 artery was occluded in each of the control groups at 4 hours, 1 week, and 4 weeks. No such occlusion was noted in the arteries of treated animals. For each time point, the number of deeply injured segments, the length of injured area, and the percentage of fracture/IEL length were similar in control and treated animals.

Effect of rPSGL-Ig on Platelet and Neutrophil Adhesion

The adhesion of platelets and neutrophils to uninjured distal arterial segments (reference, nondilated) was low and similar for the control and rPSGL-Ig-treated animals (platelets×10⁶/cm²: 0.54±0.15 versus 0.51±0.17, neutrophils×10³/cm²: 19.5±3.2 versus 14.1±2.8, respectively).

As shown in Figures 1A and 2A, 1 hour after the second angioplasty, rPSGL-Ig treatment did not significantly influ-

ence platelet and neutrophil adhesion to the injured arteries. Four hours after angioplasty, the adhesion of both platelets (Figure 1A) and neutrophils (Figure 2A) had increased significantly in the control group but was significantly reduced by ≈50% in the rPSGL-Ig-treated animals. A significant 85% and 78% inhibition of platelet (Figure 1B) and neutrophil (Figure 2B) adhesion was maintained at 1 week after angioplasty in the rPSGL-Ig-treated animals. At 4 weeks after injury, the adhesion of platelets and neutrophils was reduced (but not significantly) in rPSGL-Ig-treated animals as compared with control.

Morphometric Analyses and Restenosis

Reference distally uninjured arterial segments of control and rPSGL-Ig-treated animals in the 4-week groups showed similar morphometric values for areas within the EEL (7.1 versus 7.2 mm²) and IEL (5.1 versus 5.1 mm²) and the lengths

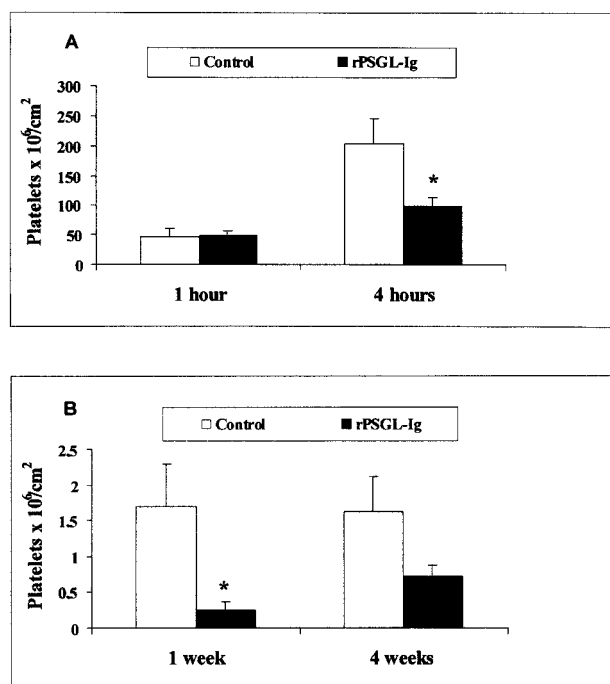


Figure 1. Platelet adhesion to deeply injured arterial segments in control and rPSGL-Ig-treated animals at 1 and 4 hours (A) and at 1 and 4 weeks (B). Values are mean±SEM. **P*<0.05 vs control.

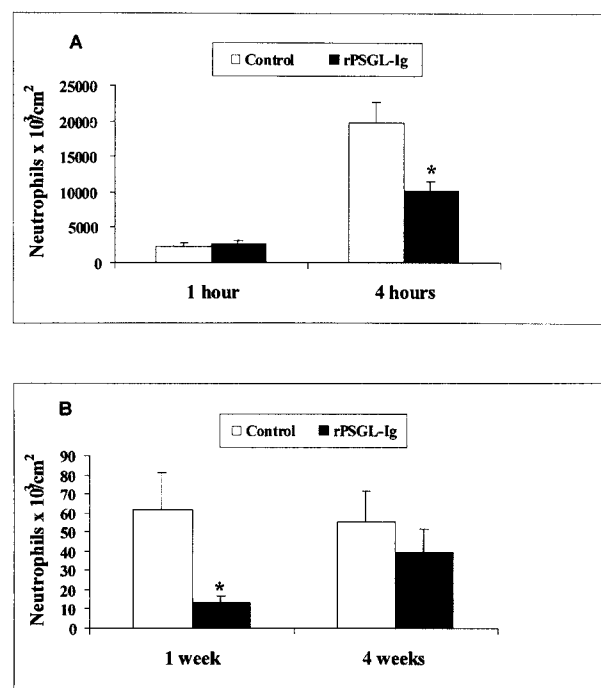


Figure 2. Neutrophil adhesion to deeply injured arterial segments in control and rPSGL-Ig-treated animals at 1 and 4 hours (A) and at 1 and 4 weeks (B). Values are mean±SEM. **P*<0.05 vs control.

TABLE 2. Histomorphological Data in Deeply Injured Segments 4 Weeks After Second Angioplasty in Control and rPSGL-Ig-Treated Animals

	Vehicle	rPSGL-Ig	P
No. of examined injured segments	21	28	
EEL area, mm ²	6.93±0.60	10.55±0.85	<0.002
Normalized	0.96±0.05	1.51±0.10	<0.001
EEL length, mm	9.38±0.40	11.57±0.44	<0.001
Normalized	0.98±0.03	1.18±0.03	<0.001
IEL area, mm ²	4.54±0.06	6.60±0.60	<0.005
Normalized	0.86±0.08	1.34±0.09	<0.001
IEL length, mm	7.49±0.05	9.18±0.04	<0.001
Normalized	0.91±0.04	1.10±0.03	<0.001
Vascular lumen, mm ²	3.84±0.06	6.08±0.58	<0.002
Normalized	0.71±0.09	1.22±0.08	<0.001
Medial area, mm ²	2.39±0.08	3.95±0.32	<0.01
% Vascular stenosis	29.2±9.5	-21.6±8.5	<0.001
Neointimal area, mm ²	0.70±0.09	0.52±0.09	NS

Values are mean±SEM.

of the EEL (9.6 versus 9.3 mm) and IEL (8.2 versus 8.4 mm). Because the uninjured segments had no neointima, these were considered reference values. Similarly, the area within the IEL in each group was considered the reference vascular lumen.

As shown in Table 2, the vascular lumen was significantly larger (by 63%) in rPSGL-Ig-treated arteries (6.08 ± 0.58 mm²) as compared with control arteries (3.84 ± 0.06 mm²), whereas the neointima in treated arteries (0.52 ± 0.09 mm²) was only 26% smaller than that in control arteries (0.7 ± 0.09 mm²). In addition, the vascular lumen was reduced by 29% in control arteries, whereas in treated arteries it was increased by 22%. Moreover, the lengths of the EEL and IEL and the areas within them were also increased in rPSGL-Ig-treated arteries when compared with control arteries.

As shown in Figure 3A, in both control and rPSGL-Ig-treated animals, a negative significant correlation was obtained between vascular stenosis and the area within EEL. In addition, although 43% of the control arterial segments were restenotic (vascular stenosis >50%), none of the treated arterial segments were restenotic. Figure 3 also indicates that 52% of the arterial segments in the control group showed inadequate compensatory enlargement (normalized sub-EEL area <1), whereas 90% of the arterial segments in the treated group showed adequate compensatory enlargement (normalized sub-EEL area >1).

When vascular stenosis is plotted against neointimal area (Figure 3B), a positive significant correlation was obtained in the control group but not in the rPSGL-Ig-treated group. These results and those of Figure 3A suggest that in the control arteries, both neointimal tissue formation and constrictive remodeling were responsible for the vascular stenosis observed 4 weeks after double angioplasty. On the other hand, it appears that rPSGL-Ig treatment permitted positive remodeling of the arterial wall. Furthermore, this positive remodeling probably occurs between 1 and 4 weeks after

injury, as suggested by the results shown in Figure 4. Although the normalized values of area within the EEL and residual lumen were similar between control and treated arteries at 1 week, they had increased significantly at 4 weeks in the rPSGL-Ig-treated arteries.

Pathological Analysis and Immunostaining

Neointima in both control and treated arteries was characterized by various amounts of spindle-shaped cells and organized mural thrombus in the extracellular matrix. As shown in Figure 5, the rPSGL-Ig-treated arteries demonstrated a dramatically increased overall vessel size and vascular lumen when compared with the control arteries. In addition, immunostaining for the DBA lectin indicated that complete neointimal reendothelialization was achieved 4 weeks after injury in both control and treated arteries. This newly formed endothelium expressed P-selectin at almost the same level in control and treated arteries. Endothelium of naive carotid arteries, however, did not express P-selectin or showed few isolated positive cells (data not shown).

Discussion

In this study, we investigated the effects of rPSGL-Ig on platelet and neutrophil adhesion in a porcine model involving double injury by angioplasty to the carotid arteries. We also assessed the effect of such treatment on the development of restenosis. In this model, a single administration of rPSGL-Ig before the second angioplasty significantly reduced the adhesion of platelets and neutrophils during the first 4 hours after injury. This effect was maintained at 1 week after injury (Figures 1 and 2). As compared with the adhesion at 1 hour, a sharp increase in the number of platelets (Figure 1A) and neutrophils (Figure 2A) adhering to and within the damaged sites of control arteries was noted at 4 hours after injury. This finding is in agreement with previous studies reporting concurrent accretion of platelets and neutrophils within the first hours after angioplasty.³⁶ The reactions of platelets are mostly integrin-dependent, involving the binding of platelet glycoprotein Ia/IIa to collagen and glycoprotein IIb/IIIa to fibrinogen, which results in shape change, release of granule contents, and aggregation, leading to thrombus growth at the sites of arterial injury. The adhesion of neutrophils, however, is predominantly mediated by their binding to P-selectin expressed on adherent activated platelets.^{9,18,20–22,37} This adhesive interaction between platelets and neutrophils promotes mutual activation and secretion of vasoactive substances, which, in turn, amplifies the inflammatory and thrombotic responses. Indeed, it has been shown that platelet and neutrophil activation and binding occur after angioplasty and are predictors of subsequent restenosis.^{12,38} The blockade of selectins has been found to be beneficial in reducing platelet-neutrophil interactions and vascular stenosis in experimental models of angioplasty.^{28,31}

In this study, treatment with rPSGL-Ig, a recombinant soluble form of PSGL-1 (the high-affinity ligand for P-selectin),¹⁶ 15 minutes before the second angioplasty significantly reduced the adhesion of neutrophils and platelets to deeply injured arterial surfaces out to 1 week after angioplasty (Figures 2B and 3B). This result is consistent with

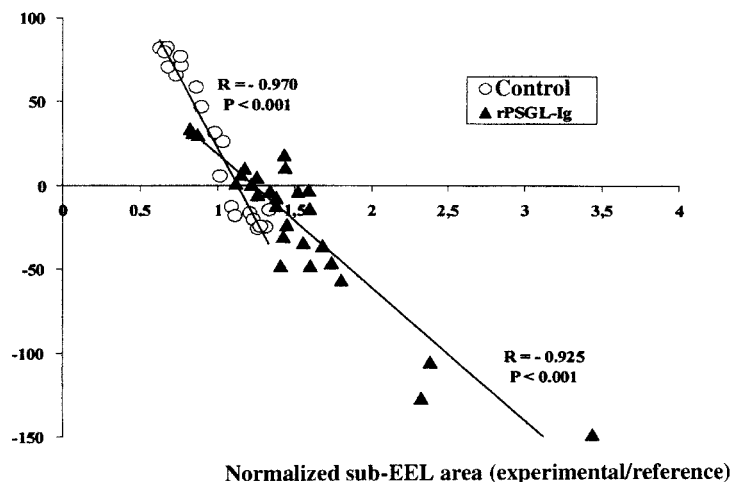
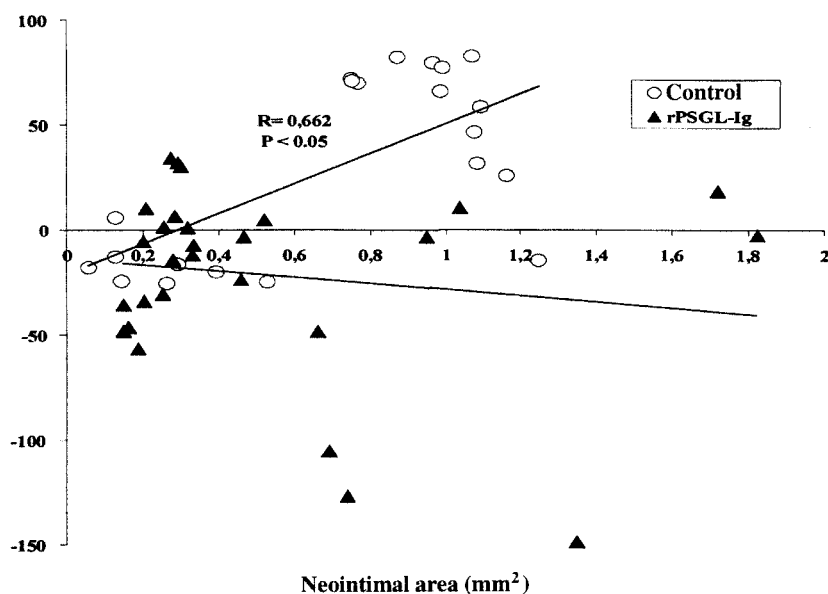
A Vascular stenosis (%)**B** Vascular stenosis (%)

Figure 3. Correlation between vascular stenosis and (A) normalized sub-EEL area values and (B) neointimal area 4 weeks after second angioplasty.

rPSGL-Ig having a long half-life of ≈ 10 days in swine and with its ability to inhibit porcine platelet-neutrophil binding in a concentration-dependent manner.³⁰

At 4 weeks after angioplasty, the level of platelet and neutrophil adhesion to injured arteries was similar to the levels observed 1 week after injury. By this time, these injured arteries were completely reendothelialized in both control and rPSGL-Ig groups. Previous reports have indicated that reendothelialization after angioplasty in pig carotid arteries, as evaluated by immunohistochemistry with DBA lectin,³⁵ can be achieved 21 days after injury.³⁹ In our study, treatment with rPSGL-Ig still reduced (but not significantly) the adhesion of platelets and neutrophils to the neointima 4 weeks after injury as compared with control. P-selectin expression was observed on the newly formed endothelium in both control and rPSGL-Ig-treated arteries (Figure 5), which suggests an ongoing proinflammatory state that continues to

contribute to neutrophil and platelet adhesion. Four weeks after a single administration of rPSGL-Ig, its plasma concentration (around $2 \mu\text{g/mL}$) may have been too low to efficiently block these reactions.

The inhibitory effect of rPSGL-Ig on platelet and neutrophil accumulation at the site of injury until 1 week after injury, when reendothelialization of the injured arteries is in progress and incomplete, probably was caused by its interference with neutrophil PSGL-1 binding to platelet P-selectin. In addition, P-selectin antagonism with rPSGL-Ig in conjunction with tissue-type plasminogen activator has been shown to accelerate thrombolysis in a porcine model.³⁰ The activity of other leukocytes, such as monocytes, which bear PSGL-1, also may be affected by rPSGL-Ig. Neutrophil and monocyte/macrophage infiltration of the damaged arterial wall release free radicals, cytokines, metalloproteinases, and growth factors, which

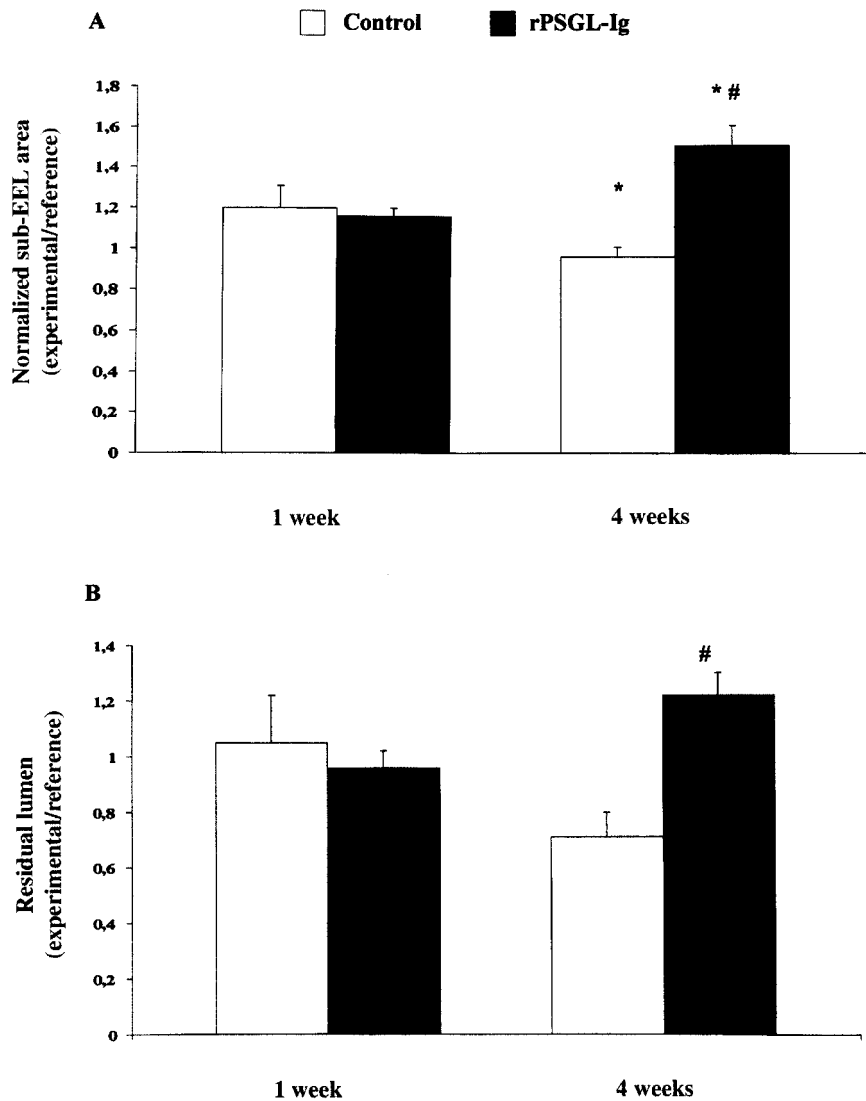


Figure 4. Normalized sub-EEL area values (A) and residual lumen values (B) 1 week and 4 weeks after second angioplasty. Values are mean \pm SEM. # $P < 0.001$ vs control, * $P < 0.05$ vs 1 week.

induce smooth muscle cell migration and proliferation, leading to the amplification of restenosis.¹⁵

The early inhibition with rPSGL-Ig of platelet and neutrophil adhesion at the site of injury was associated with a subsequent 63% increase in vascular lumen in treated arteries as compared with untreated arteries 4 weeks after injury

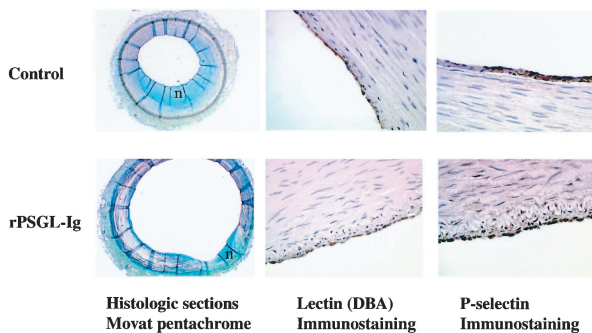


Figure 5. Representative histological sections ($\times 25$) and immunostaining ($\times 500$) of endothelial lectin and P-selectin 4 weeks after second angioplasty in control and rPSGL-Ig-treated arteries. n indicates neointima.

(Table 2). In fact, although $\approx 43\%$ of control arterial segments were restenotic ($>50\%$ stenosis), no rPSGL-Ig-treated arteries showed restenosis (Figure 3A). Reduced restenosis in rPSGL-Ig-treated arteries was mainly related to positive remodeling (normalized sub-EEL area >1 , mean = 1.5 ± 0.1), resulting in an adequate compensatory enlargement of the arterial wall. Furthermore, our results (Figure 4) revealed that the remodeling process occurred at least 1 week after angioplasty injury. These results are in agreement with studies in experimental models^{4,5,40} and in humans,^{41,42} which have suggested that remodeling may be more important than neointimal growth in the arterial response to angioplasty.⁶ Further studies are needed to assess more precisely the mechanism through which rPSGL-Ig favors positive remodeling.

Conclusions

This study highlights the importance of platelet P-selectin binding to neutrophil PSGL-1 in platelet-neutrophil interactions at the sites of arterial injury produced by double angioplasty in swine. It indicates, too, that selectin antagonism with rPSGL-Ig reduced the thrombotic and inflamma-

tory reactions and inhibited restenosis by favoring positive remodeling of the arterial wall, which may represent a unique mechanism of action. Our findings at the cellular and pathophysiological levels add new insights to the significance of platelet binding to neutrophils in thrombogenesis and restenosis. They also provide a rationale for exploring the efficacy of P-selectin antagonism with rPSGL-Ig in the clinical management of restenosis.

Acknowledgments

This work was supported by the Medical Research Council of Canada and the Heart and Stroke Foundation of Canada. We wish to thank Dr Martin Sirois for immunostaining and Nathalie Jacob and Dominique Lauzier for excellent technical assistance.

References

- Gottsauer-Wolf M, Moliterno DJ, Lincoff AM, et al. Restenosis: an open file. *Clin Cardiol*. 1996;19:347–356.
- Fuster V, Falk E, Fallon JT, et al. The three processes leading to post PTCA restenosis: dependence on the lesion substrate. *Thromb Haemost*. 1995;74:552–559.
- Lafont A, Guzman LA, Whitlow PL, et al. Restenosis after experimental angioplasty: intimal, medial, and adventitial changes associated with constrictive remodeling. *Circ Res*. 1995;76:996–1002.
- Post MJ, Borst C, Kuntz RE. The relative importance of arterial remodeling compared with intimal hyperplasia in lumen renarrowing after balloon angioplasty: a study in the normal rabbit and the hypercholesterolemic Yucatan micropig. *Circulation*. 1994;89:2816–2821.
- Andersen HR, Maeng M, Thorwest M, et al. Remodeling rather than neointimal formation explains luminal narrowing after deep vessel wall injury: insights from a porcine coronary (re)stenosis model. *Circulation*. 1996;93:1716–1724.
- Schwartz RS, Topol EJ, Serruys PW, et al. Artery size, neointima, and remodeling: time for some standards. *J Am Coll Cardiol*. 1998;32:2087–2094.
- Steele PM, Chesebro JH, Stanson AW, et al. Balloon angioplasty: natural history of the pathophysiological response to injury in a pig model. *Circ Res*. 1985;57:105–112.
- Merhi Y, L-Lacoste L, Lam JYT. Neutrophil implications in platelet deposition and vasoconstriction after deep arterial injury by angioplasty in pigs. *Circulation*. 1994;90:997–1002.
- Merhi Y, Provost P, Guidoin R, et al. Importance of platelets in neutrophil adhesion and vasoconstriction after deep carotid arterial injury by angioplasty in pigs. *Arterioscler Thromb Vasc Biol*. 1997;17:1185–1191.
- Le Breton H, Plow EF, Topol EJ. Role of platelets in restenosis after percutaneous coronary revascularization. *J Am Coll Cardiol*. 1996;28:1643–1651.
- De Servi S, Mazzone A, Ricevuti G, et al. Granulocyte activation after coronary angioplasty in humans. *Circulation*. 1990;82:140–146.
- Mickelson JK, Lakkis NM, Villarreal-Levy G, et al. Leukocyte activation with platelet adhesion after coronary angioplasty: a mechanism for recurrent disease? *J Am Coll Cardiol*. 1996;28:345–353.
- Serrano CV, Ramirez JAF, Venturinelli M, et al. Coronary angioplasty results in leukocyte and platelet activation with adhesion molecule expression: evidence of inflammatory responses in coronary angioplasty. *J Am Coll Cardiol*. 1997;29:1276–1283.
- Nash GB. Adhesion between neutrophils and platelets: a modulator of thrombotic and inflammatory events? *Thromb Res*. 1994;74(suppl 1):S3–S11.
- Libby P, Schwartz P, Brogi E, et al. A cascade model for restenosis, a special case of atherosclerosis progression. *Circulation*. 1992;86(suppl III):III-47–III-52.
- McEver RP, Cummings RD. Role of PSGL-1 binding to selectins in leukocyte recruitment. *J Clin Invest*. 1997;100(suppl 11):S97–S103.
- Hamburger SA, McEver RP. GMP-140 mediates adhesion of stimulated platelets to neutrophils. *Blood*. 1990;75:550–554.
- Kuijper PHM, Gallardo Torres HI, van der Linden JAM, et al. Platelet-dependent primary hemostasis promotes selectin- and integrin-mediated neutrophil adhesion to damaged endothelium under flow conditions. *Blood*. 1996;87:3271–3281.
- de Gaetano G, Cerletti C, Evangelista V. Recent advances in platelet-polymorphonuclear leukocyte interaction. *Haemostasis*. 1999;29:41–49.
- Palabrica T, Lobb R, Furie BC, et al. Leukocyte accumulation promoting fibrin deposition is mediated in vivo by P-selectin on adherent platelets. *Nature*. 1992;359:848–851.
- Buttrum SM, Hatton R, Nash GB. Selectin-mediated rolling of neutrophils on immobilized platelets. *Blood*. 1993;82:1165–1174.
- Ostrovsky L, King AJ, Bond S, et al. A juxtacrine mechanism for neutrophil adhesion on platelets involves platelet-activating factor and a selectin-dependent activation process. *Blood*. 1998;91:3028–3036.
- Neumann F-J, Ott I, Gawaz M, et al. Neutrophil and platelet activation at balloon-injured coronary artery plaque in patients undergoing angioplasty. *J Am Coll Cardiol*. 1996;27:819–824.
- Ott I, Neumann F-J, Gawaz M, et al. Increased neutrophil-platelet adhesion in patients with unstable angina. *Circulation*. 1996;94:1239–1246.
- Wakefield TW, Strieter RM, Schaub R, et al. Venous thrombosis prophylaxis by inflammatory inhibition without anticoagulation therapy. *J Vasc Surg*. 2000;31:309–324.
- Lefer AM, Campbell B, Scalia R, et al. Synergism between platelets and neutrophils in provoking cardiac dysfunction after ischemia and reperfusion: role of selectins. *Circulation*. 1998;98:1322–1328.
- Hayward R, Campbell B, Shin YK, et al. Recombinant soluble P-selectin glycoprotein ligand-1 protects against myocardial ischemic reperfusion injury in cats. *Cardiovasc Res*. 1999;41:65–76.
- Barron MK, Scott Lake R, Buda AJ, et al. Intimal hyperplasia after balloon injury is attenuated by blocking selectins. *Circulation*. 1997;96:3587–3592.
- Toombs CF, Degraaf GL, Martin JP, et al. Pretreatment with a blocking monoclonal antibody to P-selectin accelerates pharmacological thrombolysis in a primate model of arterial thrombosis. *J Pharmacol Exp Ther*. 1995;275:941–949.
- Kumar A, Villani MP, Patel UK, et al. Recombinant soluble form of PSGL-1 accelerates thrombolysis and prevents reocclusion in a porcine model. *Circulation*. 1999;99:1363–1369.
- Merhi Y, Provost P, Chauvet P, et al. Selectin blockade reduces neutrophil interaction with platelets at the site of deep arterial injury by angioplasty in pigs. *Arterioscler Thromb Vasc Biol*. 1999;19:372–377.
- Merhi Y, Lam JYT, Lacoste LL, et al. Effects of thrombocytopenia and shear rate on neutrophil and platelet deposition on endothelial and medial arterial surfaces. *Arterioscler Thromb*. 1993;13:951–957.
- Provost P, Tremblay J, Merhi Y. The antiadhesive and antithrombotic effects of the nitric oxide donor SIN-1 are combined with a decreased vasoconstriction in a porcine model of balloon angioplasty. *Arterioscler Thromb Vasc Biol*. 1997;17:1806–1812.
- Kumar A, Hoover JL, Simmons CA, et al. Remodeling and neointimal formation in the carotid artery of normal and P-selectin-deficient mice. *Circulation*. 1997;96:4333–4342.
- Roussel F, Dalion J. Lectins as markers of endothelial cells: comparative study between human and animal cells. *Lab Anim*. 1988;22:135–140.
- Pärsson H, Cwikiel W, Johansson K, et al. Deposition of platelets and neutrophils in porcine iliac arteries after angioplasty and Wallstent placement compared with angioplasty alone. *Cardiovasc Intervent Radiol*. 1994;17:190–196.
- Yeo EL, Sheppard J-AI, Feuerstein IA. Role of P-selectin and leukocyte activation in polymorphonuclear cell adhesion to surface adherent activated platelets under physiologic shear conditions (an injury vessel wall model). *Blood*. 1994;83:2498–2507.
- Inoue T, Sakai Y, Fujito T, et al. Clinical significance of neutrophil adhesion molecules expression after coronary angioplasty on the development of restenosis. *Thromb Haemost*. 1998;79:54–58.
- Giddings JC, Banning AP, Ralis H, et al. Redistribution of von Willebrand factor in porcine carotid arteries after balloon angioplasty. *Arterioscler Thromb Vasc Biol*. 1997;17:1872–1878.
- Lafont A, Durand E, Samuel JL, et al. Endothelial dysfunction and collagen accumulation: two independent factors for restenosis and constrictive remodeling after experimental angioplasty. *Circulation*. 1999;100:1109–1115.
- Sangiorgi G, Taylor AJ, Farb A, et al. Histopathology of percutaneous transluminal coronary angioplasty remodeling in human coronary arteries. *Am Heart J*. 1999;138:681–687.
- Mintz GS, Popma JJ, Pichard AD, et al. Arterial remodeling after coronary angioplasty: a serial intravascular ultrasound study. *Circulation*. 1996;94:35–43.

Recombinant Soluble P-Selectin Glycoprotein Ligand-1-Ig Reduces Restenosis Through Inhibition of Platelet-Neutrophil Adhesion After Double Angioplasty in Swine

Jean-Guy Bienvenu, Jean-François Tanguay, Jean-François Théorêt, Anjali Kumar, Robert G. Schaub and Yahye Merhi

Circulation. 2001;103:1128-1134

doi: 10.1161/01.CIR.103.8.1128

Circulation is published by the American Heart Association, 7272 Greenville Avenue, Dallas, TX 75231

Copyright © 2001 American Heart Association, Inc. All rights reserved.

Print ISSN: 0009-7322. Online ISSN: 1524-4539

The online version of this article, along with updated information and services, is located on the World Wide Web at:

<http://circ.ahajournals.org/content/103/8/1128>

Permissions: Requests for permissions to reproduce figures, tables, or portions of articles originally published in *Circulation* can be obtained via RightsLink, a service of the Copyright Clearance Center, not the Editorial Office. Once the online version of the published article for which permission is being requested is located, click Request Permissions in the middle column of the Web page under Services. Further information about this process is available in the [Permissions and Rights Question and Answer](#) document.

Reprints: Information about reprints can be found online at:
<http://www.lww.com/reprints>

Subscriptions: Information about subscribing to *Circulation* is online at:
<http://circ.ahajournals.org/subscriptions/>