

The Appearance of Foramen in the Internal Aspect of the Mental Region of Mandible from Japanese Cadavers and Dry Skulls Under Macroscopic Observation and Three-dimensional CT Images

By

Shunji YOSHIDA¹, Taisuke KAWAI², Koichiro OKUTSU², Takashi YOSUE²,
Hitoshi TAKAMORI³, Masataka SUNOHARA and Iwao SATO¹

¹Department of Anatomy, ²Department of Oral and Maxillofacial Radiology School of Dentistry at Tokyo,
³Oral Implant Clinic, Nippon Dental University at Tokyo, Tokyo, Japan

– Received for Publication, June 28, 2005 –

Key Words: Lingual foramen, CT, Mandible

Summary: The lingual canal with foramen displays different appearances on the internal surfaces of mandible as confirmed by macroscopic observation and computerized tomography (CT). The lingual canal was observed in the inside of mental region run to the outside of lingual foramen, which is extend internally from mandibular canal in right and left sides of the mandible in cadavers (13 sides out of 88 sides) and in dry skulls (43 out of 94 sides) examined. The spinal foramen connected with mental canal occurred at the midline of mandible in 6 cases (6 out of 47 cases) in dry skulls. In this small foramen, the inferior alveolar artery give some branches to the inside of mental region at the anterior mandible and which may be run pass through the lingual canal to the lingual foramen, where they emerge to enter the mylohyoid or anterior belly of digastric muscles. The observations of these are important considerations for surgical placement of dental implants in the region in the mandible.

The anatomical location, course and arrangement of branches of the incisive artery and nerve should be given more attention for dental implantology. A supplementary branch of the mylohyoid nerve entered the mandible through accessory foramina in the lingual side of the mandibular symphysis in 50% of the cases⁷). This was also confirmed by studies using dry skulls¹¹) and CT imaging⁵). Numerous reported have described accessory mandibular foramens^{1,8,11,12}). However, there are considerable confusions for variability in distribution, incidence, size, and contents of the accessory lingual foramina. Appearance of lingual foramen and course of lingual canal between cadaver and dry skull has not been identified by dental CT and anatomical observation. Although CT observation has been made on various incisive branches at the anterior mandible, more detailed information is needed on the lingual foramen which contain lingual branch connected with artery and nerve, they use to traverse the mandible for purposes of dental

treatments. In this study we identified the appearance of lingual and spinal foramen and course of lingual canal at the mental region of human mandible using CT from cadavers and dry skulls. This study focused on the anatomic peculiarities of the anterior mandible and implant related with clinical implications.

Materials and Methods

A total of 91 mandibles were used from adult Japanese cadavers (44 cases: 24 males; 20 females from The Donation for Human Dissection) and adult Japanese dry skulls (47 cases: 36 males; 11 females from a collection at Nippon Dental University) for this study. Three-dimensional images of the mandible were obtained from reconstruction of CT images using a CT apparatus (Toshiba Medical Co. Ltd, Tokyo, Japan, 120 kV; 50 mA; slice, 1 mm; table speed, 0.75 sec/mm). CT examination

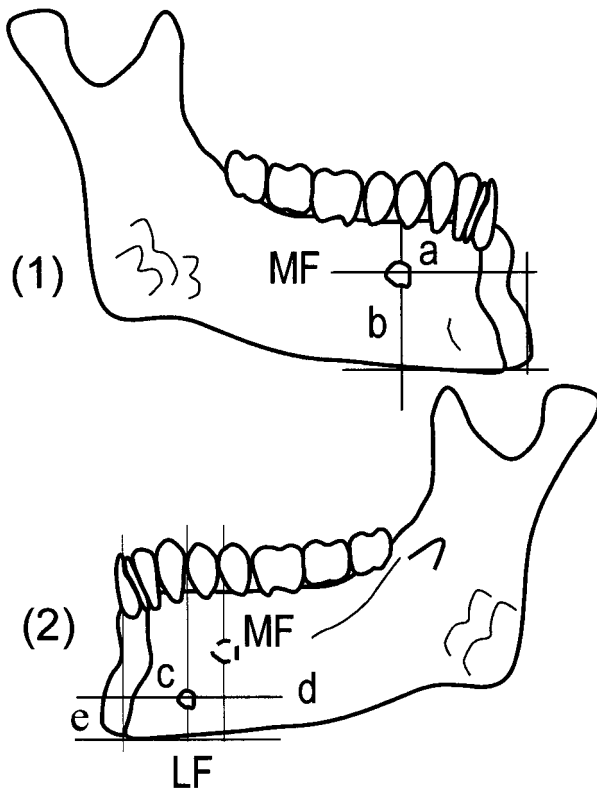


Fig. 1. Schema of mandible in measurement points.

(1) The mental foramen in the lateral surface of the right mandible. (2) Internal surface of mandible in the mental region of the mandible. a, the midline of the mandible to the centre of the mental foramen (MF); b, the center of the MF to the inferior border of the mandible; c, the midline of the mandible to the centre of the lingual foramen (LF); d, LF to the MF; e, the center of the LF to the inferior border of the mandible.

was performed at the same geometrical condition and radiological setting as routinely examinations of the jawbone quality and quantity for cadavers. Measurements of mandible from specimens was shown Figure 1. We identified above 0.4 mm diameter in the minimum permissible size of lingual and spinal foramens.

Results

A significant lingual foramen occurred in 45.7% (43 out of 94 sides) of dry skull in 14.8% (13 out of 88 sides) of cadavers at the internal aspect of the mental region of the mandible (Table 1). The mental spinal foramen (identified by McDonnell *et al.* reports⁸⁾) connected with mental canal occurred at the midline of mandible in 5 cases in male (frequency of occurrence 13.9%, 5 out of 36 sides of

Table 1. Frequency of occurrence of lingual foramen in human mandible

	Cadaver				Dry skull			
	Male		Female		Male		Female	
	N	n (%)	N	n (%)	N	n (%)	N	n (%)
R	24	3 (12.5)	20	3 (15.0)	36	17 (47.2)	11	4 (36.3)
L	24	4 (17.0)	20	3 (15.0)	36	15 (41.7)	11	7 (63.6)
R + L	48	7 (14.6)	40	6 (15.0)	72	32 (44.4)	22	11 (50.0)
Total	N = 88		13 (14.8)		N = 94		43 (45.7)	

mandibles) and 1 case in female (frequency of occurrence 9.1% 1 out of 11 sides of mandibles) of dry skulls (Figs. 2, 3, Tabel 1). The distance from the midline of the mandible to the center of the mental foramen (MF), distance from the center of the MF to the inferior border of the mandible, distance from the midline of the mandible to the center of the lingual foramen (LF) on the internal surface of mandibular body, distance from the LF to the mental foramen, and distance from the center of the LF to the inferior border of the mandible are shown in Table 2.

In the three-dimensional CT images of mandible, the lingual canal was clearly shown by three-dimensionally reconstructed CT images (Fig. 4a). Most lingual canals from specimens descended to lingual side of mandible from reconstruction of continuous slices of CT images (Fig. 4b).

Discussion

CT is an important tool for visualizing accurate structure, location, and osseous pathology associated with dental implantology¹³⁾. Jacobs *et al.* (2002)⁵⁾ confirmed the appearance of anatomical structures such as the incisive canal (93%), LF (82%), and mental canal formed the loop with the neurovascular bundle at mental region of mandible (7%) in their examination of edentulous mandibles of 152 females (mean age 55 years) using CT. In our study, LF was found in 45.7% of the dry skulls and in 14.8% of cadavers, and they indicate that LF has a low frequency of occurrence on the internal surfaces of mandibles. The low frequency of occurrence of LF from cadavers in our study may be suggested attention to keep the geometrical condition and radiological setting as examinations of the jawbone in quality and quantity under CT images. Tepper *et al.* (2001)¹²⁾ found the LF (52.9%) in the upper parts of mental spine com-

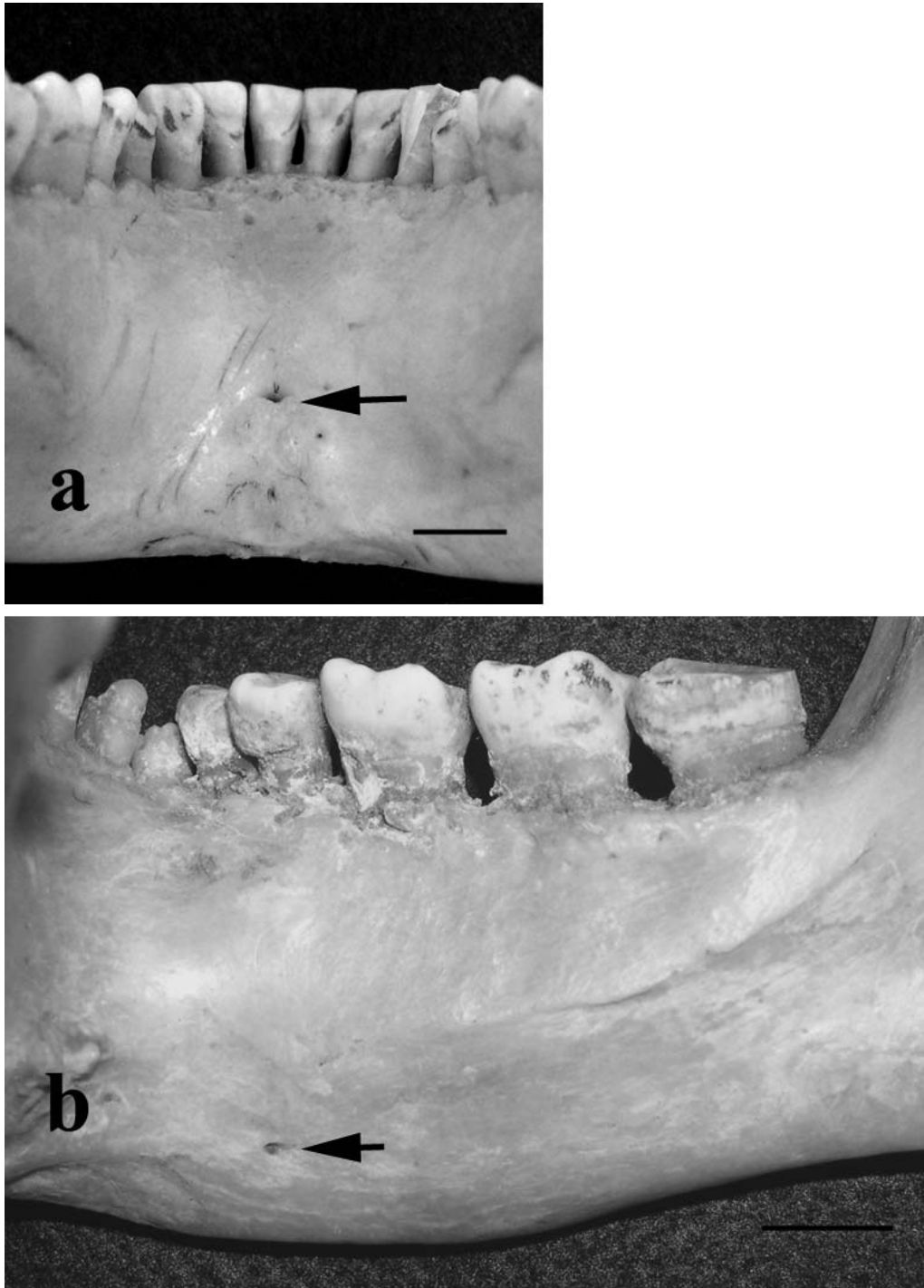


Fig. 2. Mandibular foramen in mandible from dry skull.

(a) Mental spinal foramen (arrow) was measured at the center of internal aspect of the mental region of the mandible. (b) The appearance of lingual foramen (arrow) was found in the internal aspect of the mental region of the right mandible.

posed of single foramen (44.3%) in right or left side of mandible and occurrence of single foramen each side (8.6%) of the upper parts of mental spine of the mandible. This mental spinal foramen may

be equal to the LF as McDonnell *et al.* reports (1994)⁸. McDonnell *et al.* (1994)⁸ reported that LF in the midline of the mandible occurred in 99.04% (311 out of 314 specimens) of cases and suggested

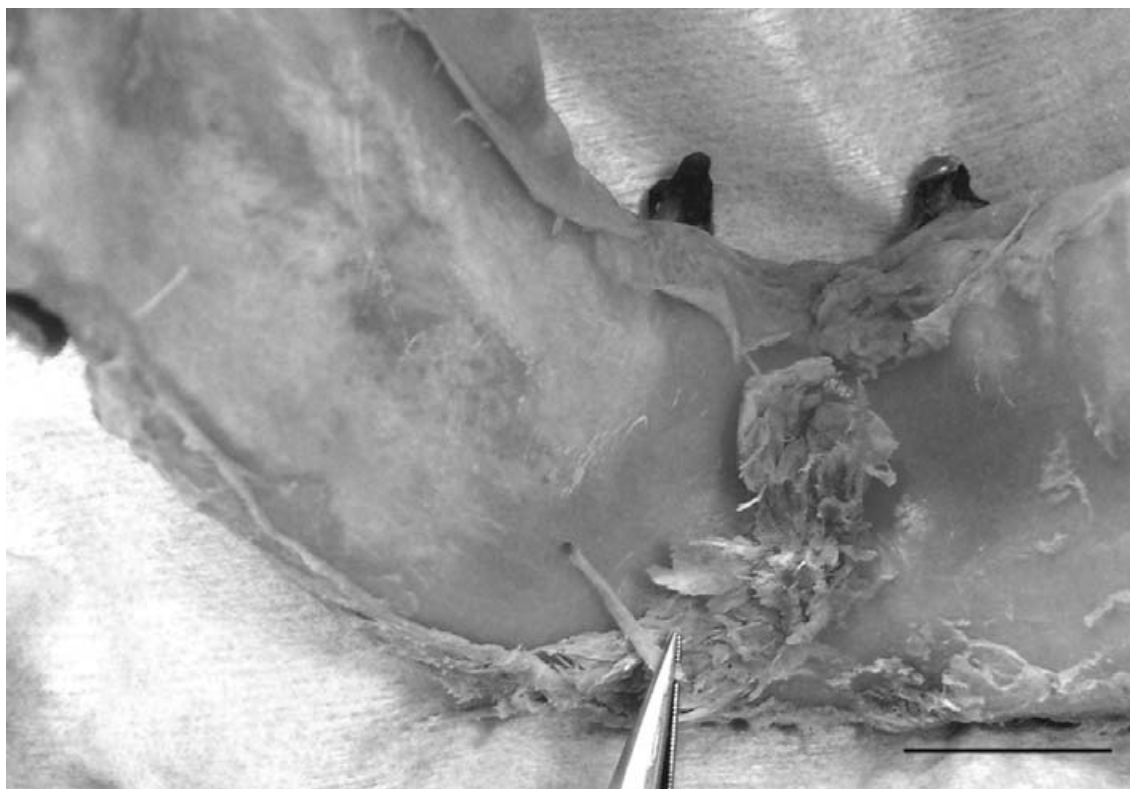


Fig. 3. The branch of inferior alveolar artery (see apex of tweezers) was found on the internal aspect of the mental region in left mandible from one cadaver (78 years old male). Bar = 1 cm

Table 2. Dimension of the distance of lingual and mental foramen

	Cadaver				Dry skull			
	Male		Female		Male		Female	
	R	L	R	L	R	L	R	L
a	26.7 ± 2.4	28.6 ± 0.9	24.3 ± 1.6	26.0 ± 1.0	28.8 ± 1.3	27.7 ± 1.9	27.1 ± 1.5	26.5 ± 2.4
b	18.2 ± 1.4	18.3 ± 0.9	13.2 ± 3.5	14.1 ± 1.5	15.5 ± 1.4	14.9 ± 1.4	13.8 ± 2.1	13.5 ± 1.1
c	12.9 ± 4.5	16.5 ± 6.1	16.5 ± 1.0	14.5 ± 1.7	15.4 ± 6.7	14.1 ± 5.0	19.8 ± 9.3	13.1 ± 4.3
d	8.8 ± 1.9	8.8 ± 5.3	6.2 ± 0.2	7.4 ± 4.7	6.5 ± 4.3	6.8 ± 4.0	9.0 ± 6.0	8.4 ± 3.0
e	9.7 ± 1.9	7.9 ± 2.5	7.1 ± 1.4	7.4 ± 1.0	7.4 ± 1.7	7.2 ± 1.0	5.6 ± 1.5	6.0 ± 1.4

Measurement points (see Fig. 1); cadaver (N = 12: male 6, female 6); dry skull (N = 28: male 21; female 7).

that the radio-opacity peripheral to the foramen, as seen on a radiograph, was produced by the entire canal after anatomical dissection, and not the genial tubercles as previously reported. In our observation, mental spinal foramen (LF in the midline of the mandible) connected with mental canal and occurred only 12.8%. We obtained the reported diameter of spinal foramen is above 0.4 mm in the minimum permissible size from dry skulls. Therefore the low frequency of occurrence in “mental

spinal foramen” was found in our study from dry skulls.

Mardinger *et al.* (2000)⁶⁾ found that the incisive canal was undetected by radiographic observation mainly because of the bony structure in the mental region of the mandible. Muraiwa *et al.* (2003)⁹⁾ and De Andrade *et al.* (2001)²⁾ also pointed out the risk of damage to vital anatomic structures, such as the anterior looping of the mental nerve and distribution of incisive nerve, in surgical procedures.

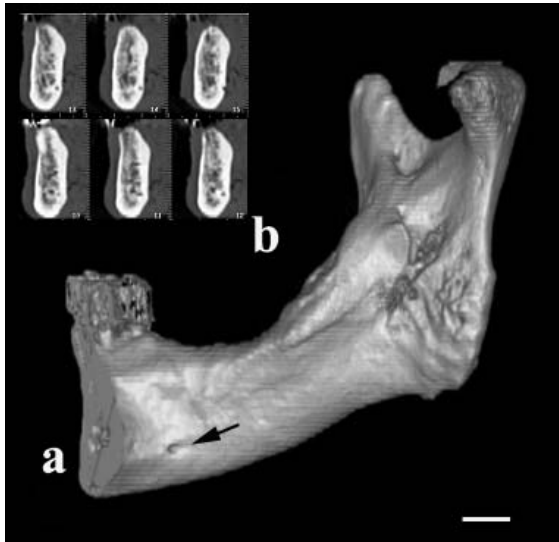


Fig. 4. Three-dimensional reconstruction of the right half of the mandible. (a) The lingual foramen (arrow) was found near the basal region on the internal aspect of the mandible. (b) The lingual canal communicated with the inferior canal from reconstruction of continuous 6 slices of CT images. Bar = 1 cm

Hofschneider *et al.* (1999)⁴⁾ observed that the sublingual artery entering the mandible is important in implant surgery in terms of the risk of injury to this vessel or one of its branches. The distance from the MF to the incisive nerve is about 21 mm, and the distance from the inferior border of the mandible to the incisive nerve is about 11 mm²⁾. Although this small area of bony structure in the mental region of the mandible is a landmark for implant surgery, it is difficult to visualize the lingual canal and the LF by radiography. By using computer-assisted systems, surgical damage of the nerve, vessel and neighboring anatomical structures can be reduced. The anatomical condition of the mental region can give beneficial information for determining implant placement, and is amenable to 3-D reconstruction by CT images. Surgical planning based on 3-dimensional radiological information is useful for surgical procedures in the oral and maxillofacial region³⁾. Multiplanar (MPR) and 3-D reconstructions permit adequate assessment of the extent of mandibular infiltration and allow early detection of ischemic complications and distant recurrences¹⁰⁾. In our results, MPR images gave useful information

of the bone structure in the mental region containing a branch of the incisive canal, such as the lingual canal. Therefore, the appearance of lingual and mental spinal foramina by CT imaging can point out possible risks of injury to vessels and nerves in the mental region.

References

- 1) Chapnick L. A foramen on the lingual of the mandible. *J Can Dent Assoc* 1980; **46**:444–445.
- 2) De Andrade E, Otomo-Corgel J, Pucher J, Ranganath KA Jr and St George N. The intraosseous course of the mandibular incisive nerve in the mandibular symphysis. *Int J Periodontics Restorative Dent* 2001; **21**:591–597.
- 3) Hassfeld S, Muhling J and Zoller J. Intraoperative navigation in oral and maxillofacial surgery. *Int J Oral Maxillofac Surg* 1995; **24**:111–119.
- 4) Hofschneider U, Tepper G, Gahleitner A and Ulm C. Assessment of the blood supply to the mental region for reduction of bleeding complications during implant surgery in the interforaminal region. *Int J Oral Maxillofac Implants* 1999; **14**:379–383.
- 5) Jacobs R, Mraiwa N, van Steenberghe D, Gijbels F and Mirylen M. Appearance, location, course, and morphology of the mandibular incisive canal: an assessment on spiral CT scan. *Dentomaxillofac Radiol* 2002; **31**:322–327.
- 6) Mardinger O, Chaushu G, Arensburg B, Taicher S and Kaffe I. Anatomic and radiologic course of the mandibular incisive canal. *Surg Radiol Anat* 2000; **22**:157–161.
- 7) Madeira MC, Percinoto C, das Gracas M and Silva M. Clinical significance of supplementary innervation of the lower incisor teeth: a dissection study of the mylohyoid nerve. *Oral Surg Oral Med Oral Pathol* 1978; **46**:608–614.
- 8) McDonnell D, Reza NM and Todd ME. The mandibular lingual foramen: a consistent arterial foramen in the middle of the mandible. *J Anat* 1994; **184**:363–369.
- 9) Muraiwa N, Jacobs R, van Steenberghe D and Quirynen M. Clinical assessment and surgical implications of anatomic challenges in the anterior mandible. *Clin Implant Dent Relat Res* 2003; **5**:219–225.
- 10) Preda L, Dore R, Benazzo M, Occhini A, Giulio GD, Fianza AL and Campani R. The role of computed tomography in the preoperative assessment and follow-up of oromandibular reconstruction with microvascular osteomyocutaneous free flaps. *Dentomaxillofac Radiol* 1999; **28**:338–343.
- 11) Shiller WR and Wiswell OB. 1954. Lingual foramina of the mandible. *Anat Rec* 1954; **119**:387–390.
- 12) Tepper G, Hofschneider UB, Gahleitner A and Ulm C. Computed tomographic diagnosis and localization of bone canals in the mandibular interforaminal region for prevention of bleeding complications during implant surgery. *Int J Oral Maxillofac Implants* 2001; **16**:68–72.
- 13) Williams M, Mealey BL and Hallmon WW. The role of computerized tomography in dental implantology. *Int J Oral Maxillofac Implants* 1992; **7**:373–380.