



## Fractures of the humerus during arm wrestling

### Prelomi humerusa nastali obaranjem ruke

Marko Ž. Bumbaširević\*†, Aleksandar R. Lešić\*†, Sladjana Z. Andjelković\*†,  
Tomislav D. Palibrk\*, Suzana M. Milutinović\*

\*Orthopedic and Traumatology Clinic, Clinical Center of Serbia, Belgrade, Serbia;

†Faculty of Medicine, University of Belgrade, Belgrade, Serbia

#### Abstract

**Background/Aim.** Humeral shaft fractures may occur as a result of arm wrestling. The aim of this study was to present our treatment of humerus fracture sustained during arm wrestling. **Methods.** A total of six patients, aged 22 to 48, were treated at our department from January 2008 to January 2010 with open reduction and internal fixation and with hanging arm casts. A review of all the relevant literature on the subject was also presented. **Results.** In all the cases, the fractures healed and function returned to normal. No patient had any neural or vascular compromise. **Conclusion.** Closed and operative treatments were equally successful in all reported cases.

#### Key words:

humeral fractures; athletic injuries; orthopedic procedures; treatment outcome.

#### Apstrakt

**Uvod/Cilj.** Prelom dijafize humerusa može nastati kao rezultat „obaranja ruke“. Cilj rada bio je prikaz načina lečenja preloma humerusa zadobijenih prilikom obaranja ruke. **Metode.** U periodu od januara 2008. do januara 2010. godine lečili smo na našem odeljenju šest pacijenata, starosti od 22 do 48 godina, otvorenom repozicijom i unutrašnjom fiksacijom ili visećim gipsom. Takođe, pregledana je i analizirana postojeća literatura vezana za ovu vrstu povrede. **Rezultati.** Kod svih bolesnika došlo je do srastanja preloma i potpunog funkcionalnog oporavka. Pacijenti nisu imali neurološke, ni vaskularne povrede. **Zaključak.** Operativno i neoperativno lečenje jednako su uspešni kod ove vrste povreda.

#### Ključne reči:

humerus, prelomi; povrede, atletske; ortopedске procedure; lečenje, ishod.

#### Introduction

Humeral shaft fractures may occur as a result of arm wrestling, also known as “iron arm”, “wrist wrestling” or “Indian wrestling”. In this game (contest) two opponents sit face-to-face with their elbows placed on a surface, gripping their hands and trying to force opponent's arm down. According to the literature, different types of fractures can occur. Spiral fracture of the humeral shaft with or without butterfly fragment<sup>1</sup>, fracture of the medial humeral epicondyle<sup>2</sup>, radial head fracture with anterior dislocation, even a radial shaft fracture<sup>3</sup>. However, most of the injuries from arm wrestling are soft tissue injuries as muscular strain and sprain of the shoulder, elbow and wrist joints.

The aim of this study was to present our experience with treatment of humerus fracture sustained during arm wrestling.

#### Methods

Within a 2-year period (from January 2008 to January 2010) we treated 6 patients with humeral shaft fractures. The

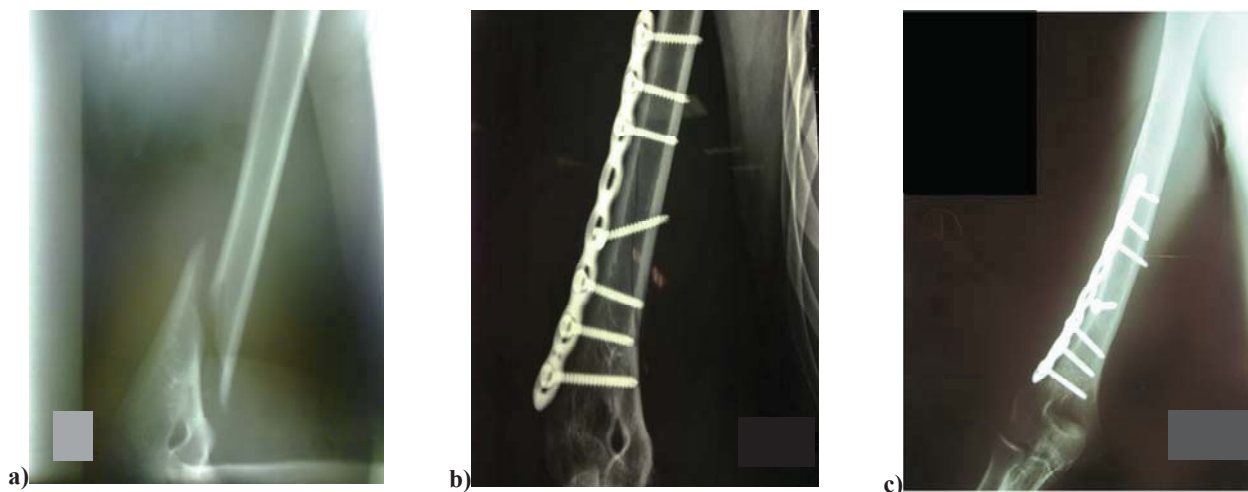treatment included open reduction and internal fixation and hanging arm casts.

#### Results and discussion

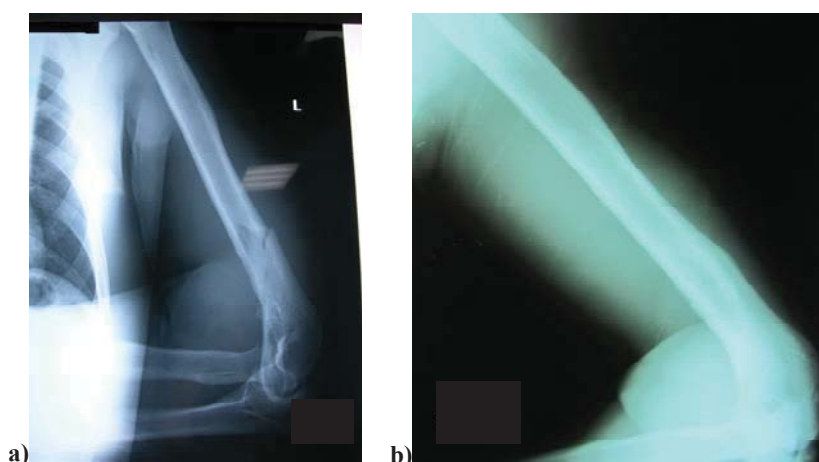
All treated patients were males and all of them wrestled with their right arm. The patients ranged in age from 22 to 48 years old, average 31.2 years.

Their humerus fractures were spiral in nature and usually located between the middle and distal third of the humerus. One case had a medial butterfly fragment. Three patients were operated primarily (Figure 1). The fracture was fixed with an AO compression plate, and the postoperative course was regular. During surgical procedure we found a muscle interposed between the fracture fragments. Three patients were treated with a hanging arm cast following closed reduction (Figure 2).

All the fractures united. The average union time of the humeral shaft fracture was ten weeks. No patient had any neural or vascular compromise. There was no shoulder, elbow, nor finger stiffness. The patients were re-



**Fig. 1 – Patient A: a) preoperative radiography done at the Emergency Room Department on the day of injury; b) and c) postoperative radiography.**



**Fig. 2 – Patient B: a) initial radiography done at the Emergency Room Department on the day of injury; b) radiography done six months after the injury (treatment with a hanging arm cast).**

turned into their previous job after an average time period of 16 weeks.

Fractures of the shaft of the humerus as a result of muscular violence are uncommon. In the literature we found articles with a small number of patients (mostly from two to ten cases)<sup>4-6</sup>. The largest series we found in a work of Ogawa and Ui<sup>7</sup> from Japan. They analyzed 30 patients with humeral shaft fracture sustained during arm wrestling.

It is obvious that arm wrestling can be connected with a powerful muscle activity, especially in the shoulder joint. While the elbow joint is fixed in flexion by the biceps and brachialis muscle, the shoulder joint is actively internally rotated against the opponent by pectoralis major, subscapularis and teres major muscle. It results in strong violent torque forces across the humeral shaft. The possible mechanism was discussed in many articles<sup>2, 6, 8, 9</sup>. Humerus shaft fractures are spiral with or without butterfly fragment. According to some authors, pure rotator force without axial load on the humerus causes spiral fracture only, while axial load and rotator force can cause a butterfly fragment<sup>1</sup>.

Fractures will unite regardless of the type of treatment, but we believe that open reduction and internal fixation shortens the immobilization time and functional recovery is faster. In our cases there was no nerve involvement, but we found that some authors recorded radial nerve palsy<sup>7, 8, 10</sup>.

Some authors also mention other factors like hypertrophy of muscles, fatigue and kinetic forces of body weight, which may contribute to fracture of the humerus, because they create of unbalanced forces<sup>8</sup>. Some also believe that position of the arm during competition determine the fracture location and type<sup>11</sup>.

In Citak's series of cases with only muscle strain, patients had regular sport activity. These factors may be considered as important for the intensity of injury<sup>3</sup>. On the other hand, many believe that these clinical entities may occur in anyone of any age who engages in this type of sport<sup>7, 12</sup>.

### Conclusion

Arm wrestling may cause severe injuries. Different types of fractures after arm wrestling have been reported in

the literature, but the most common is humeral shaft fracture. These fractures are the result of torsion forces and axial compression applied to the humerus. Closed and operative treatments were equally successful in all reported cases.

### Acknowledgement

This work was supported by the Ministry of Education and Science of the Republic of Serbia (175–095).

### R E F E R E N C E S

1. Moon MS, Moon YW, Sihn JC, Kim SS, Sun DH, Kim SS. Arm wrestler's injury-A report of thirteen cases. *J. Orthopedic Surg* 1997; 5(2): 29–34.
2. Ogawa K, Ui M. Fracture-separation of the medial humeral epicondyle caused by arm wrestling. *J Trauma* 1996; 41(3): 494–7.
3. Citak M, Backhaus M, Seybold D, Muhr G, Roetman B. Arm wrestling injuries: report on 11 cases with different injuries. *Sportverletz Sportschaden* 2010; 24(2): 107–10. (German)
4. Moon MS, Kim I, Han IH, Suh KH, Hwang JD. Arm wrestler's injury: report of seven cases. *Clin Orthop Relat Res* 1980; (147): 219–21.
5. Peace PK. Fractures of the humerus from arm wrestling. *Injury* 1977; 9(2): 162–3.
6. Brismar B, Spangen L. Fracture of the humerus from arm wrestling. *Acta Orthop Scand* 1975; 46(4): 707–8.
7. Ogawa K, Ui M. Humeral shaft fracture sustained during arm wrestling: report on 30 cases and review of the literature. *J Trauma* 1997; 42(2): 243–6.
8. Low BY, Lim J. Fracture of humerus during arm wrestling: report of 5 cases. *Singapore Med J* 1991; 32(1): 47–49.
9. Khashaba A. Broken arm wrestler. *Br J Sports Med* 2000; 34(6): 461–2.
10. Heilbronner DM, Manoli A, Morava LG. Fractures of the humerus in arm wrestlers. *Clin Orthop Relat Res* 1980; (149): 169–71.
11. Whitaker JH. Arm wrestling fractures: a humerus twist. *Am J Sports Med* 1977; 5(2): 67–77.
12. Abčan U, Aleš A, Završnik J. Završnik J. Spiral fracture of the humerus caused by arm wrestling. *Eur J Trauma* 2000; 26(6): 308–11.

Received on April 2, 2014.  
Accepted on June 27, 2014.