

Bilateral microtia, canal atresia and aplasia of cochleovestibular nerve

Asma binti Abdullah, Ms ORL-HNS^{1,2}, Roslenda Abdul Rahman, Ms ORL-HNS^{1,2}, Fadzilah Ismail, Ms ORL-HNS³, Mazita Ami, Ms ORL-HNS⁴, Marina Mat Baki, PhD (UCL)¹, Aini Ab Aziz, Ms Rad (UKM)⁵

¹Department of Otolaryngology, Head & Neck Surgery, Universiti Kebangsaan Malaysia Medical Centre, Kuala Lumpur, Malaysia, ²Institute of Ear, Hearing and Speech (Institute-HEARS), Universiti Kebangsaan Malaysia, Kuala Lumpur, Malaysia, ³Department of Otorhinolaryngology-Head & Neck Surgery, Sungai Buloh Hospital, Malaysia, ⁴KPJ Klang Specialist Hospital, Klang, Selangor, Malaysia, ⁵Department of Radiology, Universiti Kebangsaan Malaysia, Kuala Lumpur, Malaysia

SUMMARY

A six-month-old baby with congenital patent ductus arteriosus (PDA), bilateral microtia and canal atresia was referred for hearing assessment. The audiology assessment revealed bilateral profound hearing loss, which is atypical for a case of pure canal atresia. Imaging was performed much earlier than usual and, as suspected, the patient also had bilateral severe inner ear anomaly. It is extremely rare for a person to have both external and inner ear anomaly because of the different embryological origin. The only suitable hearing rehabilitation option for this kind of patients is brainstem implant. However, the parents had opted for sign language as a form of communication.

KEY WORDS:

Microtia, canal atresia, cochleovestibular nerve aplasia, inner ear anomaly

INTRODUCTION

Microtia is a malformation of the auricle, ranging from minimal abnormalities to major structural alterations or even total absence of the external ear. There are several grading systems for microtia. In the Marx classification, all of the features of a normal auricle are present in grade I (pinna is smaller than normal). In grade II, some anatomical structures are still recognisable. And in the most common form, grade III (the peanut-shell type), only a rudiment of soft tissue is present.¹

Microtia can affect either one ear (unilateral) or both ears (bilateral). The incidence of unilateral atresia is roughly three times greater than bilateral atresia, and there is a slight male predominance. Individuals with unilateral microtia usually have normal hearing in the other ear. Therefore, the speech and language development is usually normal. Many environmental factors that can cause congenital malformations are closely associated with the occurrence of isolated microtia. Univariate comparisons demonstrated that the prevalence of microtia was higher in patients whose parents lived in rural areas during pregnancy than in patients whose parents lived in urban areas. Rural residents may have greater exposure to farm toxins or chemicals than

urban residents. In addition, rural inhabitants generally have lower education levels, and lack of education may lead to poor prenatal care, which can affect embryonic development.

Microtia is often accompanied by canal atresia. The correlation between microtia grade and severity of middle ear abnormalities has been reported.² Congenital aural atresia is one of the most difficult and challenging surgeries for the ENT surgeon as aberrant course of facial nerve, absence of oval and/or round windows, poor pneumatization of the middle ear space, and fusion of malleus and incus. However, in the hands of experienced otologists, repair of this deformity can be performed safely and with predictable results using transmastoid approach. Transmastoid approach is a safe method to create a functional pathway by which sound can reach the cochlear fluid. But having a mastoid cavity may be problematic in some cases. In 1989, Bassila et al. reported that hemifacial microsomia patients with microtia and sensorineural hearing loss and facial palsy.³ Other treatment options for those with microtia, canal atresia and conductive or mixed hearing loss is the use of bone anchored hearing aid.

CASE REPORT

A 6-month-old baby girl presented with congenital bilateral microtia and aural atresia with congenital patent ductus arteriosus (PDA) to our clinic. She was delivered via elective lower caesarean section to a diabetic mother with two previous scars at 38th weeks of gestation. There was no history of toxin exposure or maternal infection during the pregnancy. She also did not have a family history of hearing loss or craniofacial malformation. Clinical examination showed that there was a right anotia with a skin tag and aural atresia. The left ear consists of a vertical skin appendage with malformed lobule and canal atresia. No other syndromic features were noted. The facial nerve function was normal bilaterally. The auditory evoked brainstem response (BSER) revealed bilateral profound hearing loss with no response at 95dBHL bilaterally and auditory steady state responses (ASSR) also confirmed no response to high intensity bilaterally.

This article was accepted: 2 August 2016

Corresponding Author: Asma Abdullah

Email: asmappukm@gmail.com

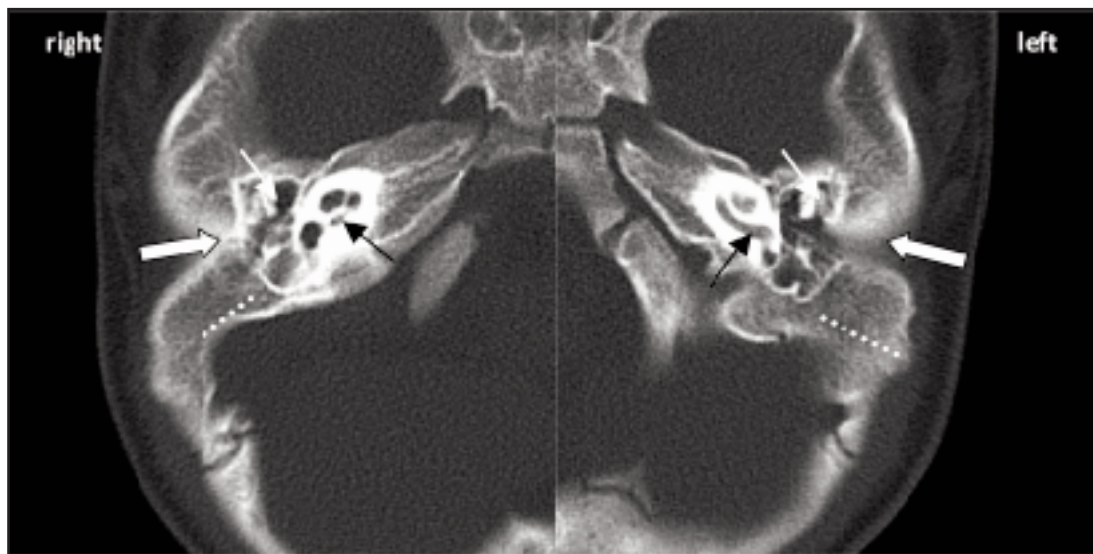


Fig. 1: Axial HRCT of the right and left temporal bone depicting bilateral atretic canal (block-arrow) with abnormal ossicles (white arrow), un-pneumatized mastoid (dotted line) and normal cochlea turns (black arrow).

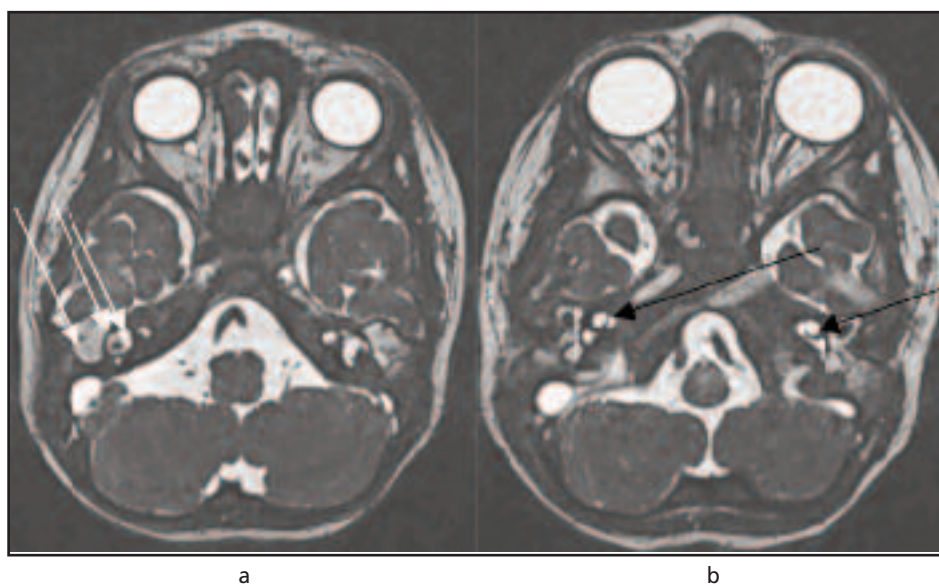


Fig. 2: MRI internal auditory meatus a) demonstrates effusion within bilateral middle ear cavity, normal vestibule and lateral semi-circular canal (white arrow) b) depicts bilateral normal cochlear (black arrow).

High resolution computed tomography scan (HRCT) of temporal bone demonstrated abnormalities of the external and middle ear (Figure 1). Both ear canals were atretic. Both the incudo-malleolar complexes were abnormal and the heads of malleus were underdeveloped. The stapes could not be identified bilaterally. The horizontal segments of the facial nerve in both mastoids were identified. The cochlear (Figure 1), superior, lateral and posterior semi-circular canals were also normal bilaterally. Both mastoid air cells were poorly pneumatized.

Magnetic Resonance Imaging (MRI) revealed effusions in both middle ears. The semi-circular canals (superior, posterior and lateral), vestibules and cochlear on both sides returned normal high signal intensity on T2WI (Figure 2). However, both the internal auditory canals (IAC) were stenosed (Right: 0.06 mm, Left: 0.09 mm), and only a single nerve was seen traversing the pontine cistern to the IAC bilaterally; the facial nerve. Hence, the diagnosis of bilateral aplastic vestibulocochlear nerve was made. She also underwent further tests which revealed normal kidneys and normal spine, to rule out Alport Syndrome and Klippel Feil Syndrome.

DISCUSSION

The incidence of congenital aural atresia ranges from 1 in 10,000 to 1 in 20,000 births and the incidence of bilateral microtia is reported at 10% to 30%, with right ear involvement in 55% to 65% of unilateral cases.⁴ The incidence of inner ear abnormalities associated with microtia is estimated between 10% and 47%,⁴ and 45% of patient with aural atresia have concomitant other abnormalities, particularly of the spine and genitourinary. In most cases of aural atresia, sensorineural function is normal, and aural atresia causes a maximal conductive hearing loss with speech reception threshold (SRT) of 45 to 60dB.

Sensorineural hearing loss (SNHL) is a type of hearing loss in which the root cause lies in either the vestibulocochlear nerve (cranial nerve VIII), the inner ear, or auditory processing centre of the brain. Early detection of sensorineural hearing loss and immediate attention towards its management are of paramount importance. Sensorineural hearing loss in conjunction with bilateral aural atresia and microtia is rare and the prevalence varies among studies ranging from 6% to 16%.² Congenital IAC stenosis is even more rare and about 20% of patient with congenital SNHL have radiographic abnormalities of inner ear and only 12% of them are reported to be accompanied by IAC stenosis.⁵ The peculiarity of this case is that this patient has bilateral canal atresia and stenosis of the IAC with aplasia of the cochleovestibular nerve. We strongly advocate that all cases of congenital canal atresia and bilateral profound SNHL should have early HRCT scan of the temporal bone and MRI to evaluate the status of external and middle ear as well as the inner ear structures respectively. However, for those children with bilateral canal atresia with expectant conductive hearing loss, the HRCT scan should be performed at four years of age as it is the time the mastoid air cells and middle ear structures have completely formed. This is the current recommended practice.

Since 2004, all potential candidates for our cochlear implantation (CI) require HRCT and MRI preoperatively. Selection criteria for CI has been expanded to include children with cochleovestibular malformations, cochlear nerve deficiency, associated syndromes, as well as multiple medical and developmental disorders. In this particular case, CI is contraindicated because of the aplastic cochleovestibular nerves bilaterally. She would have been considered for brainstem implantation. However this option was not available at that particular time. And the patient ended up learning sign language as a form of communication.

In conclusion, this case is extremely rare as the child has congenital abnormalities in all three compartments of the ear; external, middle and inner ear anomalies. The embryological development of the external and middle ear is different from inner ear, therefore they rarely co-exist. In most cases of canal atresia, imaging is performed at four years old. However, if the hearing loss is profound it is advocated to do it earlier to assess for inner ear anomalies.

REFERENCES

1. Alaani ST, Alrawi AA. Report of bilateral microtia in 2 successive female siblings in Fallujah General Hospital. *Science* 2013; 2(4): 141-43.
2. Ishimoto S, Ito K, Yamasoba T, Kondo K, Karino S, Takegoshi H et al. Correlation between microtia and temporal bone malformation evaluated using grading systems. *Arch Otolaryngol Head Neck Surg* 2005; 131(4): 326-9.
3. Bassila MK, Goldberg R. The association of facial palsy and/or sensorineural hearing loss in patients with hemifacial microsomia. *Cleft Palate J* 1989; 26(4): 287-91.
4. Lin K, Marrinan MS, Shapiro WH, Kenna MA, Cohen NL. Combined microtia and aural atresia: issues in cochlear implantation. *Laryngoscope* 2005; 115(1): 39-43.
5. Baek SK, Chae SW, Jung HH. Congenital internal auditory canal stenosis. *J Laryngol Otol* 2003; 117(10): 784-7.