

Pulsed radiofrequency with multineedles: a therapeutic proposal for wrinkles, sagging, and periorbital pigmentation

Radiofrequência pulsada com multiagulhas: uma proposta terapêutica em rugas, flacidez e pigmentação periorbital

DOI: <http://dx.doi.org/10.5935/scd1984-8773.20157303>

ABSTRACT

Introduction: *The periorbital subunit is one of the first regions to present signs of aging, resulting in sagging, wrinkles, and pigmentation. Surgical and non-surgical ambulatorial procedures, including chemical peels, lasers, neurotoxins, and cutaneous filling, form an important basis for the rejuvenation of this region.*

Objective: *The objective of this retrospective clinical study was to evaluate the effectiveness of micro-needling assisted radiofrequency for rejuvenating the periorbital region.*

Methods: *Retrospective study of the technique's safety and effectiveness through the evaluation of the results with the application of a satisfaction questionnaire to patients and of the analysis of clinical outcomes by independent dermatologists.*

Results: *Nineteen patients aged between 42 and 67 years who underwent the technique were evaluated. One hundred percent of the patients reported satisfaction with the results, whereas in the comparative evaluation of the photographs carried out by two independent dermatologists the rate of improvement was 50% in 4 patients, 75% in 8 patients, and 100% in 7 patients. Post-inflammatory hyperpigmentation was observed 10 to 15 days after the treatment in 11 patients, though it was reversed after clinical treatment.*

Conclusion: *This new procedure emerges as an alternative treatment for periorbital aging.*

Keywords: pigmentation; eyelids; pulsed radiofrequency treatment; rejuvenation

RESUMO

Introdução: A subunidade periorbital é uma das primeiras regiões a apresentar sinais de envelhecimento, resultando em flacidez, rugas e pigmentação. Procedimentos cirúrgicos e não cirúrgicos ambulatoriais formam uma importante base para o rejuvenescimento dessa região, incluindo peelings químicos, lasers, neurotoxinas e preenchimento.

Objetivo: O objetivo deste estudo clínico retrospectivo foi avaliar a eficácia da radiofrequência por microagulhas no rejuvenescimento da região periorbitária.

Métodos: Estudo retrospectivo da segurança e efetividade da técnica mediante avaliação dos resultados por aplicação de questionário de satisfação aos pacientes e julgamento dos resultados clínicos por dermatologistas independentes.

Resultados: Foram avaliados 19 pacientes com idade entre 42 e 67 anos, submetidos à técnica, 100% dos quais relataram satisfação com os resultados, enquanto na avaliação comparativa das fotografias por dois dermatologistas independentes o índice de melhora foi de: 50% em quatro pacientes, 75% em oito pacientes e 100% em sete pacientes. A hiperpigmentação pós-inflamatória foi observada de dez a 15 dias após o tratamento em 11 pacientes, tendo sido revertida após tratamento clínico.

Conclusão: Esse novo procedimento se apresenta como alternativa ao tratamento do envelhecimento periorbital.

Palavras-chave: pigmentação; pálpebras; tratamento por radiofrequência pulsada; rejuvenescimento

Original Articles

Authors:

Emerson de Andrade Lima¹

¹ Coordinator, Dermatology Department, Santa Casa de Misericórdia do Recife - Recife (PE), Brazil.

Correspondence:

Emerson de Andrade Lima
Praça Prof. Fleming 35/1201 – Jaqueira
Cep: 52050-180 Recife – PE, Brazil
E-mail: emersonderma@terra.com.br

Received on: 15/08/2015

Approved on: 30/08/2015

The present study was conducted at the Santa Casa de Misericórdia do Recife - Recife (PE), Brazil.

Financial support: None
Conflict of interests: None

INTRODUCTION

The aging of the periorbital region is established by the destruction of the delicate architecture of cutaneous components, associated to the senescence of the bone, muscle, and ligament structure, resulting in sagging, excess skin, dynamic and static wrinkles, exposure of fat pads and hyperpigmentation.

Surgical and non-surgical alternatives, separately or in combination, are available for restoring the damage suffered by the region, observing the progression of diverse unaesthetic signals.¹⁻³ Techniques such as surgical and chemical blepharoplasty, hyaluronic acid based filling procedures, applications of botulinum toxin and lasers, are often used for this purpose. More recently, radiofrequency based electrocoagulation for rejuvenation of the lower eyelid was suggested by Coimbra,⁴ who reported reduction of sagging and improvement of rhytids in this region, following a certain sequence.

Based on that report, an investigation of instrumental parameters began aimed at obtaining reproducible results. For the treatment of the periorbital region, a methodology for radio frequency devices has been developed, in addition to electrodes specifically fashioned for this purpose, termed multineedle pulsed radio frequency (MPRF).

Multineedle pulsed radio frequency (MPRF)

The use of random fractional high frequency energy shot on the skin results in a dermal regeneration in the papillary-reticular interface, via stimulation of fibroblasts with consequent synthesis of collagen and elastic fibers, as well as epidermal regeneration produced by migrating keratinocytes.

The authors of the present study propose an innovative approach for cutaneous rejuvenation, based on sub-ablative energy, through electrodes with several needles, connected to a radio-electrosurgery device.

This technique, performed in a precise and punctual manner, does not compromise the tissue adjacent to the vaporized microdots and causes a significant tissular impact, thus enabling the stimulus for the new collagen.

The electrodes containing needles are called Lima 2, Lima 4, and Lima 8 (Figure 1), with the term referencing the author. They consist of respectively two, four or eight tungsten needles with a diameter of 200 thousandths of a millimeter, with identical weight and length, and arranged in parallel in order to reach the same deep plane. With a length of 1.5mm, these needles overpass the epidermis and act in the dermis, stimulating the contraction and renewal of collagen (Figure 2). The present retrospective clinical study was aimed at evaluating the effectiveness of MPRF in rejuvenating the periorbital region.

METHODS

Records of 12 women and 7 men with aging of the periorbital region were evaluated. The studied patients had undergone treatment with MPRF, performed in an outpatient setting by the same physician, between January 2015 and July 2015. Photographic documentation was carried out with the same digital camera under the same environmental conditions, im-



FIGURE 1: Lima 2, 4 and 8 electrodes

mediately before and one month after a single intervention. The study was conducted according to the ethical criteria of the Helsinki Declaration.

After antisepsis with 1% chlorhexidine, the upper and lower palpebral regions were injected with 2% lidocaine without vasoconstrictor, in the area to be treated. The FRAXX[®] device (Loktel Medical Electronics, São Paulo, Brazil - ANVISA n. 10,362,610,008) was used for the application of MPRF, in the *single pulse* mode, with selected parameters based on the experience gathered during 12 months of research. The patients in this group were treated with the device in CUT, with the parameters *potency* adjusted for 30, and *Active* adjusted for 30ms. The Lima 8 electrode was used. Only a single pass was performed, avoiding overlaps. The palpebral aesthetic unit's external limits were observed. In the upper eyelid, the procedure was performed up until the palpebral sulcus, and in the lower eyelid, up until 2.0mm from the ciliary border.

After the procedure patients received micropored tape dressing, which was removed on the following day. For the post-operative period, the patients were instructed to use cutaneous regenerator (Ciclapast baume[®], La Roche Posay, Rio de Janeiro, Brazil) twice a day, and industrialized sunscreen SPF 60.

The evaluation of the results was carried out through the application of satisfaction questionnaires to the patients and analysis of clinical outcomes by independent dermatologist physicians.

The patients' self-assessment questionnaire included questions about the degree of satisfaction with the procedure, which could be rated as *bad*, *reasonable*, *good* and *very good*.

The before and 30 days after the intervention pictures were assessed by two dermatologist physicians unrelated to the study, who used the following scale: *regular* (25% of improvement), *good* (50% of improvement), *very good* (75% of improvement) and *excellent* (100% of improvement).

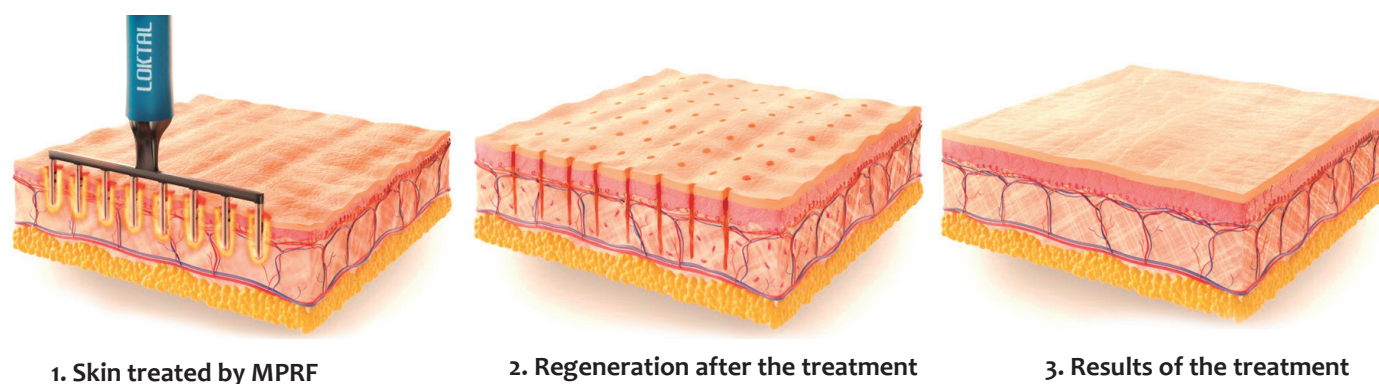


FIGURE 2: Schemes of application and regeneration, and MPRF's results

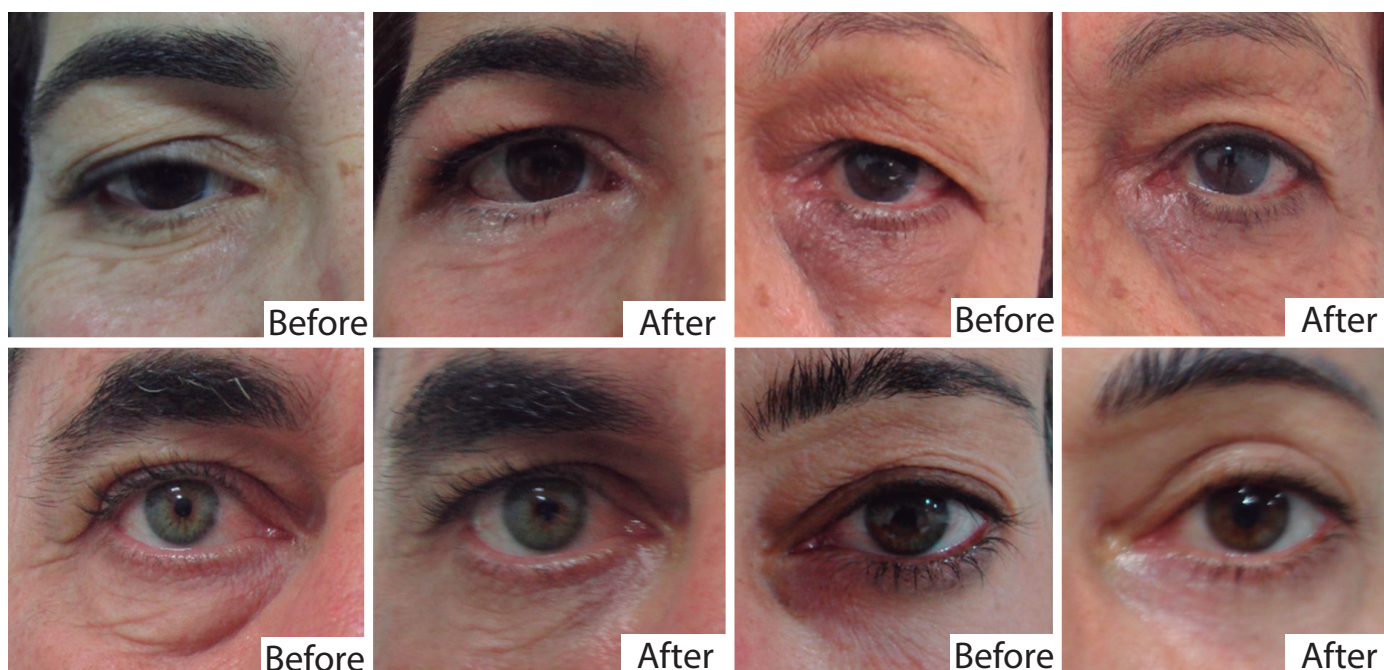


Figure 3: Appearance of the periorbital region before and 30 days after the treatment with MPRF

RESULTS

Twelve women and 7 men, between 42 and 67 years of age were recruited at the author's private clinic and at the Cosmetic Dermatology Ambulatory of the Santa Casa de Misericórdia do Recife, in the Northeast Brazilian State of Pernambuco. The skin phototype ranged from II to IV according to the Fitzpatrick classification.

All patients reported satisfaction with the results, rating them as *good* and *very good* in the questionnaire, according to the proposed questions.

In the comparative evaluation of photographs of periods before and after the procedure performed by two independent dermatologist physicians, the improvement rate was 50% (*good*) in 4 patients, 75% (*very good*) in 8 patients, and 100% (*excellent*) in 7 patients (Figure 3).

The pain during treatment was considered tolerable, with tissue regeneration being observed between 5 and 7 days, and return to work activities after the significant reduction of edema and hematoma resulting from the injected anesthesia. No infections, achromia, ectropion or unsightly scars were observed in this group.

Mild to moderate degrees of post-inflammatory hyperpigmentation were observed after a period of 10 to 15 days of treatment in 11 of 19 patients, having been resolved within 20 to 30 days using whitening formulations.

DISCUSSION

The aging of the periorbital region is a frequent complaint among patients who seek to improve their appearance.^{5, 6} Minimally invasive procedures, such as filling with hyaluronic

acid, application of botulinum toxin, use of laser with whitening and rejuvenating potential, have their limitations, especially when there are excess skin, sagging and static wrinkles.^{5,7} The surgical correction of excess skin is often not well accepted by patients, especially by the younger. Where there is modest excess skin, sagging and wrinkles, the use of a method that favors the replacement of collagen damaged by photodamage with new collagen appears to substantially improve the appearance of this region.⁴

For that purpose, the authors propose the use of MPRF – a methodology developed and thoroughly studied during the last few months – using specific electrodes – based on results observed in the last four years using already available electrodes. The data presented in the present article allow the authors to suggest that:

- MPRF is a promising therapeutic approach for periorbital rejuvenation, especially when there is no indication or desire for conventional surgery, and when thin, sagging and wrinkled skin is the most marking complaint
- The results obtained are likely to be reproduced using the methodology and electrodes described in the present article.
- The quick return to normal activities and few adverse effects observed in the group analyzed encouraged the author to recommend the inclusion of this new proposal in the already available broad therapeutic armamentarium for interventions in this region

The author suggests the evaluation the technique be carried out in other groups aimed at confirming the present paper's results and findings. ●

REFERENCES

1. Fathi R, Pfeiffer M, Tsoukas M. Minimally invasive eyelid care in dermatology: Medical, laser, and cosmetic therapies. *Clin Dermatol*. 2015; 33(2): 207–16.
2. Fioramonti P, Fallico N, Parisi P, Scuderi N. Periorbital area rejuvenation using carbon dioxide therapy. *J Cosmet Dermatol*. 2012;11(3):223-8.
3. Bagatin E, Hassun K, Talarico S. Revisão sistemática sobre peelings. *Surg Cosmet Dermatol*. 2009;1(1):37-46.
4. Coimbra D. Eletrocoagulação fracionada para o rejuvenescimento da região orbital inferior. *Surg Cosmet Dermatol*. 2010;2(3)233-6.
5. Bravo BS, Rocha CR, Bastos JT, Silva PM. Comprehensive Treatment of Periorbital Region with Hyaluronic Acid. *J Clin Aesthet Dermatol*. 2015;8(6):30-5.
6. Fathi, Pfeiffer ML, Tsoukas M. Minimally invasive eyelid care in dermatology: Medical, laser, and cosmetic therapies. *Clin Dermatol*. 2015;33(2):207-16
7. Krueger N, Levy H, Sadick NS. Safety and efficacy of a new device combining radiofrequency and low-frequency pulsed electromagnetic fields for the treatment of facial rhytides. *J Drugs Dermatol*. 2012;11(11):1306-9.