

## An animal model for the rapid induction of tongue neoplasms in human c-Ha-ras proto-oncogene transgenic rats by 4-nitroquinoline 1-oxide: its potential use for preclinical chemoprevention studies

Rikako Suzuki<sup>1,2</sup>, Hiroyuki Kohno<sup>1</sup>, Masumi Suzui<sup>3</sup>, Naoki Yoshimi<sup>3</sup>, Hiroyuki Tsuda<sup>4</sup>, Keiji Wakabayashi<sup>5</sup> and Takuji Tanaka<sup>1,\*</sup>

<sup>1</sup>Department of Oncologic Pathology, Kanazawa Medical University, 1-1 Daigaku, Uchinada, Ishikawa 920-0293, Japan, <sup>2</sup>Japan Society for the Promotion of Science, 6 Ichiban-cho, Chiyoda-ku, Tokyo 102-8471, Japan, <sup>3</sup>Department of Tumor Pathology, University of the Ryukyus Faculty of Medicine, 207 Uehara Nishihara-cho, Okinawa 903-0215, Japan, <sup>4</sup>Department of Molecular Toxicology, Graduate School of Medical Sciences, Nagoya City University, 1 Kawasumi, Mizuho-cho, Mizuho-ku, Nagoya 467-8601, Japan and <sup>5</sup>Cancer Prevention Basic Research Project, National Cancer Research Institute, 5-1-1 Tsukiji, Chuo-ku, Tokyo 104-0045, Japan

\*To whom correspondence should be addressed. Tel: +81 76 286 2211 (ext. 3611); Fax: +81 76 286 6926; E-mail: takutt@kanazawa-med.ac.jp

Oral squamous cell carcinoma is one of the most common human neoplasms, and prevention of this malignancy requires a better understanding of its carcinogenesis process. To this end, we tried to establish an animal model using the human c-Ha-ras proto-oncogene-carrying transgenic (Tg) rats and the carcinogen 4-nitroquinoline 1-oxide (4-NQO). 4-NQO (20 p.p.m.) was administered to Tg and non-Tg rats for 8 weeks in their drinking water, and then the occurrence of tongue carcinogenesis was compared during the experimental period of 22 weeks. In addition, we determined the DNA ploidy in tongue lesions and examined the immunohistochemical expression of five biomarkers such as cyclin D1, glutathione S-transferase placental form, cyclooxygenase (COX)-2, inducible nitric oxide synthase (iNOS) and  $\beta$ -catenin. Next, the cancer chemopreventive effects of nimesulide, pioglitazone and a synthetic geranylated derivative, which have been reported to be inhibitors of tongue carcinogenesis, were examined in Tg rats treated with 4-NQO. Either during or after treatment with 4-NQO in the drinking water, tongue dysplasia and tumors were observed on the tongues of both Tg and non-Tg rats, with a greater incidence and multiplicity in Tg rats. Histopathologically, squamous cell dysplasia, papilloma and carcinoma with or without invasion were present in the tongue. Immunohistochemistry revealed that expression levels against five biomarkers increase with disease progression, and the changes correlated with those of the DNA ploidy pattern. Interestingly, a strong expression of COX-2, iNOS and  $\beta$ -catenin was observed on the invasive front of squamous cell carcinomas. A subsequent chemoprevention study using Tg rats showed that the chemicals tested suppressed the occurrence of tongue carcinomas

**Abbreviations:** CDK, cyclin-dependent kinase; COX, cyclooxygenase; DMBA, 7,12-dimethylbenz(a)anthracene; EGMP, ethyl 3-(4'-geranyloxy-3'-methoxyphenyl)-2-propenoate; GST-P, glutathione S-transferase placental form; H&E, hematoxylin and eosin; iNOS, inducible nitric synthase; NO, Nitric oxide; 4-NQO, 4-nitroquinoline 1-oxide; PPAR, peroxisome proliferator-activated receptor; SCC, squamous cell carcinoma; Tg rats, Human c-Ha-ras proto-oncogene carrying transgenic rats.

when they were administered after 4-NQO-exposure. These results may thus indicate that our 4-NQO-induced Tg rat tongue carcinogenesis model simulates many aspects of human oral carcinogenesis and it can be applied for an analysis of oral cancer development while also helping to identify potentially effective cancer chemopreventive agents against oral cancer.

### Introduction

Oral cancer, mostly squamous cell carcinoma (SCC), is considered to be one of the most common neoplasms in the world with nearly 390 000 new cases per year (1). This malignancy is particularly common in such developing countries as India, Sri Lanka, Vietnam, the Philippines and Brazil, where it constitutes up to 25% of all types of cancers (2). Recently, the oral cancer incidence and mortality rates have been increasing in the USA, Japan, Germany and Scotland, especially among young males (3–5). In addition, many patients tend to develop secondary primary tumors even if the primary tumors can be treated (6). This suggests the occurrence of a multi-focal tumor development, called 'field cancerization' (7). As a result, the development of cancer chemoprevention is an important strategy for fighting this malignancy (8–10), and an animal model for preclinical studies is warranted to clarify how best to control this epithelial malignancy.

Several animal models for oral carcinoma development were utilized, including hamster, rats and mouse models. The most commonly used model is 7,12-dimethylbenz(a)anthracene (DMBA)-induced hamster cheek pouch carcinogenesis model (11) and ~60% of all SCC have a mutation in codon 61 of Ha-ras gene (12). Treatment by the administration of 4-nitroquinoline 1-oxide (4-NQO) in drinking water can induce tumors in oral cavities in rats (13) and mice (14). Oral SCCs induced by 4-NQO in rats, which shows morphological and histopathological similarities to those of human tumors, have been extensively used to investigate and test a wide variety of synthetic and natural agents for chemopreventive potential (8).

Mutations in the three *ras* genes and *p53* gene are observed in human cancers, including oral cancer (15–18). Activating mutations in K-*ras* and H-*ras* have been reported in human oral SCCs, primarily in those caused by exposure to carcinogens that are present in betel quid (19). In addition, *ras* activation involves murine oral squamous carcinogenesis (20,21), although some exceptions have been reported (22). The development of oral cancer appears to be a continuum, a progression from the early stage of oral lesions to SCC and metastasis. The results of animal model studies could thus translate directly or indirectly to clinical patients' care initiatives or at least allow targeted studies that make the best use of human clinical trials. 4-NQO-induced rat tongue carcinogenesis is such a model. In addition, genetically modified animal models are also useful

for elucidating the molecular and cellular processes that lead to cancer initiation, progression and metastasis, and on the suitability to undergo therapeutic and chemopreventive trials (23–26).

The current study was conducted using the human *c-Ha-ras* proto-oncogene-carrying transgenic (Tg) rats highly susceptible to a variety of chemical carcinogens (27) to establish a more realistic animal model for oral carcinogenesis, which reveals both histological and immunohistochemical characteristics (28) similar to the human counterpart. In this study, the sequential observation up to 22 weeks of pathological alterations in the tongue of Tg and non-Tg rats treated with 20 p.p.m. 4-NQO in their drinking water for 8 weeks was conducted. The expression of cyclin D1 (28,29), glutathione *S*-transferase placental form (GST-P) (30) cyclooxygenase (COX)-2 (31), inducible nitric synthase (iNOS) (31) and  $\beta$ -catenin (32) in the tongue lesions induced by 4-NQO was immunohistochemically investigated, because these biological and molecular markers have been characterized in experimental models for oral tumors (12,30,32). A DNA ploidy pattern was also determined in the observed tongue lesions. In addition, to assess the utility of human *c-Ha-ras* proto-oncogene Tg rats in preclinical chemoprevention study on tongue cancer, a chemoprevention study was conducted using three agents, a COX-2 inhibitor nimesulide (31), a ligand for peroxisome proliferator-activated receptor (PPAR) $\gamma$  pioglitazone (33) and a synthetic geranylated derivative ethyl 3-(4'-geranyloxy-3'-methoxyphenyl)-2-propenoate (EGMP) (34), which have been reported to exert cancer chemopreventive ability against 4-NQO-induced colon carcinogenesis in F344 rats. We have found previously the cancer chemopreventive ability of another PPAR $\gamma$  ligand troglitazone in 4-NQO-induced rat tongue carcinogenesis (29).

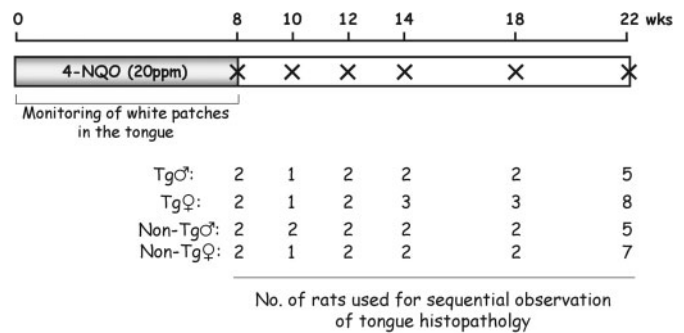
## Materials and methods

### Animals

Human *c-Ha-ras* proto-oncogene Tg and non-Tg rats bred by CLEA Japan (Tokyo, Japan) (35) at 6 weeks of age were obtained and maintained in plastic cages in an experimental room controlled at  $23 \pm 2^\circ\text{C}$  temperature,  $50 \pm 10\%$  humidity and lighting (12 h light–dark cycle). The animals were all allowed free access to a powdered basal diet CRF-1 (Oriental Yeast, Tokyo, Japan) and to tap water. The experiments were conducted according to the 'Guidelines for Animal Experiments in Kanazawa Medical University'.

### Development of animal model

A total of 69 Tg and non-Tg rats were used for the experiment after 1 week quarantine. In this experiment, which was designed to monitor the development of preneoplastic and neoplastic tongue lesions, 33 Tg rats (14 males and 19 females) and 36 non-Tg rats (20 males and 16 females) were given tap water containing 20 p.p.m. 4-NQO (98% pure, CAS no. 56-57-5, Wako Pure Chemical, Osaka, Japan) for 8 weeks, and thereafter they received no further treatments (Figure 1). The animals were sequentially killed at Week 8 (2 Tg males, 2 Tg females, 2 non-Tg males and 2 non-Tg females), Week 10 (1 Tg male, 1 Tg female, 2 non-Tg males and 1 non-Tg female), Week 12 (2 Tg males, 2 Tg females, 2 non-Tg males and 2 non-Tg females), Week 14 (2 Tg males, 3 Tg females, 2 non-Tg males and 2 non-Tg females), Week 18 (2 Tg males, 3 Tg females, 2 non-Tg males and 2 non-Tg females) and Week 22 (5 Tg males, 8 Tg females, 5 non-Tg males and 7 non-Tg females) to determine the occurrence of tongue preneoplasms and neoplasms. After killing by exsanguination under deep ether anesthesia, macroscopic observations were performed and the number of grossly visible tumors in the tongue and esophagus were recorded, and then these organs were processed for histopathological examination after being fixed in 10% buffered formalin. The tongues with or without lesions were also processed to assess the expression of cell proliferation biomarkers by immunohistochemistry. For a histological examination, the tissue and gross lesions were fixed in 10% buffered formalin, embedded in paraffin blocks, and then the histological sections were



**Fig. 1.** Experimental protocol. X, killing time points. Nos, number of Tg and non-Tg rats that are killed for tongue histopathology.

stained with hematoxylin and eosin (H&E). Epithelial lesions (hyperplasia, dysplasia and neoplasia) in the oral cavity were diagnosed according to the criteria described by Banoczy and Csiba (36) and Kramer *et al.* (37). To determine the multiplicity of the tongue lesions, the tongue was examined for gross lesions without the use of any magnification aid. The tongue was cut in half longitudinally and each tissue specimen was fixed in 10% buffered formalin. Each tissue was totally submitted as multiple transverse sections for histological processing. This averaged 5–6 pieces/tissue and 10–12 pieces/total tongue. The tongue lesions were counted on all slides stained with H&E, then the sum was divided by the number of slides, and they were expressed as the mean  $\pm$  SD.

### Immunohistochemistry for cyclin D1, GST-P, COX-2, iNOS and $\beta$ -catenin

After killing, the tongues were removed and processed to make tissue sections. Paraffin-embedded tongue tissues were cut and nine serial sections (3  $\mu\text{m}$ ) were made. One section was used for the histopathology, and the others for the immunohistochemistry of cyclin D1, GST-P, COX-2, iNOS and  $\beta$ -catenin. Immunohistochemistry for these antibodies was performed using a stain system kit ENVISION+ (K4003 or K4001, DakoCytomation, Kyoto, Japan). Primary antibodies used were as follows: a mouse monoclonal antibody against cyclin D1 (NCL-CYCLIN D1-GM, 1:100 dilution, Novocastra Laboratories, Newcastle upon Tyne, UK), a rabbit polyclonal antibody against GST-P (Cat. no. 311, 1:300 dilution, Medical and Biological Laboratories, Nagoya, Japan), a rabbit polyclonal antibody against COX-2 (Cat. no. 210726, 1:200 dilution, ALEXIS JAPAN, Tokyo, Japan), a rabbit polyclonal antibody against iNOS (Cat. no. ab15326, diluted, Abcam, Cambridge, UK) and a rabbit polyclonal antibody against  $\beta$ -catenin (Cat. no. sc-7199, 1:100 dilution, Santa Cruz Biotechnology, Santa Cruz, CA). These antibodies were applied to the sections according to the manufacturer's protocol. As negative controls, adjacent sections were processed by omitting incubation with the primary antibodies (cyclin D1, GST-P, COX-2, iNOS and  $\beta$ -catenin). The slides were subsequently reviewed in a blinded fashion.

The cells were considered positive for cyclin D1 when definite nuclear staining was identified. Positive cell ratios for cyclin D1 were calculated by counting at least 50 cells in the tongue lesions of each rat. The immunohistochemical expression of GST-P, COX-2, iNOS and  $\beta$ -catenin was observed with the grading intensity of the immunoreactivity in neoplasms and preneoplastic lesions of the tongue. Lesions with a stainability in  $>1\%$  of the cells were regarded as positive, whereas all others were regarded as negative. To quantitate the degree of stainability for each antibody, the grading system was used according to the following criteria described by (–), no immunoreactivity; ( $\pm$ , +, ++), increasing degrees of intermediate immunoreactivity; and (+++), extensive immunoreactivity. Care was taken to exclude the possibility of any inflammatory cells that were mistakenly identified as positive epithelial cells.

### DNA ploidy analysis

Tongue lesions developed in Tg males that received 4-NQO and then were killed at Week 22 were used for the DNA ploidy analysis. Sections of 5  $\mu\text{m}$  adjacent to H&E and immunohistochemically stained sections were processed for Feulgen's staining (38) after hydrolysis with 1 N HCl. The areas previously selected on the H&E sections were identified on projections of the Feulgen-stained sections. A microspectrophotometer (MMSP, Olympus, Tokyo, Japan) was used for the measurement of nuclear DNA content. The optical setting was as follows: Objective, Plan 40 $\times$ ; Condenser, 20 $\times$ ; Measuring spot, 7–12  $\mu\text{m}$ ; Wavelength, 545 nm. More than 50 cells were measured in each lesion and 100 nuclei in SCC. The DNA content of the lymphocytes contained in the section was taken as the diploid (2C) reference value (39). Ploidy histograms

(frequency of occurrence of individual cell ploidy values) were constructed for each histological category. Aneuploidy was objectively computed on the basis of the algorithm (40) as the 5C exceeding rate that is defined as the percentage of cells with a DNA content of  $>5C$ . Finally, the mean ploidy and mean rates (%) of  $<2.5C$ ,  $2.5-5C$  and  $>5C$  for each lesion category were calculated.

#### Chemoprevention study using Tg rats

For 8 weeks, 15 Tg males and 24 Tg females were given 4-NQO (20 p.p.m. in drinking water). Tg males were then divided into two groups: Group 1 (8 males) received no further treatment and Group 2 (7 males) was fed the experimental diet containing 400 p.p.m. nimesulide (Sigma Chemical, St Louis, MO) for 11 weeks, starting 1 week after cessation of 4-NQO exposure. In addition, 24 Tg females were then divided into three groups: Group 3 (7 females) received no further treatment. Groups 4 (9 females) and 5 (8 females) were fed the experimental diets mixed with 500 p.p.m. pioglitazone (Takeda Chemical Industries, Osaka, Japan) and 2% EGMP (96% purity, synthesized from ferulic acid) for 11 weeks, respectively, starting 1 week after the cessation of 4-NQO exposure. At Week 20, all Tg rats were killed by exsanguination under deep ether anesthesia, and macroscopic inspection was done. After killing, number of grossly visible tumors in the tongue and other tissues were recorded, and then these organs with lesions were processed for a histopathological examination after fixation in 10% buffered formalin. For histological examinations, tissue specimens and gross lesions fixed in 10% buffered formalin were embedded in paraffin blocks, and the histological sections were stained with H&E. The tongue was cut in half longitudinally and each tissue specimen was fixed in 10% buffered formalin. Epithelial lesions (hyperplasia, dysplasia and neoplasia) in the tongue were diagnosed according to the criteria described by Banoczy and Csiba (36) and Kramer *et al.* (37). To determine the multiplicity of the tongue lesions, the tongue was examined for gross lesions without the use of any magnification aid. Each tissue specimen was totally submitted as multiple transverse sections for histological processing. This averaged 5–6 pieces/tissue and 10–12 pieces/total tongue. The tongue lesions were counted on all slides stained with H&E, the sum was then divided by the number of slides, and the multiplicity was expressed as the mean  $\pm$  SD.

#### Statistical analysis

A statistical analysis of the incidence of lesions was performed using Fisher's exact probability test, and the other results expressed as the mean  $\pm$  SD were analyzed by Student–Newman–Keuls multiple comparison test using the GraphPad InStat software (version 3.05) (GraphPad Software, San Diego, CA). A level of  $P < 0.05$  was considered to be statistically significant.

## Results

### Monitoring of white patches

All rats were well tolerated with oral exposure of 4-NQO in drinking water. During the study, white patches were mainly

present in the dorsal site of the root of tongue. When monitored, the number of white patches (clinically called as leukoplakia) in the tongues of Tg and non-Tg rats under light ether anesthesia, starting from Week 2 to Week 8, and the frequency of such white patches gradually increased over time in both Tg and non-Tg rats of either sex between Week 2 and Week 6 (Figure 2). However, the number of lesions in the Tg rats dramatically increased between Week 6 and Week 8 (Figure 2). In addition, the frequency of males was larger than females, in both Tg and non-Tg. At Week 8, five small ( $<2$  mm in diameter) and two large ( $>3$  mm in diameter) white patches in Tg males were biopsied to determine their histopathology. The former were histologically found to be dysplastic leukoplakia while the latter were minute SCC.

### Incidence and multiplicity of tongue neoplasms and dysplasia

Exophytic papillary or invasive tongue tumors (Figure 3A) were mainly observed in the dorsal site of the root of tongue. Dysplastic lesions with various degrees of atypia (Figure 4B–1–D–1) were also found in the tongue. Tongue tumors were histopathologically squamous cell papilloma and carcinoma with or without invasion (Figure 4E–1–G–1). The incidence and multiplicity of tongue neoplasms at each killing point are given in Table I and is illustrated in Figure 3B. All Tg males killed at Weeks 8, 10, 12, 14, 18 and 22 had tongue neoplasms (squamous cell papilloma and carcinoma). Non-Tg males that were killed at Weeks 8, 10 and 14 did not have any tongue tumors, but they had dysplastic lesions in the tongue. As for non-Tg males, one of two rats killed at Week 12, two of two rats killed at Week 18 and two of five rats killed at Week 22 developed tongue papilloma and/or carcinoma. Tg females killed at Week 8 (one of two rats), Week 12 (one of two rats), Week 14 (two of three rats), Week 18 (all three rats) and Week 22 (five out of eight rats) had tongue neoplasms (squamous cell papilloma and/or carcinoma), but one Tg female killed at Week 10 did not have any tongue tumors. Non-Tg females that were killed at Weeks 8, 10 and 12 did not develop any tongue tumors, but they did have tongue dysplastic lesions. Two of two non-Tg females killed at Week 14, one of two non-Tg females killed at Week 18 and

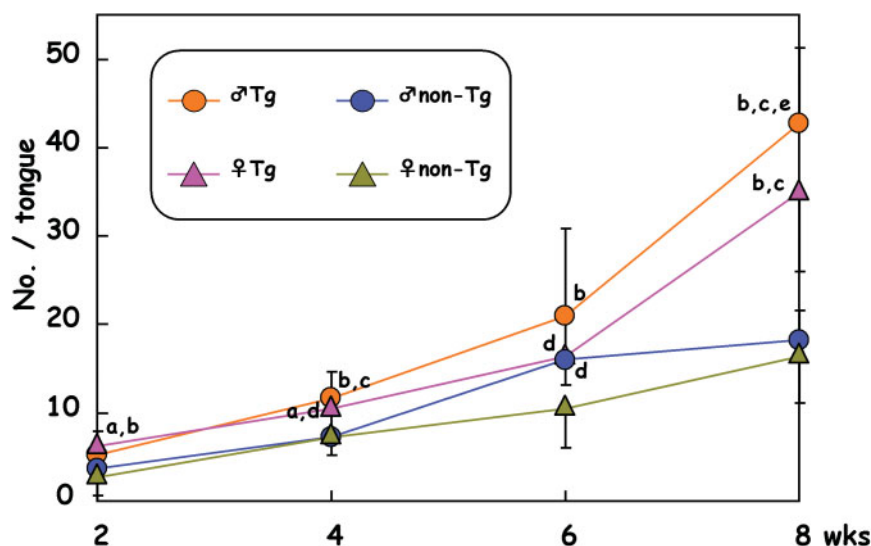
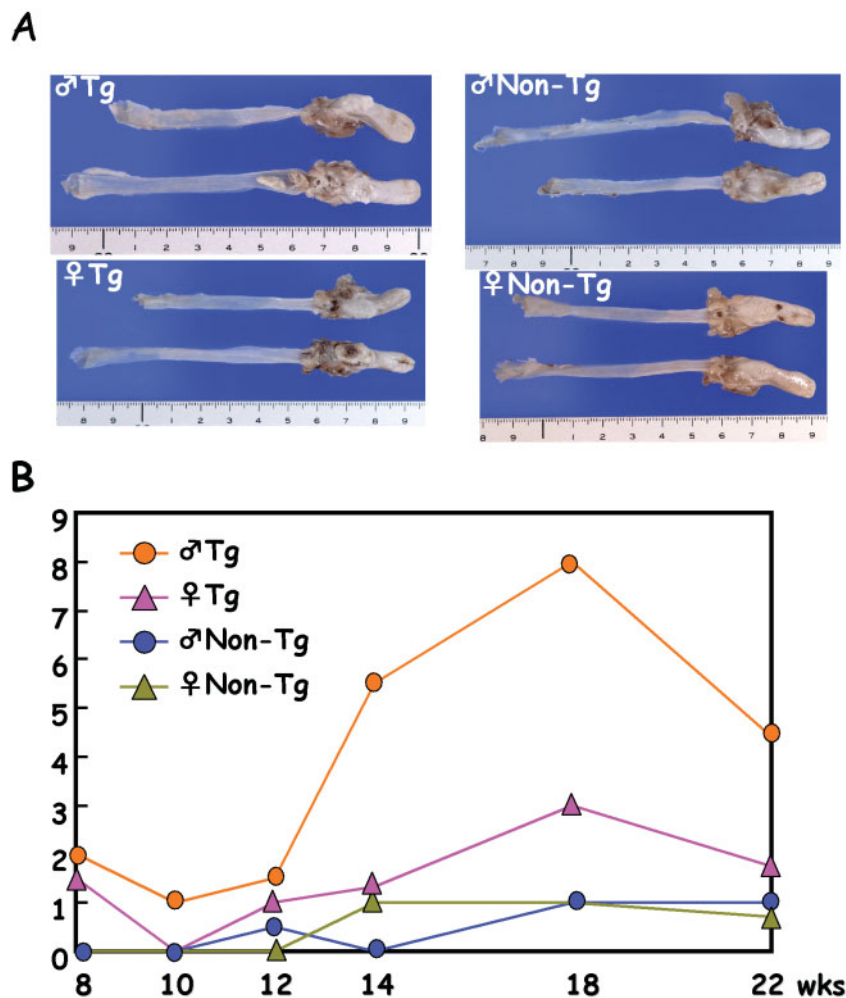


Fig. 2. Mean number of white patches in the tongue that were monitored from Week 2 through Week 8. a, significantly different from male non-Tg ( $P < 0.05$ ); b, significantly different from female non-Tg ( $P < 0.001$ ); c, significantly different from male non-Tg ( $P < 0.001$ ); d, significantly different from female non-Tg ( $P < 0.05$ ); and e, significantly different from female Tg ( $P < 0.05$ ).



**Fig. 3.** Tongue neoplasms developed in Tg and non-Tg rats that were treated with 4-NQO. (A) Macroscopic view of tongues at Week 22. Large tongue tumors with white patches develop in Tg rats of either sex, whereas only a few small tongue tumors or white patches are found in the tongue in non-Tg rats of both sexes. (B) Mean multiplicity (number of tumors/rat) of tongue tumors at each killing time point. Number of tongue tumors increased from Week 14 in male Tg rats.

two of seven non-Tg females killed at Week 22 developed papilloma and/or carcinoma. Besides neoplasms, the Tg and non-Tg rats of both sexes also had tongue dysplasia with different degrees of atypia and multiplicity: the occurrence of lesions in Tg rats was earlier than in non-Tg rats, and the frequency in Tg rats was greater than in non-Tg rats (data not shown).

In other organs, esophageal tumors and/or mammary tumors were present in Tg rats. One papilloma and two carcinomas in a Tg male killed at Week 18. In addition, two esophageal papillomas developed in a Tg male and one esophageal carcinoma in each of two Tg males that were killed at Week 22. In two Tg females, esophageal papillomas developed (one had one papilloma and the other two papillomas). However, the non-Tg rats did not develop tumors in tissues other than the tongue.

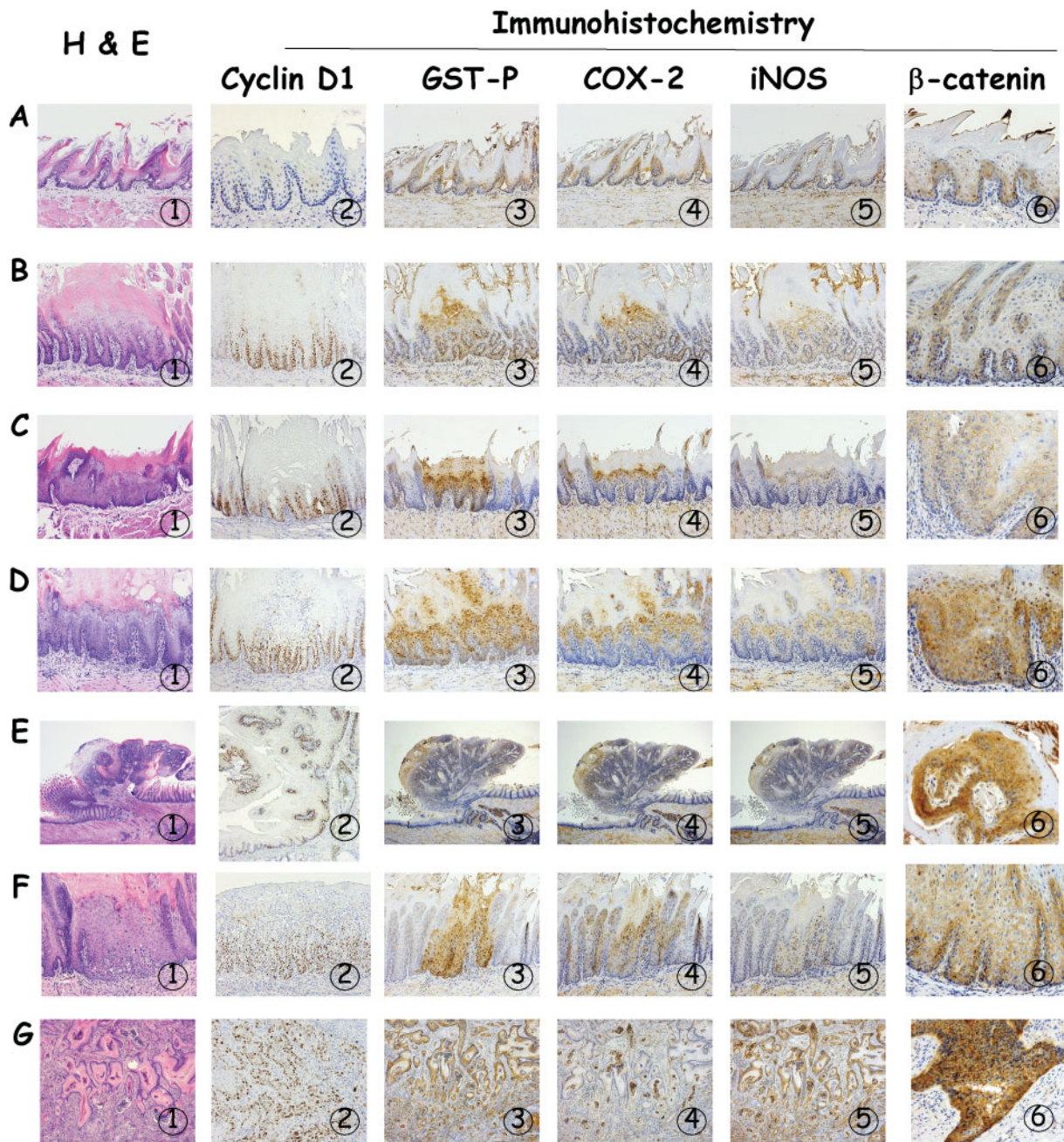
#### *Immunohistochemistry of cyclin D1, COX-2, iNOS, GST-P and $\beta$ -catenin*

Immunoreactivity against five antibodies (cyclin D1, COX-2, iNOS, GST-P and  $\beta$ -catenin) was closely similar in the non-lesional areas and lesions in the tongue of Tg and non-Tg males and females. Their expression was found in the nucleus, cytoplasm and/or cell membrane (Figure 4).

Cyclin D1 immunohistochemistry revealed that a few basal cells in the non-lesional 'normal' appearing areas were positive for nuclei (Figure 4A-2). Their nuclear stainability increased with the disease progression from dysplasia/papilloma to carcinoma (Figure 4B-2-G-2). The cyclin D1-positive ratio reflecting the rate of proliferation was the same in preneoplastic lesions dysplasia, and it reached the highest values in tumors (Table II).

Strong GST-P immunoreactivity was present in the nucleus and cytoplasm of all dysplastic lesions and carcinomas developed in rats treated with 4-NQO (Figure 4A-3-G-3). Papilloma cells were also positive for GST-P, but their intensity was weak in comparison with dysplastic and carcinoma cells (Figure 4E-3). Non-lesional cells at the lower part of squamous epithelium were weakly positive for GST-P (Figure 4A-3). The multiplicity of GST-P-positive dysplastic lesions during Week 8 through Week 22 is given in Table III. The highest multiplicity of GST-P-positive dysplastic lesions was observed at Week 12 in Tg males, at Week 8 in Tg females, at Week 18 in non-Tg males, and at Weeks 14 and 18 in non-Tg females.

COX-2 immunoreactivity was weakly present in the basal cells of the 'normal' appearing areas (Figure 4A-4-G-4). Dysplasia with mild, moderate and severe atypia



**Fig. 4.** Histopathology and immunohistochemistry of cyclin D1, GST-P, COX-2, iNOS and  $\beta$ -catenin of tongue lesions in Tg males that received 4-NQO. (A), 'Normal' appearing tongue squamous epithelium; (B) Mild dysplasia; (C) Moderate dysplasia; (D) Severe dysplasia; (E) Squamous cell papilloma; (F) SCC *in situ* and (G) Invasive SCC. (A-1), (B-1), (C-1), (D-1), (E-1), (F-1) and (G-1), H&E stain; (A-2), (B-2), (C-2), (D-2), (E-2), (F-2) and (G-2), cyclin D1 immunohistochemistry; (A-3), (B-3), (C-3), (D-3), (E-3), (F-3) and (G-3), GST-P immunohistochemistry; (A-4), (B-4), (C-4), (D-4), (E-4), (F-4) and (G-4), COX-2 immunohistochemistry; (A-5), (B-5), (C-5), (D-5), (E-5), (F-5) and (G-5), iNOS immunohistochemistry; and (A-6), (B-6), (C-6), (D-6), (E-6), (F-6) and (G-6),  $\beta$ -catenin immunohistochemistry. Five biomarkers (cyclin D1, GST-P, COX-2, iNOS and  $\beta$ -catenin) are expressed in the squamous cell lesions of these tongues and their expression increases with the disease progression. Original magnification, (A-1, A-3-5), (B-1-6), (C-1-6), (D-1-6), (F-1-5), and (G-1-5), 10 $\times$ ; (A-2), (A-6), (E-6), (F-6) and (G-6), 20 $\times$ ; and (E-1-5), 2 $\times$ .

(Figure 4B-4-D-4) showed a relatively strong positivity for COX-2 in nucleus and/or cytoplasm of cells in the upper and middle parts of the epithelium. Approximately half of all papilloma cells (Figure 4E-4) and most cancer cells (Figure 4F-4 and G-4) showed COX-2-positivity in the nucleus and/or cytoplasm. Interestingly, a strong expression of COX-2 was found in the invasion front of carcinoma, where a number of mononuclear inflammatory cells were present.

iNOS-immunohistochemistry showed a weak immunoreactivity in the nucleus and/or cytoplasm of dysplastic (Figure 4B-5-D-5) and carcinoma cells (Figure 4F-5 and G-5); the intensity was greater in the carcinoma cells than in the dysplastic cells. Similar to the COX-2 expression, a strong expression of iNOS was noted in the invasion front of cancer tissue, where numerous inflammatory cells had infiltrated. In addition, papilloma cells were positive for iNOS in their

**Table I.** Incidence and multiplicity of tongue neoplasms in Tg and non-Tg rats that received 4-NQO

Tg/non-Tg	Sex	Incidence of tongue neoplasms (multiplicity, mean or mean $\pm$ SD)					
		Week 8	Week 10	Week 12	Week 14	Week 18	Week 22
Squamous cell papilloma							
Tg	Male	2/2 (1)	0/1 (0)	0/2 (0)	2/2 (3)	2/2 (2.5)	5/5 (1.40 $\pm$ 0.80)
Tg	Female	2/2 (1)	0/1 (0)	1/2 (0.5)	2/3 (0.67 $\pm$ 0.47)	2/3 (0.67 $\pm$ 0.47)	3/8 (0.63 $\pm$ 0.99)
Non-Tg	Male	0/2 (0)	0/2 (0)	0/2 (0)	0/2 (0)	2/2 (1)	2/5 (0.60 $\pm$ 0.80)
Non-Tg	Female	0/2 (0)	0/1 (0)	0/2 (0)	2/2 (1)	1/2 (0.5)	2/7 (0.29 $\pm$ 0.45)
Squamous cell carcinoma							
Tg	Male	2/2 (1)	1/1 (1)	2/2 (1.5)	2/2 (2.5)	2/2 (5.5)	5/5 (3.00 $\pm$ 1.67)
Tg	Female	1/2 (0.5)	0/1 (0)	1/2 (0.5)	2/3 (0.67 $\pm$ 0.47)	3/3 (2.33 $\pm$ 0.47)	5/8 (1.13 $\pm$ 1.17)
Non-Tg	Male	0/2 (0)	0/2 (0)	1/2 (0.5)	0/2 (0)	0/2 (0)	2/5 (0.40 $\pm$ 0.49)
Non-Tg	Female	0/2 (0)	0/1 (0)	0/2 (0)	0/2 (0)	1/2 (0.5)	2/7 (0.43 $\pm$ 0.73)

**Table II.** Cyclin D1-positive index in various tongue lesions from male Tg and non-Tg rats treated with 4-NQO at Week 22

Lesions	Male Tg	Male non-Tg
'Non-lesional' area	2.6 $\pm$ 0.9 <sup>a</sup> (10)	6 $\pm$ 0.9 (10)
Dysplasia		
Mild	5.4 $\pm$ 1.1 <sup>b</sup> (10)	4.2 $\pm$ 0.8 (10)
Moderate	7.6 $\pm$ 1.7 <sup>c</sup> (10)	6.2 $\pm$ 2.4 <sup>c</sup> (10)
Severe	27.0 $\pm$ 5.6 <sup>d,e,f</sup> (10)	24.8 $\pm$ 4.4 <sup>d,e,f</sup> (10)
Papilloma	17.6 $\pm$ 2.1 <sup>d,e,f,g</sup> (5)	16.2 $\pm$ 4.2 <sup>d,e,f,g</sup> (5)
Carcinoma	38.8 $\pm$ 4.0 <sup>d,e,f,g</sup> (5)	37.4 $\pm$ 6.6 <sup>d,e,f,g,h</sup> (5)

Numbers in parentheses are number of lesions examined.

<sup>a</sup>Mean  $\pm$  SD.

<sup>b,c,d</sup>Significantly different from 'non-lesional' area (<sup>b</sup> $P < 0.005$ , <sup>c</sup> $P < 0.001$  and <sup>d</sup> $P < 0.001$ )

<sup>e</sup>Significantly different from 'mild dysplasia' ( $P < 0.001$ ).

<sup>f</sup>Significantly different from 'moderate dysplasia' ( $P < 0.001$ ).

<sup>g</sup>Significantly different from 'severe dysplasia' ( $P < 0.001$ ).

<sup>h</sup>Significantly different from 'papilloma' ( $P < 0.001$ ).

**Table III.** Multiplicity of GST-P-positive dysplasia at each killing time point

	Week 8	Week 10	Week 12	Week 14	Week 18	Week 22
Male Tg	5.5 <sup>a</sup> (2)	3.0 (1)	6.5 (2)	6.0 (2)	5.5 (2)	4.00 $\pm$ 2.28 (5)
Female Tg	6.5 (2)	6.0 (1)	5.0 (2)	4.7 (3)	5.0 (3)	4.00 $\pm$ 2.55 (8)
Male non-Tg	0.5 (2)	2.5 (2)	3.5 (2)	4.0 (2)	6.5 (2)	5.80 $\pm$ 2.14 (5)
Female non-Tg	3.5 (2)	3.5 (1)	4.0 (2)	5.0 (2)	5.0 (2)	4.57 $\pm$ 2.32 (7)

Numbers in parentheses are number of rats examined.

<sup>a</sup>Mean or mean  $\pm$  SD.

nucleus/cytoplasm, but the intensity was relatively lower than in cancer cells (Figure 4E-5). A faint positive reaction of iNOS was found in the nucleus/cytoplasm of the non-lesional cells at the basal layer (Figure 4A-5).

$\beta$ -Catenin staining in the non-lesional cells was weakly positive in their cell membrane, but not in the nucleus (Figure 4A-6). Their nuclear/cytoplasm/cell membrane stainability increased with disease progression from dysplasia/papilloma to carcinoma (Figure 4B-6-G-6). Among these lesions, carcinoma cells expressed the strongest intensity of  $\beta$ -catenin staining in their nuclear/cytoplasm/cell membrane (Figure 4F-6 and G-6). Interestingly, cancer cells at the invasion front expressed the cytoplasmic/nuclear pattern of

$\beta$ -catenin. Some papilloma cells were also positive for  $\beta$ -catenin in their nuclear/cytoplasm/cell membrane.

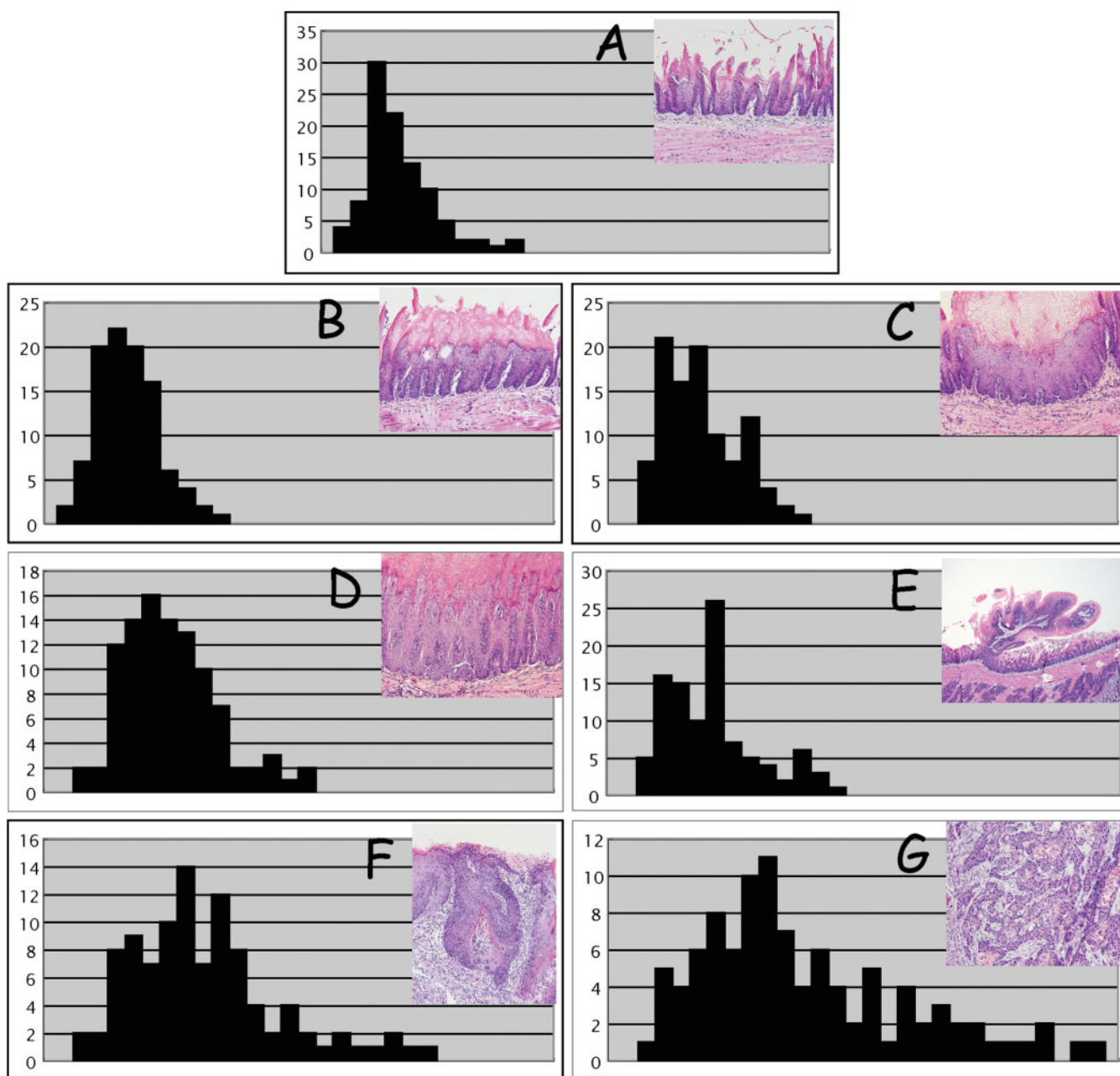
Table IV summarizes the immunoreactive intensity of five antibodies (cyclin D1, COX-2, iNOS, GST-P and  $\beta$ -catenin). Among the antibodies, GST-P positivity was the most prominent of all the lesions.

#### DNA ploidy of the tongue lesions

When determining the DNA content, ploidy histograms tended to skew to the right from the diploid value in all the histological categories. This skew increased in relation to the severity of the lesions investigated. Figure 5 shows an example of the characteristic histograms of the tongue lesions that developed in the Tg males receiving 4-NQO. Interestingly most histologically normal-appearing tongue squamous epithelium specimens showed a peak with a small deviation within the 2C-4C region and some events exceeded the tetraploid value. The mean percentages of ploidy distribution are shown in Table V. As expected, invasive carcinomas and carcinomas *in situ* exhibited a statistically significant increase in comparison with the non-lesional epithelium specimens. The mean ploidy values were around the tetraploid range. However, a considerable number of cells exhibited an aneuploid DNA content in the dysplasia and carcinoma. The results for mild dysplastic areas and histologically 'normal appearing' areas were remarkable. The mean ploidy value was significantly higher than for the 'normal appearing' areas, and aneuploid cells were detected in all of the evaluated lesions.

#### Effects of nimesulide, pioglitazone and EGMP on 4-NQO-induced tongue carcinogenesis in Tg rats

The influence of the dietary administration of the three tested chemicals (nimesulide, pioglitazone and EGMP) on tongue carcinogenesis initiated with 4-NQO in Tg rats of both sexes is illustrated in Figures 6 and 7. The administration of all the test chemicals reduced the incidence of tongue carcinoma in comparison with that in the Tg rats, which received 4-NQO alone, but the differences were not statistically significant (Figures 6A and 7A). However, the dietary administration of 400 p.p.m. nimesulide significantly lowered the multiplicity of tongue SCC (73% inhibition,  $P < 0.05$ , Figure 6B). In addition, a significant inhibition in the multiplicity of tongue SCC by feeding with 500 p.p.m. pioglitazone (61% inhibition,  $P < 0.001$ ) and by dietary feeding with 2% EGMP (34% inhibition,  $P < 0.01$ ) was observed as shown in Figure 7B. In addition, all the test chemicals in the diet reduced the development of severe tongue dysplasia (data not shown).



**Fig. 5.** Representative DNA histograms from various tongue lesions (inserts) in male Tg rats treated with 4-NQO. (A) 'Normal' appearing tongue squamous epithelium; (B) Mild dysplasia; (C) Moderate dysplasia; (D) Severe dysplasia; (E) Squamous cell papilloma; (F) SCC *in situ* and (G) Invasive SCC. DNA aneuploidy is evident with the disease progression. Inserts: tongue lesions stained with H&E. Original magnification, (A)–(D), (F) and (G), 10 $\times$ ; and (E), 2 $\times$ .

Administration of all the test chemicals in the diet did not affect the tumor incidence and multiplicity, which were quite low, in organs other than the tongue (data not shown).

## Discussion

In the current study, 4-NQO treatment rapidly induced tongue lesions (dysplasia and neoplasms) in Tg males and females, in comparison with non-Tg males and females. Our model can be utilized for the rapid assessment of the modifying effects (inhibition and/or enhancement) of xenobiotics on oral carcinogenesis. In fact, our results in a chemoprevention study using this animal model with a 20 week experimental period, where a COX-2 specific inhibitor, a PPAR $\gamma$  ligand and a

synthetic geranylated derivative suppressed the multiplicity of the tongue carcinomas induced by 4-NQO, confirmed our previous findings using a 4-NQO-induced rat tongue carcinogenesis model with a 30 or 32 week experimental period (29,31,34). Another novel finding of the present work is the association between the immunohistochemical overexpression of five biomarkers (cyclin D1, GST-P, COX-2, iNOS and  $\beta$ -catenin) and DNA aneuploidy in dysplastic and neoplastic tongue lesions.

Malignant neoplastic cells possess an indefinite proliferative capability, thus being able to elude a commitment to terminal differentiation and post-mitotic quiescence that normally regulates tissue homeostasis in an organism. In order to achieve a proliferative autonomy, malignant neoplastic cells have to

**Table IV.** Summary of immunohistochemistry of cyclin D1, GST-P, COX-2, iNOS and  $\beta$ -catenin in various tongue lesions

Antibodies	'Normal' appearing epithelium	Hyperplasia		Dysplasia			Neoplasms		
		Simple	Papillary or nodular	Mild	Moderate	Severe	Papilloma	Carcinoma <i>in situ</i>	Invasive carcinoma
Cyclin D1	-	+	+	+	+	+	+	+++	+++
GST-P	-	±	± --	+	++	++	+	+++	+++
COX-2	-	±	± --	+	+	++	+	++	+
iNOS	-	±	± --	± --	± --	+	+	+	+++
$\beta$ -catenin	+	+	+	+	++	+++	+	+++	+++

-, <5% of positive cells; ±, 5–24% of positive cells; +, 25–50% of positive cells; ++, 51–75% of positive cells; and +++, >75% of positive cells.

**Table V.** Summary of DNA ploidy determination of various tongue lesions of tg males that received 4-NQO alone

Variety of tongue lesions	No. of cases	<2.5C (%)	2.5C–5C (%)	>5C (%)	Mean ploidy
'Normal' appearing-epithelium	10	60 ± 8 <sup>a</sup>	32 ± 6	8 ± 5	2.57 ± 0.24
Dysplasia					
Mild	10	45 ± 11 <sup>b</sup>	45 ± 10 <sup>b</sup>	11 ± 9 <sup>c</sup>	3.15 ± 0.31 <sup>d</sup>
Moderate	10	25 ± 4 <sup>b,e</sup>	51 ± 7 <sup>b</sup>	24 ± 6 <sup>b,e</sup>	3.48 ± 0.35 <sup>b,f</sup>
Severe	10	18 ± 4 <sup>b,e,h</sup>	23 ± 5 <sup>e</sup>	60 ± 7 <sup>b,e</sup>	4.75 ± 0.33 <sup>b,e,i</sup>
Papilloma	10	25 ± 5 <sup>b,e,j</sup>	50 ± 5 <sup>b,k</sup>	25 ± 4 <sup>b,e,k</sup>	3.73 ± 0.64 <sup>b,g,h</sup>
CIS	10	12 ± 5 <sup>b,e,i,j,l</sup>	25 ± 8 <sup>b,e,i,l</sup>	63 ± 8 <sup>b,e,i,l</sup>	5.01 ± 0.58 <sup>b,e,i,l</sup>
Invasive	10	9 ± 2 <sup>b,e,i,k,l</sup>	27 ± 5 <sup>e,i,l</sup>	65 ± 5 <sup>b,e,i,l</sup>	5.24 ± 0.45 <sup>b,e,i,j,l</sup>

<sup>a</sup>Mean ± SD.

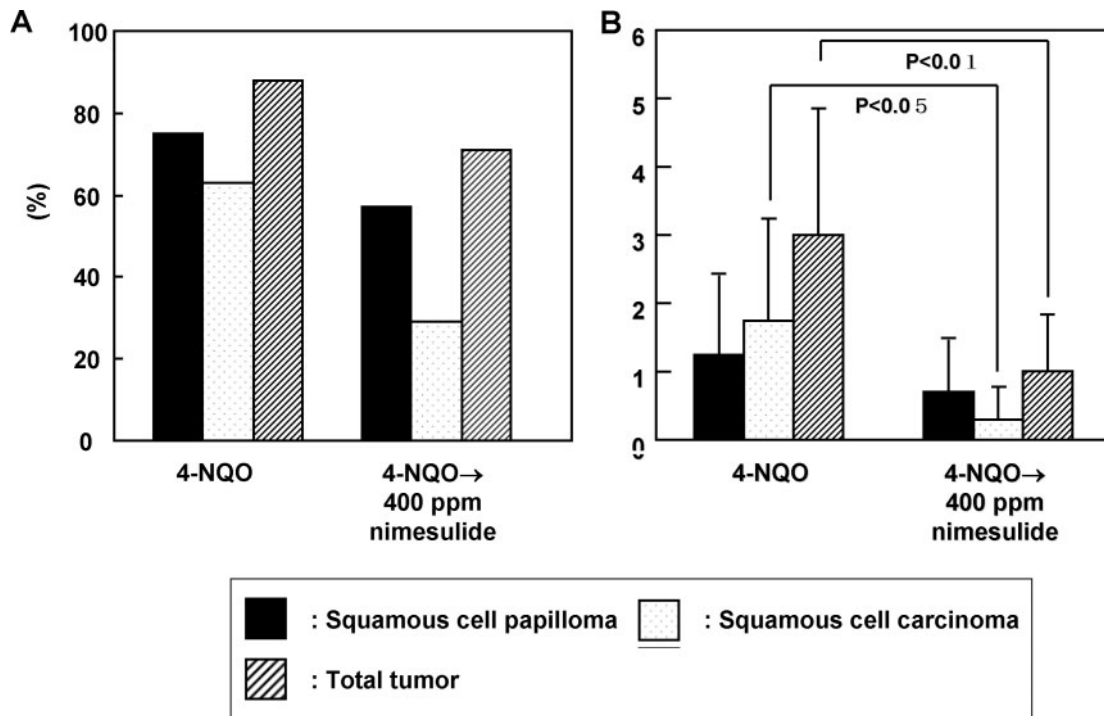
<sup>b-d</sup>Significantly different from 'normal appearing-epithelium' (<sup>b</sup>*P* < 0.001, <sup>c</sup>*P* < 0.005 and <sup>d</sup>*P* < 0.001).

<sup>e-g</sup>Significantly different from 'mild dysplasia' (<sup>e</sup>*P* < 0.001, <sup>f</sup>*P* < 0.001 and <sup>g</sup>*P* < 0.01).

<sup>h-l</sup>Significantly different from 'moderate dysplasia' (<sup>h</sup>*P* < 0.005 and <sup>i</sup>*P* < 0.01).

<sup>j,k</sup>Significantly different from 'severe dysplasia' (<sup>j</sup>*P* < 0.05 and <sup>k</sup>*P* < 0.01).

<sup>l</sup>Significantly different from 'papilloma' (*P* < 0.001).

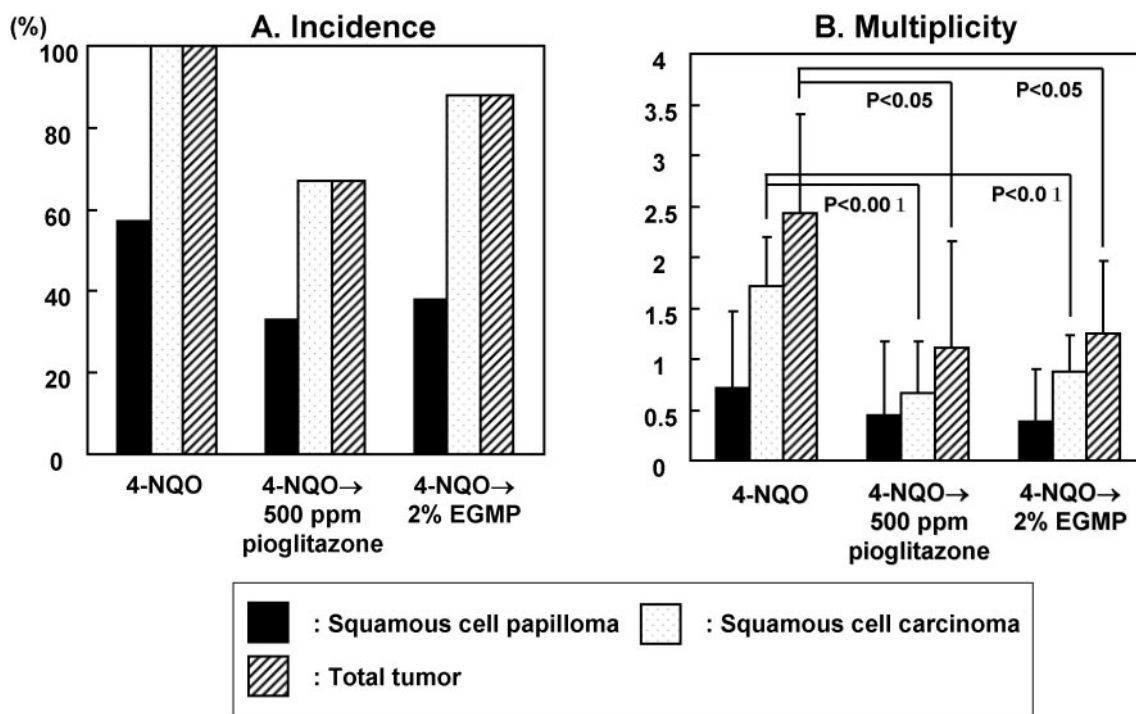


**Fig. 6.** The effect of dietary nimesulide (400 p.p.m.) on tongue neoplasms in male Tg rat. (A) Incidence (%) of tongue carcinomas and (B) multiplicity (no. of carcinoma/rat) of tongue carcinoma. Treatment with nimesulide reduced the incidence and multiplicity of tongue tumors. The inhibition in the multiplicities of carcinoma and total tumor (papilloma + carcinoma) was significant (*P* < 0.05 for carcinoma and *P* < 0.01 for total tumor).

either switch to an autocrine production of mitogenic factors or acquire activating mutations within the components of the signal transduction pathways that mediate mitogenic signaling. An example of this is the activating mutations of the small

GTPase *Ras* (41). The uncontrolled proliferation of malignant neoplastic cells is also frequently achieved by the direct deregulation of cell cycle control. Mitogenic signaling ultimately leads to the upregulated expression of cyclins that





**Fig. 7.** The effect of dietary feeding with pioglitazone (500 p.p.m.) and EGMP (2%) on tongue neoplasms in female Tg rats. (A) The incidence (%) of tongue carcinomas and (B) multiplicity (number of carcinoma/rat) of tongue carcinoma. Treatment with pioglitazone or EGMP reduced the incidence and multiplicity of the tongue tumors. The inhibition in the multiplicities of carcinoma and total tumor (papilloma + carcinoma) was significant (pioglitazone,  $P < 0.001$  for carcinoma and  $P < 0.05$  for total tumor; and EGMP,  $P < 0.01$  for carcinoma and  $P < 0.05$  for total tumor).

together with their catalytic partners, cyclin-dependent kinases (CDKs), hyperphosphorylate the products of the retinoblastoma tumor suppressor gene family.

Cyclin D1 plays an important role in the transition from the  $G_1$  to the S phase of the cell cycle, and perturbations in this control point can lead to neoplastic transformation (42). In fact, cyclin D1 is frequently overexpressed in both human (43) and rat oral tumors (28,29), and it is thought to be an important factor in their development. In this study, we immunohistochemically determined the cyclin D1 expression in sections from tongue lesions induced by 4-NQO in Tg or non-Tg rats and observed a few of cyclin D1-positive cells in the 'normal' appearing basal layer in the tongues of Tg rats after 4-NQO treatment. However, cyclin D1 staining was observed in dysplastic and neoplastic lesions with high expression levels (overexpression) in cancer cells. In contrast, papilloma cells showed a weaker expression of cyclin D1 than did dysplastic and cancer cells. This is in good agreement with our previous findings that were based on male F344 rats treated with 4-NQO (28,29). As a result, an overexpression of cyclin D1 is common in the early lesions that ultimately form malignant oral cancers but not in those that form benign tumors (44). Interestingly, the *ras* oncogene can induce the expression of cyclin D (45,46).

GST-P is a useful biomarker for detecting preneoplastic lesions in rat hepatocarcinogenesis (47). In oral carcinogenesis, an alteration in the immunohistochemical expression of GST-P was also reported in the hamster buccal pouch (48) and rat tongue (49), and this expression became stronger with tumor progression. Our findings on GST-P expression in tongue dysplasia and neoplasms are in accordance with these reports. As found in human oral lesions (dysplasia and neoplasms) that are positive for human placental form of GST

(GST- $\pi$ ) (49), nuclear/cytoplasmic staining was more frequently noted in severe dysplasia and carcinoma than in papilloma and mild/moderate dysplasia in the present study. This biological marker, thus, can be applied to the early detection of preneoplastic tongue lesions (dysplasia) in humans.

Recently, much attention has been paid to the role of COX-2 in carcinogenesis (50). COX-2 can influence several processes important to cancer development. The inducibility of COX-2 is partly explained by the presence of numerous *cis*-acting elements in the 5'-flanking region of the *COX*-gene (51). COX-2 is generally not found in the normal epithelium but increases in response to mitogens, pro-inflammatory cytokines and growth factors, and it has also been linked to carcinogenesis (52). In the current study, we found the immunohistochemical COX-2 expression to be upregulated in premalignant and malignant lesions, as given by their aberrant DNA content. In addition, a specific COX-2 inhibitor nimesulide in the diet could inhibit 4-NQO-induced tongue carcinogenesis, as shown in this study with Tg rats and in our previous experiment with F344 rats (31). These findings may indicate that an upregulation of COX-2 is related to the development of oral carcinomas (28,29,31,53).

Nitric oxide (NO) plays an important role in both carcinogenesis and tumor progression (50,54–56). NO could stimulate tumor growth and metastasis by promoting the migratory, invasive and angiogenic abilities of tumor cells, which may also be triggered by the activation of COX-2 (57). In fact, a significantly higher expression level of iNOS was found in both the human oral SCC (58) and rat tongue cancer induced by 4-NQO (31,34). As a result, iNOS generating NO in oral cancer progression might be able to play an important role in oral cancer progression. Our data on iNOS immunohistochemistry in this study may suggest a

positive correlation between the positive expression of iNOS and disease progression.

$\beta$ -Catenin functions as a transcriptional activator of the Wnt signaling pathway in embryonic and tumor development (54). In several types of human cancer, mutations in the  $\beta$ -catenin or APC gene cause an accelerated tumor cell proliferation and tumor progression through the transcriptional activation of such target genes as *cyclin D1* (59), with the resulting cytoplasmic/nuclear accumulation of  $\beta$ -catenin (60). In the current study, the immunohistochemical  $\beta$ -catenin expression in the non-lesional tongue epithelium was strictly confined to the cell membranes but not nuclei. Whereas some carcinoma cells preserved a weak membranous expression, the membranous expression of  $\beta$ -catenin decreased while the cytoplasmic/nuclear expression increased in line with the disease progression, and carcinoma cells at the invasion front showed a cytoplasmic/nuclear pattern of  $\beta$ -catenin. We did not perform a gene mutation analysis in the current study, but no mutations of  $\beta$ -catenin gene were observed in the rat tongue carcinomas induced by 4-NQO (32). These findings are in line with those reported in human oral cancers (43). As a result, it may, thus, be possible that molecular events other than mutations in  $\beta$ -catenin and APC are responsible for the activation of the Wnt/ $\beta$ -catenin signaling pathway and the cytoplasmic/nuclear expression of  $\beta$ -catenin in tongue carcinogenesis.

Oral lesions with an aberrant DNA content represent an increased risk of cancer (44,61). The value of the DNA content is useful as an early biomarker of oral cancer (61). In this study, the histological grading of 4-NQO-induced tongue lesions correlated to DNA ploidy. The quantification of the histological evaluation of tissue architecture may show a certain correlation among the degree of dysplasia, COX-2 expression and DNA ploidy (62,63). In the current study, the COX-2 expression was upregulated in DNA aneuploid tongue dysplastic and neoplastic lesions. In contrast, non-lesional 'normal' appearing tongue epithelium specimens that showed a weak COX-2 expression in the basal layer had a diploid DNA content. These findings may indicate that COX-2 is upregulated during malignant transition of the tongue epithelium, and this could be in some manner related to the development of genomic instability (64,65).

Oral cancer is a disfiguring disease that continues to increase in incidence, particularly in the young, and to an extent that cannot be fully explained by an increased exposure to the known risk factors. For such malignancies, a chemopreventive approach to oral cancer most likely should encompass a combination of chemicals targeting the metabolic pathways relevant to oral carcinogenesis. Candidate chemicals include retinoids, selective inhibitors of COX-2 and ligands of PPARs, some of which have been tested for their efficacy by our research group. Although the efficiency of any chemical for chemopreventive use should be assessed through a prospective randomized trial and then evaluated only by a definitive end-point for the prevention of cancer, our Tg rat model using intermediate biomarkers (expression of GST-P, cyclin D1, COX-2, iNOS and  $\beta$ -catenin in tongue lesions and white patches) was, thus, found to be effective for a preclinical evaluation of candidate chemopreventive agents against oral cancer development within a short-term period of time.

In conclusion, we established an animal model of oral SCC using Tg rats and the carcinogen 4-NQO. In the model, we observed dysplasia and tumors on the tongues of transgenic rats after treatment with 4-NQO in drinking water, however,

the incidence and multiplicity were greater in Tg rats than in non-Tg rats, and the onset of carcinogenesis was earlier in Tg rats. In addition, a series of pathological and immunohistochemical studies revealed that tongue squamous cell dysplasia, papilloma, carcinoma *in situ* and invasive carcinoma occurred in Tg rats. Five biomarkers (cyclin D1, GST-P, COX-2, iNOS and  $\beta$ -catenin) were expressed in these tongue squamous cell lesions and their expression increased with the disease progression. The changes of these markers were correlated with those of DNA ploidy patterns. Finally, we found that three reported cancer chemopreventive agents could inhibit the carcinogenesis in the Tg rat tongue caused by the treatment of 4-NQO. Taken together, we concluded that this Tg rat model could thus be used in the analysis and the chemoprevention/treatment of oral carcinogenesis.

## Acknowledgements

This work was supported in part by a Grant-in-Aid for Cancer Research, for the Third-Term Comprehensive 10-Year Strategy for Cancer Control from the Ministry of Health, Labour and Welfare of Japan; a Grant-in-Aid (no. 15.2052) for Scientific Research from the Ministry of Education, Culture, Science and Technology of Japan; a grant (H2005-6) for the Project Research from the High-Technology Center of Kanazawa Medical University and a grant from the Japan Food Chemical Research Foundation.

*Conflict of Interest Statement:* None declared.

## References

1. Stewart,B.W. and Kleihues,P. (eds) (2003) *World Cancer Report*. IARC, Lyon.
2. Patel,V., Leethanakul,C. and Gutkind,J.S. (2001) New approaches to the understanding of the molecular basis of oral cancer. *Crit. Rev. Oral Biol. Med.*, **12**, 55–63.
3. Davis,S. and Severson,R.K. (1987) Increasing incidence of cancer of the tongue in the United States among young adults. *Lancet*, **2**, 910–911.
4. Macfarlane,G.J., Boyle,P., Evstifeeva,T.V., Robertson,C. and Scully,C. (1994) Rising trends of oral cancer mortality among males worldwide: the return of an old public health problem. *Cancer Causes Control*, **5**, 259–265.
5. Mackenzie,J., Ah-See,K., Thakker,N., Sloan,P., Maran,A.G., Birch,J. and Macfarlane,G.J. (2000) Increasing incidence of oral cancer amongst young persons: what is the aetiology? *Oral Oncol.*, **36**, 387–389.
6. Day,G.L. and Blot,W.J. (1992) Second primary tumors in patients with oral cancer. *Cancer*, **70**, 14–19.
7. Slaughter,D.P., Southwick,H.W. and Smejkal,W. (1953) 'Field cancerization' in oral stratified squamous epithelium: clinical implications of multicentric origin. *Cancer*, **6**, 963–968.
8. Tanaka,T. (1995) Chemoprevention of oral carcinogenesis. *Eur. J. Cancer B Oral Oncol.*, **31B**, 3–15.
9. Lippman,S.M. and Hong,W.K. (2002) Cancer prevention science and practice. *Cancer Res.*, **62**, 5119–5125.
10. Kim,E.S., Hong,W.K. and Khuri,F.R. (2002) Chemoprevention of aerodigestive tract cancers. *Annu. Rev. Med.*, **53**, 223–243.
11. Gimenez-Conti,I.B. and Slaga,T.J. (1992) The hamster cheek pouch model of carcinogenesis and chemoprevention. *Adv. Exp. Med. Biol.*, **320**, 63–67.
12. Gimenez-Conti,I.B. and Slaga,T.J. (1993) The hamster cheek pouch carcinogenesis model. *J. Cell. Biochem. Suppl.*, **17F**, 83–90.
13. Tanaka,T., Kojima,T., Okumura,A., Yoshimi,N. and Mori,H. (1991) Alterations of the nucleolar organizer regions during 4-nitroquinoline 1-oxide-induced tongue carcinogenesis in rats. *Carcinogenesis*, **12**, 329–333.
14. Tang,X.H., Knudsen,B., Bemis,D., Tickoo,S. and Gudas,L.J. (2004) Oral cavity and esophageal carcinogenesis modeled in carcinogen-treated mice. *Clin. Cancer Res.*, **10**, 301–313.
15. Paterson,I.C., Eveson,J.W. and Prime,S.S. (1996) Molecular changes in oral cancer may reflect aetiology and ethnic origin. *Eur. J. Cancer B Oral Oncol.*, **32B**, 150–153.
16. Harris,C.C. (1996) p53 tumor suppressor gene: at the crossroads of molecular carcinogenesis, molecular epidemiology, and cancer risk assessment. *Environ. Health Perspect.*, **104**(suppl.), 435–439.

17. Frijhoff, A.F., Conti, C.J. and Senderowicz, A.M. (2004) Advances in molecular carcinogenesis: current and future use of mouse models to screen and validate molecularly targeted anticancer drugs. *Mol. Carcinog.*, **39**, 183–194.
18. Bos, J.L. (1989) Ras oncogenes in human cancer: a review. *Cancer Res.*, **49**, 4682–4689.
19. Das, N., Majumder, J. and DasGupta, U.B. (2000) Ras gene mutations in oral cancer in eastern India. *Oral Oncol.*, **36**, 76–80.
20. Yuan, B., Heniford, B.W., Ackermann, D.M., Hawkins, B.L. and Hendler, F.J. (1994) Harvey ras (H-ras) point mutations are induced by 4-nitroquinoline-1-oxide in murine oral squamous epithelia, while squamous cell carcinomas and loss of heterozygosity occur without additional exposure. *Cancer Res.*, **54**, 5310–5317.
21. Caulin, C., Nguyen, T., Longley, M.A., Zhou, Z., Wang, X.J. and Roop, D.R. (2004) Inducible activation of oncogenic K-ras results in tumor formation in the oral cavity. *Cancer Res.*, **64**, 5054–5058.
22. Suzui, M., Yoshimi, N., Tanaka, T. and Mori, H. (1995) Infrequent Ha-ras mutations and absence of Ki-ras, N-ras, and p53 mutations in 4-nitroquinoline 1-oxide-induced rat oral lesions. *Mol. Carcinog.*, **14**, 294–298.
23. Resor, L., Bowen, T.J. and Wynshaw-Boris, A. (2001) Unraveling human cancer in the mouse: recent refinements to modeling and analysis. *Hum. Mol. Genet.*, **10**, 669–675.
24. Klatt, P. and Serrano, M. (2003) Engineering cancer resistance in mice. *Carcinogenesis*, **24**, 817–826.
25. Herzog, M. and Christofori, G. (2002) Recent advances in cancer research: mouse models of tumorigenesis. *Biochim. Biophys. Acta*, **1602**, 97–113.
26. Green, J.E. and Hudson, T. (2005) The promise of genetically engineered mice for cancer prevention studies. *Nat. Rev. Cancer*, **5**, 184–198.
27. Tsuda, H., Fukamachi, K., Ohshima, Y., Ueda, S., Matsuoka, Y., Hamaguchi, T., Ohnishi, T., Takasuka, N. and Naito, A. (2005) High susceptibility of human c-Ha-ras proto-oncogene transgenic rats to carcinogenesis: A cancer-prone animal model. *Cancer Sci.*, **96**, 309–316.
28. Yoshida, K., Tanaka, T., Hirose, Y., Yamaguchi, F., Kohno, H., Toida, M., Hara, A., Sugie, S., Shibata, T. and Mori, H. (2005) Dietary garcinol inhibits 4-nitroquinoline 1-oxide-induced tongue carcinogenesis in rats. *Cancer Lett.*, **221**, 29–39.
29. Yoshida, K., Hirose, Y., Tanaka, T. et al. (2003) Inhibitory effects of troglitazone, a peroxisome proliferator-activated receptor gamma ligand, in rat tongue carcinogenesis initiated with 4-nitroquinoline 1-oxide. *Cancer Sci.*, **94**, 365–371.
30. Iida, K., Yamamoto, M., Kato, M., Yoshida, K., Kurita, K. and Tatematsu, M. (1999) Strong expression of glutathione S-transferase placental form in early preneoplastic lesions and decrease with progression in hamster buccal pouch carcinogenesis. *Cancer Lett.*, **135**, 129–136.
31. Yoshida, K., Tanaka, T., Kohno, H., Sakata, K., Kawamori, T., Mori, H. and Wakabayashi, K. (2003) A COX-2 inhibitor, nimesulide, inhibits chemically-induced rat tongue carcinogenesis through suppression of cell proliferation activity and COX-2 and iNOS expression. *Histol. Histopathol.*, **18**, 39–48.
32. Suzui, M., Sugie, S., Mori, H., Okuno, M., Tanaka, T. and Moriwaki, H. (2001) Different mutation status of the beta-catenin gene in carcinogen-induced colon, brain, and oral tumors in rats. *Mol. Carcinog.*, **32**, 206–212.
33. Tanaka, T., Kohno, H., Yoshitani, S., Takashima, S., Okumura, A., Murakami, A. and Hosokawa, M. (2001) Ligands for peroxisome proliferator-activated receptors alpha and gamma inhibit chemically induced colitis and formation of aberrant crypt foci in rats. *Cancer Res.*, **61**, 2424–2428.
34. Tanaka, T., Kohno, H., Nomura, E., Taniguchi, H., Tsuno, T. and Tsuda, H. (2003) A novel geranylated derivative, ethyl 3-(4'-geranyloxy-3'-methoxyphenyl)-2-propenoate, synthesized from ferulic acid suppresses carcinogenesis and inducible nitric oxide synthase in rat tongue. *Oncology*, **64**, 166–175.
35. Asamoto, M., Toriyama-Baba, H., Ohnishi, T., Naito, A., Ota, T., Ando, A., Ochiya, T. and Tsuda, H. (2002) Transgenic rats carrying human c-Ha-ras proto-oncogene are highly susceptible to N-nitrosomethylbenzylamine induction of esophageal tumorigenesis. *Jpn. J. Cancer Res.*, **93**, 744–751.
36. Banoczy, J. and Csiba, A. (1976) Occurrence of epithelial dysplasia in oral leukoplakia. Analysis and follow-up study of 12 cases. *Oral Surg. Oral Med. Oral Pathol.*, **42**, 766–774.
37. Kramer, I.R., Lucas, R.B., Pindborg, J.J. and Sobin, L.H. (1978) Definition of leukoplakia and related lesions: an aid to studies on oral precancer. *Oral Surg. Oral Med. Oral Pathol.*, **46**, 518–539.
38. Tanaka, T. (1986) Proliferative activity in dysplasia, carcinoma in situ and microinvasive carcinoma of the uterine cervix. *Pathol. Res. Pract.*, **181**, 531–539.
39. Tanaka, T., Mori, H., Takahashi, M. and Williams, G.M. (1984) DNA content of hyperplastic and neoplastic acinar cell lesions in rat and human pancreas. *J. Exp. Pathol.*, **1**, 315–326.
40. Mori, H., Tanaka, T., Sugie, S., Takahashi, M. and Williams, G.M. (1982) DNA content of liver cell nuclei of N-2-fluorenylacetylamide-induced altered foci and neoplasms in rats and human hyperplastic foci. *J. Natl Cancer Inst.*, **69**, 1277–1282.
41. Hanahan, D. and Weinberg, R.A. (2000) The hallmarks of cancer. *Cell*, **100**, 57–70.
42. Hunter, T. and Pines, J. (1994) Cyclins and cancer. II: Cyclin D and CDK inhibitors come of age. *Cell*, **79**, 573–582.
43. Odajima, T., Sasaki, Y., Tanaka, N., Kato-Mori, Y., Asanuma, H., Ikeda, T., Satoh, M., Hiratsuka, H., Tokino, T. and Sawada, N. (2005) Abnormal beta-catenin expression in oral cancer with no gene mutation: correlation with expression of cyclin D1 and epidermal growth factor receptor, Ki-67 labeling index, and clinicopathological features. *Virchows Arch.*, **36**, 234–241.
44. Lippman, S.M., Sudbo, J. and Hong, W.K. (2005) Oral cancer prevention and the evolution of molecular-targeted drug development. *J. Clin. Oncol.*, **23**, 346–356.
45. Filmus, J., Robles, A.I., Shi, W., Wong, M.J., Colombo, L.L. and Conti, C.J. (1994) Induction of cyclin D1 overexpression by activated ras. *Oncogene*, **9**, 3627–3633.
46. Aktas, H., Cai, H. and Cooper, G.M. (1997) Ras links growth factor signaling to the cell cycle machinery via regulation of cyclin D1 and the Cdk inhibitor p27KIP1. *Mol. Cell Biol.*, **17**, 3850–3857.
47. Tsuda, H., Fukushima, S., Wanibuchi, H., Morimura, K., Nakae, D., Imaida, K., Tatematsu, M., Hirose, M., Wakabayashi, K. and Moore, M.A. (2003) Value of GST-P positive preneoplastic hepatic foci in dose-response studies of hepatocarcinogenesis: evidence for practical thresholds with both genotoxic and nongenotoxic carcinogens. A review of recent work. *Toxicol. Pathol.*, **31**, 80–86.
48. Chen, Y.K. and Lin, L.M. (1996) Sequential expression of placental glutathione S-transferase (GST-P) during DMBA-induced hamster buccal pouch squamous cell carcinogenesis. *J. Oral Pathol. Med.*, **25**, 388–394.
49. Li, T., Hirayama, Y. and Kitano, M. (1997) Glutathione S-transferase pi-class as a tumour marker in lingual preneoplastic and neoplastic lesions of rats and humans. *Virchows Arch.*, **431**, 37–43.
50. Watanabe, K., Kawamori, T., Nakatsugi, S. and Wakabayashi, K. (2000) COX-2 and iNOS, good targets for chemoprevention of colon cancer. *Biofactors*, **12**, 129–133.
51. Inoue, H., Yokoyama, C., Hara, S., Tone, Y. and Tanabe, T. (1995) Transcriptional regulation of human prostaglandin-endoperoxide synthase-2 gene by lipopolysaccharide and phorbol ester in vascular endothelial cells. Involvement of both nuclear factor for interleukin-6 expression site and cAMP response element. *J. Biol. Chem.*, **270**, 24965–24971.
52. Dubois, R.N., Abramson, S.B., Crofford, L., Gupta, R.A., Simon, L.S., Van De Putte, L.B. and Lipsky, P.E. (1998) Cyclooxygenase in biology and disease. *FASEB J.*, **12**, 1063–1073.
53. Chan, G., Boyle, J.O., Yang, E.K. et al. (1999) Cyclooxygenase-2 expression is up-regulated in squamous cell carcinoma of the head and neck. *Cancer Res.*, **59**, 991–994.
54. Takahashi, M. and Wakabayashi, K. (2004) Gene mutations and altered gene expression in azoxymethane-induced colon carcinogenesis in rodents. *Cancer Sci.*, **95**, 475–480.
55. Rao, C.V. (2004) Nitric oxide signaling in colon cancer chemoprevention. *Mutat. Res.*, **555**, 107–119.
56. Reddy, B.S. (2004) Studies with the azoxymethane-rat preclinical model for assessing colon tumor development and chemoprevention. *Environ. Mol. Mutagen.*, **44**, 26–35.
57. Lala, P.K. and Chakraborty, C. (2001) Role of nitric oxide in carcinogenesis and tumour progression. *Lancet Oncol.*, **2**, 149–156.
58. Chen, Y.K., Hsue, S.S. and Lin, L.M. (2002) Increased expression of inducible nitric oxide synthase for human buccal squamous-cell carcinomas: immunohistochemical, reverse transcription-polymerase chain reaction (RT-PCR) and *in situ* RT-PCR studies. *Head Neck*, **24**, 925–932.
59. Tetsu, O. and McCormick, F. (1999)  $\beta$ -Catenin regulates expression of cyclin D1 in colon carcinoma cells. *Nature*, **398**, 422–426.
60. Morin, P.J., Sparks, A.B., Korinek, V., Barker, N., Clevers, H., Vogelstein, B. and Kinzler, K.W. (1997) Activation of  $\beta$ -catenin-Tcf signaling in colon cancer by mutations in  $\beta$ -catenin or APC. *Science*, **275**, 1787–1790.
61. Sudbo, J., Kildal, W., Risberg, B., Koppang, H.S., Danielsen, H.E. and Reith, A. (2001) DNA content as a prognostic marker in patients with oral leukoplakia. *N. Engl. J. Med.*, **344**, 1270–1278.

62. Sudbo, J., Bankfalvi, A., Bryne, M., Marcelpoil, R., Boysen, M., Piffko, J., Hemmer, J., Kraft, K. and Reith, A. (2000) Prognostic value of graph theory-based tissue architecture analysis in carcinomas of the tongue. *Lab. Invest.*, **80**, 1881–1889.
63. Sudbo, J., Ristimaki, A., Sondresen, J.E., Kildal, W., Boysen, M., Koppang, H.S., Reith, A., Risberg, B., Nesland, J.M. and Bryne, M. (2003) Cyclooxygenase-2 (COX-2) expression in high-risk premalignant oral lesions. *Oral Oncol.*, **39**, 497–505.
64. Wang, D., Mann, J.R. and DuBois, R.N. (2004) WNT and cyclooxygenase-2 cross-talk accelerates adenoma growth. *Cell Cycle*, **3**, 1512–1515.
65. Han, S. and Roman, J. (2004) Suppression of prostaglandin E2 receptor subtype EP2 by PPAR $\gamma$  ligands inhibits human lung carcinoma cell growth. *Biochem. Biophys. Res. Commun.*, **314**, 1093–1099.

*Received July 4, 2005; revised September 11, 2005;  
accepted September 30, 2005*