Online May 31, 2017
Journal of Neuroendovascular Therapy 2017; 11: 492–495 DOI: 10.5797/jnet.tn.2016-0102

Technical Note

Usefulness of Flat Detector CT Perfusion Images in the Diagnosis and Determination of the Therapeutic Strategy for Intracranial Vascular Occlusion as a Complication of Cerebral Angiography: Technical Note

Keiichiro Maeda, Haruo Goto, Yasuhiro Takeda, Yoshiaki Goto, and Shiko Shimada

Objective: Flat detector CT perfusion (FD-CTP) imaging is a new modality that permits rapid assessment of the state of perfusion in the angiography suite. We present a case in which FD-CTP was useful for the determination of the therapeutic strategy for embolism that occurred during angiography.

Case Presentation: Cerebral angiography performed before surgery for brain tumor suggested left posterior cerebral artery occlusion. Since the judgment of whether it was chronic occlusion or embolism that occurred during the examination was difficult, FD-CTP was performed. As hypoperfused area was observed in the left occipital lobe without previously known infarction, the lesion was judged not to be chronic occlusion but to possibly cause cerebral infarction without treatment. We immediately performed thrombectomy and prevented its development into cerebral infarction.

Conclusion: FD-CTP was useful for the diagnosis and determination of the therapeutic strategy for intracranial vascular occlusion as a complication of cerebral angiography because it can be promptly performed in the angiography suite.

Keywords ▶ angiography, flat panel, CT perfusion, cerebral blood volume

Introduction

Recently, perfusion study using a flat panel type cerebral angiographic system has become possible, and there have been reports of the use of the technique for the assessment of the state of perfusion in thrombectomy for acute cerebral infarction, etc., by taking advantage of the possibility of promptly performing the examination in the angiography suite without transferring the patient.[1–4] We could accurately evaluate the condition of a patient who developed embolism during cerebral angiography before surgery for brain tumor by performing flat detector CT perfusion (FD-CTP) study and prevent cerebral angiography by thrombectomy. This case is presented as it first demonstrated the usefulness of FD-CTP for troubleshooting during cerebral angiography.

Department of Neurosurgery, Aidu Chuo Hospital, Aiduwakamatsu, Fukushima, Japan

Received: November 9, 2016; Accepted: May 1, 2017
Corresponding author: Keiichiro Maeda. Department of Neurosurgery, Aidu Chuo Hospital, 1-1 Tsuruga-machi, Aiduwakamatsu, Fukushima 965-8611, Japan
Email: maeda@onchikai.jp

Case Presentation

The patient was a 64-year-old male with disturbance of consciousness as a principal symptom. Despite a history of surgery for brain tumor at the age of 13 years, he had no particular event in the subsequent developmental history. At the age of 57 years, working became difficult due to impairment of the cognitive function, and he lived under care at home. He was admitted to a care facility at the age of 64 years, but he gradually exhibited a tendency of lethargy and consulted our department. Since head MRI revealed a tumor in the left temporal lobe, he was admitted for surgical treatment and underwent cerebral angiography as a preoperative examination.

Neurological examination on admission showed an E3V3M5 level of consciousness on the Glasgow Coma Scale and had no gross motor paralysis.

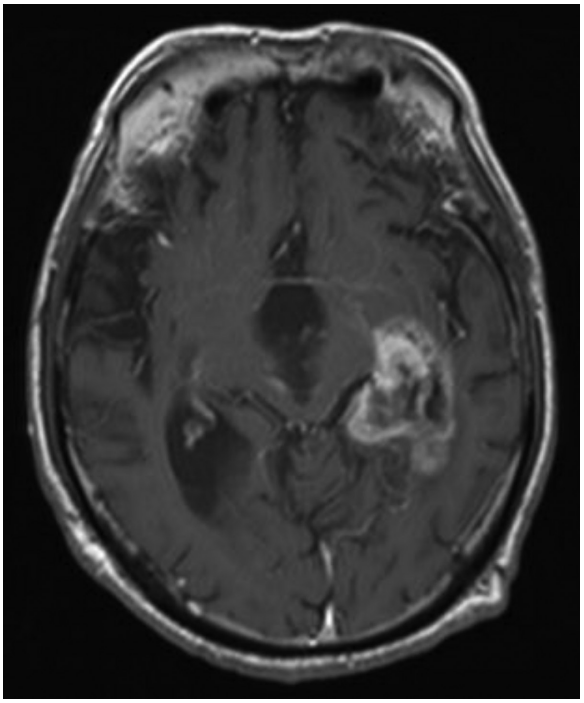

Fig. 1 Magnetic resonance (MR) imaging showing a tumor in the left temporal lobe.

Concerning imaging examinations, contrast-enhanced MRI of the head showed a lesion extending from the left temporal lobe to the left lateral ventricle on T_1-weighted imaging with partial contrast enhancement of the ventricular wall (**Fig. 1**). On T_2-weighted, FLAIR, and diffusion-weighted imaging, no abnormality was noted except at the site of the tumor.

Cerebral angiography was performed using a biplane FD angiographic system (Artis Q; Siemens Healthcare, Forchheim, Germany), and four-vessel study was performed by puncture of the right groin. When left vertebral artery angiography was initiated following bilateral common carotid artery angiography, occlusion of the P2 segment of the left posterior cerebral artery was detected (**Fig. 2A**). No retrograde filling from other branches of the posterior cerebral artery was also noted in the capillary or venous phase. While we reviewed previous images, the judgment of whether the left P2 occlusion had been noted previously or was new embolism caused by the examination was impossible because angiography, CT angiography, or MR angiography had not been performed. Since MRI on admission showed no old infarction in the left occipital lobe, prompt thrombectomy was considered necessary if the lesion should be treatment-related embolism. Also, if it should be chronic occlusion, an attempt of thrombectomy was considered to involve the risk of scattering the thrombus or vascular perforation.

Therefore, we immediately evaluated the state of perfusion by FD-CTP imaging to judge whether the condition was chronic occlusion or acute occlusion.

First, a 4 Fr pigtail catheter (Pig straight; Technowood, Tokyo, Japan) was placed in the ascending aorta and connected to an injector (Press Duo; Nemoto, Tokyo, Japan). Mask imaging was performed first. When the flat panel returned to the original position, infusion of 15 mL of a contrast agent (Oypalomin 300; Konica Minolta, Tokyo, Japan) and 30 mL of physiologic saline was initiated at a rate of 5 mL/sec via the pigtail catheter, and, from after 9 seconds, the flat panel was rotated over 6 seconds, and imaging was ended after a total of 15 seconds. The imaging conditions were set as follows: acquisition time, 6 seconds; 73 kV, 616 × 480 matrix; 30 × 40 cm flat panel size; 200° total angle; 0.5° per frame; 400 frames total; and 0.36 mGy per frame. Thereafter, images were constituted by processing the data with software (Syngo XWP; Siemens).[5] Briefly, the cerebral blood volume (CBV) was obtained by subtracting the mask images from the contrast-enhanced images and converting the 3D voxel data into the blood volume by the software.

Since a marked decrease in the CBV was observed in the left occipital lobe, the occlusion of the left posterior cerebral artery was judged to be caused by the present examination procedure (**Fig. 2B**). Thrombectomy was decided to be performed, the 4 Fr sheath in the right groin was replaced with a 6 Fr sheath, and 5000 units of heparin was intravenously administered. A 6 Fr Envoy (Codman, MA, USA) was placed in the left vertebral artery, and a Trevo pro 14 (Stryker, Kalamazoo, MI, USA) and a ASAHI CHIKAI 14 (ASAHI Intecc, Aichi, Japan) were guided, crossing the lesion. Using a 3 × 20 mm Trevo XP, ProVue stent (Stryker), the thrombus could be retrieved by a single pass. The occluded left posterior cerebral artery was recanalized, and repeated FD-CTP study showed an improvement in the CBV of the left occipital lobe (**Fig. 3**). No tumor invasion was observed in the wall of the left posterior cerebral artery, and the present occlusion was judged to be related to the angiographic procedure. No infarction was observed in the left occipital lobe on MRI performed on the day after the procedure (**Fig. 4**).

Discussion

The FD angiographic system has begun to be used widely, and not only high-resolution angiographic images, but also CT images of the brain parenchyma can be obtained by rotating the flat panel. Moreover, it has become possible to obtain CBV images using a commercially based angiographic

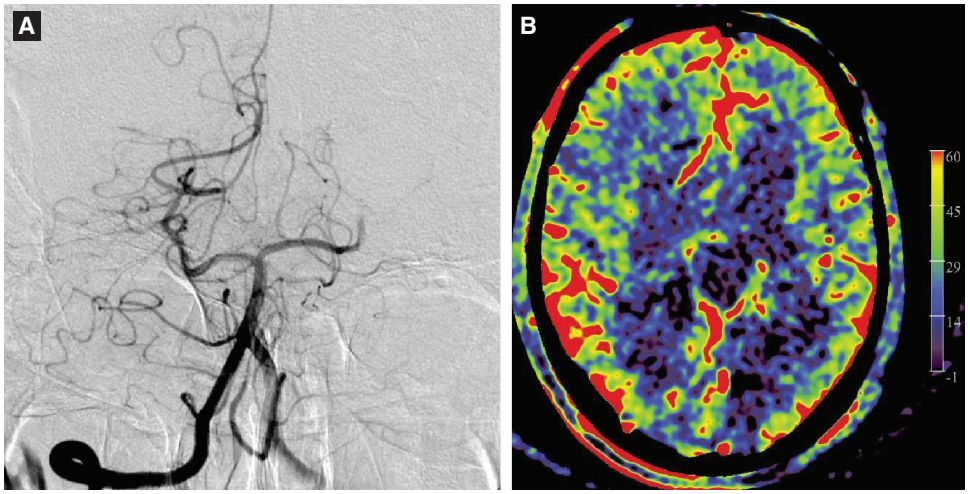

Fig. 2 (**A**) A right vertebral angiogram demonstrating occlusion of the left posterior cerebral artery. (**B**) An image of flat detector CT perfusion revealing decrease in cerebral blood volume in the left occipital lobe.

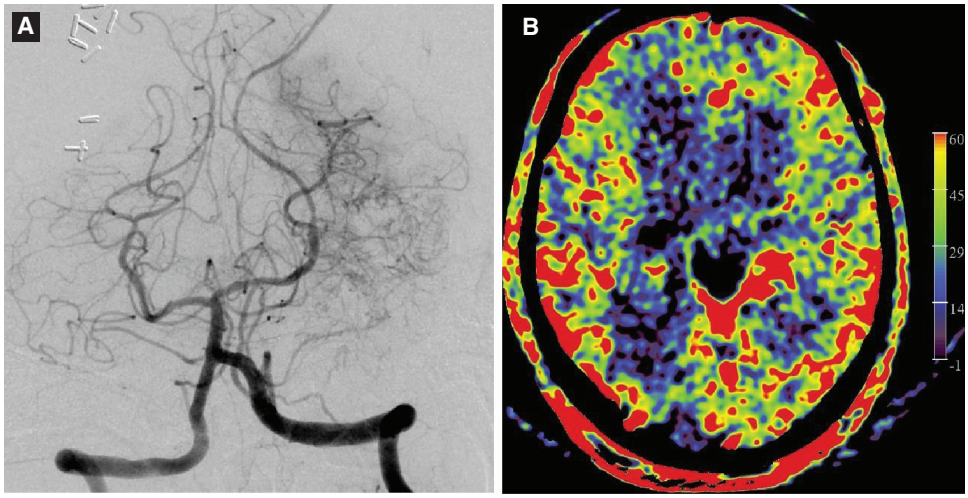

Fig. 3 (**A**) A right vertebral angiogram after the treatment demonstrating recanalization of the left posterior cerebral artery. (**B**) An image of flat detector CT perfusion after the treatment revealing normalization of cerebral blood volume in the left occipital lobe.

system by injecting a diluted contrast agent via the ascending aorta.[1,4] FD-CTP imaging is not inferior in detection sensitivity for hypoperfused areas in actual patients with cerebral ischemia compared with the CBV determined using conventional multi-slice CT,[1] and the sizes of the hypoperfused areas judged by the two methods have been reported to be closely correlated.[4,6]

Struffert et al. reported that areas in which the CBV did not recover after acute phase revascularization eventually lapsed into cerebral infarction by a study of 16 patients with acute cerebral infarction using FD-CTP imaging.[3] In the patient presented here, cerebral infarction is considered to have been prevented as the markedly reduced CBV of the left occipital lobe recovered after thrombectomy.

Advantages of obtaining cerebral perfusion data in the angiography suite are the promptness and simplicity due to the absence of loss of time associated with the transport of the patient, etc. The balloon occlusion test to judge the appropriateness of internal carotid artery occlusion for treating internal carotid artery aneurysms has been reported as a clinical use of FD-CTP imaging exploiting these advantages.[7,8] Similarly, in the treatment of posterior cerebral artery aneurysms, for which occlusion of the parent artery is often performed,[9] FD-CTP imaging may also be useful for the determination of the therapeutic strategy because we could clearly demonstrate a decrease in the CBV due to occlusion of the posterior cerebral artery by this technique.

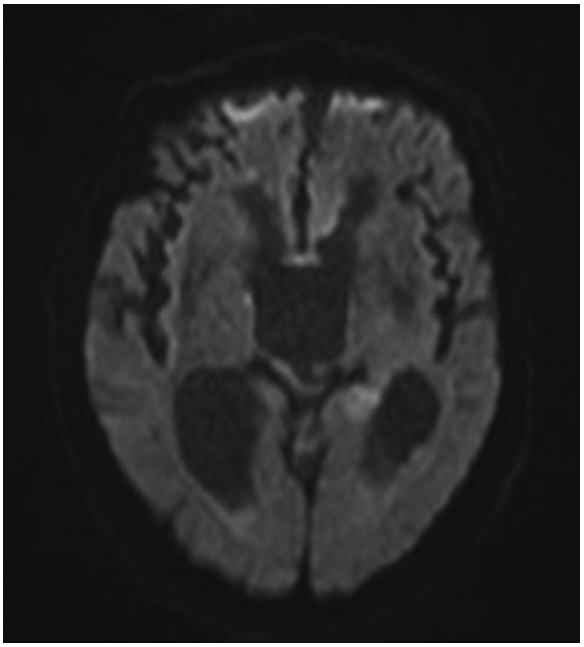

Fig. 4 MRI diffusion-weighted magnetic resonance imaging (DWI) 1 day after the treatment showing no ischemic lesion in the left occipital lobe.

MRI is naturally an option for the evaluation of indications for thrombectomy for vascular occlusion as an intraprocedural complication, but it requires trouble and time for the transport of the patient. There is also a time window in diffusion-weighted magnetic resonance imaging (DWI) until abnormal signals can be detected, and accurate evaluation of the presence or absence and severity of brain ischemia is occasionally difficult. Therefore, these modalities are not expected to be used widely for clinical practice. Usually, the presence or absence of leptomeningeal anastomosis from blood vessels other than the occluded vessel is used as a criterion for the judgment of the necessity of treatment for acute occlusion. In our present patient, we omitted the evaluation of leptomeningeal anastomosis, but a decrease in the CBV due to occlusion of an intracranial vessel could be promptly and objectively evaluated by performing FD-CTP imaging. In addition, FD-CTP was advantageous in that the therapeutic effect after recanalization of an occluded vessel could be immediately checked. Therefore, along with the evaluation of the collateral blood flows by conventional cerebral angiography, FD-CTP imaging may become an extremely useful tool.

Conclusion

We could promptly evaluate embolism that occurred during angiography by FD-CTP imaging and prevent cerebral infarction by thrombectomy. FD-CTP imaging is considered useful for troubleshooting in acute phase thromboembolic occlusion during cerebral angiography.

Disclosure Statement

There are no conflicts of interest to disclose.

References

1) Fiorella D, Turk A, Chaudry I, et al: A prospective, multicenter pilot study investigating the utility of flat detector derived parenchymal blood volume maps to estimate cerebral blood volume in stroke patients. *J Neurointerv Surg* 2014; 6: 451–156.
2) Lin CJ, Yu M, Hung SC, et al: In-room assessment of cerebral blood volume for guidance during intra-arterial thrombolytic therapy. *Interv Neuroradiol* 2012; 18: 463–468.
3) Struffert T, Deuerling-Zheng Y, Engelhorn T, et al: Feasibility of cerebral blood volume mapping by flat panel detector CT in the angiography suite: first experience in patients with acute middle cerebral artery occlusions. *AJNR Am J Neuroradiol* 2012; 33: 618–625.
4) Struffert T, Deuerling-Zheng Y, Kloska S, et al: Dynamic angiography and perfusion imaging using flat detector CT in the angiography suite: A pilot study in patients with acute middle cerebral artery occlusions. *AJNR Am J Neuroradiol* 2015; 36: 1964–1970.
5) Zhang Q, Xu R, Sun Q, et al: Exploring the value of using color-coded quantitative DSA evaluation on bilateral common carotid arteries in predicting the reliability of intra-ascending aorta flat detector CT-CBV maps. *AJNR Am J Neuroradiol* 2015; 36: 960–966.
6) Lin CJ, Guo WY, Chang FC, et al: Using flat-panel perfusion imaging to measure cerebral hemodynamics: A pilot feasibility study in patients with carotid stenosis. *Medicine (Baltimore)* 2016; 95: e3529. doi: 10.1097/MD.0000000000003529.
7) Struffert T, Deuerling-Zheng Y, Engelhorn T, et al: Monitoring of balloon test occlusion of the internal carotid artery by parametric color coding and perfusion imaging within the angio suite: first results. *Clin Neuroradiol* 2013; 23: 285–292.
8) Yang M, Wu J, Ma L, et al: The value of syngo DynaPBV neuro during neuro-interventional hypotensive balloon occlusion test. *Clin Neuroradiol* 2015; 25: 387–395.
9) Wang J, Sun Z, Bao J, et al: Characteristics and endovascular treatment of aneurysms of posterior cerebral artery. *Neurol India* 2011; 59: 6–11.