

Comparison of 1470 nm Radial Fiber Laser Ablation and Radiofrequency Ablation in Endovascular Treatment of Venous Insufficiency

Havva Nur Alparslan Yümün^{1*}, Özcan Gür², Selami Gürkan²

¹Department of General Surgery, Çorlu Devlet Hastanesi, Tekirdag, Turkey

²Department of Cardiovascular Surgery, Namık Kemal University, Tekirdag, Turkey

Email: *nuralparslanyumun@gmail.com

How to cite this paper: Yümün, H.N.A., Gür, Ö. and Gürkan, S. (2016) Comparison of 1470 nm Radial Fiber Laser Ablation and Radiofrequency Ablation in Endovascular Treatment of Venous Insufficiency. *World Journal of Cardiovascular Surgery*, 6, 117-124.

<http://dx.doi.org/10.4236/wjcs.2016.69019>

Received: August 5, 2016

Accepted: September 13, 2016

Published: September 16, 2016

Copyright © 2016 by authors and Scientific Research Publishing Inc.

This work is licensed under the Creative Commons Attribution International License (CC BY 4.0).

<http://creativecommons.org/licenses/by/4.0/>



Open Access

Abstract

Background: In this study, we aimed to compare the results of endovenous laser ablation (EVLA) and radiofrequency ablation (RFA) in patients with lower extremity venous insufficiency due to great saphenous vein (GSV) reflux on efficiency, patient comfort and postoperative morbidity. **Methods:** Endovascular approach in treatment of GSV insufficiency was performed in 283 patients between 2011 and 2014 at our clinic. In group 1, EVLA was performed on 149 patients (42 male, 107 female; mean age 46.90 ± 11.43) and in group 2, RFA was performed on 134 patients (41 male, 93 female; mean age 47.02 ± 12.58). The results were compared in terms of local pain, ecchymosis, paresthesia, venous clinic severity score (VCSS), length of GSV that process performed, efficiency and Clinical Etiology Anatomy Pathophysiology (CEAP) classification data. **Results:** GSV diameter at saphenofemoral junction level was 10.65 ± 3.72 mm and 11.29 ± 3.78 mm in group 1 and 2, respectively. Length of GSV that process performed was 38.97 ± 6.88 cm in group 1 and 41.83 ± 4.82 cm in group 2. Postoperatively burn, pulmonary embolism (PE) and deep venous thrombosis (DVT) were not observed in both groups. Postoperative complications in group 1 were hematoma formation in 2 (1.3%) patients, ecchymosis in 13 (8.7%) patients, edema in 21 (14.1%) patients and paresthesia in 10 (6.7%) patients. Postoperative complications in group 2 were hematoma formation in 1 (0.7%) patient, ecchymosis in 8 (6%) patients, edema in 12 (9%) patients and paresthesia in 6 (4.5%) patients. The efficiency of the process was 96.6% in EVLA group and 98.5% in RFA group. **Conclusion:** We conclude that both RFA and 1470 nm radial fiber EVLA procedures are effective and reliable techniques in treatment of GSV insufficiency. No significant difference was found between two techniques in terms of efficiency and postoperative morbidity.

Keywords

Endovascular, Radiofrequency Laser, Venous Insufficiency

1. Introduction

The incidence of venous disorders in the community is becoming more frequent at the present time [1] [2]. It may reduce the quality of life and cause loss of labor force [3]. In the last decades, treatment of venous insufficiency was directed to endovascular procedures rather than surgical procedures. The most commonly used procedures are radio-frequency ablation (RFA) and endovenous laser ablation (EVLA). Ecchymosis, edema, local pain, deep venous thrombosis, pulmonary embolism, arteriovenous fistula formation and inadequate occlusion of great saphenous vein (GSV) are the possible complications after EVLA and RFA [4]-[6]. In a previous similar study postoperative edema, ecchymosis, hyperemia and mean time to return to work were higher in RF group. Moreover recanalization developed in only RF group [7]. In the second study there was no significant difference among venous clinical severity score, measured adverse effects, and procedure failure rate [8]. In a randomized study RF thermal ablation was significantly superior to EVL as measured by a comprehensive array of postprocedural recovery and quality of life [9].

In this study, we aimed to compare the results of 1470 nm EVLA and RFA in patients with lower extremity venous insufficiency due to GSV reflux on efficiency, patient comfort and postoperative morbidity.

2. Material and Method

Endovascular approach in treatment of GSV reflux was used in 283 patients between 2011 and 2014 at our clinic. Ethical approval was confirmed for the study from the local ethics committee. Patients were randomly divided into two groups according to the procedure performed. In group 1, EVLA (Venocure, Diotech, Pusan, Korea) was performed in 149 patients (42 male, 107 female; mean age 46.90 ± 11.43). In group 2, RFA (ClosureFAST, Covidien, Dublin, Ireland) was performed in 134 patients (41 male, 93 female; mean age 47.02 ± 12.58). All patients were examined preoperatively both clinically and anatomically by Doppler ultrasonography (DUSG). Patients with symptomatic varicose veins and high reflux at GSV by DUSG were included in the study. Patients with a history of lower extremity surgery, lumbar disc hernia and diabetic patients with lower extremity paresthesia were excluded from the study. Patients' clinical data and DUSG data were recorded and summarized in **Table 1**. Postoperatively edema, local pain, paresthesia, venous clinical severity score (VCSS) at 0 day, 10th day, 1st, 3rd and 6th months, return to daily activities and length of GSV that process performed were recorded and compared. The postoperative complications, VCSS follow up and process efficiency results are summarized in **Table 2**.

All procedures were completed in the operating theatre under 0.5 mg/kg midazolam (Dormicum, Roche, Basel, Switzerland) sedation and tumescent anesthesia.

2.1. Endovascular Procedure

A 6F intravascular sheath (Terumo, Tokyo, Japan) was placed under guidance of DUSG (Micromaxx, Sonosite Tech, Washington-USA) by using Seldinger technique into GSV.

Table 1. Preoperative patient data and CEAP classification.

	EVLA (Group 1, n = 149)	RFA (Group 2, n = 134)	P Value
Age	46.90 ± 11.43	47.02 ± 12.58	NS
Sex (Female)	107 (71.8%)	93 (69.4%)	NS
GSV Diameter (mm)	10.65 ± 3.72	11.29 ± 3.78	NS
Reflux Time (sec)	6.42 ± 1.72	6.55 ± 1.54	NS
Ext (Right)	71 (52.3%)	65 (48.5%)	NS
2	37 (27.6%)	53 (35.6%)	NS
3	61 (45.5%)	73 (49%)	NS
CEAP 4	29 (21.6%)	19 (12.8%)	NS
5	4 (3%)	2 (1.3%)	NS
6	3 (2.2%)	2 (1.3%)	NS

EVLA: Endovascular Laser Ablation, **RFA:** Radiofrequency Ablation, **GSV:** Great Saphenous Vein, **Ext:** Extremity, **CEAP:** Clinical Etiology Anatomy Pathophysiology.

Table 2. Complications, VCSS and process efficiency data after endovascular procedures.

	EVLA (Group 1, n = 149)	RFA (Group 2, n = 134)	P Value
Operation Time (min)	19.19 ± 5.44	19.71 ± 6.62	NS
GSV Length(cm)	38.92 ± 6.88	41.83 ± 4.82	<i>P</i> < 0.001
Tumescent (ml)	343.18 ± 61.93	332.72 ± 70.11	NS
Hematoma n (%)	2 (1.3%)	1 (0.7%)	NS
Ecchymosis n (%)	13 (8.7%)	8 (6%)	NS
Edema n (%)	21 (14.1%)	12 (9%)	NS
Paresthesia n (%)	10 (6.7%)	6 (4.5%)	NS
Burn n (%)	0 (0%)	0 (0%)	NS
DVT n (%)	0 (0%)	0 (0%)	NS
PE n (%)	0 (0%)	0 (0%)	NS
Phlebitis n (%)	3 (2%)	2 (1.5%)	NS
Pain n (%)	31 (20.8%)	19 (14.2%)	NS
VCSS			
Preoperative	9.37 ± 0.99	8.91 ± 1.00	<i>P</i> < 0.001
Postoperative 10 th day	4.56 ± 1.24	3.84 ± 1.11	<i>P</i> < 0.001
Postoperative 1 st month	3.73 ± 1.37	3.69 ± 1.24	NS
Postoperative 3 rd month	2.84 ± 1.08	3.03 ± 1.13	NS
Postoperative 6 th month	1.83 ± 0.74	1.81 ± 0.74	NS
RDA	2.10 ± 0.89	1.89 ± 0.89	NS
GSV Occlusion	145 (96.6%)	136 (98.5%)	NS

EVLA: Endovascular Laser Ablation, **RFA:** Radiofrequency Ablation, **GSV:** Great Saphenous Vein, **DVT:** Deep Venous Thrombosis, **PE:** Pulmonary Embolism, **VCSS:** Venous Clinic Severity Score, **RDA:** Return to Daily Activities.

RFA or EVLA catheter was inserted from that sheath just distal to the superficial epigastric vein (SEV) (**Figure 1**). Tumescent anesthesia (250 ml isotonic, 60 ml 1% lidocaine, 1/100,000 epinephrine and 6 ml 8.4% NaHCO₃) was performed through the GSV line by a 20 gauge spinal needle in order to increase the efficiency of the process and reduce tissue injury. After the RFA or EVLA procedure was complete, extremity was wrapped with an elastic bandage. All patients were mobilized at the second hour after the procedure. Enoxaparine sodium at a dosage of 1 mg/kg was injected subcutaneously. All patients were discharged at the same day with medium pressure varicose surgical stocking for venous thromboembolism prophylaxis.

2.2. Statistical Analysis

All statistical calculations were performed using the SPSS version 20.0 software (SPSS Inc., Chicago, IL, USA). Demographic data was compared by using student t test and Mann Whitney U test. Postoperative data was compared by using Fisher's exact test. All reported P-values were based on two-sided tests and a P-value of <0.05 was considered significant.

3. Results

Postoperative complications including; pain, ecchymosis, paresthesia and edema were similar both female and male patients ($P > 0.05$). Endovascular procedures for venous insufficiency were performed from right lower extremity in 78 patients (52.3%) and from left lower extremity in 71 patients (47.7%) in group 1, from right lower extremity

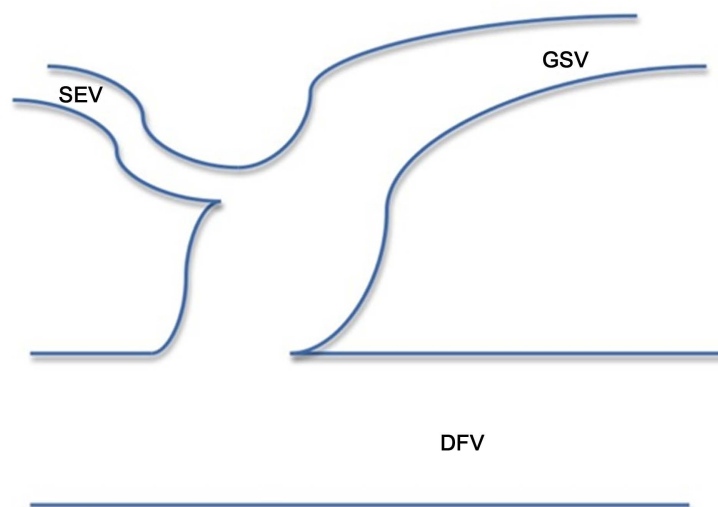


Figure 1. RFA or EVLA catheter was inserted from that sheath just distal to the superficial epigastric vein (SEV).

in 65 patients (48.5%) and from left lower extremity in 69 patients (51.5%) in group 2. Operation time was 19.19 ± 5.44 minutes in group 1 and 19.71 ± 6.62 minutes in group 2. The amount of tumescent anesthesia used during the procedure was 343.18 ± 61.93 ml in group 1 and 332.72 ± 70.11 ml in group 2. GSV diameter was 10.65 ± 3.72 mm in group 1 and 11.29 ± 3.78 mm in group 2. Length of GSV that endovascular process performed was 38.92 ± 6.88 cm in group 1 and 41.83 ± 4.82 cm in group 2. Postoperative complications in group 1 were hematoma formation in 2 (1.3%) patients, ecchymosis in 13 (8.7%) patients, edema in 21 (14.1%) patients and paresthesia in 10 (6.7%) patients (**Table 2**).

Postoperative complications in group 2 were hematoma formation in 1 (0.7%) patient, ecchymosis in 8 (6%) patients, edema in 12 (9%) patients and paresthesia in 6 (4.5%) patients. Postoperatively burn, pulmonary embolism (PE) and deep venous thrombosis (DVT) was not observed in both groups. Return to daily activities (RDA) after the procedures was 2.10 ± 0.89 days in group 1 and 1.89 ± 0.89 days in group 2. The changes in VCSS values were 9.37 ± 0.99 prior to procedure, 4.56 ± 1.24 at 10th day, 3.73 ± 1.37 at 1st month, 2.84 ± 1.08 at 3rd month, 1.83 ± 0.74 at 6th month in group 1 and 8.91 ± 1.00 prior to procedure, 3.84 ± 1.11 at 10th day, 3.69 ± 1.24 at 1st month, 3.03 ± 1.13 at 3rd month, 1.81 ± 0.74 at 6th month in group 2. The efficiency of the process is defined as closure of GSV and was 96.6% in EVLA group and 98.5% in RFA group.

We found statistically significant difference between two groups in terms of preoperative and 10th day VCSS values and length of GSV process performed, other postoperative complication data and efficiency of the process did not show statistically significant difference. We detected a statistically significant difference in terms of VCSS scores after both procedures compared to preoperative values and significant clinical healing was observed from 10th postoperative day on in both groups. ($p < 0.001$)

4. Discussion

Although conventional treatment options in venous insufficiency such as perforating branch ligation, extirpation, saphenous vein ligation and stripping exist, advantages of RFA and EVLA in terms of low morbidity, effectivity, quick return to daily activities and patient comfort caused widespread use of that techniques [10] [11]. Different energy sources used for RFA and EVLA affect the postoperative complication types and frequency. In EVLA technique, GSV is closed due to intimal injury because of thermal effect, collagen denaturation at media layer and fibrotic occlusion. First, thrombus formation occurs due to intimal injury in EVLA technique. In RFA technique, GSV occlusion occurs due to tissue denaturation and thrombus formation is rarely observed [1] [12] [13]. The closure rates in our study groups were 96.6% in EVLA group and 98.5% in RFA group; also we detected a significant clinical healing in terms of VCSS values after both procedures postoperatively. Postoperatively burn, pulmonary embolism (PE) and deep venous thrombosis (DVT) was not observed in both groups. The complication rates for hematoma, ecchymosis, edema, phlebitis and paresthesia are higher in group 1, but the difference was not statistically different between groups. In our study,

we couldn't find any significant difference between two techniques, but Goode et al. proposed that RFA has better results compared to EVLA technique [14]. Similar results were presented with the studies on 810 nm diode laser [15] [16]. We assume that the difference between those studies is due to different wave lengths of the laser catheters used. Longer wave length used for EVLA results in change in energy release and reduction in complication rates. The 810 nm, 940 nm and 980 nm laser wave lengths are hemoglobin absorbable; however 1054 nm, 1320 nm and 1470 nm laser wave lengths are water and collagen absorbable. This fact reduces the energy amount, saphenous vein perforation rates and postoperative complication rates [1] [5]. In the studies comparing EVLA and RFA techniques, 810 nm diode laser catheters were used, but in our study we used 1470 nm wave length radial fiber laser catheter for EVLA. In studies comparing 1470 nm wave length laser application with 980 nm laser, they showed that postoperative complication rates and VCSS value follow up results are better with radial fiber catheter with 1470 nm laser catheter [17] [18]. Those studies by Dogancı and Gurkan may explain the cause of different results of our study compared to other studies for RFA and EVLA.

DVT and PE are among the feared complications after RFA and EVLA [19]. The venous thromboembolism incidence is reported to be between 0% - 16% after RFA and 0% - 8% after EVLA, but no significant difference was found between the techniques [20]-[22]. Type of anesthesia performed may affect venous thromboembolism incidence during endovascular procedures. The incidence of DVT after endovascular procedures is increased after general or spinal anesthesia [23]. Gampel compared venous thromboembolism rates after EVLA and RFA and found that DVT rate is higher in EVLA group. The high rate of general anesthesia in EVLA performed group in that study may explain the higher rate of DVT [24]. Another factor contributing to DVT rates is SEV ablation. Continuation of the blood flow in SEV may protect from DVT by its washing effect [2]. In our study group, we did not observe DVT. Probably, this is due to commencement of the ablation protocol distally from the SEV, use of sedation and local anesthesia rather than general or spinal anesthesia, early mobilization, mechanical and medical thromboembolism prophylaxis applications.

5. Limitations

In the study we have tried to provide standardization by using the same type of laser and radiofrequency devices in all patients. However, the main limitation of this study was that postoperative ultrasound control cannot be done in 72 hours to all patients. Finally all patients' control was achieved with Doppler ultrasound in 10 days postoperatively. Additionally as in previous studies postoperative clinical scoring is based on the patient's response.

6. Conclusion

We conclude that both RFA and 1470 nm EVLA procedures are effective and reliable

techniques in treatment of venous insufficiency; there was no significant difference between two methods in terms of effectivity and postoperative complication rates.

References

- [1] Sadick, N.S. (2006) Advances in the Treatment of Varicose Veins: Ambulatory Phlebectomy, Foam Sclerotherapy, Endovascular Laser, and Radio Frequency Closure. *Advances in Dermatology*, **22**, 139-156. <http://dx.doi.org/10.1016/j.yadr.2006.09.001>
- [2] Gibson, K.D., Ferris, B.L., Polissar, N., Neradilek, B. and Pepper, D. (2007) Endovenous Laser Treatment of the Small [Corrected] Saphenous Vein: Efficacy and Complications. *Journal of Vascular Surgery*, **45**, 795-801; Discussion 801-3. 2.
- [3] Criqui, M.H., Jamosmos, M., Fronck, A., *et al.* (2003) Chronic Venous Disease in an Ethnically Diverse Population: The San Diego Population Study. *American Journal of Epidemiology*, **158**, 448. <http://dx.doi.org/10.1093/aje/kwg166>
- [4] Timperman, P.E. (2004) Arteriovenous Fistula after Endovenous Laser Treatment of the Short Saphenous Vein. *Journal of Vascular and Interventional Radiology*, **15**, 625-627. <http://dx.doi.org/10.1097/01.RVI.00000130166.12122.83>
- [5] Proebstle, T.M., Lehr, H.A., Kargl, A., Espinola-Klein, C., Rother, W., Bethge, S. and Knop, J. (2002) Endovenous Treatment of the Greater Saphenous Vein with a 940-nm Diode Laser: Thrombotic Occlusion after Endoluminal Thermal Damage by Laser-Generated Steam Bubbles. *Journal of Vascular Surgery*, **35**, 729-736. <http://dx.doi.org/10.1067/mva.2002.121132>
- [6] Theivacumar, N.S., Dellagrammaticas, D., Darwood, R.J., Mavor, A.I. and Gough, M.J. (2008) Fate of the Great Saphenous Vein Following Endovenous Laser Ablation: Does Recanalisation Mean Recurrence? *European Journal of Vascular and Endovascular Surgery*, **36**, 211-215. <http://dx.doi.org/10.1016/j.ejvs.2008.03.014>
- [7] Mese, B., Bozoglan, O., Eroglu, E., Erdem, K., Acipayam, M., Ekerbicer, H.C. and Yasim, A. (2015) A Comparison of 1,470-nm Endovenous Laser Ablation and Radiofrequency Ablation in the Treatment of Great Saphenous Veins 10 mm or More in Size. *Annals of Vascular Surgery*, **29**, 1368-1372. <http://dx.doi.org/10.1016/j.avsg.2015.03.063>
- [8] Sydnor, M., Mavropoulos, J., Slobodnik, N., Wolfe, L., Strife, B. and Komorowski, D. (2016) A Randomized Prospective Long-Term (>1 Year) Clinical Trial Comparing the Efficacy and Safety of Radiofrequency Ablation to 980 nm Laser Ablation of the Great Saphenous Vein. *Phlebology*. [Epub Ahead of Print] <http://dx.doi.org/10.1177/0268355516658592>
- [9] Almeida, J.I., Kaufmann, J., Gockeritz, O., Chopra, P., Evans, M.T., *et al.* (2009) Radiofrequency Endovenous Closure FAST versus Laser Ablation for the Treatment of Great Saphenous Reflux: A Multicenter, Single-Blinded, Randomized Study (RECOVERY Study). *Journal of Vascular and Interventional Radiology*, **20**, 752-759. <http://dx.doi.org/10.1016/j.jvir.2009.03.008>
- [10] Hamel-Desnos, C., Gerard, J.L. and Desnos, P. (2009) Endovenous Laser Procedure in a Clinic Room: Feasibility and Side Effects Study of 1700 Cases. *Phlebology*, **24**, 125-130. <http://dx.doi.org/10.1258/phleb.2008.008040>
- [11] Luebke, T., Gawenda, M., Heckenkamp, J., *et al.* (2008) Meta-Analysis of Endovenous Radiofrequency Obliteration of the Great Saphenous Vein in Primary Varicosis. *Journal of Endovascular Therapy*, **15**, 213-223. <http://dx.doi.org/10.1583/07-2287.1>
- [12] Kalra, M., Glociczki, P., Rochester, M.N., *et al.* (2006) Fifteen Years Ago Laser Was Supposed to Open Arteries, Now It Is Supposed to Close Veins: What Is the Reality behind the Tool? *Perspectives in Vascular Surgery and Endovascular Therapy*, **18**, 3-8.

- <http://dx.doi.org/10.1177/153100350601800102>
- [13] Beale, R.J., Mavor, A.I.D., Gough, M.J., *et al.* (2004) Minimally Invasive Treatment for Varicose Veins: A Review of Endovenous Laser Treatment and Radiofrequency. *Ablation*, **3**, 188-197.
- [14] Goode, S.D., Chowdhury, A., Crockett, M., Beech, A., Simpson, R., Richards, T. and Braithwaite, B.D. (2010) Laser and Radiofrequency Ablation Study (LARA Study): A Randomised Study Comparing Radiofrequency Ablation and Endovenous Laser Ablation (810 nm). *European Journal of Vascular and Endovascular Surgery*, **40**, 246-253.
<http://dx.doi.org/10.1016/j.ejvs.2010.02.026>
- [15] Pannier, F. and Rabe, E. (2006) Endovenous Laser Therapy and Radiofrequency Ablation of Saphenous Varicose Veins. *The Journal of Cardiovascular Surgery*, **47**, 3-8.
- [16] Puggioni, A., Kalra, M., Carmo, M., Mozes, G. and Gloviczki, P. (2005) Endovenous Laser Therapy and Radiofrequency Ablation of the Great Saphenous Vein: Analysis of Early Efficacy and Complications. *Journal of Vascular Surgery*, **42**, 488-493.
<http://dx.doi.org/10.1016/j.jvs.2005.05.014>
- [17] Dogancı, S. and Demirkılıç, U. (2010) Comparison of 980 NM Laser and Bare-Tip Fibre with 1470 NM Laser and Radial Fibre in the Treatment of Great Saphenous Vein Varicosities: A Prospective Randomised Clinical Trial. *European Journal of Vascular & Endovascular Surgery*, **40**, 254-259. <http://dx.doi.org/10.1016/j.ejvs.2010.04.006>
- [18] Gurkan, S., Gur, O., Arar, C., Donbaloglu, M.O. and Ege, T. (2013) Comparison of Manual Pull Back 980 NM Wavelength Bare Tip Fiber Laser with Automated Pull Back 1470 NM Wavelength Radial Fiber Laser in Great Saphenous Vein Insufficiency: Analysis of Early Term Efficacy and Complications. *Damar Cerrahisi Dergisi*, **22**, 211-216.
<http://dx.doi.org/10.9739/uvcd.2013-35730>
- [19] Rosales-Velderrain, A., Gloviczkin, P., Said, S.M., Hernandez, M.T., Canton, L.G. and Kaira, M. (2013) Pulmonary Embolism after Endovenous Thermal Ablation of the Saphenous Vein. *Seminars in Vascular Surgery*, **26**, 14-22.
<http://dx.doi.org/10.1053/j.semvascsurg.2013.07.001>
- [20] Gloviczki, P., Comerota, A.J., Dalsing, M.C., Eklof, B.G., Gillespie, D.L., Gloviczki, M.L., *et al.* (2011) The Care of Patients with Varicose Veins and Associated Chronic Venous Diseases: Clinical Practice Guidelines of the Society for Vascular Surgery and the American Venous Forum. *Journal of Vascular Surgery*, **53**, 2S-48S.
<http://dx.doi.org/10.1016/j.jvs.2011.01.079>
- [21] Van Rij, A.M., Chai, J., Hill, G.B. and Christie, R.A. (2004) Incidence of Deep Vein Thrombosis after Varicose Vein Surgery. *British Journal of Surgery*, **91**, 1582-1585.
<http://dx.doi.org/10.1002/bjs.4701>
- [22] Marsh, P., Price, B.A., Holdstock, J., Harrison, C. and Whiteley, M.S. (2010) Deep Vein Thrombosis (DVT) after Venous Thermoablation Techniques: Rates of Endovenous Heat-Induced Thrombosis (EHIT) and Classical DVT after Radiofrequency and Endovenous Laser Ablation in a Single Centre. *European Journal of Vascular & Endovascular Surgery*, **40**, 521-527. <http://dx.doi.org/10.1016/j.ejvs.2010.05.011>
- [23] Min, R.J., Khilnani, N. and Zimmet, S.E. (2003) Endovenous Laser Treatment of Saphenous Vein Reflux: Long-Term Results. *Journal of Vascular and Interventional Radiology*, **14**, 991-996. <http://dx.doi.org/10.1097/01.RVI.0000082864.05622.E4>
- [24] Benarroch-Gampel, J., Sheffield, K.M., Boyd, C.A., Riall, T.S. and Killewic, L.A. (2013) Analysis of Venous Thromboembolic Events after Saphenous Ablation. *Journal of Vascular Surgery: Venous and Lymphatic Disorders*, **1**, 26-32.
<http://dx.doi.org/10.1016/j.jvsv.2012.07.006>



Submit or recommend next manuscript to SCIRP and we will provide best service for you:

Accepting pre-submission inquiries through Email, Facebook, LinkedIn, Twitter, etc.

A wide selection of journals (inclusive of 9 subjects, more than 200 journals)

Providing 24-hour high-quality service

User-friendly online submission system

Fair and swift peer-review system

Efficient typesetting and proofreading procedure

Display of the result of downloads and visits, as well as the number of cited articles

Maximum dissemination of your research work

Submit your manuscript at: <http://papersubmission.scirp.org/>