

Differential influence of hippocampal subfields to memory formation: insights from patients with temporal lobe epilepsy

Roland Coras,^{1,*} Elisabeth Pauli,^{2,*} Jinmei Li,^{1,3} Michael Schwarz,² Karl Rössler,⁴ Michael Buchfelder,⁴ Hajo Hamer,² Hermann Stefan² and Ingmar Blumcke¹

1 Department of Neuropathology, University Hospital Erlangen, Schwabachanlage 6, 91054 Erlangen, Germany

2 Epilepsy Centre, Department of Neurology, University Hospital Erlangen, Schwabachanlage 6, 91054 Erlangen, Germany

3 Department of Neurology, West China Hospital, West China Medical School, Sichuan University, Chengdu, China

4 Department of Neurosurgery, University Hospital Erlangen, Schwabachanlage 6, 91054 Erlangen, Germany

*These authors contributed equally to this work.

Correspondence to: Dr Ingmar Blumcke,
Department of Neuropathology,
University Hospital Erlangen,
Schwabachanlage 6, 91054 Erlangen, Germany
E-mail: bluemcke@uk-erlangen.de

See doi:10.1093/brain/awu125 for the scientific commentary on this article.

To clarify the anatomical organization of human memory remains a major challenge in clinical neuroscience. Experimental data suggest dentate gyrus granule cells play a major role in memory acquisition, i.e. pattern separation and rapid pattern completion, whereas hippocampal CA1 neurons are implicated in place memory and autobiographical memory retrieval. Patients with temporal lobe epilepsy present with a broad spectrum of memory impairment, which can be assessed during clinical examination. Although long seizure histories may contribute to a pathophysiological reorganization of functional connectivity, surgical resection of the epileptic hippocampus offers a unique possibility to anatomically study the differential contribution of hippocampal subfields to compromised learning and memory in humans. Herein, we tested the hypothesis of hippocampal subfield specialization in a series of 100 consecutive patients with temporal lobe epilepsy submitted to epilepsy surgery. Memory profiles were obtained from intracarotid amobarbital testing and non-invasive verbal memory assessment before surgery, and correlated with histopathologically quantified cell loss pattern in hippocampal subfields obtained from the same patients using the new international consensus classification for hippocampal sclerosis proposed by the International League against Epilepsy (HS ILAE). Interestingly, patients with CA1 predominant cell loss (HS ILAE Type 2; $n = 13$) did not show declarative memory impairment and were indistinguishable from patients without any hippocampal cell loss ($n = 19$). In contrast, 63 patients with neuronal loss affecting all hippocampal subfields including CA1, CA4 and dentate gyrus (HS ILAE Type 1), or predominant cell loss in CA4 and partially affecting also CA3 and dentate gyrus (HS ILAE Type 3, $n = 5$) showed significantly reduced declarative memory capacities (intracarotid amobarbital testing: $P < 0.001$; verbal memory: $P < 0.05$). Our results suggested an alternative model of how memory processing can be organized amongst hippocampal subfields, and that CA1 pyramidal cells are less critically involved in declarative human memory acquisition compared to dentate gyrus granule cells or CA4/CA3 pyramidal cells.

Keywords: brain; hippocampus; dentate gyrus; epilepsy; seizure; neuropathology

Abbreviations: CA = cornu ammonis; IAT = intracarotid amybarbital testing; HS ILAE = hippocampal sclerosis classification of the International League against Epilepsy; TLE = temporal lobe epilepsy

Introduction

Our knowledge about the anatomy of memory relies mostly on rodent animal models and developed an increasingly complex image of structural and functional connectivity between hippocampal subfields and the rest of the brain (van Strien *et al.*, 2009). Human studies are rare and obtained from neuroimaging or neuropathology data in patients with specific neurological and psychiatric disorders (Zola-Morgan *et al.*, 1986; Rempel-Clower *et al.*, 1996; Narr *et al.*, 2004; Bartsch *et al.*, 2010; Coras *et al.*, 2010; Small *et al.*, 2011). Patients with transient global amnesia and cerebral ischaemia preferentially affecting the hippocampal CA (cornu ammonis) 1 sector allow us to study specific roles of hippocampal subfield during learning and memory consolidation and the studies suggested a role of CA1 in remote autobiographic memory retrieval (Bartsch *et al.*, 2006, 2010, 2011) and that isolated CA1 dysfunction leads to significant anterograde and retrograde amnesia (Zola-Morgan *et al.*, 1986; Rempel-Clower *et al.*, 1996; Bartsch *et al.*, 2006). In contrast, animal studies suggested a selective role for CA1 pyramidal cells in intermediate and long-term memory consolidation, but not in short-term acquisition or memory encoding (Remondes and Schuman, 2004; Vago *et al.*, 2007). As the anatomy of human memory is even more complex and experimental data are limited, current knowledge remains incomplete and contradictory results require careful consideration.

In humans, epilepsy surgery of the temporal lobe offers the unique opportunity to quantitatively estimate memory impairment and structural subfield abnormalities by microscopic inspection of the resected hippocampus (Sass *et al.*, 1991; Rausch and Babb, 1993; Chelune, 1995; Pauli *et al.*, 2006). Notwithstanding, chronic disease progression in these patients may have considerable impact on the functional organization of human memory, in particular if seizure onset compromises the maturing young brain. Hippocampus-dependent declarative memory is often impaired in patients with temporal lobe epilepsy (TLE) (Helmstaedter and Elger, 2009), and can be reliably assessed using invasive intracarotid amybarbital testing (IAT) memory testing or non-invasive verbal memory scales (Wada and Rasmussen, 1960; Hermann *et al.*, 1992).

Herein, we tested the hypothesis whether declarative memory impairment in patients with TLE is interrelated with distinct hippocampal subfield lesions (i.e. a parallel processing hypothesis), or if neuronal cell loss at any hippocampal location would significantly deteriorate memory formation (i.e. a sequential processing hypothesis). We examined presurgical memory performance in a series of 100 patients with TLE consecutively submitted to the Erlangen epilepsy surgery programme, and correlated declarative memory scores with histopathologically quantified hippocampal cell loss obtained from the same patients. Hippocampal cell loss patterns were scored according to the new International League against Epilepsy classification system for hippocampal sclerosis (HS

ILAE), which separates different patterns of neuronal cell loss in hippocampal subfields (Blumcke *et al.*, 2013a,b). Three hippocampal sclerosis subtypes can be reliably distinguished with ILAE Type 1 affecting all hippocampal subfields as well as the dentate gyrus (i.e. up to 85% cell loss in CA1; Blumcke *et al.*, 2007), and two atypical hippocampal sclerosis subtypes. Atypical hippocampal sclerosis subtypes have been designated as ILAE Type 2 when cell loss predominantly affects CA1 (mean of 78.2% loss; all other regions show minor reduction of <20%) and ILAE Type 3 (44.7% cell loss in CA4 and 34.5% cell loss in dentate gyrus, but all other sectors including CA1 showing only minor reduction <20%; Blumcke *et al.*, 2007). In addition, we were keen to understand the impact of hippocampal pathology on postoperative memory performance, which has also been shown to be heterogeneously affected in surgical patients with TLE (Hermann *et al.*, 1995).

Materials and methods

Participants

One hundred patients with drug-resistant TLE were included in this study. They were consecutively enrolled into the presurgical monitoring and epilepsy surgery programme of the Erlangen University Hospital between 2002 and 2011, and selected for the presented study if at least one hippocampal tissue specimen from *en bloc* resection was available for assessment of the entire subfield anatomy. Before admission at our hospital, all patients received antiepileptic drug treatment, and failed adequate trials of two tolerated, appropriately chosen and used antiepileptic drug schedules. Patients were 38.66 ± 10.36 years old at time of surgery (range 17–60 years), and experienced a mean of 25.6 ± 17.2 years with seizures before surgery (range 2–55 years); 55 patients were male and 45 female. The seizure focus and resection site were left temporal in 45 and right temporal in 55 patients. Informed and written consent for additional scientific investigations was obtained from all patients included in our study and approved by the local ethics committee of the University of Erlangen. All procedures were conducted in accordance with the Declaration of Helsinki.

Presurgical evaluation, surgical treatment and outcome

All patients were enrolled into the presurgical evaluation programme including long-term video-EEG monitoring, MRI at 1.5 or 3 T (Siemens Sonata or Trio) and neuropsychological testing. During presurgical evaluation, 42% of patients were on monotherapy and 55% on polytherapy with two drugs, only 3% on three drugs. At the time of neuropsychological investigation and surgery, 70% of patients received two drugs (25% three drugs, 5% four drugs). Levetiracetam, lamotrigine, carbamazepine and oxcarbazepine were administered most frequently, no patient was on topiramate or valproate. Seventy-eight patients were submitted to bilateral IAT (see

below). Additional PET, single photon emission computed tomography (SPECT), magnetic source imaging (MEG) or functional MRI investigations were applied in selected cases to reliably identify the epileptogenic focus and compromised temporal lobe area. Patients with bilateral TLE or bilateral memory impairment were not included in our study. Tailored surgical procedures varied from selective amygdalo-hippocampectomy to anterior two-third temporal lobe removal, including *en bloc* resection of the hippocampus (for anterior-to-mid-body region). Patients underwent neuropsychological re-evaluation 6 months after brain surgery, and seizure frequency was assessed after 1 year using Engel's scoring system (Engel, 1987).

Neuropathological evaluation and hippocampal sclerosis classification

Surgical hippocampus specimens were dissected into 5-mm slices in coronal planes along the anterior–posterior axis, fixed in 10% formalin and routinely processed into liquid paraffin. In 36 cases of this series, we obtained more than one coronal slice of an anatomically well-preserved hippocampus. In the remainder, only one slice was sufficiently preserved to allow microscopic inspection of all hippocampal subfields. Paraffin-embedded specimens were cut at 4 µm on a rotation microtome (Microm) and stained with haematoxylin and eosin and NeuN (Millipore, 1:1000; Wolf *et al.*, 1996) using an automated staining apparatus (Ventana). All tissue specimens were microscopically reviewed by two neuropathologists (I.B. and R.C.), who were blinded to the presurgical evaluation of the patient. Hippocampal sectors CA1, CA2, CA3 and CA4 were examined at ×20 objective magnification at four randomly selected microscopic fields (each 250 × 250 µm). The internal and external limbs of the dentate gyrus were examined at ×40 objective magnification, at 10 randomly selected microscopic fields (each 100 × 100 µm). Subiculum was examined at ×20 objective magnification at 10 randomly selected microscopic fields (each 250 × 250 µm). Measurements were performed using a microcomputer imaging system (ColorView II CCD camera, Soft imaging system SIS) attached to a BX51 microscope (Olympus). NeuN stained neuronal cell bodies were tagged on the computer screen, counted within the region of interest and expressed as mean number of neurons/mm² using AnalySIS imaging software (SIS). Cell densities were transformed into z-scores, based on normal values obtained from age-matched autopsy controls (Blumcke *et al.*, 2007). Individual z-score vectors for hippocampal and dentate gyrus subfields were classified into hippocampal sclerosis subtypes as previously described (Blumcke *et al.*, 2013b): HS ILAE Type 1 = classic hippocampal sclerosis with pronounced neuronal cell loss in all hippocampal subfields (in particular CA1 >80% cell loss; CA4 >40% neuronal cell loss); HS ILAE Type 2 = atypical hippocampal sclerosis with predominant neuronal cell loss in CA1 (>78%) and less severe neuronal cell loss in all other subfields (<25%); and HS ILAE Type 3 = atypical hippocampal sclerosis with predominant neuronal cell loss in CA4 (>45%). Patterns of granule cell loss and architectural granule cell layer abnormalities, i.e. dispersion, were recorded, but not proven specific for any hippocampal sclerosis subtype (Blumcke *et al.*, 2007, 2009). A semi-automated hippocampal sclerosis subtype prediction software for hippocampal NeuN cell counts was used for this study and is available at the German Neuropathology Reference Centre for Epilepsy Surgery (www.epilepsie-register.de; personal registration required).

For myeloarchitectural analysis Cresyl violet and Luxol Fast blue histochemistry was applied in all hippocampal specimens. In addition, paraffin-embedded hippocampal specimens were stained with CNPase (2',3'-cyclic nucleotide 3'-phosphodi-esterase, Millipore, 1:200) and

MBP (Dako, 1:400) using an automated immunohistochemistry staining apparatus (Ventana).

Intracarotid amobarbital testing and standardized Erlangen protocol

IAT was performed in 78 of 100 patients to assess the risk for post-operative memory impairment. The greatest potential risk in surgical treatment is verbal memory loss in patients suffering from left-sided TLE (Chelune, 1995), but suspicion of atypical memory dominance in right-sided TLE also requires examination. A standardized IAT protocol used at our department for 20 years, includes double encodable memory items tested under recall and recognition conditions. All results are transformed into z-scores using normative values specific for speech dominant and for non-dominant hemispheres, respectively. As healthy controls are not available for IAT, standardization was based on norm values (mean M_n and standard deviation SD_n) from the contralateral, non-affected left or right temporal lobes, including only those patients from our database ($n > 200$) presenting with: (i) unilateral mesial TLE; (ii) complete postoperative seizure freedom; (iii) unilateral left-sided speech dominance; and (iv) normal range IQ. IAT memory scores were transformed into z-values following the calculation: (i) if the resected hippocampus was from the speech dominant hemisphere: $z \text{ IAT memory} = [(total \text{ memory score} - M_n \text{ left}) / SD_n \text{ left}]$; and (ii) if the resected hippocampus was from the non-dominant hemisphere: $z \text{ IAT memory} = [(total \text{ memory score} - M_n \text{ right}) / SD_n \text{ right}]$. Thus, a z-score of 0 indicates full functional integrity of the investigated dominant or non-dominant hippocampal structure; i.e. indicates equality with the average score of non-affected left or right hippocampi, respectively in unilateral TLE. Z-scores below -1 indicate impaired function.

On the first day, training without injection of amobarbital was performed to familiarize the patient with the procedure and assess their baseline functioning. On the next two consecutive days the test was performed with injection of amobarbital into the left and right carotid artery. Intracarotid injection of 150 mg amobarbital in a 10% solution via transfemoral catheterization was administered. The procedure was videotaped and monitored with EEG (from 10 positions of the 10/20 system) to control the barbiturate effect. Further validation of the barbiturate effect was recognition of hemiparesis. We used three parallel versions of the test with equally difficult items for memory and language testing. The three parallel forms were randomly applied to the three IAT sessions. Presentation of memory material was performed during the maximal barbiturate effect as indicated by EEG slowing and hemiparesis (usually spanning the first 3–5 min).

The sequential test protocol for language and memory testing were: (i) serial speech: counting starts immediately before the amobarbital injection and is continued after the injection; (ii) naming and memorizing of five pictures of objects and three objects given to the non-paretic hand; (iii) reading, hearing and memorizing of five words (all object names); (iv) receptive speech: (a) comprehension of two spoken commands, (b) Token Test from (ii) and (iii); (v) repetition of two letters, six words and two sentences; (vi) reading of five sentences (semantic and syntactical decisions are assessed); and (vii) counting backwards as control for language recovery.

Memory was assessed for free recall and recognition memory. Correctly recalled items were scored with 1 point. For the assessment of recognition, each item was presented to the patient along with three distractors (forced choice). Each correctly recognized item was scored an additional point. The main assessment parameter was total memory score (free recall + recognition), which proved to be

advantageous to avoid ceiling and bottom effects and justified because both depend on hippocampal integrity.

Some criticism of the IAT has been raised concerning the lack of direct perfusion with amobarbital of the posterior hippocampus during the standard test administration. However, studies using stereo-EEG recordings from intrahippocampal depth electrodes, high-resolution SPECT and PET have shown that during the IAT the activity of anterior and posterior hippocampus in the hemisphere receiving the amobarbital is significantly reduced (Urbach *et al.*, 1999). In support of the usefulness of the Wada test Trenerry and Loring (1995) also state:

‘...the Wada test is effective in lateralizing seizure onset, predicting post-operative seizure control, and predicting degree of verbal memory decline following left temporal lobectomy. The validity of Wada test data has also been supported by correlations between Wada memory performance and hippocampal pyramidal cell loss or MR imaging determined hippocampal volumes.’

Verbal memory assessment

Verbal memory was assessed using the Berlin Amnesia Test (Metzler *et al.*, 1991), a standardized German Memory Test Battery for quantitative assessment of amnesic deficits (anterograde amnesia). Here we used the total verbal memory score (learning of structured and unstructured word lists, testing by free recall and recognition). Results were transformed into z-scores using normal values from healthy subjects.

The Berliner Amnesia Test is a German memory inventory composed of eight material and recall-specific subtests aiming at the diagnosis of memory impairment as a result of brain pathology (Metzler *et al.*, 1991). The test is adapted to detect empirically established amnesic symptoms (Hirst, 1982), with special consideration given to differentiation between individuals in the lower performance range. In addition to the normal population, normative data are also available on specific subpopulations of amnesic patients. Raw scores are z-transformed and total scales i.e. for verbal and figural memory are computed. In contrast to other memory inventories such as the Wechsler Memory Scale, the Berliner Amnesia Test provides empirically derived material-specific scales. The construct validity of the test was evaluated by the authors using principal component analysis which resulted in a two-factor solution: Factor 1, severity of amnesic impairment, with high loading of verbal subtests (free recall and recognition); and Factor 2, loading highly on figural subtests, allowing to differentiate between verbal and figural memory deficits.

Statistical analysis

Statistical analysis was performed using SPSS statistical software (PASW Statistics 16.0). All memory test results and neuropathological parameters (cell counts in the different hippocampal subfields) were given in z-scores ($M = 0$, $SD = 1$). Univariate analysis of variance (ANOVA) and Bonferroni *post hoc* tests were used for independent groups, in case of repeated measures the univariate analysis for variance for repeated measurement was applied (all co-varied for gender). We used Levines statistic to test the homogeneity of variances. Regression analysis was performed to assess the relative importance of each hippocampal subfield predicting memory performance. We applied *t*-statistics for the linear regression coefficient and only values >2 were considered significant. To check for multicollinearity, tolerance statistics were used. To test the possible impact of seizure history and disease load (age at onset, duration, seizure

frequency) on neuropathological parameters and memory performance, nonparametric statistics (Spearman correlation analyses) were used.

Results

Histopathological analysis

Histopathological examination at the hippocampal mid-body level was available from all surgical specimens and revealed differential patterns of pyramidal cell loss across subregions of the cornu ammonis (Fig. 1). Cell density measurements of NeuN stained neurons allowed stratification into the classic hippocampal sclerosis variant (HS ILAE Type 1) in 63 surgical specimens (Fig. 1E and F). Atypical HS ILAE Type 2 (CA1-predominant sclerosis) was detected in 13 patients (Fig. 1C and D), and there were five patients with atypical HS ILAE Type 3 (CA4-predominant sclerosis). No hippocampal sclerosis was microscopically confirmed in 19 cases (Fig. 1A and B). Cell density measurements of NeuN stained neurons revealed lower cell densities in CA3 and CA4 subfields and dentate gyrus in HS ILAE Types 1 and 3 as compared to HS ILAE Type 2 ($F = 9.8$, $df = 2/88$, $P < 0.001$; Fig. 2). Postsurgical follow-up was assessable 1 year after operation in 93 of 100 patients. A total of 62 patients were classified free of disabling seizures (Engel I, 67%), with 57 patients achieving complete seizure control (Engel Ia; 61.3%). The most beneficial outcome was obtained in patients with HS ILAE Type 1. Of these, 74.6% became seizure-free (Engel class Ia/b), compared to 38.5% of patients with HS ILAE Type 2, 50% in HS ILAE Type 3 and 52.6% in no hippocampal sclerosis. We assessed hippocampal myeloarchitecture using Cresyl violet and Luxol Fast blue histochemistry as well as CNPase and MBP immunohistochemistry. Comparison of the myeloarchitecture from distinct subregions of the hippocampal formation (entorhinal cortex, CA1, CA2 and CA3/fimbria complex) revealed different patterns of myelin breakdown or loss, allowing us to reliably distinguish no hippocampal sclerosis, ILAE hippocampal sclerosis Type 1 and ILAE hippocampal sclerosis Type 2 (Fig. 3). At the level of CA1, both HS ILAE Type 1 and Type 2 showed reduced myelin densities in the stratum radiatum and lacunosum/moleculare compared to no hippocampal sclerosis (Fig. 3B). This pattern continues at the level of sector CA2 in HS ILAE Type 1 (Fig. 3G) but these fibres were preserved in HS ILAE Type 2 (Fig. 3K), and similar to no hippocampal sclerosis (Fig. 3C). Another obvious difference was observed in the region of CA3 where the fimbria trail can be recognized (Fig. 3D, H and L). Similar to specimens with no hippocampal sclerosis (Fig. 3D), this trail was preserved in HS ILAE Type 2 (Fig. 3L), but almost completely lost in HS ILAE Type 1 (Fig. 3H).

In 36 *en bloc* resected hippocampal specimens, we obtained several section levels along the anterior–posterior axis that showed a well-preserved anatomical representation of hippocampal subfields. A mean of 2.4 (± 0.7) slides from each patient were available for our analysis. Neither the hippocampus head nor uncus were enrolled into our semiquantitative assessment, as the given coronal section plane did not allow a complete reconstruction of cornu ammonis subfields. Cell density measurements of

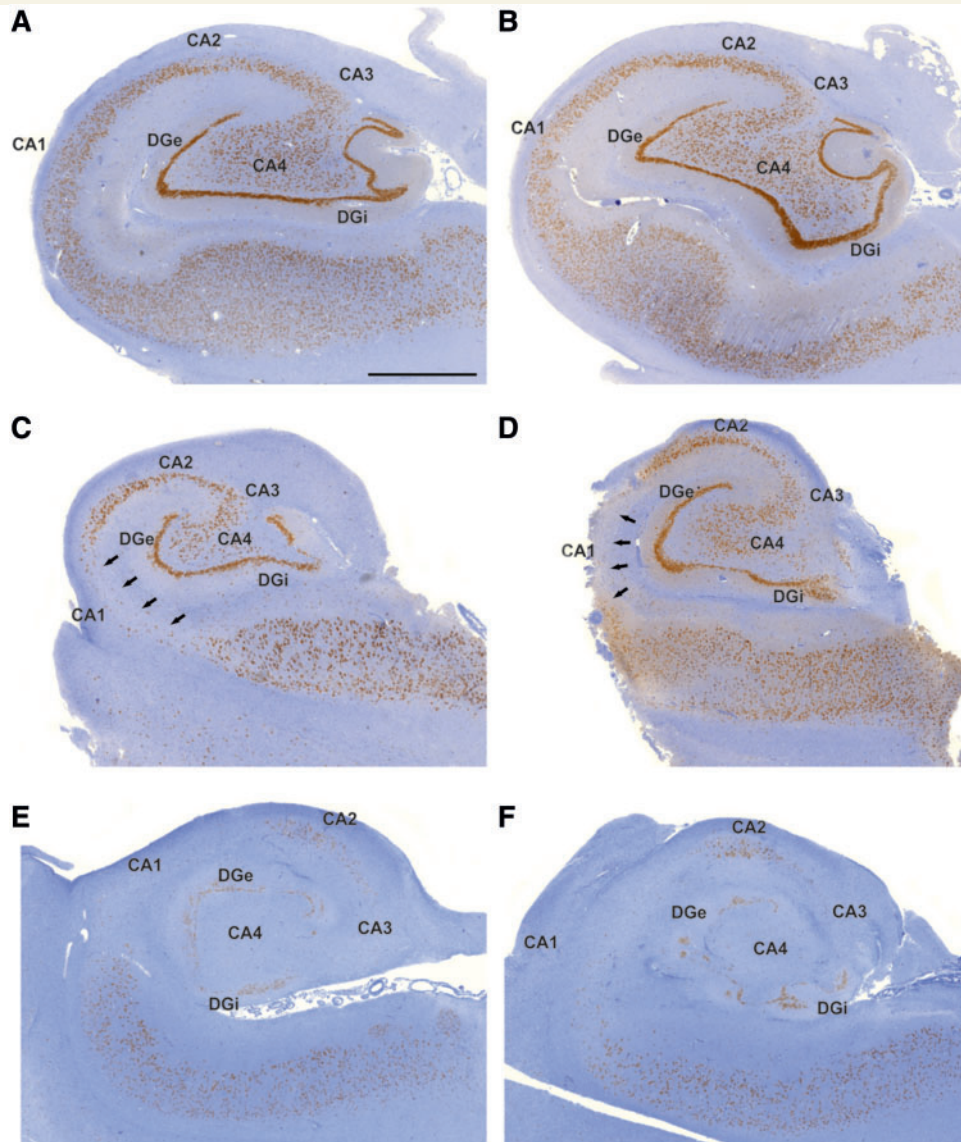


Figure 1 Subfield specific patterns of hippocampal damage in patients with TLE. The neuronal density patterns/patterns of hippocampal sclerosis were assessed at two separate levels of the same hippocampal specimen along the anterior–posterior axis (**A**→**B**, **C**→**D** and **E**→**F**) and did not show any differences. (**A** and **B**) No hippocampal sclerosis, no segmental cell loss in the hippocampal subfields CA1, CA2, CA3 and CA4. (**C** and **D**) HS ILAE Type 2 (CA1-sclerosis), the CA1 sector is heavily depleted of pyramidal cells (black arrows) whereas sectors CA2, CA3 and CA4 are well preserved. (**E** and **F**) HS ILAE Type 1 (classic hippocampal sclerosis), all sectors are affected by a severe pyramidal cell loss. Scale bars: **A**–**F** = 2000 μ m. DGe = dentate gyrus (external limb); DGi = dentate gyrus (internal limb).

NeuN stained neurons showed similar mean numbers across anterior–posterior section levels in all 36 patients, and hippocampal sclerosis classification as well as subfield-specific cell loss (in particular in HS ILAE Type 2) did not change for any of these patients: HS ILAE Type 1 ($n = 27$), HS ILAE Type 2 ($n = 2$), HS ILAE Type 3 ($n = 1$), no hippocampal sclerosis ($n = 6$).

In hippocampal specimens from 80 patients, the subiculum revealed a sufficiently large area of at least 0.625 mm² to allow semiquantitative cell density measurements (see above). The distribution of hippocampal sclerosis patterns in this series of patients was as follows: HS ILAE Type 1: $n = 53$, HS ILAE Type 2: $n = 11$, HS ILAE Type 3: $n = 3$, no hippocampal sclerosis: $n = 13$. ANOVA

revealed no significant group differences in subiculum cell densities: HS ILAE Type 1 (mean 300.79 neurons/mm², SD = 46.78), HS ILAE Type 2 (mean 314.77 neurons/mm², SD = 40.65), ILAE Type 3 (mean 317.67 neurons/mm², SD = 46.65) and no hippocampal sclerosis (mean 312.35 neurons/mm², SD = 36.77). We also found no correlation with any clinical parameter or memory scores.

The entorhinal cortex is located anterior at the level of the hippocampus head and is not accessible from hippocampal mid-body specimens. We identified 15 surgical specimens in which the entorhinal cortex was anatomically well preserved at the level of the hippocampus head, and the frequency of hippocampal

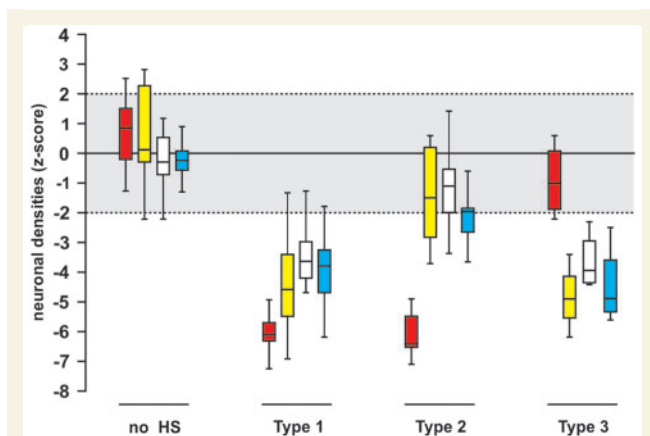


Figure 2 Neuronal density measurements in hippocampal sclerosis subtypes. Cluster analysis of NeuN immunoreactive neuronal cell counts at different hippocampal subfields. No hippocampal sclerosis: $n = 19$; HS ILAE Type 1: $n = 63$; HS ILAE Type 2: $n = 13$; HS ILAE Type 3: $n = 5$. Red: CA1; yellow: CA3; white: CA4; blue: dentate gyrus (internal limb) using our previously proposed hippocampal subfield specific classification scheme (modified from Blumcke *et al.*, 2007). The grey shading indicates the range of normal neuronal cell densities (in z-scores).

sclerosis patterns in this series of patients was as follows: HS ILAE Type 1: $n = 6$; HS ILAE Type 2: $n = 1$; HS ILAE Type 3: $n = 1$; and no hippocampal sclerosis: $n = 7$. Visual inspection did not reveal significant cell loss patterns in Layer III (Du *et al.*, 1993; Yilmazer-Hanke *et al.*, 2000), nor any other cortical layer (Fig. 4). We used no further semiquantitative cell counting to corroborate our visual inspection.

We systematically studied correlations between subfield-specific hippocampal cell densities and clinical parameters. Significant findings were observed between hippocampal sclerosis subtypes and age at epilepsy onset and epilepsy duration (Table 1). Additional pairwise testing using the Mann-Whitney U-test revealed that group differences in age at epilepsy onset were driven by differences between the no hippocampal sclerosis and ILAE Type 1 groups (Mann-Whitney $U = 315.5$, $P = 0.005$; uncorrected for multiple comparisons) and those between the ILAE Types 1 and 3 groups (Mann-Whitney $U = 86.0$, $P = 0.029$ uncorrected for multiple comparisons; Table 1). Differences among groups in terms of epilepsy duration were only significant between no hippocampal sclerosis and ILAE Type 1 (Mann-Whitney $U = 360.0$, $P = 0.022$ uncorrected for multiple comparisons). We also assessed the correlation between histopathological cell counts and indicators of seizure frequency and found that patients with earlier disease onset had a lower cell count in the CA1 region (Spearman $\rho = 0.258$, $P = 0.011$) and dentate gyrus (Spearman $\rho = 0.259$, $P = 0.010$). Furthermore, longer epilepsy duration was associated with reduced numbers of cells in the CA1, CA3, CA4 subfields and dentate gyrus. Other associations between indicators of disease load (i.e. seizure frequency, age at first hit) were not significant (all P 's > 0.169). With respect to postoperative seizure control, patients with HS ILAE Type 2 were less likely to

become seizure-free with $\chi^2 = 6.39$ and $df = 1$ at $P = 0.011$ (Table 1). All other comparisons of postoperative seizure freedom among hippocampal sclerosis groups revealed no significant differences.

Correlation between memory and hippocampal subfield pathology

In patients with TLE with selective CA1 pyramidal cell loss (HS ILAE Type 2; $n = 13$), ipsilateral IAT memory scores were significantly higher compared to patients with HS ILAE Type 1 ($n = 48$), and HS ILAE Type 3 ($n = 5$; Fig. 5). ANOVA confirmed the significant group effect ($F = 18.58$, $df = 3/73$, $P < 0.001$) and Bonferroni *post hoc* tests showed that HS ILAE Type 2 differed significantly from HS ILAE Type 1 ($P < 0.001$) and from HS ILAE Type 3 ($P < 0.005$). However, memory capacity in patients with HS ILAE Type 2 did not significantly differ from normal values nor from patients without detectable neuronal cell loss in the resected hippocampus (no hippocampal sclerosis, $n = 11$), indicating functional integrity of the hippocampus in HS ILAE Type 2. Contralateral IAT memory was within the normal range in all patients before surgery.

Multiple regression and partial correlation analysis also showed that cell loss in the CA1 region does not contribute to explain memory impairment in patients with TLE. This was in contrast with dentate gyrus granule cell densities, which constituted a highly significant predictor of each patient's memory capacity. A loss of $>60\%$ of granule cells (-4 SD) removed the ability to successfully encode memory (Fig. 6).

Preoperative verbal memory testing showed similar patterns as described for IAT (Fig. 7). Patients with left CA1 predominant sclerosis (HS ILAE Type 2) and left no hippocampal sclerosis had better preoperative verbal memory than patients with left HS ILAE Type 1 or left hippocampal sclerosis Type 3. ANOVA ($F = 3.6$, $df = 2/32$, $P < 0.05$) and *post hoc* comparison between HS ILAE Type 2 and HS ILAE Type 1 ($P < 0.05$) confirmed these difference (as only two patients with HS ILAE Type 3 were operated in the dominant hemisphere, this group must be excluded from statistical analysis). Postoperatively, verbal memory was significantly decreased in patients with HS ILAE Type 2 or no hippocampal sclerosis ($P = 0.05$; Fig. 7), and the level of postoperative verbal memory capacity was comparably low in all HS ILAE subtypes.

There was no statistical significance for any correlation between postoperative memory impairment with postoperative seizure control, seizure type and frequency, duration of epilepsy, epilepsy onset and age at first hit. Furthermore, we studied the impact of seizure history and disease load on memory function, but could not detect any correlation with memory impairment (Table 2).

Discussion

Our data showed that patients with TLE with predominant pyramidal cell loss in the hippocampal CA1 region did not suffer from declarative memory dysfunction. This finding is remarkable and contrasts with severely impaired ipsilateral memory scores in

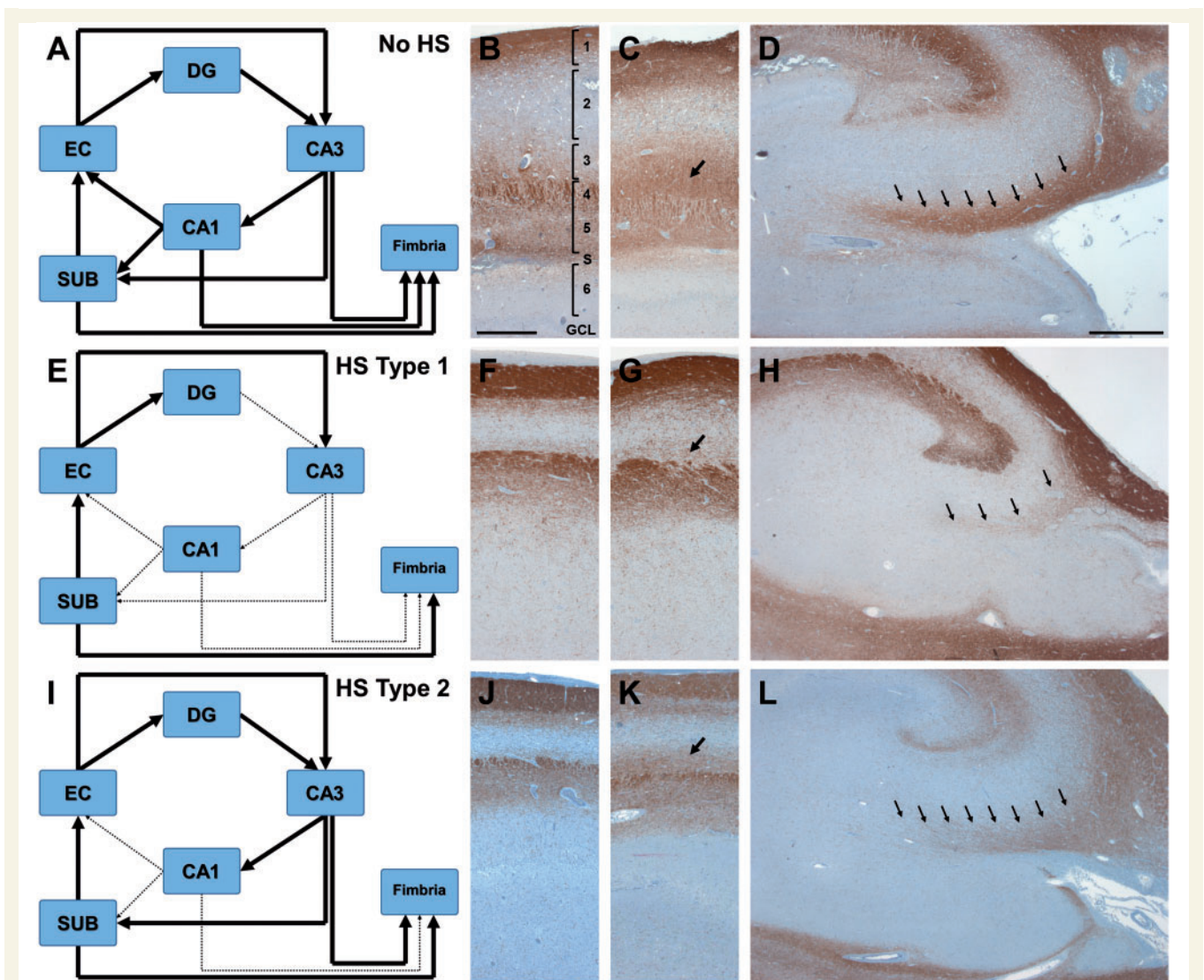


Figure 3 An alternative model of how the hippocampus communicates with the rest of the brain without CA1. (A, E and I) Schematic representation of the polysynaptic intrahippocampal pathway (modified from Duvernoy *et al.*, 2013). (A–D) No hippocampal sclerosis; (E–H) HS ILAE Type 1; (I–L) HS ILAE Type 2. Dotted and thinned connecting lines in E and I highlight areas of reduced connectivity between particular switch-points of the polysynaptic intrahippocampal pathway compared to an intact interconnection in patients with no hippocampal sclerosis. (B, F and J) Higher magnification at the level of CA1 (CNPase immunohistochemistry). (C, G and K) Higher magnification at the level of CA2 (CNPase immunohistochemistry). (D, H and L) Higher magnification at the level of CA3/4 (CNPase immunohistochemistry). Arrows in C, G and K: myelinated fibres of the stratum radiatum preserved in no hippocampal sclerosis (C) and HS ILAE Type 2 (K) whereas were significantly reduced in HS ILAE Type 1 (G). Arrows in D, H and L: myelinated fibres from CA3 into the fimbria in no hippocampal sclerosis (D) and HS ILAE Type 2 (L) whereas were significantly reduced in hippocampal sclerosis Type 1 (H). 1 = alveus/stratum oriens; 2 = stratum pyramidale; 3 = stratum radiatum; 4/5 = stratum lacunosum-moleculare; S = hippocampal sulcus; 6 = stratum moleculare (of the dentate gyrus); GCL = granule cell layer; SUB = subiculum; EC = entorhinal cortex. Scale bar in B = 500 μ m, applies also to F, J, C, G and K. Scale bar in D = 1000 μ m, applies also for H and L.

patients with TLE with hippocampal cell loss affecting the dentate gyrus and CA4, i.e. HS ILAE Type 1 or Type 3. Our results also showed coherence between IAT memory testing and verbal memory scores from left patients with TLE. Regression and correlation analysis confirmed that decreased neuronal cell densities in CA1 did not contribute to the extent of memory impairment. Even in patients with most severe CA1 pyramidal cell loss, anterograde memory acquisition was sustained, if this was the only affected

sector. In contrast, dentate gyrus granule cell densities proved to be highly predictive for each patient's memory capacity. We could demonstrate that memory formation is severely hampered beyond a granule cell loss of >60%. Notwithstanding, other confounding factors associated with disease load and severity should be taken into consideration, and HS ILAE Type 1 is often associated with early seizure onset and longer epilepsy duration before surgery. However, HS ILAE Type 3 presented with later disease onset

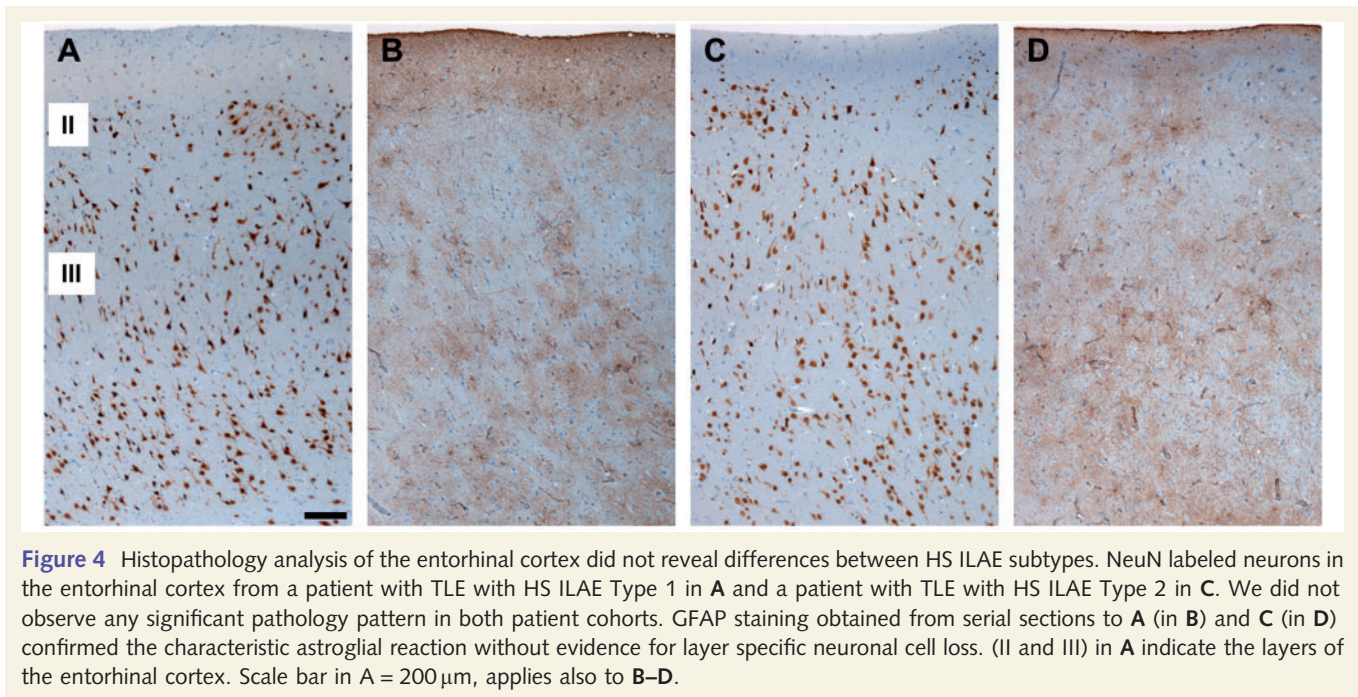


Figure 4 Histopathology analysis of the entorhinal cortex did not reveal differences between HS ILAE subtypes. NeuN labeled neurons in the entorhinal cortex from a patient with TLE with HS ILAE Type 1 in **A** and a patient with TLE with HS ILAE Type 2 in **C**. We did not observe any significant pathology pattern in both patient cohorts. GFAP staining obtained from serial sections to **A** (in **B**) and **C** (in **D**) confirmed the characteristic astroglial reaction without evidence for layer specific neuronal cell loss. (II and III) in **A** indicate the layers of the entorhinal cortex. Scale bar in **A** = 200 μ m, applies also to **B–D**.

similar to patients with hippocampal sclerosis Type 2 or no hippocampal sclerosis, but suffered from same memory impairment than patients with HS ILAE Type 1. When reviewing the myeloarchitectural organization of different hippocampal sclerosis subtypes, we observed maintenance of the dentate gyrus–CA3–fimbria pathway and also of CA3 collaterals projecting to the subiculum (Fig. 3). These data support the existence of an intricately connected hippocampal–parahippocampal network deciphered from rat (van Strien *et al.*, 2009) also in the human brain.

In previous studies, selective lesions of the hippocampal CA1 sector have been associated with severe memory impairment (Zola-Morgan *et al.*, 1986; Rempel-Clower *et al.*, 1996). However, our neuropathological findings described for HS ILAE Type 2 (predominant CA1 pyramidal cell loss) significantly differ from other pathological conditions associated with persisting memory impairment, i.e. transient ischaemic episodes or Alzheimer's disease. As an example, hippocampal damage in Alzheimer's disease always occurs in CA1, but also extends into subiculum and entorhinal cortex (Montine *et al.*, 2012). On the other hand, transient hypoxaemia may predominantly manifest in CA1 (Zola-Morgan *et al.*, 1986; Rempel-Clower *et al.*, 1996). The latter two studies reported four patients with transient cardiac arrhythmia and decreased blood pressure (Patient GD), cardiac arrest or infarction (Patients RB and WH), and one patient suffered from generalized tonic-clonic seizures induced either by chronic alcohol abuse or alcohol withdrawal. In these studies, brain autopsies and systematic histopathology were performed and showed complete neuronal cell loss in CA1 with increased glial cell densities (also in stratum oriens and stratum radiatum), and increased vascularization adjacent to the hippocampal fissure, which is consistent with the histomorphological pattern of pseudolaminar necrosis. In all patients, CA1 lesions extended into the subiculum, although to varying extent. In two patients, CA3 and

dentate gyrus were also compromised. The severity of memory impairment increased in these patients, confirming the contribution of dentate gyrus granule and CA4/CA3 pyramidal cells for memory. It is also important to note that brain ischaemia follows a different pathophysiological mechanism of neuronal cell death as those reported in our series of patients with TLE and hippocampal sclerosis. Whereas the CA1 sector in HS ILAE Type 2 shows a mean of $78.2 \pm 9.1\%$ neuronal cell loss (Figs 1 and 2; Blumcke *et al.*, 2007, 2012, 2013a, b), hypoxaemic damage terminates all neurons in oxygen-deficient anatomical regions. Interestingly, our myeloarchitectonical studies in HS ILAE Type 2 also identified persisting CA4/CA3 fibres connecting to the fimbria and subiculum (located in the preserved stratum moleculare-lacunosum; Fig. 3C and K), but were lost in HS ILAE Type 1 (Fig. 3G).

Most of our recent knowledge and appreciation of complex memory processing is deduced from rodent animal models (Nakashiba *et al.*, 2012), as well as from neuroimaging studies of human subjects with memory impairment due to localized brain lesions (Bartsch *et al.*, 2010, 2011). Animal studies suggest a selective role for CA1 pyramidal cells in intermediate/long-term memory consolidation, but not in short-term acquisition or encoding. Selective CA1 lesions in rats did impair spatial memory at retest intervals of 4 weeks, but not at a retest interval of 24 h, implicating disruption of long-term rather than short-term memories (Remondes and Schuman, 2004; Vago *et al.*, 2007). In our study, patients with atypical neuronal cell loss restricted to the CA1 subfield did not suffer from declarative memory deficits, even when the speech dominant hemisphere was affected, which is in good agreement with these animal studies. It also supports the notion of CA1-mediated autobiographical memory retrieval, mental time travel, and auto-noetic consciousness (Bartsch *et al.*, 2011). These findings suggest altogether, that fast hippocampal learning processes (enabling the formation of

Table 1 Clinical and histopathological data of patients included into the study

	HS ILAE subtype				P-value
	No hippocampal sclerosis	Type 1	Type 2	Type 3	
<i>n</i>	18	63	13	6	
Age (years)	37.9 ± 8.9	39.5 ± 10.9	36.8 ± 10.2	36.5 ± 10.1	
Gender (female)	9	27	4	6	
Age at first hit ^a	0.1 ± 10.9	0.5 ± 1.4	0.5 ± 1.5	0.8	
Type of first hit					
Febrile seizure	1	29	8	1	
Encephalitis	3	12	1	0	
Birth	1	6	3	0	
Other	9	5	0	0	
Unknown	4	11	1	5	
Age at epilepsy onset ^a	17.0 ± 13.3	6.5 ± 15.0	14.0 ± 21.5	17.5 ± 11.3	0.016
Epilepsy duration ^a	17.5 ± 20.0	27.0 ± 23.0	20.0 ± 21.0	14.5 ± 22.0	0.038
Side of focus (speech dominant)	4	32	5	2	
Complex partial seizures					
<5 per month	12	40	9	3	
5–10 per month	5	15	3	1	
>10 per month	1	7	1	2	
Generalized tonic-clonic seizures					
<3 per year	8	35	8	3	
3–10 per year	4	7	1	0	
>10 per year	3	13	2	2	
Speech dominance					
Left	13	55	10	6	
Right	2	2	0	0	
Bilateral	3	6	3	0	
MRI findings					
MRI negative	6	1	0	0	
Hippocampal sclerosis	0	60	10	4	
Lesion	12	0	0	0	
Hippocampal sclerosis + lesion	0	2	3	0	
Slight indication of hippocampal sclerosis	0	0	0	2	
Extrahippocampal pathology ^b					
Gliosis	7	2	1	0	
Congenital malformation	6	0	0	0	
Vascular malformation	2	0	0	0	
Tumours ^c	3	1	0	0	
FCD	0	0	2	0	
Last outcome					0.029
Not available	0	3	0	0	
Engel Ia	8	42	5	4	
Engel Ib	2	3	1	0	
Engel II	3	7	4	1	
Engel III	2	7	2	1	
Engel IV	3	1	1	0	
Postoperative seizure freedom ^d					0.046
Seizure-free	9 (50%)	44 (75%)	5 (39%)	3 (60%)	
Not seizure free	9 (50%)	14 (25%)	8 (61%)	2 (40%)	

^aMedian and interquartile range are shown.

^bData from histology.

^cGangliogliomas or dysembryoplastic neuroepithelial tumours; P-values are indicated where significant for group differences using Kruskal-Wallis *H* test.

^d χ^2 test for post-operative seizure freedom.

FCD = focal cortical dysplasia.

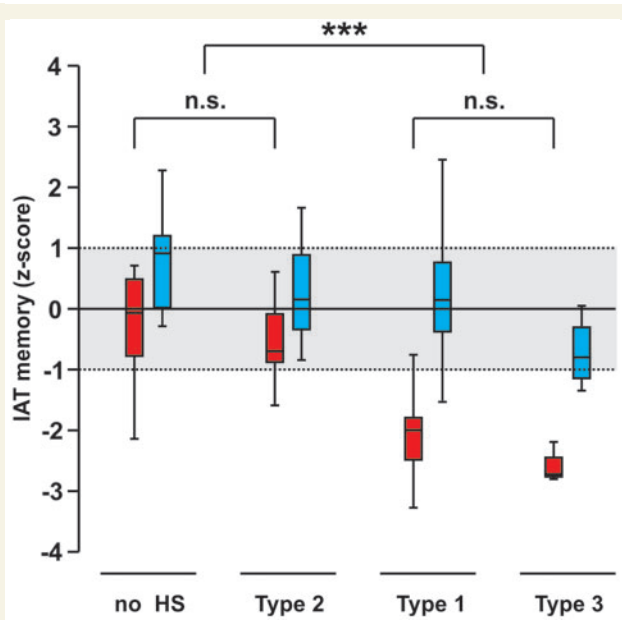


Figure 5 Relationship between preoperative IAT and hippocampal sclerosis patterns. Relationship between hippocampal sclerosis subtypes and preoperative ipsilateral (in red) or contralateral (in blue) IAT memory scores (transformed into z-scores). No hippocampal sclerosis: $n = 13$; HS ILAE Type 1: $n = 48$; HS ILAE Type 2: $n = 13$; HS ILAE Type 3: $n = 4$. Note significant lower ipsilateral memory scores in HS ILAE Type 1 (classical hippocampal sclerosis) and HS ILAE Type 3 (CA4 predominant sclerosis) compared to no-hippocampal sclerosis (hippocampi without neuronal cell loss) and HS ILAE Type 2 (CA1 predominant sclerosis). Note that all contralateral memory scores in blue corresponded to normal values (grey shading). $***P < 0.001$.

memory traces) may also operate independent from CA1 neurons. The deleterious impact of severe hippocampal sclerosis patterns on memory formation rather point to an important role of interaction between dentate gyrus and CA3. Dentate gyrus has been always regarded as intriguing anatomical region and focus of interest, and the awareness of life-long granule cell neurogenesis further increased its appeal (Eriksson *et al.*, 1998; Gage, 2000). Newly generated granule cells showed enhanced synaptic plasticity (Schmidt-Hieber *et al.*, 2004), functionally integrate into hippocampal networks (van Praag *et al.*, 2002), and contribute to rapid pattern separation (Nakashiba *et al.*, 2012). Notwithstanding, granule cells and dentate gyrus anatomy are very difficult to study in healthy humans, as MRI cannot quantify cell loss or properly separate the internal structure of the human hippocampus from adjacent CA subfields. Our group has previously published a series of studies showing that granule cell numbers are the most reliable predictor for declarative memory acquisition in patients with TLE (Pauli *et al.*, 2006; Blumcke *et al.*, 2009; Stefan *et al.*, 2009). *In vitro* studies from TLE-derived granule cell precursor cells proved further evidence that dentate gyrus capacity to generate new neurons significantly correlates with each patient's ability to store and retrieve declarative memory (Coras *et al.*, 2010). An interesting and yet little acknowledged finding was the subfield-specific impact of the dentate gyrus's internal limb. According to the seminal work of Altman and Bayer (1990a, b, c), the internal limb is more likely to generate granule cells in postnatal periods compared to more matured cells at the external limb position. Semiquantitative NeuN cell counts in all specimens of the presented study confirmed this observation and proved granule cell numbers at the internal limb within normal range in patients with HS ILAE Type 2 and no

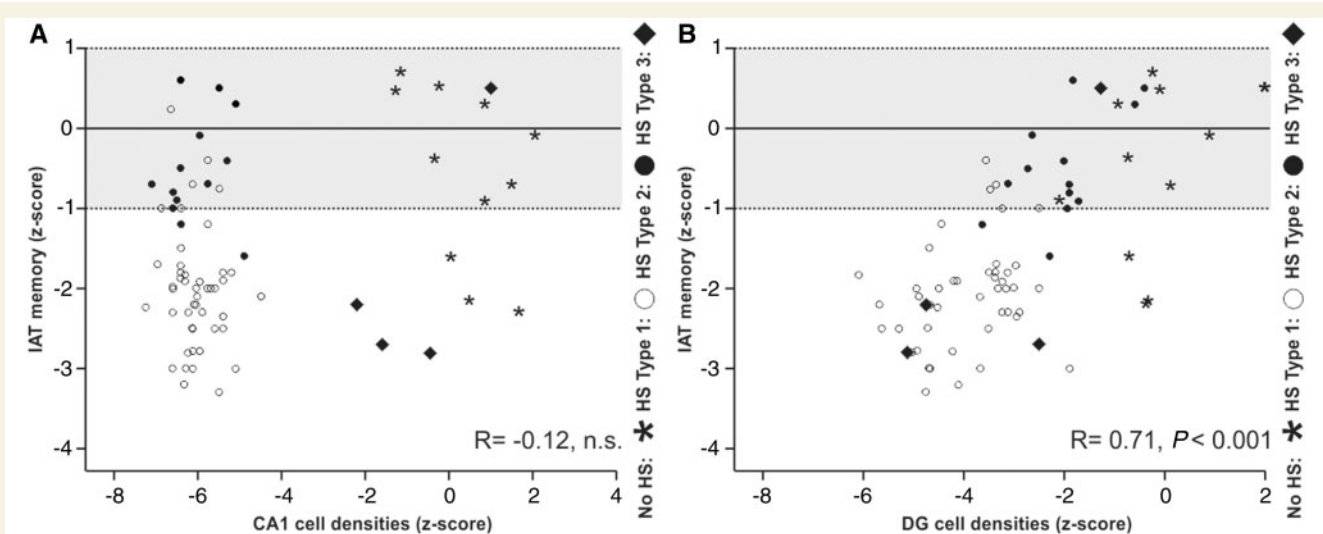


Figure 6 Relationship between preoperative IAT, CA1 pyramidal cell loss and granule cell loss. Relationship between preoperative ipsilateral IAT memory scores (transformed into z-scores) and pyramidal cell loss in CA1 (A) or granule cell loss in the dentate gyrus (B). No hippocampal sclerosis: $n = 13$; HS ILAE Type 1: $n = 48$; HS ILAE Type 2: $n = 13$; HS ILAE Type 3: $n = 4$. Memory function is sustained even in the presence of most severe cell loss in CA1 (A) whereas it was significantly impaired in patients with granule cell loss (B). The grey shading indicates the normal range of memory scores. Labelling of hippocampal sclerosis subtypes: open circle = HS ILAE Type 1, closed circle = HS ILAE Type 2, diamonds = HS ILAE Type 3, asterisks = no hippocampal sclerosis.

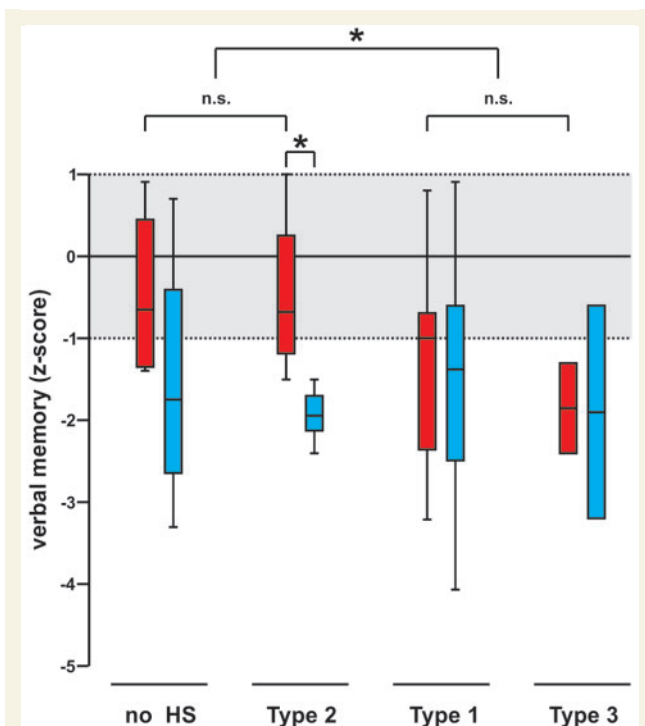


Figure 7 Pre- and postoperative loss in verbal memory is related to HS ILAE subtypes. Box plots of preoperative (red) and postoperative (blue) verbal memory scores (transformed into z-scores) in relation to hippocampal sclerosis subtypes in patients with left-sided TLE. No hippocampal sclerosis: $n = 4$; HS ILAE Type 1: $n = 35$; HS ILAE Type 2: $n = 4$; HS ILAE Type 3: $n = 2$. A normal range of verbal memory scores was considered between -1 and $+1$. Note the significant greater loss in verbal memory in hippocampal sclerosis Type 2 (CA1 predominant sclerosis) and cases with no hippocampal sclerosis compared to HS ILAE Type 1 and 3, in which cell loss affected also the dentate gyrus and CA4 (Fig. 2) * $P = <0.05$.

Table 2 Spearman correlation coefficient between memory and indicators of disease load

	Berliner Amnesia Test verbal	Wada ipsilateral	Wada contralateral
Age at first hit	-0.018	-0.075	0.085
Age at epilepsy onset	0.040	-0.021	-0.079
Epilepsy duration	-0.117	-0.066	-0.164
CPS per month	0.104	0.140	0.009
GTCS per year	-0.115	-0.047	-0.157

CPS = complex partial seizures; GTCS = generalized tonic-clonic seizures.

hippocampal sclerosis, but particularly compromised in patients with TLE with HS ILAE Type 1 or 3 and severely impaired memory capacity.

We and others have proposed that TLE with hippocampal sclerosis (TLE-HS) manifests with different clinicopathological variants (Wyler *et al.*, 1992; Watson *et al.*, 1996; Wieser, 2004; Blumcke

et al., 2007, 2012, 2013b; Thom *et al.*, 2010). Whereas classical hippocampal sclerosis patterns affected most anatomical subfields (including CA1, CA4 and the dentate gyrus; HS ILAE Type 1), atypical patterns of predominant pyramidal cell loss in CA1 (HS ILAE Type 2) or CA4 and the dentate gyrus (HS ILAE Type 3) can be encountered in $\sim 10\%$ of large case series. Because of the different terminology used, few data are available about the prognostic or predictive value of hippocampal sclerosis classification systems, and reported findings were not always consistent (Blumcke *et al.*, 2013b). However, there is no obvious correlation between hippocampal sclerosis subtypes and gender, side of resection, previous antiepileptic drug treatment and anatomical location of hippocampal specimens along the anterior–posterior axis. In addition, seizure frequency and estimated lifetime seizures did not have any influence on severity of hippocampal pathology, whereas analysis of variance revealed an influence of epilepsy duration with neuropathological hippocampal sclerosis patterns. Patients with TLE with no hippocampal sclerosis and HS ILAE Type 3 had a shorter epilepsy duration compared to HS ILAE Type 1 and 2. The HS ILAE classification system applied in the present study may allow, however, some prediction of postsurgical outcome, as most favourable seizure control can be achieved in patients presenting with HS ILAE Type 1 (74.6%). As most patients with HS ILAE Type 1 also suffered from severe memory impairment, lower seizure control rates in no hippocampal sclerosis or HS ILAE subtypes 2 and 3 cannot exclude another or larger seizure focus, although not detectable by MRI nor video-EEG monitoring. However, better memory performance in HS ILAE Type 2 and no hippocampal sclerosis make any contribution of seizure control rates less likely to contribute to severe memory deterioration. Obviously, our study allows only limited conclusions about anatomically and functionally related brain regions aside from the hippocampal midbody, which were also differentially involved in memory processing (Fanselow and Dong, 2010; Lau *et al.*, 2010; Small *et al.*, 2011; Squire *et al.*, 1992). Although we could not detect any significant differences with respect to neuronal cell loss in more anterior aspects of the human hippocampus, this analysis is helpful to exclude a localization bias within our presented data set. However, case numbers remain small and we could not approach the very anterior hippocampus head. In addition, we were able to study 15 specimens obtained from the entorhinal cortex and 80 from the subiculum. We could not prove significant neuronal cell pathology or differences between hippocampal sclerosis subgroups, suggesting that neither entorhinal nor subiculum pathology should be regarded as confounding variable or bias in our series. Chronic seizure burden needs careful consideration in all of our TLE-patients, as it may have direct impact on the anatomic-physiological organization of hippocampal memory compared to healthy controls. This obstacle cannot be adjusted in human studies. Therefore, we followed the strategy to compare different hippocampal sclerosis subtype patterns in a large TLE patient cohort from one single epilepsy centre sharing similar disease histories (Table 1). This strategy identified significant group differences in declarative memory performances related to structural lesion patterns rather than disease histories, i.e. no hippocampal sclerosis was similar to HS ILAE Type 2 and HS ILAE Type 1 similar to HS ILAE Type 3 (Figs 5 and 7).

Differential correlations between hippocampal sclerosis subtypes and memory impairment have not been described yet, and our data emphasize that patients with TLE with CA1 predominant sclerosis may be at risk for severely impaired postoperative memory capacities (Fig. 7). This corresponds well with the clinical observation that high preoperative functional integrity is a risk factor for postoperative memory loss (Hermann *et al.*, 1995). In conclusion, subfield-specific analysis of hippocampal sclerosis may help to better classify TLE phenotypes and clinical variability. With more advanced magnetic resonance technology available, using ultra-high field magnets and resolution for imaging of the human hippocampus, subfield-specific anatomical features may be visualized already during presurgical evaluation (Fatterpekar *et al.*, 2002; Augustinack *et al.*, 2005; Mueller *et al.*, 2009; Das *et al.*, 2011; Bonnici *et al.*, 2012, 2013; Garbelli *et al.*, 2012).

Acknowledgements

We kindly thank T. Jungbauer and B. Rings for their expert technical assistance.

Funding

This work was supported by EpiGENet (DFG BI 421/3-1) and the Johannes and Frieda Marohn Foundation of the Friedrich-Alexander University Erlangen-Nuremberg. The research received also funding from the European Union Seventh Framework Programme FP7/2007-2013 under the project DESIRE (grant agreement n°602531)

References

- Altman J, Bayer SA. Migration and distribution of two populations of hippocampal granule cell precursors during the perinatal and postnatal periods. *J Comp Neurol* 1990a; 301: 365–81.
- Altman J, Bayer SA. Mosaic organization of the hippocampal neuroepithelium and the multiple germinal sources of dentate granule cells. *J Comp Neurol* 1990b; 301: 325–42.
- Altman J, Bayer SA. Prolonged sojourn of developing pyramidal cells in the intermediate zone of the hippocampus and their settling in the stratum pyramidale. *J Comp Neurol* 1990c; 301: 343–64.
- Augustinack JC, van der Kouwe AJ, Blackwell ML, Salat DH, Wiggins CJ, Frosch MP, *et al.* Detection of entorhinal layer II using 7Tesla [corrected] magnetic resonance imaging. *Ann Neurol* 2005; 57: 489–94.
- Bartsch T, Alfke K, Stingele R, Rohr A, Freitag-Wolf S, Jansen O, *et al.* Selective affection of hippocampal CA-1 neurons in patients with transient global amnesia without long-term sequelae. *Brain* 2006; 129 (Pt 11): 2874–84.
- Bartsch T, Dohring J, Rohr A, Jansen O, Deuschl G. CA1 neurons in the human hippocampus are critical for autobiographical memory, mental time travel, and autooetic consciousness. *Proc Natl Acad Sci USA* 2011; 108: 17562–7.
- Bartsch T, Schonfeld R, Muller FJ, Alfke K, Leplow B, Aldenhoff J, *et al.* Focal lesions of human hippocampal CA1 neurons in transient global amnesia impair place memory. *Science* 2010; 328: 1412–5.
- Blumcke I, Coras R, Miyata H, Ozkara C. Defining clinico-neuropathological subtypes of mesial temporal lobe epilepsy with hippocampal sclerosis. *Brain Pathol* 2012; 22: 402–11.
- Blumcke I, Cross JH, Spreafico R. The international consensus classification for hippocampal sclerosis: an important step towards accurate prognosis. *Lancet Neurol* 2013a; 12: 844–6.
- Blumcke I, Thom M, Aronica E, Armstrong DD, Bartolomei F, Bernasconi A, *et al.* International consensus classification of hippocampal sclerosis in temporal lobe epilepsy: a task force report from the ILAE commission on diagnostic methods. *Epilepsia* 2013b; 54: 1315–29.
- Blumcke I, Kistner I, Clusmann H, Schramm J, Becker AJ, Elger CE, *et al.* Towards a clinico-pathological classification of granule cell dispersion in human mesial temporal lobe epilepsies. *Acta Neuropathol* 2009; 117: 535–44.
- Blumcke I, Pauli E, Clusmann H, Schramm J, Becker A, Elger C, *et al.* A new clinico-pathological classification system for mesial temporal sclerosis. *Acta Neuropathol* 2007; 113: 235–44.
- Bonnici HM, Chadwick MJ, Kumaran D, Hassabis D, Weiskopf N, Maguire EA. Multi-voxel pattern analysis in human hippocampal subfields. *Front Hum Neurosci* 2012; 6: 290.
- Bonnici HM, Sidhu M, Chadwick MJ, Duncan JS, Maguire EA. Assessing hippocampal functional reserve in temporal lobe epilepsy: a multi-voxel pattern analysis of fMRI data. *Epilepsy Res* 2013; 105: 140–9.
- Chelune GJ. Hippocampal adequacy versus functional reserve: predicting memory functions following temporal lobectomy. *Arch Clin Neuropsychol* 1995; 10: 413–32.
- Coras R, Siebzehrnubl FA, Pauli E, Huttner HB, Njunting M, Kobow K, *et al.* Low proliferation and differentiation capacities of adult hippocampal stem cells correlate with memory dysfunction in humans. *Brain* 2010; 133: 3359–72.
- Das SR, Mechanic-Hamilton D, Pluta J, Korczykowski M, Detre JA, Yushkevich PA. Heterogeneity of functional activation during memory encoding across hippocampal subfields in temporal lobe epilepsy. *Neuroimage* 2011; 58: 1121–30.
- Du F, Whetsell WJ, Abou Khalil B, Blumenkopf B, Lothman EW, Schwarcz R. Preferential neuronal loss in layer III of the entorhinal cortex in patients with temporal lobe epilepsy. *Epilepsy Res* 1993; 16: 223–33.
- Duvernoy HM, Cattin F, Risold PY. The human hippocampus. Functional anatomy, vascularization and serial sections with MRI. 4th edn. Berlin-Heidelberg: Springer; 2013.
- Engel J. Outcome with respect to epileptic seizures. In: Engel JJ, editor. *Surgical treatment of the Epilepsies*. New York: Raven; 1987. p. 553–71.
- Eriksson PS, Perfilieva E, Bjork-Eriksson T, Alborn AM, Nordborg C, Peterson DA, *et al.* Neurogenesis in the adult human hippocampus. *Nat Med* 1998; 4: 1313–7.
- Fanselow MS, Dong HW. Are the dorsal and ventral hippocampus functionally distinct structures? *Neuron* 2010; 65: 7–19.
- Fatterpekar GM, Naidich TP, Delman BN, Aguinaldo JG, Gultekin SH, Sherwood CC, *et al.* Cytoarchitecture of the human cerebral cortex: MR microscopy of excised specimens at 9.4 Tesla. *AJNR Am J Neuroradiol* 2002; 23: 1313–21.
- Gage FH. Mammalian neural stem cells. *Science* 2000; 287: 1433–8.
- Garbelli R, Milesi G, Medici V, Villani F, Didato G, Deleo F, *et al.* Blurring in patients with temporal lobe epilepsy: clinical, high-field imaging and ultrastructural study. *Brain* 2012; 135 (Pt 8): 2337–49.
- Helmstaedter C, Elger CE. Chronic temporal lobe epilepsy: a neurodevelopmental or progressively dementing disease? *Brain* 2009; 132 (Pt 10): 2822–30.
- Hermann BP, Seidenberg M, Dohan FJ, Wyler AR, Haltiner A, Bobholz J, *et al.* Reports by patients and their families of memory change after left anterior temporal lobectomy: relationship to degree of hippocampal sclerosis. *Neurosurgery* 1995; 36: 39–44.
- Hermann BP, Wyler AR, Bush AJ, Tabatabai FR. Differential effects of left and right anterior temporal lobectomy on verbal learning and memory performance. *Epilepsia* 1992; 33: 289–97.
- Hirst W. The amnesic syndrome: descriptions and explanations. *Psychol Bull* 1982; 91: 435–60.

- Lau JY, Goldman D, Buzas B, Hodgkinson C, Leibenluft E, Nelson E, et al. BDNF gene polymorphism (Val66Met) predicts amygdala and anterior hippocampus responses to emotional faces in anxious and depressed adolescents. *Neuroimage* 2010; 53: 952–61.
- Metzler P, Rudolph M, Voshage J, Nickel B. The concept of amnesia and quantitative assessment of amnesic disorders. *Fortschr Neurol Psychiatr* 1991; 59: 207–15.
- Montine TJ, Phelps CH, Beach TG, Bigio EH, Cairns NJ, Dickson DW, et al. National Institute on Aging-Alzheimer's Association guidelines for the neuropathologic assessment of Alzheimer's disease: a practical approach. *Acta Neuropathol* 2012; 123: 1–11.
- Mueller SG, Laxer KD, Barakos J, Cheong I, Garcia P, Weiner MW. Subfield atrophy pattern in temporal lobe epilepsy with and without mesial sclerosis detected by high-resolution MRI at 4 Tesla: preliminary results. *Epilepsia* 2009; 50: 1474–83.
- Nakashiba T, Cushman JD, Pelkey KA, Renaudineau S, Buhl DL, McHugh TJ, et al. Young dentate granule cells mediate pattern separation, whereas old granule cells facilitate pattern completion. *Cell* 2012; 149: 188–201.
- Narr KL, Thompson PM, Szeszko P, Robinson D, Jang S, Woods RP, et al. Regional specificity of hippocampal volume reductions in first-episode schizophrenia. *Neuroimage* 2004; 21: 1563–75.
- Pauli E, Hildebrandt M, Romstock J, Stefan H, Blumcke I. Deficient memory acquisition in temporal lobe epilepsy is predicted by hippocampal granule cell loss. *Neurology* 2006; 67: 1383–9.
- Rausch R, Babb TL. Hippocampal neuron loss and memory scores before and after temporal lobe surgery for epilepsy. *Arch Neurol* 1993; 50: 812–7.
- Remondes M, Schuman EM. Role for a cortical input to hippocampal area CA1 in the consolidation of a long-term memory. *Nature* 2004; 431: 699–703.
- Rempel-Clower NL, Zola SM, Squire LR, Amaral DG. Three cases of enduring memory impairment after bilateral damage limited to the hippocampal formation. *J Neurosci* 1996; 16: 5233–55.
- Sass KJ, Lencz T, Westerveld M, Novelly RA, Spencer DD, Kim JH. The neural substrate of memory impairment demonstrated by the intracarotid amobarbital procedure. *Arch Neurol* 1991; 48: 48–52.
- Schmidt-Hieber C, Jonas P, Bischofberger J. Enhanced synaptic plasticity in newly generated granule cells of the adult hippocampus. *Nature* 2004; 429: 184–7.
- Small SA, Schobel SA, Buxton RB, Witter MP, Barnes CA. A pathophysiological framework of hippocampal dysfunction in ageing and disease. *Nat Rev Neurosci* 2011; 12: 585–601.
- Stefan H, Hildebrandt M, Kerling F, Kasper BS, Hammen T, Dorfler A, et al. Clinical prediction of postoperative seizure control: structural, functional findings and disease histories. *J Neurol Neurosurg Psychiatry* 2009; 80: 196–200.
- Squire LR. Memory and the hippocampus: a synthesis from findings with rats, monkeys, and humans. *Psychol Rev* 1992; 99: 195–231.
- Thom M, Liagkouras I, Elliot KJ, Martinian L, Harkness W, McEvoy A, et al. Reliability of patterns of hippocampal sclerosis as predictors of postsurgical outcome. *Epilepsia* 2010; 51: 1801–8.
- Trenerry MR, Loring DW. Intracarotid amobarbital procedure. The Wada test. *Neuroimaging Clin N Am* 1995; 5: 721–8.
- Urbach H, Kurthen M, Klemm E, Grunwald T, Van Roost D, Linke DB, et al. Amobarbital effects on the posterior hippocampus during the intracarotid amobarbital test. *Neurology* 1999; 52: 1596–602.
- Vago DR, Bevan A, Kesner RP. The role of the direct perforant path input to the CA1 subregion of the dorsal hippocampus in memory retention and retrieval. *Hippocampus* 2007; 17: 977–87.
- van Praag H, Schinder AF, Christie BR, Toni N, Palmer TD, Gage FH. Functional neurogenesis in the adult hippocampus. *Nature* 2002; 415: 1030–4.
- van Strien NM, Cappaert NL, Witter MP. The anatomy of memory: an interactive overview of the parahippocampal-hippocampal network. *Nat Rev Neurosci* 2009; 10: 272–82.
- Wada J, Rasmussen T. Intracarotid injection of sodium amytal for the lateralisation of cerebral speech dominance: experimental and clinical observations. *J Neurosurg* 1960; 17: 266–82.
- Watson C, Nielsen SL, Cobb C, Burgerman R, Williamson B. Pathological grading system for hippocampal sclerosis: correlation with magnetic resonance imaging-based volume measurements of the hippocampus. *J Epilepsy* 1996; 9: 56–64.
- Wieser HG. ILAE Commission Report. Mesial temporal lobe epilepsy with hippocampal sclerosis. *Epilepsia* 2004; 45: 695–714.
- Wolf HK, Buslei R, Schmidt Kastner R, Schmidt Kastner PK, Pietsch T, Wiestler OD, et al. NeuN: a useful neuronal marker for diagnostic histopathology. *J Histochem Cytochem* 1996; 44: 1167–71.
- Wyler AR, Dohan FC, Schweitzer JB, Berry AD. A grading system for mesial temporal pathology (hippocampal sclerosis) from anterior temporal lobectomy. *J Epilepsy* 1992; 5: 220–5.
- Yassa MA, Lacy JW, Stark SM, Albert MS, Gallagher M, Stark CE. Pattern separation deficits associated with increased hippocampal CA3 and dentate gyrus activity in nondemented older adults. *Hippocampus* 2011; 21: 968–79.
- Yilmazer-Hanke DM, Wolf HK, Schramm J, Elger CE, Wiestler OD, Blumcke I. Subregional pathology of the amygdala complex and entorhinal region in surgical specimens from patients with pharmacoresistant temporal lobe epilepsy. *J Neuropathol Exp Neurol* 2000; 59: 907–20.
- Zola-Morgan S, Squire LR, Amaral DG. Human amnesia and the medial temporal region: enduring memory impairment following a bilateral lesion limited to field CA1 of the hippocampus. *J Neurosci* 1986; 6: 2950–67.