

Tension pneumopericardium after removal of pericardiocentesis drainage catheter

Hye Ryun Kim¹, Donghoon Choi^{1,2}, Joo Won Chung¹,
Young Nam Youn³, Chi Young Shim^{1,2}

¹Department of Internal Medicine, Yonsei University College of Medicine, Seoul, Korea

²Division of Cardiology, Yonsei Cardiovascular Hospital, Seoul, Korea

³Department of Cardiovascular Surgery, Yonsei University College of Medicine, Seoul, Korea

Abstract

This image showed tension pneumopericardium caused by removing the pericardiocentesis catheter, which was inserted to drain malignant pericardial effusion. Tension pneumopericardium is a rare and potentially fatal event. Mortality from tension pneumopericardium can be as high as 50%. Therefore, it is important to suspect and detect early, if the patient complained of dyspnea after removing the pericardiocentesis drainage catheter. (Cardiol J 2009; 16, 5: 477–478)

Key words: tension pneumopericardium pericardiocentesis

A 44 year-old female patient diagnosed with advanced gastric cancer with multiple metastases was admitted to our hospital with shortness of breath which had lasted for two months. Chest X-ray revealed cardiomegaly and electrocardiogram showed sinus tachycardia (100 bpm) with low voltage QRS complex. A two-dimensional (2D) echocardiogram showed large amount of malignant pericardial effusion (4.7 cm at apical view) and Doppler findings revealed with tamponade physiology. So, emergency pericardiocentesis was performed without complication. After 12 days, we removed the drainage catheter, because the amount of pericardial fluid was decreased and symptoms were relieved. After ten hours, the patient suddenly developed dyspnea and her systolic blood pressure fell below 70 mm Hg. At that time, chest X-ray revealed that two obvious radiolucent areas along heart borders suggesting pneumopericardium (Fig. 1). Computerized tomography showed that the bilateral air space in the pericardium implicated pneumopericardium (Fig. 2). Besides, she had tamponade resulting from the progressive accumulation of

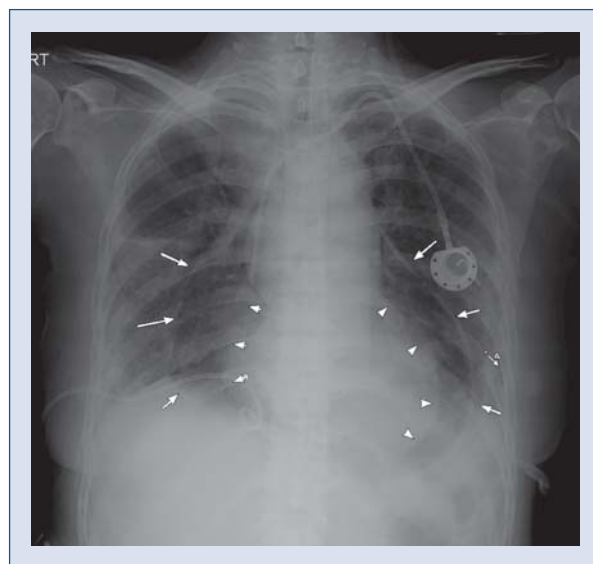


Figure 1. The chest X-ray showed two obvious radiolucent areas (arrow and arrow head) along both heart borders, suggesting accumulation of air in pericardium space (pneumopericardium). The catheter in this picture was placed in the pleural space to remove malignant pleural effusion.

Address for correspondence: Chi Young Shim, MD, Division of Cardiology, Yonsei Cardiovascular Center, Yonsei University College of Medicine, 250 Seongsanno, Seodaemun-Ku, Seoul, Korea, 120-752, tel: 82 2 2228 8453, fax: 82 2 393 2041, e-mail: cysprs@yuhs.ac

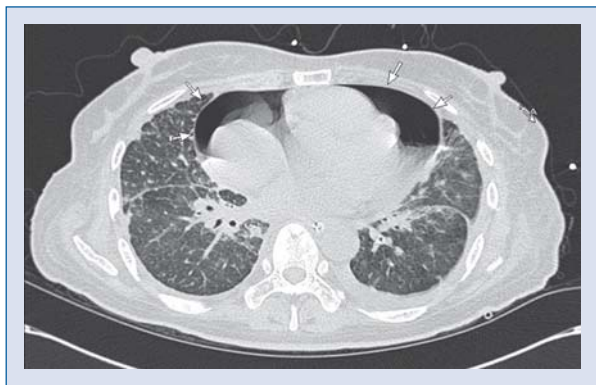


Figure 2. Computerized tomography showed pneumopericardium (arrow) but no pneumothorax. The interlobular septal thickening and bronchovascular bundle thickening implicated lymphangitic metastasis.

air with uncorrectable hypotension along atrial fibrillation. So, we decided to do emergency window formation and inserted tube 17 Fr to remove air within pericardium sac. Even though the pneumopericardium was relieved, she died from rapidly developing acute respiratory distress syndrome.

To the best of our knowledge, there have been few reports of pneumopericardium after removing pericardiocentesis catheter. Some reports show pneumopericardium was related to procedures such as endomyocardial biopsy, lung transplantation, pacemaker placement, chest crushing, blunting trauma and mechanical ventilation, etc. The cause of pneumopericardium has been thought the formation of broncho-pericardial fistula [1]. But we cannot know the exact cause of pneumopericardium in this patient. Mortality from tension pneumopericardium is about 50% [2]. Therefore, it is necessary to consider pneumopericardium in patients complaining of dyspnea and hypotension after removing their catheter.

Acknowledgements

The authors do not report any conflict of interest regarding this work.

References

1. Braiteh F, Malik I. Pneumopericardium. *CMAJ*, 2008; 179: 1087.
2. Haan JM, Scalea TM. Tension pneumopericardium: A case report and a review of the literature. *Am Surg*, 2006; 72: 330–331.