

SHORT REPORT

Hyperfibrinolysis during intracranial surgery: effect of high dose aprotinin

James D Palmer, Debby A Francis, O Stuart Roath, John L Francis, Fausto Iannotti

Abstract

A patient undergoing intracranial surgery developed disseminated intravascular coagulation with life threatening perioperative bleeding. Thromboelastography established the diagnosis of hyperfibrinolysis, usually a fatal complication of a neurosurgical operation. With the administration of a high dose regimen of aprotinin (Trasylol®) the haemorrhage was controlled and the hyperfibrinolytic state reversed. Evaluation of blood samples from the jugular bulb suggested that there was a pronounced local release of tissue plasminogen activator into the circulation.

(*J Neurol Neurosurg Psychiatry* 1995;58:104-106)

Keywords: hyperfibrinolysis; intracranial surgery; aprotinin

The changes in haemostasis during an operation have been extensively investigated in cardiac bypass surgery¹ and liver surgery.² Although excessive blood loss in neurosurgery may significantly affect morbidity and mortality, very few studies have dealt with changes in haemostasis during intracranial surgery. The brain is a major source of the potent procoagulant tissue factor³ and certain types of brain tumour, such as meningioma and glioblastoma, have been found to be rich in tissue plasminogen activator.⁴ In theory, therefore, considerable initiation of clotting and fibrinolysis may occur during surgery for a cerebral tumour. High local concentrations of tissue plasminogen activator may result in rapid clot lysis and local release of tissue factor could induce local consumptive coagulopathy.

The local haemostatic events during various intracranial operations are currently under investigation at the Wessex Neurological Centre. We report here a patient who developed disseminated intravascular coagulation. Aprotinin (Trasylol®) is now in regular use in cardiac surgery for reduction of surgical bleeding⁵ and is currently under trial for neurosurgery. The novel use of aprotinin for the control of disseminated intravascular coagulation described here is supported by evidence from molecular

markers of haemostasis and fibrinolysis and from thromboelastography.

Methods

A 68 year old man was admitted to the Wessex Neurological Centre with focal partial seizures and the subsequent development of a flaccid hemiparesis. Computed tomography showed evidence of a tumour, which had spontaneously haemorrhaged into the surrounding brain parenchyma. With ethical approval and the patient's consent a catheter was placed, under radiographical control, from the right femoral vein and passed to just below the jugular bulb to sample blood draining directly from the brain. After placement of the catheter the patient was taken to the operating theatre for a craniotomy.

Blood samples were drawn from the jugular catheter and from the radial artery immediately before operation, during the operation, and two hours afterwards just before the jugular catheter was removed. Further samples were collected from a peripheral vein one and five days after the operation. Samples were treated with citrate and separated by centrifugation at 3000 rpm for 10 minutes, and the plasma was frozen at -70°C.

Thromboelastography was performed on each sample with a recalcified, celite activated, technique and a computerised instrument (Launch Diagnostics, Longfield, UK). Tissue plasminogen activator was measured with the Asserachrom t-PA ELISA (Diagnostica Stago), soluble tissue factor with the Imubind® tissue factor enzyme linked immunosorbent assay (ELISA) kit (American Diagnostica Inc, Greenwich, CT, USA), prothrombin F1 + 2 with the Enzygnost® F 1 + 2 micro (Behring, Somerville, NJ, USA), and total fibrin(ogen) degradation products with the Fibrinostika® TDP microelisa system (Organon Teknika, Durham, NJ, USA).

Results

After the craniotomy and once the dura was opened, the tumour haemorrhaged acutely into the brain parenchyma rupturing the brain surface. The haematoma was evacuated, the tumour identified and biopsied, and

Southampton
University Hospitals,
Southampton
SO9 4XY, UK

Clinical Neurological
Sciences

J D Palmer
F Iannotti

University
Department of
Haematology
D A Francis
O S Roath
J L Francis

Correspondence to:
Dr J D Palmer, Room
LF 73 South Academic
Block, Southampton
General Hospital, Tremona
Road, Southampton SO9
4XY, UK.

Received 14 March 1994
and in revised form
17 June 1994.
Accepted 27 June 1994

Tissue factor, prothrombin F1·2, tissue plasminogen activator, and total fibrin(ogen) degradation products in arterial and jugular blood

Sample site	Preoperative		Peroperative		2 hours postoperative		1 day postoperative	5 days postoperative	Normal
	Art	Jug	Art	Jug	Art	Jug			
TF (pg/ml)	61·4	29·9	34·6	10·6	48	26	2	0	
P F1 + 2 (ng/ml)	3·20	1·98	9·0	3·3	8·8	8·2	6·85	ND	< 1·5
tPA (ng/ml)	14·2	11·1	32·7	73·2	ND	35·3	12·1	13·0	< 12·0
TDPs (ng/ml)	6970	5345	85 235	37 674	40 200	39 500	3568	3613	< 650

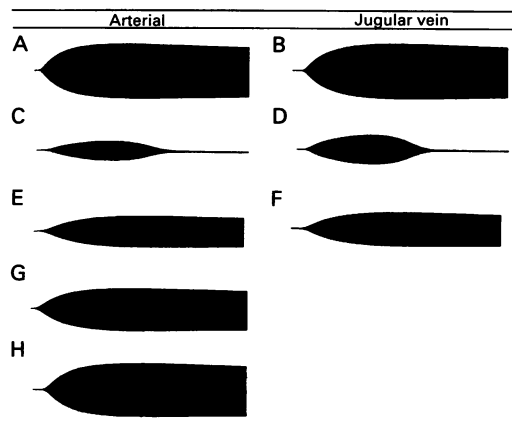
Art = arterial; Jug = jugular; ND = not done; TF = tissue factor; P F1 + 2 = prothrombin F1 + 2; tPA = tissue plasminogen activator; TDPs = total fibrin(ogen) degradation products.

later determined to be a glioblastoma multiforme. The brain tissue continued to haemorrhage, further surgical excision of the tumour was not possible, and the procedure was abandoned. Once the results of the peroperative thromboelastography (see later) were available 30 000 KIU per kg aprotinin (Bayer AG, Leverkusen) was given intravenously followed by 10 000 KIU per kg per hour for the subsequent six hours. The clinical picture of disseminated intravascular coagulation with spontaneous bleeding from the nasopharynx, venous cannulation, and venepuncture sites was controlled within 30 minutes. The patient was transferred back to the district hospital on the eighth postoperative day in a drowsy state but with no increased neurological deficit. He died three months later of his brain tumour.

THROMBOELASTOGRAPHY

The preoperative thromboelastography (figure (A, B)) maximal amplitude was below normal in arterial and jugular bulb blood (39·0 and 41·0 mm respectively). The peroperative sample (figure (C, D)) strikingly demonstrated acute hyperfibrinolysis with pronounced narrowing of the amplitude and 50% lysis at 30 minutes. The postoperative thromboelastography after high dose aprotinin (figure (E, F)) showed complete correction of the clot lysis and partial correction of the maximal amplitude. The trace further improved one day after the operation (figure (G)) and had returned to the preoperative state by day 5 (figure (H)).

Thromboelastography on arterial and jugular vein blood by the recalcified, celite activated technique. (A) and (B) preoperative; (C) and (D) peroperative during haemorrhagic crisis; (E) and (F) two hours postoperative after aprotinin loading dose; (G) 24 hours after operation; (H) five days after operation.



TISSUE FACTOR

Preoperatively the concentration of circulating tissue factor was 62 pg/ml. During the operation this fell to 34·6 pg/ml in arterial blood and to 10·6 pg/ml in jugular blood. The fall continued postoperatively with no detectable circulating tissue factor present by day 5 (table).

PROTHROMBIN F1 + 2

This marker of thrombin generation was raised in arterial blood preoperatively (table). It rose considerably during the procedure and remained above the normal value at 24 hours. Jugular blood showed consistently lower concentrations.

TISSUE PLASMINOGEN ACTIVATOR

Slightly raised above normal preoperatively, tissue plasminogen activator concentration rose considerably during the procedure, particularly in jugular blood. By 24 hours it had returned to normal.

TOTAL FIBRIN(OGEN) DEGRADATION PRODUCTS

Total fibrin(ogen) degradation products were raised preoperatively and rose during the operation, falling below preoperative concentrations by 24 hours postoperatively. During the operation the arterial concentration rose above that of jugular blood, but by two hours postoperation the concentrations in jugular and arterial blood were about equal.

Discussion

The data collected from this patient suggest the development of disseminated intravascular coagulation during brain surgery. Major coagulopathy is an infrequent but often catastrophic complication of intracranial pathology.⁶ In the patient reported here the presence of plasma tissue factor preoperatively and increase in prothrombin F1+2 indicated that activation of coagulation was present before the operation. Disruption of the blood brain barrier and exposure of brain tissue factor to circulating blood might lead to activation of coagulation. During the operation, however, the tissue factor concentrations fell and postoperatively were minimal by day 5. The major component in this patient's coagulopathy was the activation of fibrinolysis. During the procedure, tissue plasminogen activator concentrations in jugular blood were twice those in arterial blood

suggesting that tissue plasminogen activator was being released into the circulation by the cerebrovascular endothelium. The total fibrin(ogen) degradation products and prothrombin F1 + 2 at the same time were much higher in arterial blood indicating that greater activation of coagulation and fibrinolysis was occurring in the periphery than in the cerebral circulation. The reversal of the clinical coagulopathy as well as the hyperfibrinolysis seen on thromboelastography by aprotinin, a plasmin inhibitor, is important, particularly in neurosurgery where full anticoagulation with heparin to treat disseminated intravascular coagulation may add to the risks of intracranial haematoma. Our results suggest that aprotinin may be useful in the treatment of acute disseminated intravascular coagulation associated with neurosurgery.

This study was funded by the Wessex Regional Health Authority.

- 1 Kalter RD, Saul CM, Wetstein L, Soriano C, Reiss RF. Cardiopulmonary bypass-associated hemostatic abnormalities. *J Thorac Cardiovasc Surg* 1979;77:427-35.
- 2 Kratzer MAA, Dietrich J, Denecke H, Knedel M. Hemostatic variables and blood loss during orthotopic human liver transplantation. *Transplant Proc* 1991;23:1906-11.
- 3 Brozna JP. Cellular regulation of tissue factor. *Blood Coagul Fibrinolysis* 1990;1:415-26.
- 4 Sawaya R, Ramo OJ, Shi ML, Mandybur G. Biological significance of tissue plasminogen activator content in brain tumours. *J Neurosurg* 1991;74:480-6.
- 5 Bidstrup BP, Royston D, Sapsford RN, Taylor KM. Reduction in blood loss and blood use after cardiopulmonary bypass with high dose aprotinin (Trasyol). *J Cardiovasc Surg (Torino)* 1989;97:364-72.
- 6 Kaufmann HH, Moake JL, Olson JD. Delayed and recurrent intracranial hematomas related to disseminated intravascular clotting and fibrinolysis in head injury. *Neurosurgery* 1982;7:445.



Hyperfibrinolysis during intracranial surgery: effect of high dose aprotinin.

J D Palmer, D A Francis, O S Roath, J L Francis and F Iannotti

J Neurol Neurosurg Psychiatry 1995 58: 104-106
doi: 10.1136/jnp.58.1.104

Updated information and services can be found at:
<http://jnp.bmj.com/content/58/1/104>

Email alerting service

These include:

Receive free email alerts when new articles cite this article. Sign up in the box at the top right corner of the online article.

Notes

To request permissions go to:
<http://group.bmj.com/group/rights-licensing/permissions>

To order reprints go to:
<http://journals.bmj.com/cgi/reprintform>

To subscribe to BMJ go to:
<http://group.bmj.com/subscribe/>