

# A history of materials and practices for wound management

Daunton C, Kothari S, Smith L & Steele D

## Abstract

From a spiritual vessel to an extremely intricate system, the human body has slowly become less mysterious to us. As civilisation and technology evolved, the teachings, methodology and materials used in the care of both acute and chronic wounds have grown, both in sophistication and in variety. This article provides a brief overview of some of the methods employed by healers throughout history to enhance the wound healing process as well as an overview of current materials available.

*Keywords:* wound dressings, healing, history, smart dressing.

## Introduction

Throughout history, from the ridiculous to the ingenious, various interventions have been utilised to enhance healing in acute wounds and to overcome the unique challenges posed by chronic wounds. As medicine shifted from the realm of the spiritual to the scientific, so did the need to understand the outcomes of medical intervention. This review examines the biochemical mechanisms behind wound healing in acute and chronic wounds, and discusses the types of materials used to enhance healing and stave off infection.

Upon wounding, damage occurs to the epidermis, the local vasculature and possibly the dermis and underlying tissues, depending on the depth of the wound. This creates a potential threat to the integrity of the organism as it allows entry by pathogens, as well as blood loss<sup>1,2</sup>. Wounding sets off an intricate cascade of biological events that stimulates the healing response<sup>3</sup> and results in the restoration of the barrier function of skin, destruction and removal of any invading pathogens and foreign debris, restoration of the local vasculature and tissues and, finally, remodelling of the injury site to more closely resemble uninjured tissue. Wound healing concludes with up to 80% original tensile strength being restored to the site<sup>1,4-6</sup>. Wound healing involves four tightly regulated overlapping phases: haemostasis (formation of the fibrin clot); inflammation (the body's immune response); proliferation or re-epithelialisation (cell migration and wound closure); and remodelling (reorganisation of the disorganised extra cellular matrix to more closely resemble uninjured tissue) as shown in Figure 1.

While modern investigations have provided much information regarding the wound healing process<sup>7,8</sup>, the obvious indicators of healing have been known since ancient times, along with contraindications such as infection and chronicity. In order to ensure a wound healed properly, a wide range of practices and materials were used throughout history. These interventions were in line with the perceived best practice of the day, some examples of which are presented below.

## Materials used in wound care – ancient history

The earliest known record of the treatment of wounds was found on clay tablets of Mesopotamian origin from about 2500 BCE<sup>9</sup>. Wound care was thought to have come about through trial and error, with primitive cultures employing age-old techniques and wisdom<sup>9</sup>. Wound care in ancient

### Ms Carla Daunton

The Mawson Institute, University of South Australia, Mawson Lakes Campus, Mawson Lakes, Adelaide, SA

### Dr Sherry Kothari

The Mawson Institute, University of South Australia, Mawson Lakes Campus, Mawson Lakes, Adelaide, SA

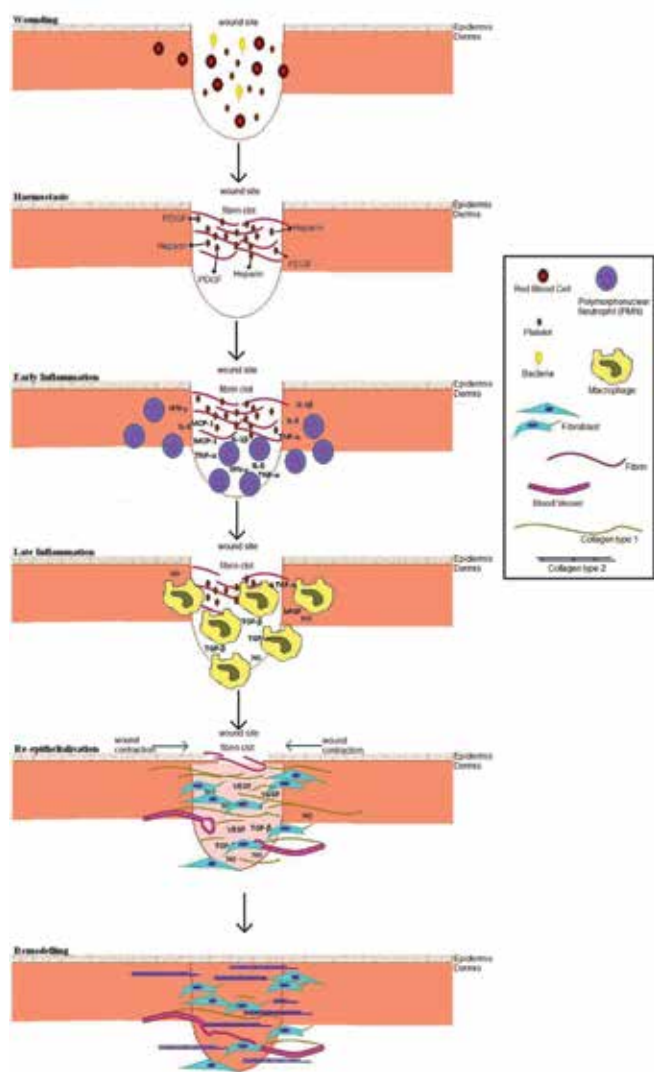
### Dr Louise Smith

The Mawson Institute, University of South Australia, Mawson Lakes Campus, Mawson Lakes, Adelaide, SA

### Dr David Steele\*

The Mawson Institute, University of South Australia, Mawson Lakes Campus, Mawson Lakes, Adelaide, SA  
Email david.steele@unisa.edu.au

\*Corresponding author



**Figure 1. Schematic of normal wound healing:** wounding stimulates fibrin clot formulation restoring haemostasis; platelets degranulate releasing cytokines and growth factors. Early inflammation follows with infiltration of neutrophils from local tissues; vasodilation in late inflammation occurs, allowing increased blood flow and immune cells such as macrophages to migrate into the area. Re-epithelialisation results in new vasculature and proliferation and migration of keratinocytes, remodelling sees a reorganisation of the ECM and replacement of collagen type 1 to collagen type 2, increasing strength and order of the tissue.

Egypt had a spiritual basis: the open wound was seen as a possible entry point for mischievous entities, thus requiring the use of a repellent, in the form of faeces from donkeys to pack the wound, to ensure the integrity of the spiritual vessel<sup>10</sup>. Although repugnant, this intervention is said to have contained a number of antibiotic substances and proteins such as trypsin that may have aided healing<sup>10</sup>. Other interventions involved the use of adhesive tape and gauze bandaging to close a cleanly cut wound, while some wounds were left open and covered with fresh meat on the first day,

followed by treatment with astringents, herbs and honey<sup>9,10</sup>. Mouldy bread was used as an antibiotic and a number of herbs and minerals were utilised when inflammation and infection were present<sup>10-12</sup>. Mesopotamians washed wounds with milk or water before dressing with honey or resin<sup>11</sup>. Hippocrates of ancient Greece (460–370 BCE) advocated the use of wine or vinegar for washing wounds with honey, oil and wine as further treatments<sup>11,13</sup>. Wool boiled in water or wine was considered to be an appropriate bandage<sup>11,13</sup>.

Homer, in his epic, *Iliad*, (800 BCE), wrote of the treatment of numerous battle wounds sustained during the battle of Troy and described 130 wounds<sup>14,15</sup>. Galen (131–201 ACE), physician to the Greek Emperor Marcus Aurelius after gaining fame as a surgeon to the gladiators in Pergamos<sup>13</sup>, wrote of applying styptics that contained elements with antibiotic properties as well as postulating developments in a range of treatments for haemorrhage. Although he is generally seen to have had a negative effect on the progress of medicine, due to the Christian church adopting his writings as an absolute truth during the Middle Ages, Galen's experimentation and observation facilitated significant developments in surgical suturing and anatomy<sup>12-14</sup>, even though his approach to wound healing still relied on materials such as gauze for bandaging.

The holistic approach of traditional Chinese medicine, similar to other ancient cultures, has changed little over the centuries. Chinese medicine addresses the spiritual and physical aspects of the human body. Bronze instruments, green tea, liquorice, soaked mushrooms, anaesthetics, soporific drugs, antiseptics and other herbal powders have been utilised to promote granulation tissue, aid in debridement and help stave off infection. Both gauze and silk have been used to bandage and acupuncture has been heavily utilised for a wide range of ailments<sup>11,16-18</sup>.

## Materials used in wound care – modern era

### Gauze

The use of gauze to dress and bandage wounds has its origins in ancient times, having been firmly established by the fifth century BCE and is still in use today<sup>11,19</sup>. The term 'gauze' represents two types of bandaging material: woven gauze is the 100% natural cotton cloth that we are most familiar with. Non-woven gauze refers to more modern, synthetic dressings made of rayon or synthetic fibre blends<sup>11,19</sup>.

Woven gauze is problematic in dressing and packing wounds as it sheds fibres when cut and may leave debris in the wound bed when removed. It is also absorbent and tends to stick to the wound, resulting in trauma upon removal as it quickly dries out the wound, becoming trapped within the eschar. Until recently, this was considered advantageous as a dry wound was considered optimal for healing and the

removal of the embedded dry eschar was seen as a form of physical debridement<sup>19</sup>. The perception that a wound was best healed under dry conditions persisted from the times of Hippocrates until relatively recent research promoted the maintenance of a moist wound environment<sup>19-22</sup>. This research began with Winter and the 1962 investigation in a pig model which concluded that moist wounds healed faster than dry wounds<sup>23,24</sup>. Gauze strips soaked in antibiotics such as EUSOL, proflavin or chlorhexidine were used to pack wounds to prevent closure and promote granulation from the wound base. This was subsequently changed to saline-soaked gauze because the use of antibiotics in this fashion was thought to be potentially cytotoxic. Saline was employed as a hypertonic solution but quickly dried out, resulting in painful removal<sup>19,25,26</sup>.

Today, woven gauze is seen as a 'wet to dry' dressing and utilised in a range of wound care strategies. Despite its non-selective mode of physical debridement, trauma to the wound bed and resultant pain, it is still the most utilised wound dressing in the world<sup>26,27</sup>. It is also utilised as a vehicle for antimicrobial agents but presents complications such as degradation or inactivation of the antimicrobial agent upon exposure to the high protein levels within wound fluid and lateral bacterial migration into the wound bed within the moist environment<sup>28,29</sup>. Factors such as cost, education and the ability to follow best practice are thought to determine selection of wound dressings and may account for continued use of this ancient product, seemingly surpassed by modern dressings<sup>19,27,29</sup>.

Although gauze is commonly used, a range of more appropriate dressings has been available for a number of years. These dressings employ many technological advancements and exhibit qualities considered to be essential in the 'perfect' wound dressing such as: the ability to maintain a moist wound environment while preventing maceration of surrounding tissue; non-adherent and atraumatic; thermally insulating and gas-permeable; antibiotic and non-toxic<sup>30</sup>. Although the perfect dressing is yet to be developed, wound dressings have evolved from simple, impregnated gauzes to being 'smart'; an overview of this evolution is described below.

## Advancements in the 20th century

The problem of adherent dressings was first noticed during World War I. Lumiere developed the first non-adherent dressing which consisted of two layers<sup>27</sup>: The first was a cotton mesh containing paraffin and a balsam for contact with the wound, while the second comprised gauze which enabled drainage<sup>27</sup>. This multilayer format continues to form the basis for advancements today, where each layer performs a specific function, that is, one layer for mechanical integrity and a second layer for fluid absorption<sup>27,30-33</sup>.

## Semi-permeable films

World War II triggered further advancements in medicine, with the development of the first alternative to gauze through the work of Bloom<sup>19,30,34</sup>. He utilised sterilised cellophane packaging, from blood transfusion equipment, to dress burn wounds while in a prisoner of war camp. He observed increased healing rates and decreased pain immediately after application of the cellophane<sup>34</sup>. He also noted that the wound healed under a thin layer of serum and that the dressing was water-permeable<sup>19,30,34</sup>.

The war also saw the use of adherent, non-porous, plasticised polyvinyl polymer films coupled with cotton-lint pads in first aid. Current semi-permeable films allow gas and water exchange while preventing bacterial migration into the wound bed. A commonly used example is the BAND-AID® brand, which began manufacturing adhesive bandages in 1920 after an employee of Johnson & Johnson, Earle Dickson, produced a prototype bandage to enable his wife to dress her wounds without assistance. Johnson & Johnson introduced sterile bandages in 1938<sup>30,35</sup>. Several dressings were developed and underwent rigorous clinical trials. Some proved to be efficacious in facilitating wound healing, but were subsequently abandoned. One recent example is polyamide film, which was shown to reduce healing time but was expensive, rigid and difficult to coat with the required adhesive<sup>30,36</sup>.

## Calcium or calcium/sodium alginate

Calcium alginate was developed by Blaine in 1947 as a soluble dressing and has since been manufactured into fibres, films and foams for use in surgery and wound dressings<sup>37</sup>. Calcium alginate is comprised of a natural polymer extracted from brown seaweed<sup>37,38</sup>. In their first applications, they dried out to form a hard mass, which then posed similar risks to that of woven gauze in that further trauma is inflicted upon removal unless moistened first. Alginates are applied dry and form a gel on absorbing excess wound exudate. As they are fibrous in structure, they can leave residual debris in the wound bed if the exudate is insufficient to gel the fibres and the dressing may require further moistening as failure to do so may lead to infection. They also require a second dressing to be used in adjunct. However, their ability to absorb excess exudate aids in the prevention of maceration of surrounding healthy tissue and they can be sterilised by autoclaving. The wide range of alginates currently on the market is safe to use when employed correctly<sup>30,38,39</sup>.

## Spray-on dressings

Olow and Hogeman<sup>40</sup> and Wallgren<sup>41</sup> investigated the use of Nobecutane, which is a spray-on formulation of acrylic resin dissolved in a mixture of acetic esters. It forms a thin plastic film upon evaporation of its organic solvent<sup>42</sup>. However,

the authors found that it was difficult to maintain a seal between the film and skin as a result of bleeding due to a possible haemolysing or vasodilating effect from the solvent or accumulated exudate, resulting in consequent infection<sup>43</sup>. Despite this, subsequent trials found that Nobecutane and other spray-on dressings were useful in reducing infection rates in facial and scrotal surgeries as well as in abdominal surgery where the application of traditional dressings was difficult<sup>30</sup>. Currently, spray-on dressings are commercially available to the public as an appropriate first aid response for superficial acute wounds (for example, Elastoplast®).

### Hydrocolloids

Hydrocolloid dressings, first developed in 1982, consist of an inner layer of hydrophilic gel made from gelatin, pectin, sodium carboxymethylcellulose and polyisobutylene, backed by a film, forming a flexible wafer dressing<sup>19,27,44</sup>. These occlusive dressings have been shown to provide a moist, hypoxic wound environment which promotes autolytic debridement<sup>27</sup>. They also allow gas exchange and are semi-permeable to vapour but may cause maceration if used on heavily exuding wounds, although it's been suggested that the application of a hydrocolloid dressing may reduce the amount of exudate produced by a wound<sup>27,45,46</sup>. Various specific types of hydrocolloid dressings have come to market, but while they differ in size, shape, exudate absorption and intended use, their basic mode of action remains the same<sup>46</sup>.

### Hydrogels

Hydrogels consist of cross-linked polymers such as starch, cellulose or other plant- or animal-derived polysaccharides and contain up to 96% water<sup>47,48</sup>. They can provide moisture to dry wounds as well as absorb excess exudate, depending on moisture levels at the wound and are atraumatic when used correctly<sup>29</sup>. Hydrogels also facilitate the autolysis of necrotic tissue, and do not support bacterial growth but their use is limited to dry and low exuding wounds as they can cause maceration to surrounding tissues when higher volumes of wound exudate are present<sup>44</sup>. There is also a risk that when used on exuding ischaemic ulcers their use can result in a shift from dry to wet gangrene within the wound<sup>49</sup>. Interestingly, one group has recently reported some active antimicrobial and antifungal properties in a hydrogel dressing based on polyvinylpyrrolidone/polyethylene glycol polymers<sup>48,49</sup>. Hydrogels are available in a variety of formats such as sheets, gels and beads which enable a tailored application to individual wounds. Hydrogels are utilised for the treatment of burns, chronic ulcers, surgical wounds and even injected into the spinal column<sup>50</sup>.

### Foams

Polyurethane foam dressings are easy to use and customise as they can be cut to shape and come in a range of absorbencies.

They are designed to absorb excess wound exudate while maintaining a moist wound interface and providing thermal insulation. They also prevent maceration of surrounding healthy tissue and facilitate the removal of slough<sup>51</sup>. A range of foam dressings exists with some incorporating other components to enhance absorbance, control infection or ensure atraumatic removal. These impregnated foams are used for a wide range of applications in both acute and chronic wounds, including post-surgical dressing, application on heavily exuding wounds or for packing deep cavity wounds<sup>36,45,47</sup>.

### Silicone dressings

Silicone is used either as a contact dressing<sup>52</sup> or as the contact layer within a dressing, for example, Mepilex, a polyurethane foam membrane coated with a soft silicone layer<sup>52</sup>. It is also used as a coating on materials like non-woven polyester nets<sup>53</sup>. In negative pressure therapy, silicone-coated polyester enhances healing rates in sheep models and may assist in the prevention of hypertrophic scarring when combined with pressure therapy<sup>53,54</sup>. Dressings incorporating soft silicone contact layers adhere to dry skin while remaining non-adherent to the wound site, resulting in atraumatic removal and a decreased risk of damage to the wound site upon dressing changes<sup>52,55</sup>. Silicone can be used on a range of acute and chronic wounds as it is incorporated in many different bandaging strategies (Table 1).

### Capillary action dressings

Capillary action dressings incorporate an absorbent pad of hydrophilic fibres, typically comprising 80% polyester, 20% cotton fibres between two layers of perforated, permeable, non-woven polyester. Exudate is removed from the wound by capillary action and the excess is spread laterally through the absorbent pad along a capillary pressure gradient, preventing tissue maceration. These dressings decrease bacterial load on the wound surface, assist in debridement and desloughing, but may adhere to wounds with low levels of exudate, resulting in traumatic removal. They are best used in conjunction with a non-adherent contact layer and are not recommended for arterial or heavily bleeding wounds<sup>36,39,56-58</sup>.

### Odour-absorbent dressings

The use of a charcoal cloth to address malodour was first reported by Butcher *et al.* in 1976. Odour in a wound is primarily produced from anaerobic bacteria, and whilst the initial line of management should be infection control, it is often advantageous to incorporate an odour-absorbing dressing into the treatment protocol<sup>59</sup>. These dressings use charcoal or activated carbon to absorb odour from the wound and are often used in conjunction with absorbent secondary dressings. The odour-causing molecules are retained by the carbon<sup>44,59</sup> and charcoal is shown to retain bacteria;

Table 1. Examples of dressings with pros and cons of use.

Dressing type	Trade name	Materials used	Pros	Cons	Refs
Gauze	Kerlix	Cotton fibres.	Cheap, accessible, physical debridement, impregnable.	Sheds fibres, traumatic removal, lateral bacterial migration.	11, 19, 22–26
Semi-permeable film	BAND-AID®	Non-porous, plasticised polyvinyl polymer.	Sterilisable, maintains moist environment, prevents bacterial migration.	May not prevent maceration.	19, 30, 34–36
Calcium alginate	CURASORB	Polymer extracted from seaweed.	Absorbs excess moisture, prevents maceration, sterilisable.	Can shed fibres, requires moisture to ensure atraumatic removal, not suitable for dry wounds, requires a secondary dressing.	30, 37–39
Hydrogel	Skintegrity hydrogel dressing	Cross-linked polymers such as starch, cellulose or other plant- or animal-derived polysaccharide.	Can provide moisture to dry wounds as well as absorb excess exudate depending. Atraumatic when used correctly. Facilitates autolysis of necrotic tissue, and does not support bacterial growth.	Only suitable for low exuding wounds or dry wounds. Can cause maceration in heavily exuding wounds, can shift from dry to wet gangrene in exuding ischaemic ulcers.	47–50
Hydrocolloid	Medi-Pak Performance hydrocolloid dressing	Gelatin, pectin, sodium carboxymethylcellulose and polyisobutylene.	Provides a moist, hypoxic wound environment.	Does not prevent maceration in heavily exuding wounds.	19, 27, 44–46
Spray-on	Nobecutane	Acrylic resin dissolved in acetic esters.	Appropriate first aid, reduces infection in some surgeries.	Possibly haemolysing, difficult to achieve an even coating.	40–43
Foam	Tegaderm foam dressing	Polyurethane	Cut to shape, thermally insulating, provides moist interface, absorbs excess exudate, impregnable.	Not suitable for dry wounds.	36, 45, 47, 51
Capillary action	Vacutex	80% polyester with 20% cotton fibres, between two layers of perforated, permeable, non-woven polyester.	Decreases bacterial load on wound surface, assists in debridement and desloughing, prevents maceration.	Adheres to wounds with low exudate, possible traumatic removal. Adjunct contact layer required for arterial or heavily bleeding wounds.	36, 39, 56–58
Odour absorbent	Carbonet	Incorporated charcoal or activated carbon layer within dressing.	Retains odour-causing molecules and bacteria, impregnable with antimicrobial agents.	Efficacy to retain odour and absorb exudate varies.	45, 59, 60
Scaffold – natural material	Alloderm (dermal substitute)	Acellular de-epithelialised cadaver dermis.	Biocompatible, degradable, and is low in antigenicity.	Collagen may enable the transmission of infectious agents and thus requires vigorous disinfection protocols.	

Table 1 (continued). Examples of dressings with pros and cons of use.

Scaffold – synthetic material	Integra (dermal substitute)	Silicone, collagen, glycosaminoglycans.	Variety of methods of construction, electrospun scaffolds stimulate cellular adhesion. Polylactides degrade to lactic acid ensuring limited host immune response.	Localised production of lactic acid may affect the efficacy of some proteins in the local environment.	48, 67, 69, 71–73
Honey dressing	Derma Sciences MediHoney	Medicinal honey such as Manuka honey, incorporated into a hydrogel or alginate or applied topically.	Antimicrobial, antifungal, anti-inflammatory, deodorising, maintains moist environment.	As a topical treatment, it rapidly dilutes and requires frequent dressings to maintain efficacy.	40, 70–75
Iodine dressing	Inadine dressings	Iodophors povidone-iodine (PVP-1) and cadexomer-iodine impregnated dressings.	Antiseptic, only small amounts of free iodine released into wound site.	Impedes wound healing through cytotoxic action against fibroblasts, keratinocytes and leukocytes; only suitable for short-term use.	27, 76–83
Silver dressing	Sorbsan Silver	Ionic, metallic and nano-crystalline forms of silver have been employed in the form of foams, hydrofibres and hydrocolloids.	Antibacterial action well established.	Possible systemic toxicity currently being investigated; effectiveness varies between products.	44, 84–93
Soft Silicone	Mepitel, Mepilex Ag	The contact layer consists of a polyamide net coated with soft silicone.	Prevents maceration of the surrounding tissue, atraumatic removal with nonadherence to the wound site, suitable for wide range of wound types, can be used for difficult wound sites, can be left for up to 10 days, can be impregnated with silver.	Used in conjunction with secondary absorbent dressing, requires contact with the wound site.	52, 53, 55, 120, 121

Modified with permission from 122.

when incorporated with antimicrobial agents like silver, antibacterial activity is attained<sup>59,60</sup>. Efficacy in retaining odour and absorbing wound exudate varies considerably across products<sup>59</sup>.

### Scaffolds

A scaffold is a 3D support that possesses a rigid structure of nano- and micro-topography that can be generated from natural or synthetic materials. Scaffolds facilitate infiltration of cells such as fibroblasts and keratinocytes through pores of a controllable size while maintaining optimal healing conditions. Ideally, a dermal scaffold would mimic the tissue's natural extracellular matrix (ECM); allowing for the incorporation of bioactive molecules while also being biocompatible. Resorbable structures, dissolving within an appropriate time, allow maturation of new tissue at the wound site to occur<sup>48</sup>. Scaffolds can be either acellular

or seeded with dermal cells to further facilitate wound healing through the secretion of growth factors and structural proteins<sup>61,62</sup>.

Natural acellular scaffolds involve the decellularisation of porcine or human tissue, whereby cells are destroyed and washed off, leaving only the ECM behind<sup>63,64</sup>. A variation on this technique involves the cultivation of human cells, including pluripotent cells *in vitro*; this often involves a multi-step process in order to achieve a structure analogous to that of the host tissue<sup>65</sup>.

Scaffolds may be manufactured using natural or synthetic polymers; each type exhibits both limiting and desirable traits and lends itself to specific processes in developing a 3D structure best suited for use in wound management. An example of a natural scaffold is chitosan, a natural polymer

derived from chitin, a structural protein found in abundance in animal exoskeletons and refined for use in the biomedical industry<sup>66</sup>. Chitosan is biocompatible, degradable, and low in antigenicity, and therefore considered an optimal material for use in dermal scaffolds<sup>67</sup>. Collagen is another naturally derived example that possesses similar qualities, but may enable the transmission of infectious agents and thus requires vigorous disinfection protocols<sup>48,68</sup>. Polysaccharides from plant sources have also been developed for use as hydrogel-type scaffolds<sup>48</sup>.

The most commonly used compounds for synthetic scaffolds are based on lactic and glycolic acids<sup>48</sup>. The use of synthetic polymers enables a range of strategies to be employed in scaffold construction. One such technique, electrospinning, involves forming polymer fibres of 3–5 µm in diameter through interaction with electrostatic forces into 3D matrices that exhibit specifically selected characteristics<sup>69,70</sup>. Electrospun scaffolds have already been shown to facilitate cellular adhesion and migration in a number of *in vitro* and *in vivo* studies<sup>67,71–73</sup>. Biocompatible polymers such as polylactides, polyglycolides, and polyvinyl alcohol may be used<sup>61,69</sup>. Polylactides degrade to their monomer, lactic acid, thus ensuring a limited host immune response, although the localised breakdown of the scaffold increases acidity, which may affect the efficacy of some proteins in the local environment<sup>48,69</sup>.

## Antibacterial dressings

### Honey dressings

The use of honey as an antibacterial is well established in modern wound care, with medical-grade honey used in a variety of commercially available dressings. These dressings provide antimicrobial and anti-inflammatory properties through autolytic debridement and maintenance of a moist wound environment while inhibiting bacterial growth, stimulating wound healing and deodorising the wound, although research trends are mixed in regard to their overall efficacy<sup>44,74–76</sup>. Honey is bactericidal and antifungal against approximately 70 bacterial strains, both gram-positive and gram-negative, and some yeasts<sup>77,78</sup> and is often used to control bacterial strains resistant to conventional antibiotics. Antimicrobial action is both mechanical and enzymatic. Like sugar pastes, honey can inhibit bacterial growth through its osmolarity, where the high concentration of sugars causes water to be drawn from the local wound environment. This also maintains a moist wound environment by stimulating fluid transfer from surrounding tissues<sup>78</sup>. Whilst this action dilutes the honey, its antibacterial effects remain<sup>79</sup>. Honey is applied topically to a wide range of wounds in the form of an ointment, for packing cavities, or impregnated within a hydrogel or alginate dressing. When used as an ointment, the honey will rapidly dilute due to absorption of wound exudate as well as increase in fluidity upon warming to body

temperature and may, therefore, require frequent dressing changes in order to maintain efficacy<sup>77</sup>.

### Iodine dressings

Iodine, a natural halogen, is an antiseptic and available in a range of topical applications. Like all antiseptics, it targets a broad spectrum of bacteria and other pathogens such as fungi, viruses, protozoa and prions through non-specific action<sup>80,81</sup>. Iodine has been used to prevent and treat infection since the fourth century BCE and debate over its use remains. This debate began when Fleming first advocated the use of antiseptics such as iodine in the prevention of gas gangrene in wounds obtained during World War I<sup>81,82</sup>. Although antiseptic use has declined due to the rise of resistant bacterial strains, modern preparations of iodine in managing infection are being explored, but results are conflicting and general consensus remains to be reached<sup>82</sup>.

Iodophors, one such modern formulation, were developed in the 1950s<sup>81</sup> by complexing elemental iodine to a surfactant to improve solubility and reduce cytotoxicity effects. Elemental iodine is cytotoxic against fibroblasts, keratinocytes and leukocytes, thus impeding wound healing. The use of iodophors in modern wound dressings ensures release of lower concentrations of free iodine into the wound exudate<sup>27,81,82</sup>. The most widely utilised formulations are povidone-iodine (PVP-1) and cadexomer-iodine<sup>62,82</sup>.

The former, while being the most commonly utilised form of iodine in the clinical setting<sup>81,83</sup>, is not recommended for long-term use or for complex wounds. Indeed, the use of current formulations of PVP-1 is still contentious. Previous research has shown that clinical concentrations of as little as 1% are cytotoxic to granulocytes and monocytes *in vitro* and systemic iodine toxicity can occur with PVP-1 dressings, which typically contain concentrations of 7.5%<sup>27,83</sup>.

Studies exploring cadexomer-iodine formulations as a topical application found them to be effective in controlling bacterial load<sup>84</sup>. Subsequent studies in humans and porcine models showed an acceleration of epidermal migration and re-epithelialisation, through upregulation of cytokines like vascular endothelial growth factor (VEGF)<sup>85,86</sup>. Cadexomer-iodine was also found to positively affect healing rates in chronic wounds in one small study conducted by Eming and colleagues<sup>87</sup>. Cadexomer-iodine formulations are available as ointments, powders or dressings (hydrogels, ointments gauze, knitted viscose, beads and paste)<sup>27,81,88</sup>.

### Silver dressings

Although the antibacterial action of silver is well established, with silver dressings used in a wide range of infected wounds<sup>89–91</sup>, their potential cytotoxicity remains an issue<sup>92–94</sup>. Ionic, metallic and nanocrystalline forms of silver have been

employed as foams, hydrofibres and hydrocolloids. The amount of free silver available to action upon the wound varies from product to product, which impacts upon the effectiveness of the dressing<sup>44,95</sup>.

Silver ions act upon bacteria by binding and disrupting proteins and nucleic acids through interaction with their negatively charged groups such as thiol groups, carboxylates, phosphates, hydroxyls, imidazoles, indoles and amines as well as stimulating the generation of reactive oxygen species<sup>94</sup>. As a result, cellular changes rapidly occur through a number of mechanisms that result in loss of viability<sup>96</sup>.

Investigations have begun only recently on the systemic toxicity of silver nanoparticles. Asharani *et al.*<sup>97</sup> investigated the cytotoxicity of silver nanoparticles on human glioblastoma and lung fibroblast cells *in vitro*. The nanoparticles were found to penetrate into mitochondria and nuclei, interrupting ATP synthesis and resulting in DNA damage<sup>97</sup>. Others have noted the cytotoxic effects of silver nanoparticles on keratinocytes *in vitro*<sup>81,98</sup>.

#### Other antibacterial dressings

Antibacterial agents such as chlorhexidine have been incorporated into a wide range of commercially available dressings and washes<sup>28,44,99</sup>. Chlorhexidine has been utilised in infection control since the 1950s but has been mostly limited to irrigation and wound cleansing protocols with limited evidence to support efficacy<sup>96</sup>.

Chitosan acetate is currently used as a haemostatic dressing in the form of a bandage, but some investigations into its antimicrobial action have shown it can prevent fatal systemic sepsis and control the growth of *Pseudomonas aeruginosa* and *Pseudomonas mirabilis*<sup>100-102</sup>.

Table 1 summarises and describes some currently available dressings and provides an overview of a fraction of the extensive range of wound dressings on the market.

### The future of wound dressings

As shown in this review, simple woven gauze is commonly used worldwide, despite being destructive to newly formed granulation tissue (due to penetration by migrating cells and formation of capillary loops within the dressing), being painful to remove and providing an inroad to infection (due to fibres left behind in the wound bed)<sup>32</sup>. This is not due to a lack of alternatives; there is a plethora of modern wound dressings that address at least one factor that promotes healing. Modern dressings ensure appropriate healing through their ability to maintain a moist wound environment and ensure patient comfort<sup>29,45,103</sup>.

Best practice for wound care involves regular inspection of the wound site, maintenance of nutritional status and an

in-depth analysis of the patient's history and lifestyle<sup>104,105</sup>. As the wound progresses through the stages of healing, these requirements change and so should the materials used<sup>106</sup>. Clinicians readily recognise that each wound is unique and that there is no single dressing 'cure-all' and yet the breadth and depth of choices available to the clinician can impede their decisions and render the selection of the most appropriate dressing a long and confusing process. This is especially true when individual patients require specific lifestyle considerations such as frequency of dressing changes, cosmetic concerns and comorbidities<sup>105,107</sup>.

Deeper understanding of the biochemical processes that occur in wound healing is paramount in assisting clinicians in making correct decisions and research is ongoing in this area. Alongside this investigation is the development of the next generation of wound dressings such as smart dressings. These smart dressings look to incorporate biosensors that respond to known biomarkers such as pH or to release growth factors and antimicrobial agents in a controlled manner<sup>108-110</sup>. Research is also focused on improving dressing materials already in use, such as modifying cotton gauze so that it selectively captures excess neutrophil elastase within a chronic wound<sup>111</sup>.

Plant- and animal-derived products for use in modern wound healing strategies are also being explored. Substances known to ancient and indigenous cultures as 'old wisdom' is examined with a modern eye; that is, traditional Chinese herbal formulae F1 and F2 were recently investigated in relation to their traditional use with diabetic ulcers. The plant extracts used in these formulations were found to promote fibroblast viability *in vitro* and liquorice is being investigated for its ability to assist dermal wound healing<sup>112,113</sup>. Papaya is another 'old remedy' that has undergone scrutiny as a topical treatment for burns and wounds. Extracts of unripe papaya peel and papaya latex are high in antioxidants, exhibit antibacterial properties and have been shown to enhance wound healing in diabetic rodents<sup>114-117</sup>.

As technology and engineering processes become increasingly sophisticated, the development of complex materials on the nano-scale provides dressings such as hydrogels which provide a biologically appropriate treatment for hard to heal wounds and other complex wounds<sup>44</sup>. One can only anticipate that further development of biocompatible scaffolds will result in a range of sophisticated dressings that will be capable of facilitating migration and proliferation through the controlled release of cytokines and growth factors, in response to biomarkers present in the wound environment, while impeding infection and relieving pain. Each wound arises from a unique cause, be it a particular trauma or underlying condition on a unique patient. This requires a range of dressings to ensure optimal healing conditions for



all wounds and, ultimately, a suite of sophisticated dressings that possess all of the features of an 'ideal dressing' while catering to the individual.

## Conclusion

The human body has always been prone to injury; this review has outlined man's attempts to cope with this. A critical component in all ancient medicine was the utilisation of a range of strategies to manage injuries to skin and to maximise the perceived outcome for the patient. The approaches developed were culturally dependent, with a wide range of practical and spiritual strategies employed (with varying success). The majority of wound healing techniques arose from trial and error until civilisations developed structured approaches to medicine, which often saw the human body as a spiritual vessel. There were significant advancements in wound healing strategies during times of great battles, from the battle of Troy, as described in the *Iliad*, the first and second world wars through to ongoing and cutting-edge research being conducted during modern conflicts<sup>14,34,118</sup>. These resulted in the development of a suite of increasingly complex materials. Recent trends indicate that materials used to maximise wound healing in the future will utilise a wide range of nanotechnologies as smart dressings that respond to the wound environment, with dressings capable of releasing biomolecules or producing a signal currently being developed<sup>109</sup>. Another expanding field is the investigation of natural agents such as plant- and animal-derived polymers for use in scaffolds and gels as well as a return to natural antimicrobial agents that were known to ancient cultures such as silver, honey and iodine. Ultimately, clinicians will be able to select from a suite of sophisticated, smart dressings in order to best maximise outcomes for each unique wound, and, subsequently, the patient.

## References

- Guo S & Dipietro LA. Factors affecting wound healing. *J Dent Res* 2010 Mar; 89(3):219–29.
- Laplante AF, Germain L, Auger FA & Moulin V. Mechanisms of wound re-epithelialization: hints from a tissue-engineered reconstructed skin to long-standing questions. *FASEB J* 2001 Nov; 15(13):2377–89.
- Galeano M, Altavilla D, Cucinotta D *et al.* Recombinant human erythropoietin stimulates angiogenesis and wound healing in the genetically diabetic mouse. *Diabetes* 2004 Sep; 53(9):2509–17.
- Block ER, Tolino MA, Lozano JS *et al.* Free edges in epithelial cell sheets stimulate epidermal growth factor receptor signaling. *Mol Biol Cell* 2010 Jul 1; 21(13):2172–81.
- Kiritly CP, Lynch AB & Lynch SE. Role of growth factors in cutaneous wound healing: a review. *Crit Rev Oral Biol Med* 1993; 4(5):729–60.
- Singer AJ & Clark RA. Cutaneous wound healing. *N Engl J Med* 1999 Sep 2; 341(10):738–46.
- Lingen MW. Role of leukocytes and endothelial cells in the development of angiogenesis in inflammation and wound healing. *Arch Pathol Lab Med* 2001 Jan; 125(1):67–71.
- Strodtbeck F. Physiology of wound healing. *Newborn and infant nursing reviews*. 2001 March 1; 1:43–52.
- Forrest R. Early history of wound treatment. *J R Soc Med* 1982 March; 75(3):198–205.
- Sipos P, Gyory H, Hagymasi K, Ondrejka P & Blazovics A. Special wound healing methods used in ancient Egypt and the mythological background. *World J Surg* 2004 Feb; 28(2):211–6.
- Majno G. *The healing hand: man and wound in the ancient world*. 1st paperback edn. Cambridge, Mass: Harvard University Press, 1991.
- Subbarayappa BV. The roots of ancient medicine: an historical outline. *J Biosci* 2001 Jun; 26(2):135–43.
- Temkin O. *Greek Medicine as Science and Craft*. Isis: The University of Chicago Press on behalf of The History of Science Society, 1953, pp. 213–25.
- Broughton II G & Burris D. *War and Medicine: A Brief History of the Military's Contribution to Wound Care Through World War I*. In: Sen CK (ed). *Adv Wound Care: Mary Ann Liebert Inc*; 2010, p. 640.
- Santos GH. Chest trauma during the battle of Troy: ancient warfare and chest trauma. *Ann Thorac Surg* 2000 Apr; 69(4):1285–7.
- Kopp J, Wang GY, Horch RE, Pallua N & Ge SD. Ancient traditional Chinese medicine in burn treatment: a historical review. *Burns* 2003 Aug; 29(5):473–8.
- Fu X, Wang Z & Sheng Z. Advances in wound healing research in China: from antiquity to the present. *Wound Repair Regen* 2001 Jan–Feb; 9(1):2–10.
- Lev E & Amar Z. "Fossils" of practical medical knowledge from medieval Cairo. *J Ethnopharmacol* 2008 Sep 2; 119(1):24–40.
- Jones VJ. The use of gauze: will it ever change? *Int Wound J* 2006 Jun; 3(2):79–86.
- Archer HG, Barnett S, Irving S, Middleton KR & Seal DV. A controlled model of moist wound healing: comparison between semi-permeable film, antiseptics and sugar paste. *J Exp Pathol (Oxford)* 1990 Apr; 71(2):155–70.
- Bolton L. Operational definition of moist wound healing. *J Wound Ostomy Continence Nurs* 2007 Jan–Feb; 34(1):23–9.
- Eagelstein WH. Moist wound healing with occlusive dressings: a clinical focus. *Dermatol Surg* 2001 Feb; 27(2):175–81.
- Winter GD. Formation of the scab and the rate of epithelization of superficial wounds in the skin of the young domestic pig. *Nature* 1962 Jan 20; 193:293–4.
- Winter GD & Scales JT. Effect of air drying and dressings on the surface of a wound. *Nature* 1963 Jan 5; 197:91–2.
- Queen D, Orsted H, Sanada H & Sussman G. A dressing history. *Int Wound J* 2004; 1(1):59–77.
- Steed DL. Debridement. *Am J Surg* 2004 May; 187(5A):715–45.
- Jones AM & San Miguel L. Are modern wound dressings a clinical and cost-effective alternative to the use of gauze? *J Wound Care* 2006 Feb; 15(2):65–9.
- Reitsma AM, Rodeheaver GT & Mansfield MA. Effectiveness of a New Antimicrobial Gauze Dressing as a Bacterial Barrier. *Tyco Healthcare Group L* 2001, pp. 1–4.
- Boateng JS, Matthews KH, Stevens HN & Eccleston GM. Wound healing dressings and drug delivery systems: a review. *J Pharm Sci* 2008 Aug; 97(8):2892–923.
- Martineau L & Shek PN. Evaluation of a bi-layer wound dressing for burn care I. Cooling and wound healing properties. *Burns* 2006 Feb; 32(1):70–6.
- Szycher M & Lee SJ. Modern wound dressings: a systematic approach to wound healing. *J Biomater Appl* 1992 Oct; 7(2):142–213.
- Jones V, Grey JE & Harding KG. Wound dressings. *BMJ*. 2006 Apr 1; 332(7544):777–80.
- Scales JT. Wound healing and the dressing. *Br J Ind Med* 1963 Apr; 20:82–94.
- Bloom H. "Cellophane" dressing for second-degree burns. *The Lancet* 1945; 246(6375):559.
- Johnson & Johnson I. BAND-AID® Brand Adhesive Bandages Beginnings. Johnson & Johnson Consumer Companies, Inc.; 2012. [Updated 2012; cited 4 April 2012] Available from: <http://www.band-aid.com/brand-heritage>.
- Dumville JC, Deshpande S, O'Meara S & Speak K. Foam dressings for healing diabetic foot ulcers. *Cochrane Database Syst Rev* 2011; 9:CD009111.
- Blaine G. Experimental Observations on Absorbable Alginate Products in Surgery: Gel, Film, Gauze and Foam. *Ann Surg* 1947 Jan; 125(1):102–14.
- Gilchrist T & Martin AM. Wound treatment with Sorbsan — an alginate fibre dressing. *Biomaterials* 1983; 4(4):317–20.
- Weller C & Sussman G. Wound Dressings Update. *J Pharm Pract Res* 2006; 36(4):318–23.

40. Olow B & Hogeman KE. [Plastic dressing for wounds; preliminary report]. *Nord Med* 1953 Mar 6; 49(10):362-4.
41. Wallgren GR. Plastics as surgical dressings; one year's experience with nobecutane. *Ann Chir Gynaecol Fenn* 1954; 43(4):278-85.
42. Miller JM, Ginsberg M, McElfratrick GE & Shonberg IL. Use of a plastic film as a dressing for wounds. *Arch Surg* 1961 Feb; 82:326-8.
43. Giles KW. Experience with nobecutane in minor surgery. *Br Med J* 1956 Mar 31; 1(4969):727-8.
44. Dumville JC, O'Meara S, Deshpande S & Speak K. Hydrogel dressings for healing diabetic foot ulcers. *Cochrane Database Syst Rev* 2011; 9:CD009101.
45. Davies P & Rippon M. Comparison of foam and hydrocolloid dressings in the management of wounds: a review of the published literature. *World Wide Wounds* [Online]; 2010.
46. Thomas S & Loveless P. A comparative study of the properties of twelve hydrocolloid dressings. *World Wide Wounds*; 1997.
47. Dinah F & Adhikari A. Gauze packing of open surgical wounds: empirical or evidence-based practice? *Ann R Coll Surg Engl* 2006 Jan; 88(1):33-6.
48. Juris S, Mueller A, Smith B, Johnston S, Walker R & Kross R. Biodegradable Polysaccharide Gels for Skin Scaffolds. *J Biomater Nanobiotechnol* 2011; 2(3):216-25.
49. Biazar E, Roveimiab Z, Shahhosseini G, Khataminezhad M, Zafari M & Majidi A. Biocompatibility evaluation of a new hydrogel dressing based on polyvinylpyrrolidone/polyethylene glycol. *J Biomed Biotechnol* 2012; 2012:343989.
50. Macaya D & Spector M. Injectable hydrogel materials for spinal cord regeneration: a review. *Biomed Mater (Bristol, UK)* 2012; 7(012001):2012.
51. Varma AK, Bal A, Kumar H, Kesav R & Nair S. Efficacy of Polyurethane Foam Dressing in Debrided Diabetic Lower Limb Wounds. *Wounds*; 2008.
52. White R. Evidence for atraumatic soft silicone wound dressing use. *Wounds UK* 2005; 1(3):104-109.
53. Losi P, Briganti E, Costa M, Sanguinetti E & Soldani G. Silicone-coated non-woven polyester dressing enhances re-epithelialisation in a sheep model of dermal wounds. *J Mater Sci: Mater Med* 2012; 23:2235-2243.
54. Li-Tsang CWP, Zheng YP & Lau JCM. A Randomized Clinical Trial to Study the Effect of Silicone Gel Dressing and Pressure Therapy on Posttraumatic Hypertrophic Scars. *Journal of Burn Care & Research* 2010; 31(3):448-457.
55. Meuleneire F. A case study evaluation of Safetac® dressings used for paediatric wounds. *Wounds UK* 2009; 5(2):12-18.
56. Deeth M, Oldfield A, Hampton S & Goodwin L. Rapid Action Capillary Dressings. In: *Medical A* (ed), Advancis Medical, 2012.
57. Deeth M & Pain L. VACUTEX: a dressing designed for patients, tailored by nurses. *Br J Nurs* 2001; 10(4):268-71.
58. Bellingham S, Conlon M, Cundell J *et al.* National Health and Social Services Board (NHSSB) Wound Management Manual. Northern Ireland: NHSSB, 2005.
59. Thomas S, Fisher B, Fram P & Waring M. Odour Absorbing Dressings: A comparative laboratory study. *World Wide Wounds* [serial on the Internet]; 1998. [Cited February 2012]. Available from: <http://www.worldwidewounds.com/1998/march/Odour-Absorbing-Dressings/odour-absorbing-dressings.html>.
60. Kerihuel JC. Charcoal combined with silver for the treatment of chronic wounds. *Wounds UK* 2009; 5(3):87-93.
61. Sobajo C, Behzad F, Yuan XF & Bayat A. Silk: a potential medium for tissue engineering. *Eplasty* 2008; 8:e47.
62. Chaikof EL, Matthew H, Kohn J, Mikos AG, Prestwich GD & Yip CM. Biomaterials and scaffolds in reparative medicine. *Ann N Y Acad Sci* 2002 Jun; 961:96-105.
63. Sezer AD & Cevher E. Biopolymers as Wound Healing Materials: Challenges and New Strategies. In: Pignatello R (ed). *Biomaterials Applications for Nanomedicine: InTech*, 2011, p. 458.
64. Stapleton TW, Ingram J, Fisher J & Ingham E. Investigation of the regenerative capacity of an acellular porcine medial meniscus for tissue engineering applications. *Tissue Eng Part A* 2011 Jan; 17(1-2):231-42.
65. Solomon DE. An *in vitro* examination of an extracellular matrix scaffold for use in wound healing. *Int J Exp Pathol* 2002 Oct; 83(5):209-16.
66. Stone CA, Wright H, Clarke T, Powell R & Devaraj VS. Healing at skin graft donor sites dressed with chitosan. *Br J Plast Surg* 2000 Oct; 53(7):601-6.
67. Neamnarka A, Sanchavanakitb N, Pavasantb P, Rujiravanita R & Supaphola P. *In vitro* biocompatibility of electrospun hexanoyl chitosan fibrous scaffolds towards human keratinocytes and fibroblasts. *Eur Polym J* 2008; 44(7):2060-7.
68. Han CM, Zhang LP, Sun JZ, Shi HF, Zhou J & Gao CY. Application of collagen-chitosan/fibrin glue asymmetric scaffolds in skin tissue engineering. *J Zhejiang Univ Sci B* 2010 Jul; 11(7):524-30.
69. Kluger PJ, Wyrwa R, Weisser J *et al.* Electrospun poly(D/L-lactide-co-L-lactide) hybrid matrix: a novel scaffold material for soft tissue engineering. *J Mater Sci Mater Med* 2010 Sep; 21(9):2665-71.
70. Zhong SP, Zhang YZ & Lim CT. Tissue scaffolds for skin wound healing and dermal reconstruction. *Wiley Interdiscip Rev Nanomed Nanobiotechnol* 2010 Sep-Oct; 2(5):510-25.
71. Blackwood KA, McKean R, Canton I *et al.* Development of biodegradable electrospun scaffolds for dermal replacement. *Biomaterials* 2008 Jul; 29(21):3091-104.

## Australia's leading supplier supporting wound care

**BrightSky**  
AUSTRALIA

specialist healthcare products at your door

To find out more:

☎ 1300 88 66 01

@ info@brightsky.com.au

🌐 www.brightsky.com.au

- One-stop-shop for traditional and advanced wound care
- Extensive range of products and brands in stock
- Flexible and reliable delivery service Australia-wide
- Order in small or large quantities
- Clinical expertise, tools and the BeBright Study Series for healthcare professionals

72. Khil MS, Cha DI, Kim HY, Kim IS & Bhattarai N. Electrospun nanofibrous polyurethane membrane as wound dressing. *J Biomed Mater Res B Appl Biomater* 2003 Nov 15; 67(2):675–9.
73. Sun T, Mai S, Norton D, Haycock JW, Ryan AJ & MacNeil S. Self-organization of skin cells in three-dimensional electrospun polystyrene scaffolds. *Tissue Eng* 2005 Jul–Aug; 11(7–8):1023–33.
74. Molan PC. The Evidence Supporting the Use of Honey as a Wound Dressing. *Int J Low Extrem Wounds* 2006; 5(1):40–54.
75. Jull AB, Rodgers A & Walker N. Honey as a topical treatment for wounds. *Cochrane Database Syst Rev* 2008; 4:CD005083.
76. Henriques A, Jackson S, Cooper R & Burton N. Free radical production and quenching in honeys with wound healing potential. *J Antimicrob Chemother* 2006 Oct; 58(4):773–7.
77. Molan P. Honey as a topical antibacterial agent for treatment of infected wounds *World Wide Wounds*; 2001.
78. Cooper R. Using honey to inhibit wound pathogens. *Nurs Times* 2008 Jan 22–28; 104(3):46, 8–9.
79. Kwakman PH & Zaat SA. Antibacterial components of honey. *IUBMB Life* 2012 Jan; 64(1):48–55.
80. Cooper RA. Iodine revisited. *Int Wound J* 2007 Jun; 4(2):124–37.
81. Sibbald RG, Leaper DJ & Queen D. Iodine Made Easy. *Wounds Int* 2011 May 2; 2:s1–6.
82. Angel DE, Morey P, Storer JG & Mwapatayi BP. The great debate over iodine in wound care continues: a review of the literature. *Wound Practice & Research* 2008; 16(1):6–21.
83. Burks RI. Povidone-iodine solution in wound treatment. *Phys Ther* 1998 Feb; 78(2):212–8.
84. Mertz PM, Oliveira-Gandia MF & Davis SC. The evaluation of a cadexomer iodine wound dressing on methicillin resistant *Staphylococcus aureus* (MRSA) in acute wounds. *Dermatol Surg* 1999 Feb; 25(2):89–93.
85. Ohtani T, Mizuashi M, Ito Y & Aiba S. Cadexomer as well as cadexomer iodine induces the production of proinflammatory cytokines and vascular endothelial growth factor by human macrophages. *Exp Dermatol* 2007 Apr; 16(4):318–23.
86. Lamme EN, Gustafsson TO & Middelkoop E. Cadexomer-iodine ointment shows stimulation of epidermal regeneration in experimental full-thickness wounds. *Arch Dermatol Res* 1998 Jan–Feb; 290(1–2):18–24.
87. Eming SA, Smola-Hess S, Kurschat P, Hirche D, Krieg T & Smola H. A novel property of povidone-iodine: inhibition of excessive protease levels in chronic non-healing wounds. *J Invest Dermatol* 2006 Dec; 126(12):2731–3.
88. Flores A & Kingsley A. Topical Antimicrobial Dressings: an overview. *Wound Essentials* 2007; 2:182–5.
89. Elliott C. The effects of silver dressings on chronic and burns wound healing. *Br J Nurs* 2010 Aug 12 – Sep 8; 19(15):s32–6.
90. Leaper DJ. Silver dressings: their role in wound management. *Int Wound J* 2006 Dec; 3(4):282–94.
91. Poon VK & Burd A. *In vitro* cytotoxicity of silver: implication for clinical wound care. *Burns* 2004 Mar; 30(2):140–7.
92. Wei L, Tang J, Zhang Z, Chen Y, Zhou G & Xi T. Investigation of the cytotoxicity mechanism of silver nanoparticles *in vitro*. *Biomedical Materials* 2010; 5(4):044103.
93. Zou SB, Yoon WY, Han SK, Jeong SH, Cui ZJ & Kim WK. Cytotoxicity of silver dressings on diabetic fibroblasts. *Int Wound J* 2012 Apr 26.
94. Kim TH, Kim M, Park HS, Shin US, Gong MS & Kim HW. Size-dependent cellular toxicity of silver nanoparticles. *J Biomed Mater Res A* 2012 Apr; 100(4):1033–43.
95. Jude EB, Apelqvist J, Spraul M & Martini J. Prospective randomized controlled study of Hydrofibre dressing containing ionic silver or calcium alginate dressings in non-ischaemic diabetic foot ulcers. *Diabet Med* 2007 Mar; 24(3):280–8.
96. Cooper R. A review of the evidence for the use of topical antimicrobial agents in wound care. *World Wide Wounds* 2004.
97. Asharani PV, Hande MP & Valiyaveetil S. Anti-proliferative activity of silver nanoparticles. *BMC Cell Biol* 2009; 10:65.
98. Zanette C, Pelin M, Crosera M *et al.* Silver nanoparticles exert a long-lasting antiproliferative effect on human keratinocyte HaCaT cell line. *Toxicol In Vitro*. 2011 Aug; 25(5):1053–60.
99. Aramwit P, Muangman P, Namviriyachote N & Srichana T. *In vitro* evaluation of the antimicrobial effectiveness and moisture binding properties of wound dressings. *Int J Mol Sci* 2010; 11(8):2864–74.
100. Dai T, Tegos GP, Burkatovskaya M, Castano AP & Hamblin MR. Chitosan acetate bandage as a topical antimicrobial dressing for infected burns. *Antimicrob Agents Chemother* 2009 Feb; 53(2):393–400.
101. Burkatovskaya M, Castano AP, Demidova-Rice TN, Tegos GP & Hamblin MR. Effect of chitosan acetate bandage on wound healing in infected and noninfected wounds in mice. *Wound Repair Regen* 2008 May–Jun; 16(3):425–31.
102. Dutta J, Tripathi S & Dutta PK. Progress in antimicrobial activities of chitin, chitosan and its oligosaccharides: a systematic study needs for food applications. *Food Science and Technology International* 2011; 18(1):3–34.
103. Hayward PG & Morrison WA. Current concepts in wound dressings. *Australian Prescriber* 1996; 19(11):3.
104. Dwyer K, Bezzina A, Smith G *et al.* Nurse Practitioner Clinical Practice Guidelines for the Management Of Wounds. In: Wales IHS0NS (ed). Illawarra: Emergency Shellharbour Hospital, 2004, p. 26.
105. AWMA. Standards for Wound Management, 2nd edn. The Australian Wound Management Association Inc, 2010.
106. Fife CE, Carter MJ & Walker D. Why is it so hard to do the right thing in wound care? *Wound Repair Regen* 2010 Mar–Apr; 18(2):154–8.
107. Purser K. Wound Dressing Guidelines, 2nd edn. Bath: Royal United Hospital Bath NHS Trust, 2009, p. 25.
108. Nocke A, Schröter A, Cherif C, Gerlach G. Miniaturized textile-based multi-layer pH-Sensor for wound monitoring applications. *AUTEX Research Journal* 2012 March 1; 12:3.
109. Hwang MR, Kim JO, Lee JH *et al.* Gentamicin-loaded wound dressing with polyvinyl alcohol/dextran hydrogel: gel characterization and *in vivo* healing evaluation. *AAPS PharmSciTech* 2010 Sep; 11(3):1092–103.
110. Stefonek-Puccinelli TJ & Masters KS. Co-immobilization of gradient-patterned growth factors for directed cell migration. *Ann Biomed Eng* 2008 Dec; 36(12):2121–33.
111. Edwards JV, Yager DR, Cohen IK *et al.* Modified cotton gauze dressings that selectively absorb neutrophil elastase activity in solution. *Wound Repair Regen* 2001; 9(1):9.
112. Lau TW, Chan YW, Lau CP *et al.* Investigation of the effects of Chinese medicine on fibroblast viability: implications in wound healing. *Phytother Res* 2007 Oct ;21(10):938–47.
113. Zaki AA, El-Bakryand MH & Fahmy AA. Effect of Licorice on Wound Healing In Rabbits. *Egyptian Journal Of Hospital Medicine* 2005; 20:58–65.
114. Anuar NS, Zahari SS, Taib IA & Rahman MT. Effect of green and ripe Carica papaya epicarp extracts on wound healing and during pregnancy. *Food Chem Toxicol* 2008; 48(7):2384–9.
115. Gurung S & Skalko-Basnet N. Wound healing properties of Carica papaya latex: *in vivo* evaluation in mice burn model. *J Ethnopharmacol* 2009; 121(2):338–41.
116. Nayak SB, Pinto Pereira L & Maharaj, D. Wound healing activity of Carica papaya L. in experimentally induced diabetic rats. *Indian J Exp Biol* 2007; 45(8):738–43.
117. Nayak SB, Ramdeen R, Adogwa A, Ramsuhag A & Marshall JR. Wound-healing potential of an ethanol extract of Carica papaya (Caricaceae) seeds. *Int Wound J* 2012; DOI:10.1111/j.1742-481X.2011.00933.x.
118. Forsberg JA, Elster EA, Andersen RC *et al.* Correlation of procalcitonin and cytokine expression with dehiscence of wartime extremity wounds. *J Bone Joint Surg Am* 2008 Mar; 90(3):580–8.
119. Zhou J, Loftus AL, Mulley G & Jenkins AT. A thin film detection/response system for pathogenic bacteria. *J Am Chem Soc* 2010 May 12; 132(18):6566–70.
120. Silverstein P, Heimbach D, Meites H *et al.* An Open, Parallel, Randomized, Comparative, Multicenter Study to Evaluate the Cost-Effectiveness, Performance, Tolerance, and Safety of a Silver-Containing Soft Silicone Foam Dressing (Intervention) vs Silver Sulfadiazine Cream. *Journal of Burn Care & Research* 2011; 32(6):617–626.
121. Tang CJ & Ponsky DC. Seal it and reveal it: Postoperative otoplasty care using a silicone-based occlusive dressing. *Otolaryngology – Head and Neck Surgery* 2010; 142:621–623.
122. Smith LE. Development of poly(vinylpyrrolidone) networks for treatment of skin graft contracture. Unpublished Thesis (PhD) University of Sheffield, 2007.