

# A STUDY ON VARIATIONS OF NUTRIENT FORAMEN OF HUMERUS WITH ITS CLINICAL IMPLICATIONS

Aashish J Rathwa<sup>1</sup>, Sanjay R Chavda<sup>\*2</sup>.

<sup>1</sup> Tutor, Department of Anatomy, P.D.U. Medical College, Rajkot, Gujarat, India.

<sup>\*2</sup> Assistant Professor, Department of Anatomy, P.D.U. Medical College, Rajkot, Gujarat, India.

## ABSTRACT

**Background:** Nutrient foramen is an opening into shaft of humerus which gives passage to the blood vessels of medullary cavity. The knowledge of nutrient foramen is important in surgical procedures like bone grafting and more recently in microsurgical vascularized bone transplantation. Lack of an adequate vascular supply can significantly delay or prevent fracture healing. Nutrient artery is the major source of blood supply to the long bone and hence plays an important role in fracture healing.

**Objective:** The nutrient foramens obey the rule of ossification, that is directed away from the growing end of the bone or not.

**Materials and Methods:** The present study consisted of 68 (34 right and 34 left) dried humerus excluding any fracture or pathological abnormalities. Number and direction of nutrient foramen was observed in each humerus. Location of nutrient foramen in relation with surfaces and zones of humerus was determined.

**Result:** It has been observed that 94.12% of the humerus had a single nutrient foramen, 6.39% double foramen, all humerus have nutrient foramina. It was concluded that the majority (73.61%) of the nutrient foramina were present on the antero-medial surface, 8.33% on the anterolateral surface and 8.33% on the posterior surface of the shaft of humerus and 8.33% of nutrient foramina present on anterior border. It was also concluded that most (86.11%) of the foramina present in the zone II followed by zone I (8.33%) then by zone III (5.56%). All foramina were directed toward the lower end of humerus.

**Conclusion:** By knowing the number and location of the nutrient foramina in humerus would be useful in preventing intra-operative injury of nutrient artery during orthopedic, plastic and reconstructive surgery and will also be relevant in medico legal practice.

**KEY WORDS:** Clinical implications, Foraminal index, Humerus, Nutrient foramen.

**Address for Correspondence:** Dr. Sanjay R Chavda, Assistant Professor, Department of Anatomy, P.D.U. Medical College, Rajkot - 360001, Gujarat, India. Mobile No: 8866385680

**E-Mail:** [drsanjay1409@gmail.com](mailto:drsanjay1409@gmail.com)

Access this Article online	Journal Information
<b>Quick Response code</b>  DOI: 10.16965/ijar.2018.410	<b>International Journal of Anatomy and Research</b> ICV for 2016 90.30 ISSN (E) 2321-4287   ISSN (P) 2321-8967 <a href="https://www.ijmhr.org/ijar.htm">https://www.ijmhr.org/ijar.htm</a> DOI-Prefix: <a href="https://dx.doi.org/10.16965/ijar">https://dx.doi.org/10.16965/ijar</a> 
Article Information	
Received: 19 Oct 2018	Accepted: 06 Dec 2018
Peer Review: 20 Oct 2018	Published (O): 05 Feb 2019
Revised: None	Published (P): 05 Feb 2019

## INTRODUCTION

Nutrient foramen is an opening into the shaft of humerus bone. It leads to oblique nutrient canal passing through cortex and ultimately opens into the medullary cavity. The nutrient artery enters into the medullary cavity through

nutrient foramen and the canal which is a rich source of blood supply to the medullary cavity and inner two-third of cortex of the Humerus [1]. The nutrient blood supply is crucial for any long bones and it should be preserved in order to promote the fracture healing [2]. Moreover, the

presence of preserved nutrient blood supply is essential for the survival of the osteocytes in cases of tumor resection, trauma, and congenital pseudoarthrosis [3].

It is usually single in number and located on the antero-medial surface of the humerus a little below its midpoint close to the medial border. It is usually directed toward the lower end of Humerus [4]. The number and location of foramina remains are non-constant feature in long bones [5]. Henderson RG also reported that their location in mammalian bones are variable and may alter during the growth [6]. Knowledge of the number and location of nutrient foramina is useful in certain surgical procedures [7].

Though studies on the vascularization of long bones of various populations were conducted analyzing the nutrient foramina morphometry and the vascular anatomy in reconstructive surgeries [8-11].

## MATERIALS AND METHODS

The present study consisted of 68(34 right and 34 left) dried and cleaned humerus which were available in the Department of Anatomy, PDU Medical Collage Rajkot Gujarat. All the humerus that were taken for the study were normal and with any fracture or pathological abnormalities were excluded from the study. The side determination was done for the entire humerus. In each humerus, nutrient foramen was observed and studied carefully under proper illumination.

The nutrient foramina were distinguished by the presence of a well-marked groove leading to the foramen, and by a well marked often slightly raised edge of the foramen at the commencement of the canal. Location of nutrient foramen in relation with surface and zone were observed and recorded. Direction of nutrient foramen in relation with growing end of humerus was noted. The position of nutrient foramen was determined by calculating a Foraminal Index (FI) using the Hughes formula:  $12 FI = (DNF \backslash TL) \times 100$  where DNF stands for distance from the proximal end of the bone to the nutrient foramina and TL stands for total length of the bone in millimeter. Determination of total length of the individual humerus was taken as the distance between the superior aspect of the head and

the most distal aspect of the trochlea of each humerus in millimeter.

The position of foramina was divided into three types according to FI as follows:


**Zone I:** FI up to 33.33%, the foramen was in proximal third of the bone.

**Zone II:** FI from 33.33% to 66.66%, the foramen was in the middle third of bone.

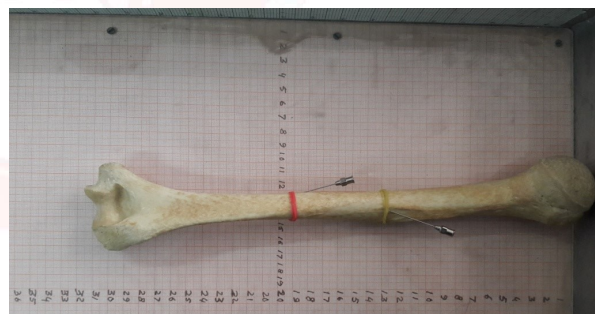**Zone III:** FI above 66.66%, the foramen was in the distal third of bone.

All the numerical data were subjected to statistical analysis using EPI INFO The observations and measurements were presented in descriptive statistics.

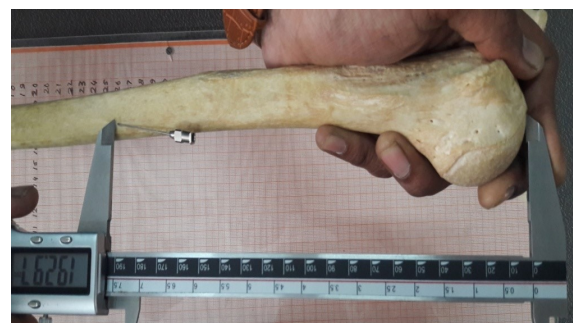**Fig. 1:** Showing Double Nutrient Foramen.




**Fig. 2:** Shows Direction Of Nutrient Foramen.



**Fig. 3:** Shows Measurement Of PI(Proximal Length) Of Humerus.



**Fig. 4:** Shows Total Length Of Humerus.



## RESULTS

The following observations were found to conclude the results of the study.

As shown in Table 1, the single nutrient foramen was present in 97.05% (33) of right humerus and 91.12% (31) of left humerus, double nutrient foramina in 3.95% (01) of right humerus and 6.39% (03) of left humerus, triple nutrient foramina was not found in any humerus.

**Table 1:** Showing distribution of nutrient foramen of humerus.

No of nutrient foramen	RT(N=34)		LT(N=34)		TOTAL(N=68)	
	No of humerus	%	No of humerus	%	No of humerus	%
1	33	97.05	31	91.12	64	94.12
2	1	3.95	3	6.39	4	6.39
3	0	0	0	0	0	0

It has been concluded that 94.12 % of the humerus had a single nutrient foramen. The double foramen was observed in 6.39% of the humerus. Triple foramen was found in 0% of the humerus.

**Location of foramina:** It has been observed that a total of 72 numbers of nutrient foramina were found to be present in all studied humerus. In relation to surfaces, it was found that antero-medial surface (AMS) had 74.28% (26) of nutrient foramina in right humerus and 72.97% (27) of nutrient foramina in left humerus, posterior surface (PS) had 5.71% (02) of nutrient foramina in right humerus and 10.81% (04) of nutrient foramina in left humerus and antero-lateral surface (ALS) had 8.57% (03) of nutrient foramina in the right humerus and 8.10% (03) of nutrient foramina in the left humerus were found on anterolateral surface of the shaft of humerus and 11.4%(04)werefoundon anterior border on right humerus and 8.10%(03)were found on anterior border at left humerus as shown in n Table. 2.

**Table 2:** Showing distribution of nutrient foramen in respect to surface of humerus.

Surface	Right (N=35nf)		Left (N=37nf)		Total (N=72)	
AMS	26	74.28%	27	72.97%	53	73.61%
ALS	3	8.57%	3	8.10%	6	8.33%
Anterior Border	4	11.42%	3	8.10%	7	9.72%
PS	2	5.71%	4	10.81%	6	8.33%
Total	35		37		72	

Therefore, it was concluded that the majority (73.61%) of the nutrient foramina were found to be present on the antero-medial surface of the shaft of humerus, followed by 9.72% of the nutrient foramina were concentrated on the anterior border and 8.33% of the nutrient foramina were located on the posterior surface and anterolateral surface of the shaft of humerus.

As shown in Table 3, the incidence of nutrient foramina present in Zone I of the shaft of humerus was found to be 8.57% (03) in right humerus whereas the nutrient foramina was found to be 8.10% in Zone I of left humerus. It was observed that 30 nutrient foramina (85.71%) were present in Zone II of right humerus and 32 nutrient foramina (86.47%) in Zone II of left humerus. It was also observed that 2 nutrient foramina (5.71%) were present in Zone III of right humerus and 2 nutrient foramina (5.40%) in Zone III of left humerus in relation to the zones.

**Table 3:** Showing distribution of nutrient foramen in respect to zone of humerus.

ZONE	RT(N=35NF)		LT(N=37NF)		TOTAL	
	NO	%	NO	%	NO	%
ZONE-I	3	8.57	3	8.1	6	8.33
ZONE-II	30	85.71	32	86.47	62	86.11
ZONE-III	2	5.4	2	5.4	4	5.56
TOTAL	35		37		72	

Overall incidence of presence of nutrient foramina in the middle one-third or Zone II of the shaft of humerus were 86.11%, followed by Zone I (8.33%) and by lower one-third or zoneIII (5.56%).

**Direction of foramina:** The direction of nutrient foramina was not showing any deviation from normal anatomical feature even in single case throughout the study. All the foramina were directed downward or toward the lower end of humerus.

As shown in Table 4, the mean total length of humerus was found to be 270.56 mm in right and 269.97 mm in left humerus; and mean distance from proximal end of humerus to the nutrient foramen was found to be 149.17 mm for right and 150.11 mm for left humerus and the foraminal index was found to be 54.87% on right humerus and 55.44% on left humerus. Therefore, an average the total mean length of humerus

was found to be  $270.22 \pm 20.54$  mm; and mean distance from proximal end of humerus to the nutrient foramen was found to be 149.71 mm and the mean foraminal index was found to be 55.20%.

**Table 4:** Showing mean values of statistical measurements of humerus.

Parameters	RT(N=34)	LT(N=34)	Total
Mean total length	27.69 CM	28.52 CM	56.21 CM
Distance from proximal end of nutrient foramen	16.30 CM	16.39 CM	32.69 CM
Foraminal index	53.73%	54.25%	54.49%

## DISCUSSION

The knowledge of variations of nutrient foramina is significantly important for orthopaedic surgeons undertaking an open reduction of a fracture to avoid injuring the nutrient artery and thus lessening the chances of delayed or non-union of the fracture [13]. Intact arterial supply is very important for healing of a fractured bone [14]. It is well known fact that one of the causes of delayed union or non-union of fracture is lack of arterial supply [15].

**Number of foramina:** The present study showed that single nutrient foramen was present in 94.12% of humerus. A similar finding (88.5%) was reported by Peirere et al in south Brazil<sup>16</sup> and Bhatnagar et al reported the incidence of 90% of humerus with single nutrient foramen in Uttar Pradesh india [17]. Similar trend also reported by Forriol et al(75%) in 36 humerus collected from Medical School of Alcala de Henares University with single nutrient foramen as compared to the present study [18]. Many studies reported low percentage of incidence of single foramina. A study done by Shaheen in Saudi Arabia observed that 60% of humerus had single nutrient foramen [19]. Similar findings also observe Mysorekar(58%) in Indian population and Joshi et al.63% among Gujarati population [7,13]. Carroll et al also observed in 71 humerus collected from University of Western Ontario, London and observed that 67.61% of humerus had a single nutrient foramen [20].

The present study showed that the prevalence of double nutrient foramina were found in 6.39% of humerus which was similar to the findings observed by Bhatnagar et al. who reported 7.14% of humerus, Halagatti et al. (17.5%) and

Solanke et al. (4%) found a similar incidence of double foramina in humerus to that of present study [20-22]. In contrast to this result, Joshi et al. reported 33% and 33.3% of double nutrient foramina observed by Shaheen. Carroll in London who also reported 28.16% higher incidence in humerus to that present study [13,19,20].

However, most of the authors in their study agreed that the majority of humerus had a single nutrient foramen at a higher incidence compared to that of the double or triple or the quadruple nutrient foramina.

**Location of foramina:** The nutrient foramina are situated a little below its midpoint on the antero medial surface close the medial border of humerus<sup>4</sup>. However; the location of foramina may vary in position. The present study concluded that 73.61% of foramina were situated on antero-medial surface of the humerus which was in accordance to the findings of Gopalakrishna et al.70.97% halagatti et al(87%)and Yaseen et al. (88.5%)also found similar observation in their study [22-24].

In contrast to this, a study conducted by Khan et al. in humerus of Pakistan cadavers reported the higher incidence (96%) of nutrient foramina situated on the antero- medial surface of the shaft of the Humerus [25]. But some author reported the lesser incidence of the nutrient foramina on the antero medial surface of humerus. Such as Vinay et al. reported only 30.23% of nutrient foramina on the antero-medial surface of Humerus [26].

The present study also concluded that 8.33% of nutrient foramina were located on the posterior surface. Similar study was conducted by Ukoha et al. in humerus of Nigerian population and reported the incidence of 7.5% and Gopalakrishna et al. in their study observed 8.06% of nutrient foramina on posterior surface which were almost similar to the finding of the present study [23,27].

However, a study conducted by Anusha et al. and observed the higher incidence (19%) of the presence of nutrient foramina on posterior surface than the present result [28].

Forriol et al. reported 15.55% of foramina in Spanish population and Kizilikant et al. (18.1%)

in Turkish population which was comparatively also higher than the present result [18,29]. But a study conducted in Pakistani cadavers by Khan et al. and reported that 2.66% of nutrient foramina were found to be present on posterior surface which was comparatively lesser than the value of the present study [25].

The present study showed that the majority of nutrient foramina (86.11%) were found to be present in zone II (the middle one-third) of the shaft of the humerus which was correlated with the study conducted by Halagatti et al. noticed that (84%) incidence of presence of nutrient foramina in the middle one-third of the shaft of Humerus [22]. Khan et al. who reported 96.20% of nutrient foramina on the middle one-third of humerus of Pakistan cadavers [25].

A study conducted by Ukoha et al. in humerus of Nigerian population found that 100% of the nutrient foramina were located on the middle one-third of the humerus and a similar trend also reported by Kumar et al. (100%) in Indian population which were higher than the present result [27,30].

**Direction of foramina:** Many studies had been conducted to observe the direction of nutrient foramina in humerus to determine that whether it follows the law of ossification or not. Berard reported that the direction of the nutrient foramina of humerus was constant and the nutrient canal was slanted towards that end at which the epiphysis was first united with the shaft of Humerus [31].

The direction of the nutrient foramina were directed horizontally before birth but as the growth proceeds the direction of nutrient foramina were directed from the growing end of the Humerus [32].

The present study observed that the direction of all the nutrient foramina of humerus was directed towards the lower end of humerus which was supported by many studies [22,23,25,30].

Which revealed that the direction of nutrient foramina were constant and obeys the law of ossification [17,23,24,28,33]. Similarly, Kumar et al. reported that the direction of all nutrient foramina present in the humerus were directed away from the growing end of humerus except one which was directed towards the upper end

[30]. Similarly, Khan et al. also opined that 98.67% of the nutrient foramina were directed distally towards the lower end of humerus which was accordance with the present result [25].

Pereira et al. reported the mean foraminal index was 55.2% and Pramart et al. also reported 55.2% which were in accordance with that of the present study [16,34]. Ukoha et al. found that value of mean foraminal index for humerus was 56.28% in humerus of Nigerian population and Muralimanju et al. reported 57.6% among Indian population which were slightly higher in comparison to the present result [27,35]. However, one study reported the lower value of mean foraminal index for humerus (52.65%) [22].

The present study was retrospective study. Though the study was conducted on adult humerus, this may not be applicable for children. The exact determination of the gender was not studied. No any radiological methods were used.

## CONCLUSION

The knowledge about the location of the nutrient foramina is highly important because of the increased chances of damage to the nutrient artery during open or close procedures. Damage to the nutrient artery may cause delayed union or non-union of the bone following fracture of humeral shaft. By having the knowledge of variations in the position of the nutrient foramina of humerus, placement of internal fixation devices can be appropriately done to limit the chances of delayed or non-union during fracture of the shaft of humerus. It will be helpful for the orthopedic surgeons to avoid this area during any surgical procedures such as bone repair, bone graft, microvascular bone surgery and during extensive stripping of the periosteum so that they can minimize the damage to the nutrient artery of humerus.

**Conflicts of Interests: None**

## REFERENCES

- [1]. Krishna Garg. BD Chaurasia's Hand Book of General Anatomy. Blood supply of bones. 4th ed. 2011. CBS Publishers and Distributors Pvt. Ltd:43-44.
- [2]. Longia GS, Ajmani ML, Saxena SK, Thomas RJ. Study of diaphyseal nutrient foramina in human long bones. Acta Anat. 1980;107:399- 406.

- [3]. Sendemir E, Cimen A. Nutrient foramina in the shafts of lower limb long bones: situation and number. *Surg Radiol Anat.* 1991; 13:105-8.
- [4]. Standring S. *Gray's Anatomy*, 40th ed. CHURCHILL LIVINGSTONE ELSEVIER, 2008:798.
- [5]. Bokariya P, Gudadhe D, Kothari R, Murkey PN, Shende MR. Comparison of humerus and femur with respect to location and number of nutrient foramina. *Indian Journal of Forensic Medicine and Pathology.* 2012;5(2):79-81.
- [6]. Henderson RG. The position of the nutrient foramen in the growing tibia and femur of the rat. *J Anat.* 1978; 125(3):593-9.
- [7]. Mysorekar VR. Diaphyseal nutrient foramina in human long bones. *J Anat.* 1967;101(4):813-22.
- [8]. Nagel A. The clinical significance of the nutrient artery. *Orthop Rev* 1993; 22:557-61
- [9]. Dyankova S. Vascular anatomy of the radius and ulna diaphyses in their reconstructive surgery. *Acta Chir Plast* 2004; 46:105-9.
- [10]. Choi SW, Kim HJ, Koh KS, Chung IH, Cha IH. Topographical anatomy of the fibula and peroneal artery in Koreans. *Int J Oral Maxillofac Surg* 2001;30:329-32.
- [11]. Schiessel A, Zweymuller K. The nutrient artery canal of the femur: a radiological study in patients with primary total hip replacement. *Skeletal Radiol* 2004;33:142-9.
- [12]. Hughes H. The factors determining the direction of canal for the nutrient artery in the long bones of mammals and birds. *Acta Anatomica.* 1952; 15(3): 261-280.
- [13]. Joshi H, Doshi B, Malukar O. A study of the nutrient foramina of the humeral diaphysis. *NJIRM* 2011;2:14-17.
- [14]. Hoy WE, Hughson MD, Bertram JF, Douglas-Denton R, Amann K. Nephron number, hypertension, renal disease, and renal failure. *J Am Soc Nephrol.* 2005;16(9):2557-64.
- [15]. Sharma M, Prashar R, Sharma T, Wadhwa A. Morphological Variations of Nutrient Foramina in upper limb long bones. *Int J Med and Dent Sci.* 2013;2(2):177-81.
- [16]. Pereira GAM, Lopes PTC, Santos AMPV, Silveira FHS. Nutrient foramina in the upper and lower limb long bones: Morphometric study in bones of southern Brazilian adults. *Int J Morph.* 2011;29(2):514-20.
- [17]. Bhatnagar S, Deshwal AK, Tripathi A. Nutrient foramina in the upper and lower limb long bones: A morphometric study in bones of western Uttar Pradesh. *Int J Sci Res.* 2014;3(1):301-3.
- [18]. Forriol FC, Gomez LP, Gianonatti MA, Fernandez RV. A study of the nutrient foramina in human long bones. *Surg Radiol Anat.* 1987;9: 251-5.
- [19]. Shaheen SY. Diaphyseal nutrient foramina in human upper and lower limb long bones. A thesis submitted for the partial fulfillment of the requirement for the master degree in anatomy. 2009:20-21.
- [20]. Carroll SE. A study of the nutrient foramina of the humeral diaphysis. *J Bone Joint Surg.* 1963; 45: 176-181.
- [21]. Solanke KS, Bhatnagar R, Pokhrel R. The number and position of nutrient foramina in humerus, radius, ulna of human dry bones of Indian origin with clinical correlation. *OA.* 2014;2(1):1-8.
- [22]. Halagatti MS, Rangasubhe P. A study of nutrient foramina in dry adult humeri of south Indian subjects. *NJCA.* 2011;1(2):76-80.
- [23]. Gopalakrishna K, Sreekala MA, Rathna BS. A study on the incidence and direction of nutrient foramina in south Indian humeral diaphysis and their clinical importance. *J Med Heal Sci.* 2013;3(1):71-6.
- [24]. Yaseen S, Nitya W, Ravinder M. Morphological and topographical study of nutrient foramina in adult humeri. *Int J Innov Res Sci Eng Technol.* 2014;3(4):7-10.
- [25]. Khan AS, Shah Z, Inayat Q. Anatomical variations in diaphyseal nutrient foramina of humerus in cadavers from khyber pakhtunkhwa, pakistan. *Khyber Med Univ J.* 2014;6(1):18-21.
- [26]. Vinay G, Kumar AS. A study of nutrient foramina in long bones of upper limb. *Anat Karnataka.* 2011;5(3):53-6.
- [27]. Ukoha UU, Umeasalugo KE, Nzeako HC, Ezejindu DN, Ejimofor OC, Obazie IF. A study of nutrient foramina in long bones of Nigerians. *Natl J Med* 2013;3(4):304-8.
- [28]. Anusha P, Naidu MP. A study on the nutrient foramina of long bones. *Jour of Med Sci and Tech.* 2013;2(3):150-7.
- [29]. Kizilkanat E, Boyan N, Ozsahin ET, Soames R, Oguz O. Location, number and clinical significance of nutrient foramina in human long bones. *Ann Anat.* 2007;189:87-95.
- [30]. Kumar S, Kathiresan K, Gowda MST, Nagalaxmi. Study of diaphyseal nutrient foramina in human long bones. *Anat Karnataka.* 2012;6(2): 66-70.
- [31]. Berard A. *Memoirs Sur le Rapport Qui Existe Entre La Direction Des Conduits Nourriciers Des Os Longs, Et l'ordre Suivant Lequelles Epiphyses Se Soudent Au Corps De l'os.* *Arch Gen Med Series.* 1835; 27:176-183.
- [32]. Datta AK. *Essentials of Human Osteology: General Consideration.* 2nd ed. Kolkata. Current Books International 1997:5.
- [33]. Chandrasekaran S, Shanthi KC. A study on the nutrient foramina of adult humeri. *J Clin Diagn Res.* 2013;7(6):975-7.
- [34]. Parmar AMB, Vaghela B, Shah K, Patel B, Tridevi B. Morphometric analysis of nutrient foramina in human typical long bones of upper limb. *Natl J Integr Res Med.* 2014;5(5):26-9.
- [35]. Murlimanju BV, Prashanth KU, Prabhu LV, Saralaya VV, Pai MM, Rai R. Morphological and topographical anatomy of nutrient foramina in human upper limb long bones and their surgical importance. *Rom J Morphol Embryol* 2011;52(3):859-62.

**How to cite this article:** Aashish J Rathwa, Sanjay R Chavda. A STUDY ON VARIATIONS OF NUTRIENT FORAMEN OF HUMERUS WITH ITS CLINICAL IMPLICATIONS. *Int J Anat Res* 2019;7(1.2):6132-6137. DOI: 10.16965/ijar.2018.410