

A retrospective institutional study of histopathologic pattern of Oral Squamous Cell Carcinoma (OSCC) in Tehran, Iran during 2006-2015

Ramin Ghafari¹, Noushin Jalayer Naderi¹, Amirnader Emami Razavi²

¹Department of Oral and Maxillofacial Pathology, Faculty of Dentistry, Shahed University, Tehran, Iran, ²Iran National Tumor Bank, Cancer Biology Research Center, Cancer Institute of Iran, Tehran University of Medical Sciences, Tehran, Iran

Background: Despite the available data on demographic information of oral squamous cell carcinoma (OSCC), the changing trend of histopathologic pattern of OSCC has not conducted yet, in Iran. The aim was to investigate the pattern of histopathologic features of OSCC in Iran by analyzing the patients referred to Cancer Institute, Imam Khomeini Hospital, Tehran University of Medical Sciences, Tehran, Iran, during 2006-2015. **Materials and Methods:** The study was a retrospective institutional study. The pathology records with the diagnosis of OSCC were retrieved from Iran National Tumor Bank, Cancer Biology Research Center, Cancer Institute of Iran, Tehran University of Medical Sciences, Tehran, Iran, during 2006-2015. The demographic characteristics and histopathologic features were recorded and analyzed for possible trend. Descriptive analysis was used for statistical interpretation. **Results:** The data showed an increasing number of moderately and poorly differentiated OSCC. Accordingly, higher increasing rate in tumor size and vascular, perineural invasion was detected. **Conclusion:** On the basis of histopathologic features, moderately differentiated OSCC with increasing rate of tumor size and vascular, perineural invasion was indicated in recent decade. Based on the findings, lower differentiation potentially is compatible with worsen prognosis.

Key words: Carcinomas, epidemiology, squamous cell, trends

How to cite this article: Ghafari R, Jalayer Naderi N, Emami Razavi A. A retrospective institutional study of histopathologic pattern of Oral Squamous Cell Carcinoma (OSCC) in Tehran, Iran during 2006-2015. *J Res Med Sci* 2019;24:53.

INTRODUCTION

Oral squamous cell carcinoma (OSCC) comprises more than 90% of all oral cavity malignancies. OSCC is a debilitating disease with a 5-year survival rate lower than 50%. It has been shown that the geographical differences and environmental factors affect the OSCC prevalence.^[1]

The prevalence of oral cancers in Iran is 20–36.3 per 100 thousand people.^[2] In Iran, the pattern of epidemiological characteristic of OSCC, is similar to the other cancers.^[3] The studies from 1962 to 2009 in academic centers and hospitals have been shown that the prevalence of OSCC

in major cities of Tehran, Mashhad, and Shiraz was 1.29–1.6,^[4-6] 0.9–3.1,^[7-9] and 1.4%–5%,^[10,11] respectively. The incidence of OSCC in Iran is similar to India and Pakistan.^[2] In recent years, the increasing prevalence of oral cancer has been documented in Asia, especially in India.^[12] Data on OSCC trend in Iran are very limited and insufficient. Updating the data about the epidemiological characteristics of OSCC has not been conducted in Iran in recent years. Despite the available data on demographic information of OSCC, the evaluation of histopathologic pattern of OSCC has not conducted yet, in Iran. The histopathologic grade of OSCC is one of the most important issues to determine the prognosis. Considering the subject, informed the decision-makers

Access this article online

Quick Response Code:



Website:
www.jmsjournal.net

DOI:
10.4103/jrms.JRMS_882_18

This is an open access journal, and articles are distributed under the terms of the Creative Commons Attribution-NonCommercial-ShareAlike 4.0 License, which allows others to remix, tweak, and build upon the work non-commercially, as long as appropriate credit is given and the new creations are licensed under the identical terms.

For reprints contact: reprints@medknow.com

Address for correspondence: Dr. Noushin Jalayer Naderi, Department of Oral and Maxillofacial Pathology, Faculty of Dentistry, Shahed University, Tehran, Iran. E-mail: jalayer@shahed.ac.ir

Received: 15-11-2018; **Revised:** 20-02-2019; **Accepted:** 24-02-2019

about the histopathologic trend of malignant tumors such as OSCC will help the authorities to prepare more facilities for provide the better, effective services to laboratories and patients. The aim was to investigate the histopathologic pattern of OSCC in Iran by analyzing the patients referred to Cancer Institute, Imam Khomeini Hospital, Tehran University of Medical Sciences, Tehran, Iran, from 2006-2015.

MATERIALS AND METHODS

The study was a retrospective, institutional review. The statistical society was medical records of patients with histopathologic diagnosis of OSCC from archive of Iran National Tumor Bank, Cancer Biology Research Center, Cancer Institute of Iran, Tehran University of Medical Sciences, Tehran, Iran, during 2006-2015. The inclusion criteria were complete registered information of medical records about demographic characteristics and histopathologic features. The exclusion criteria were incisional biopsy samples. All samples with histopathologic diagnosis of squamous cell carcinoma (SCC) were retrieved from archive, and cases with oral cavity involvement were included in the study. The histopathologic records that had met the inclusion criteria were investigated. Demographic characteristics (age and gender) and clinicopathologic features (tumor size, anatomic location, differentiation degree, vascular invasion, perineural involvement, and

lymph node involvement) were recorded. The clinical appearance of lesions comprising of the color, texture and shape was not included in the registration. There were a total number of 6200 SCCs from 2006 to 2015. Overall, 587 OSCCs were retrieved. Three hundred and fifty-nine incisional biopsies were excluded because of insufficient data of lymph node involvement and invasion state. The frequency of demographic characteristics and histopathologic features was reported. The SPSS software version 19 for windows (SPSS Inc., IBM Co., Chicago, Illinois, USA) was used.

RESULTS

The age ranged from 15 to 93 years with a mean of 59.3 ± 15.7 years. The seventh and eighth decades ($n = 136$, 23.2% and $n = 135$, 23%, respectively) included the highest incidence of disease. The least number of cases was obtained from tenth and second decades ($n = 3$, 0.5% and $n = 6$, 1%, respectively). Three hundred and fifty (59.6%) OSCCs occurred in males and 236 (40.2%) in females. The male-to-female ratio was 1.48:1. Tongue was the most common site of OSCC with 224 cases (38.2%), followed by mandible (108, 18.4%). Vestibule (5, 0.9%) and gingiva (8, 1.4%) were the least prevalent anatomic sites of OSCC [Table 1].

Two hundred and sixty-eight (45/7%) cases of all samples were well differentiated, followed by moderate (249, 42.4%)

Table 1: Frequency of clinical features of oral squamous cell carcinoma during 2006-2015 based on the number of cases

Variable	Years									
	2006	2007	2008	2009	2010	2011	2012	2013	2014	2015
Age										
10-20	0	0	2	1	1	0	0	2	0	0
21-30	0	2	4	2	2	2	2	4	1	1
31-40	2	1	4	3	3	9	3	10	8	4
41-50	0	5	3	9	5	20	10	18	5	6
51-60	2	7	6	7	15	16	22	26	6	8
61-70	6	8	7	5	13	18	22	32	18	7
71-80	4	8	9	11	15	18	17	29	12	12
81-90	1	1	2	1	8	9	5	8	2	3
91-99	0	0	0	0	0	0	3	0	0	0
Gender										
Male	7	20	23	24	33	56	49	82	30	26
Female	8	12	15	16	29	36	35	48	22	15
Site										
Tongue	4	10	19	16	19	34	40	53	16	13
Mandible	8	7	5	7	12	12	15	27	6	9
Lip	1	7	6	7	6	27	12	19	15	6
Buccal	0	0	1	0	12	7	4	14	6	6
Mouth floor	1	5	2	2	8	3	3	5	3	1
Maxilla	0	2	2	5	4	3	6	6	2	3
Palate	0	0	1	0	1	5	3	4	3	3
Gingiva	1	0	0	2	0	2	1	2	0	0
Vestibule	0	1	2	1	0	0	0	0	1	0

Table 2: Frequency of histopathologic finding of oral squamous cell carcinoma during 2006-2015 based on the number of cases

Variable	Years									
	2006	2007	2008	2009	2010	2011	2012	2013	2014	2015
Grade										
Well	10	13	17	21	34	45	34	55	19	20
Moderate	5	15	16	11	23	42	42	57	27	14
Poor	0	0	0	2	2	4	5	12	8	5
Size										
0-2	3	4	7	15	12	21	27	33	12	9
2.1-4	8	12	9	15	21	44	29	54	21	16
4.1-6	0	7	17	4	11	18	21	31	10	10
6<	1	1	0	2	3	10	6	12	9	4
Vascular invasion										
+	3	4	10	7	12	18	27	31	23	18
-	5	13	14	13	22	61	50	84	23	18
Perineural invasion										
+	1	6	14	12	13	35	27	46	21	18
-	3	8	7	11	23	46	49	73	21	16
Lymphatic invasion										
+	7	16	14	7	15	28	23	42	15	12
-	6	11	19	25	33	34	33	50	21	17

+: With involvement; -: Without involvement

and poor differentiation (38, 6.5%). Tumor size ranged from 0.4 to 11 cm with a mean of $3/0 \pm 1.77$ cm. The lymph node involvement, vascular invasion, and perineural involvement were found in 179 (41.8%) of 428, 153 (33.6%) of 456, and 193 (42.9%) of 450 cases, respectively [Table 2].

From 2006 to 2015, the histopathologic grade of OSCC had increasing number toward moderate and poor differentiation. In coordinate to histopathologic differentiation, tumor size and invasion to vascular and perineural structures had higher prevalence. In the period of the study, lymph node involvement had an irregular pattern until 2011. Contrary, the pattern of lymph node involvement followed a linear model [Figure 1]. Despite the higher number of well-differentiated OSCC as a whole, a higher incidence of moderately and poorly differentiated cases was indicated during 2010–2014 and 2012–2015, respectively.

DISCUSSION

The oral cancer comprises almost 2% of all cancers in the United States,^[1] and it is the most frequent one in India.^[13] In Asia, the occurrence of OSCC in Pakistan and Sri Lanka had increasing and decreasing trends in recent years, respectively.^[12] The pattern of OSCC incidence in Iran is similar to India and Pakistan.^[2] Data on OSCC trend in Iran are very limited. Basically, studies have been focused on the demographic changes of OSCC. The available information on histopathologic changes of OSCC is very small and insufficient. The histopathologic pattern of OSCC in Iran was investigated retrospectively by analyzing the

pathologic records of OSCC in Iran National Tumor Bank, Cancer Biology Research Center, Cancer Institute of Iran, Tehran University of Medical Sciences, Tehran, Iran, during 2006-2015.

The results showed that from the total cases of OSCC during 2006–2015, 45/7%, 42.4%, and 6.5% of cases were well, moderately, and poorly differentiated, respectively.

The finding is compatible with previous studies. The studies showed the most prevalence of well-differentiated OSCC.^[14-17] The findings were different from some previous reports which showed a more prevalence rate of moderately- and poorly differentiated OSCCs.^[18,19] The difference can be due to the type of samples. Unlike surgical specimens, diagnostic specimens in patients referred to clinics or patients who are involved with unknown lesions are typically in the form of incisional. Because of this, it does not represent all aspects of tumor such as lymph node involvement. In contrast, hospital-derived specimens consist of lesions as a whole and include all parts of the tumor. In these circumstances, pathologist has more insight to overcome the pitfalls of histopathologic diagnosis.

Despite the higher number of well-differentiated OSCC as a whole, the peak incidence of moderately and poorly differentiated cases was during 2010–2014 and 2012–2015, respectively. The finding is in agreement with Sherin *et al.* in India who showed more prevalence of moderately differentiated OSCC in both young adult and older age groups.^[20]

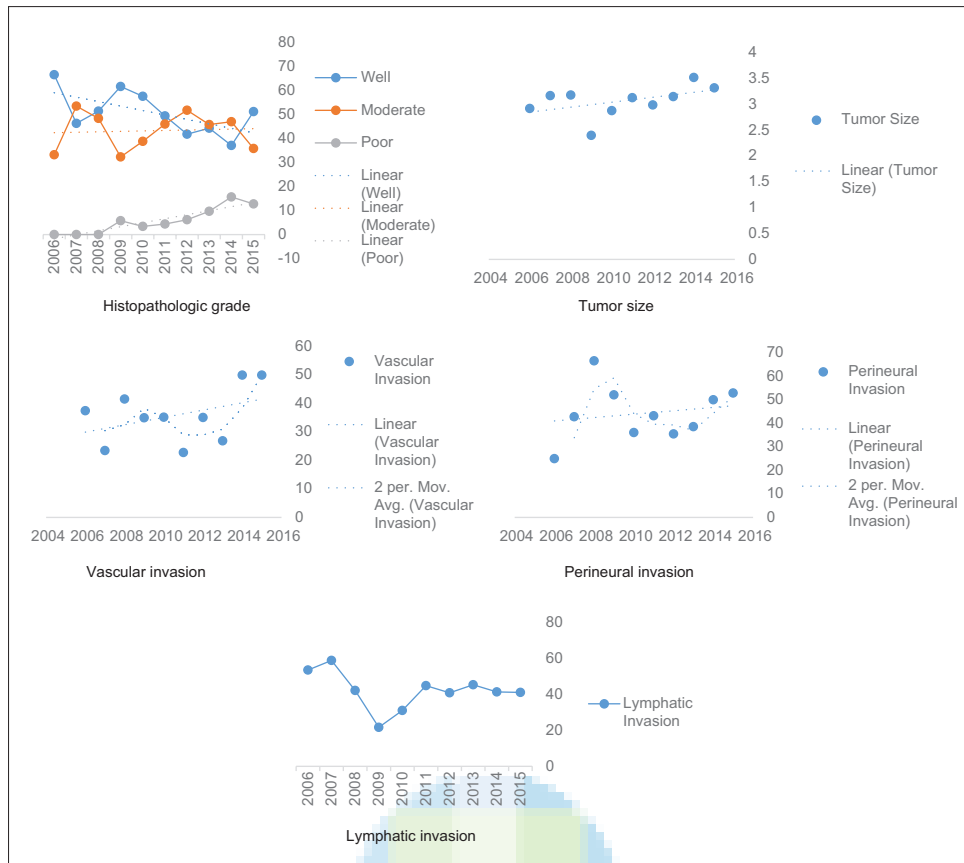


Figure 1: The trend of histopathologic parameters of oral squamous cell carcinoma during 2006–2015

Using Broder’s criteria in histopathologic grading, Ur Rahman and Ahmed Mujib reported no difference in OSCC between younger and older (40 years old age) patients. Using Anneroth *et al.* classification, results showed higher grades of histopathologic parameters in younger.^[21] The finding indicated the aggressiveness of OSCC in younger patients. In the present study, data were not restricted to any age group. Compatible with previous studies, higher histopathologic grades in population were noted.

The progression of the tumor that represents an invasion of a tumor is not only determined by an increase in the size but also characterized by an increase in the heterogeneity of the tumor and an increase in malignancy. Heterogeneity results from multiple and independent mutations in tumor cells. This causes the invasion, the rate of growth, and even the response to treatment. Monoclonal cells become heterogenic over time and affect the clinical course of the tumor. Immunologic factors can also change this process. Chemical and environmental factors and viruses can cause cancer-induced genetic damage and affect the malignancy.^[22] Cancer progresses take years to develop. The effect of various carcinogenic factors during this period can affect the course of the disease. The study findings showed that in addition to increasing the histopathologic grade, the size of the tumor and its invasion also increased.

More biologic and molecular studies need to investigate the causes of malignant up trend of OSCC.

Social and cultural variables have important impact on oral cancer. Human papillomavirus infection and tobacco and alcohol consumption are among the most important factors in developing the OSCC. It has been shown that in United States, the females in younger ages were more prone to oral cavity cancers as in mid 1990s.^[23]

The epidemiologic studies revealed that a pattern of OSCC features in Iran is similar to other countries. Based on results, in Iran, OSCC is more prevalent in males, tongue and older adults. The well-differentiated OSCC comprises the most cases.^[3]

Despite the available information on the epidemiological situation of OSCC in Iran, the possible changing trend has not been studied. Since the registration of disease outbreaks is essential for health planning, determining the possible changes in the course of the disease is an important issue.

The present study was single centered. Therefore, it cannot reflect the whole condition of the Iranian society. In spite of this limitation, due to the fact that the Iran National Tumor Bank, Cancer Biology Research Center, Cancer Institute of

Iran, Tehran University of Medical Sciences, Tehran, Iran contained the samples of patients from different provinces, it can reflect the present status. Expressing the general condition of Iran, multicentral studies are necessary. In the present study, the sex and age status of patients on the histopathological profile of cancer were not investigated. The impact of age and sex on the extent of malignancy is suggested in future studies.

CONCLUSION

On the basis of histopathologic features, moderately differentiated OSCC with increasing rate of tumor size and vascular, perineural invasion was indicated in recent decade. The recent prevalence of higher histopathology grades of OSCC can contribute to modern lifestyle and environmental factors. Determining the present inclination in histopathologic grade of OSCC requires community health research.

Acknowledgments

The authors thank the staff of Iran National Tumor Bank, Cancer Biology Research Center, Cancer Institute of Iran, Tehran University of Medical Sciences, for kindly assistance in archive retrieval. The study was approved by the Ethical Committee of Shahed University under registration number IR.Shahed.REC. 1396.55.

Financial support and sponsorship

Biological materials were provided by the Iran National Tumor Bank which is funded by Cancer Institute of Tehran University of Medical Sciences, for Cancer Research.

Conflicts of interest

There are no conflicts of interest.

REFERENCES

- Neville BW, Damm DD, Allen CM, Chi AC. Oral and Maxillofacial Pathology. 4th ed. Canada: Elsevier; 2016. p. 374-9.
- Petersen PE. The world oral health report 2003: Continuous improvement of oral health in the 21st century – The approach of the WHO global oral health programme. Community Dent Oral Epidemiol 2003;31 Suppl 1:3-23.
- Maleki D, Ghojzadeh M, Mahmoudi SS, Mahmoudi SM, Pournaghi-Azar F, Torab A, *et al.* Epidemiology of oral cancer in Iran: A systematic review. Asian Pac J Cancer Prev 2015;16:5427-32.
- Eshghyar N, Motahari P, Khoureshidian A. Evaluation of clinical and histological parameters in patients with oral squamous cell carcinoma referred to Tehran faculty of dentistry (1966-2002). JIDA 2005;17:62-7.
- Razmpa E. Epidemiology of Laryngeal carcinoma. A review of 100 patient's files admitted in Imam Khomeiny hospital. Teb Tazkiyeh 1997;27:34-6.
- Sargeran K, Murtomaa H, Safavi SM, Vehkalahti M, Teronen O. Malignant oral tumors in Iran: Ten-year analysis on patient and tumor characteristics of 1042 patients in Tehran. J Craniofac Surg 2006;17:1230-3.
- Delavarian Z, Pakfetrat A, Mahmoudi S. Five years retrospective study of oral and maxillofacial malignancies in patients referred to oral medicine department of Mashhad dental school-Iran. J Mashhad Dent Sch 2009;33:129-38.
- Falaki F, Dalirsani Z, Pakfetrat A, Falaki A, Saghraevanian N, Nosratzahi T, *et al.* Clinical and histopathological analysis of oral squamous cell carcinoma of young patients in Mashhad, Iran: A retrospective study and review of literature. Med Oral Patol Oral Cir Bucal 2011;16:e473-7.
- Hoseinpour Jajarm H, Ghodsi K. The assessment of chromosomal abnormalities in patients with oral cancer. J Mashhad Dent Sch 2005;29:51-6.
- Andisheh-Tadbir A, Mehrabani D, Heydari ST. Epidemiology of squamous cell carcinoma of the oral cavity in Iran. J Craniofac Surg 2008;19:1699-702.
- Fahmy MS, Sadeghi A, Behrard S. Epidemiologic study of oral cancer in Fars Province, Iran. Community Dent Oral Epidemiol 1983;11:50-8.
- Krishna Rao SV, Mejia G, Roberts-Thomson K, Logan R. Epidemiology of oral cancer in Asia in the past decade – An update (2000-2012). Asian Pac J Cancer Prev 2013;14:5567-77.
- Rastogi T, Devesa S, Mangtani P, Mathew A, Cooper N, Kao R, *et al.* Cancer incidence rates among South Asians in four geographic regions: India, Singapore, UK and US. Int J Epidemiol 2008;37:147-60.
- Salian V, Dinakar C, Shetty P, Ajila V. Etiological trends in oral squamous cell carcinoma: A retrospective institutional study. Cancer Transl Med 2016;2:33-6.
- Pires FR, Ramos AB, Oliveira JB, Tavares AS, Luz PS, Santos TC. Oral squamous cell carcinoma: Clinicopathological features from 346 cases from a single oral pathology service during an 8-year period. J Appl Oral Sci 2013;21:460-7.
- Halboub E, Al-Mohaya M, Abdulhuq M, Al-Mandili A, Al-Anazi Y. Oral squamous cell carcinoma among Yemenis: Onset in young age and presentation at advanced stage. J Clin Exp Dent 2012;4:e221-5.
- Smitha T, Mohan CV, Hemavathy S. Clinicopathological features of oral squamous cell carcinoma: A hospital-based retrospective study. J NTR Univ Health Sci 2017;6:29-34.
- Muange P, Chindia M, Njiru W, Dimba E, Mutave R. Oral squamous cell carcinoma: A 6-month clinico-histopathologic audit in a Kenyan population. Open J Stomatol 2014;4:475-83.
- Hernández-Guerrero JC, Jacinto-Alemán LF, Jiménez-Farfán MD, Macario-Hernández A, Hernández-Flores F, Alcántara-Vázquez A. Prevalence trends of oral squamous cell carcinoma. Mexico city's general hospital experience. Med Oral Patol Oral Cir Bucal 2013;18:e306-11.
- Sherin N, Simi T, Shameena PM, Sudha S. Changing trends in oral cancer. Indian J Cancer 2018;45:93-6.
- Ur Rahaman SM, Ahmed Mujib B. Histopathological correlation of oral squamous cell carcinoma among younger and older patients. J Oral Maxillofac Pathol 2014;18:183-8.
- Kumar V, Abbas AK, Aster JC. Robbins and Cotran Pathologic Basis of Disease. 9th ed. Canada: Elsevier; 2015.
- Bleyer A. Cancer of the oral cavity and pharynx in young females: Increasing incidence, role of human papilloma virus, and lack of survival improvement. Semin Oncol 2009;36:451-9.