YALE JOURNAL OF BIOLOGY AND MEDICINE 81 (2008), pp.115-119.

CASE REPORT

An Unusual Log-splitter Injury Leading to Radial Artery Thrombosis, Ulnar Artery Laceration, and Scapholunate Dissociation

Christopher R. Spock, BA, Jeffrey C. Salomon, MD, Deepak Narayan, MD*

Department of Plastic and Reconstructive Surgery, Yale University School of Medicine, New Haven, Connecticut

A log splitter is a gasoline- or diesel-powered machine that uses a hydraulic-powered cutting wedge to do the work of an axe. Log-splitter injuries that do not result in amputation of digits or limbs are uncommon and not well described in the literature. We present a unique case of a patient who sustained a log-splitter injury that resulted in thrombosis of the radial artery and avulsion laceration of the ulnar artery leading to acute hand ischemia, in addition to scapholunate ligament disruption leading to a DISI deformity. In this case, thrombolytic therapy was contraindicated and surgical revascularization was the best possible treatment option. Our case illustrates the pitfalls of using this modality in a crush injury, since the use of thrombolytics in this instance would have resulted in severe hemorrhage. An important clinical caveat is the potentially misleading arteriographic diagnosis of thrombosis and/or spasm.

INTRODUCTION

Log-splitter injuries that do not result in amputation of digits or limbs are uncommon. The pressure generated by a log splitter, upward of 13.5 meganewtons per square meter [1], is more than enough to cause amputation as well as severe crush injury. Traditionally, severe crush to the hand has been associated with a poor functional outcome [2,3]. In the typical case, one can expect metacarpal fractures, ragged skin flaps, and an unusually high incidence of compartment syndromes [4]. In addition to damage to skin and bone, vascular compromise can be an important characteristic of such injuries. Acute post-traumatic hand ischemia is an emergency requiring an immediate attempt at revascularization. Garcia-Elias et al., from a review of the literature, recognized a sub-group of hand injuries with a concomitant vascular injury in which hand amputation was the end point of treatment if urgent vascular reconstruction was not carried out [5]. These injuries, however, usually can be salvaged, provided that vascularity is maintained or restored.

*To whom all correspondence should be addressed: Deepak Narayan, MD, Department of Plastic and Reconstructive Surgery, Yale University School of Medicine, PO Box 208062, New Haven, CT 06520-8062; Tele: 203-785-2573; Fax: 203-785-5714; E-mail: deepak.narayan@yale.edu.

†Abbreviations: tPA, tissue plasinogen activator; DISI, dorsal intercalated segment instability; DRC, dorsal radiocapitate.

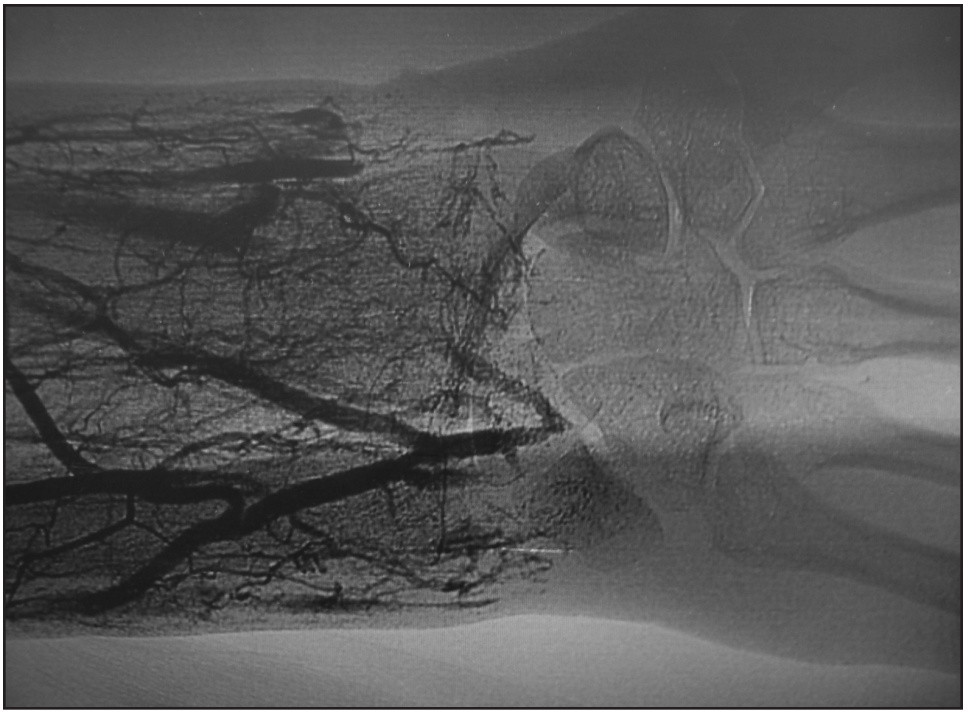

Figure 1. Left Hand Arteriogram

We present a case of a patient who sustained an unusual combination of injuries from a log-splitter accident. The important features of the patient's injuries were thrombus occlusion of the radial artery, an avulsion disruption of the ulnar artery, and disruption of the scapholunate ligament leading to dorsal intercalated segment instability (DISI) deformity.

CASE REPORT

A 39-year-old right master-handed gentleman presented approximately 20 hours after sustaining a crush injury to his left non-master hand in a log splitter at home. His past medical history was significant for hypertension.

The patient initially was seen at a neighboring institution for evaluation and treatment. The physical exam on transfer revealed bruising of the distal volar forearm just proximal to the wrist without skin laceration. Radial and ulnar pulses were lacking distal to the area of injury. Clinically, the hand was cool, slightly blue, and lacked digital pulp turgor. Plain X-ray revealed pisiform fracture and scapholunate dissociation. The patient underwent emergency angiogram, which revealed abrupt cutoff of radial and ulnar artery flow into the left hand at the level of the distal forearm just proximal to the wrist junction. There was no evidence of extravasation of dye (Figure 1). Radiologic interpretation was felt to be consistent with ulnar and radial artery spasm. The patient was not felt to be a candidate for tissue plasminogen activator (tPA[†]), given the nature of his injuries. Since the patient showed no improvement on IV Heparin and the hand remained mottled and cool, emergent surgical exploration was recommended and accepted.

Fasciotomies were performed on the volar forearm, the thenar eminence, and the inter-metacarpal regions in conjunction with a carpal tunnel release. Additionally, a Guyon's canal release also was performed. The median and ulnar nerves were both intact. The ulnar artery was severely bruised and thrombosed over a length of 8 cm, extending from the ulnar aspect of the superficial palmar arch to 2 cm proximal to the volar wrist crease. At that level in the distal

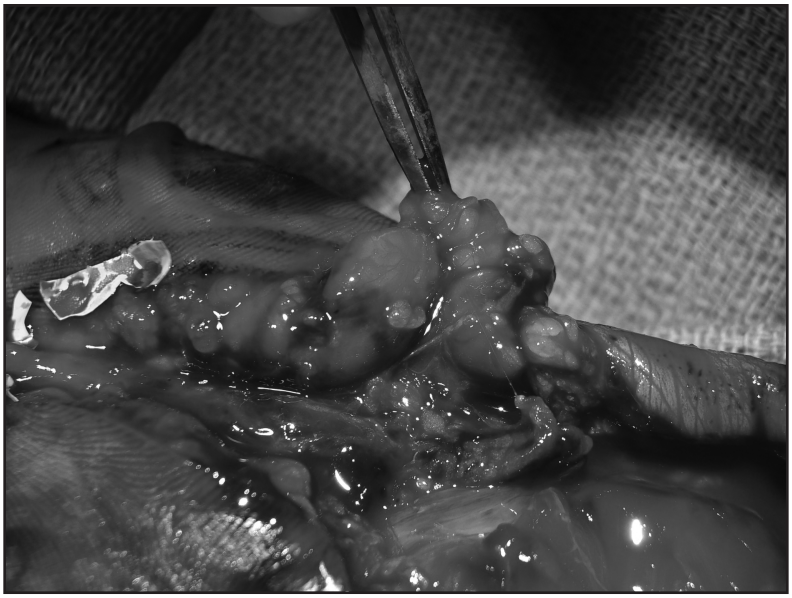

Figure 2. Intra-operative photo of ulnar artery avulsion

forearm, a total avulsion injury of the ulnar artery was evident with the proximal and distal components of the ulnar artery separated by 5 cm (Figure 2). The intervening gap between the ends of the ulnar artery contained torn and stretched adventitial tissue.

Exploration of the radial volar forearm showed a discrete 0.75 cm area of thrombus within the radial artery about 1.5 cm proximal to the wrist crease. The remainder of the architecture of the radial artery was intact. A radial artery thrombectomy was performed.

Vascular reconstruction of the ulnar artery was performed using an 8 cm interposition saphenous vein graft from the forearm to the superficial palmar arch. The patient was maintained on aspirin post-operatively, and strong Doppler signals were maintained from both the radial and ulnar arteries.

A post-operative MRI revealed scapholunate ligament disruption and rotary subluxation of the scaphoid (Figure 3). The lateral view of the wrist demonstrated dorsal tilt of the lunate consistent with a DISI deformity. In addition, a fracture fragment was seen distal to the ulnar styloid process, likely representing an avulsion off the pisiform.

At 12 months, the patient underwent a proximal row carpectomy as well as an open procedure using a K-wire to pin a dislocated capitate of the wrist. The patient currently has normal 2-point discrimination in all digits and the ability to pinch with 5 pounds of strength.

The patient has some residual intrinsic muscle fibrosis and decreased thenar muscle mass. The thumb-index space is tight, secondary to partial adductor muscle fibrosis, and the patient has difficulty with prehensile activities secondary to this fibrosis. He also has difficulty extending the thumb out of the plane of the palm and thumb abduction secondary to partial fibrosis of thenar muscles; however, he can oppose his thumb pulp to all fingertips. In addition, the patient has returned to work.

DISCUSSION

A log splitter is a gasoline- or diesel-powered machine that uses a hydraulic-powered cutting wedge to do the work of an axe. The typical log splitter consists of a flat, narrow platform with a splitting wedge in a fixed position at one end and a moveable driving ram at the other. A lever control engages a hydraulic pump powered by an engine to advance and withdraw the ram. Pressures upward of 13.5 meganewtons per square meter are generated [1].

Log-splitter injuries are uncommonly reported in the medical literature. A Medline

Figure 3. Post-operative MRI

search using both keywords and titles, including "log splitter," reveals only two articles [1,6]. While there is no characteristic "log splitter hand," the most common resultant injuries are complete or partial loss of digits, fracture(s) with soft tissue loss, or both [1]. Often, the crushing nature of the injury precludes successful replantation of amputated parts.

The unique features of this particular injury include a complete avulsion/traction rupture of the ulnar artery in the distal forearm in a closed injury and a trans-scaphoid dislocation with the proximal pole of the scaphoid and capitate both dorsal to the lunate, consistent with a dorsal intercalated segment instability (DISI) deformity. We postulate that this injury was caused by the rapid forceful radial deviation and extension of the wrist, hence the rupture of the ulnar artery, by the patient attempting to extricate himself from the log splitter in which his hand was pinned.

In the case we report, the angiogram demonstrated an abrupt cutoff of the radial and ulnar arterial inflow to the hand at the level of the wrist. Initial radiographic impression was vascular spasm vs. thrombosis or a combination of both, simultaneously involving both the radial and ulnar arteries. The angiographer did not feel that the patient was a candidate for thrombolytic treatment because the nature of the injury posed a bleeding risk. In certain cases, thrombolytic therapy has been useful in the management of thrombotic and embolic hand ischemia [7-10], but little information exists on thrombolysis in the setting of an acute crush injury. Wheatley and Swift report a case of successful hand revascularization using urokinase following crush injury [10]. In that particular case report, there was absence of distal vessel reconstitution in the palmar arch and digital vasculature.

To our knowledge, a case of arterial thrombosis and concomitant arterial avulsion and laceration resulting in complete loss of blood flow to the hand following this type of injury has not been reported. In addition to the vascular injury, the patient sustained scapholunate ligament disruption, rotary subluxation of the scaphoid, and dorsal tilt of the lunate consistent with a dorsal intercalated segment instability (DISI) deformity.

We postulate that our patient suffered the ulnar artery disruption while forcefully torquing his arm and body in an effort to quickly extricate his hand from under the log in the log splitter. Without force sufficient to disrupt the distal radial-ulnar joint and tear the triangular fibrocartilage complex and scapholunate ligaments, it would be unlikely that the wrist could radially deviate sufficiently from the axis of the forearm to allow sufficient stretch on the ulnar artery to allow it to rupture. In effect, we believe that the patient sustained a flash proximal carpal row dislocation into complete radial deviation.

The scapholunate disruption initially was not pinned because restoration of blood flow to the ischemic hand was of primary importance. Once blood flow was restored and the hand was viable, the decision was made not to pin the scapholunate disruption at that time. We did not want to manipulate the fresh anastomosis of the saphenous vein graft or risk damaging the vessel through pinning.

The mechanism of a scapholunate disruption is similar to that of a scaphoid fracture, which is characterized by stress loading of the extended carpus. However, in a scapholunate disruption, the wrist is usually in ulnar, rather than radial, deviation, and

with a severe hyperextension injury of the wrist, there is tear of scapholunate interosseous ligament. Further loading of the extended carpus causes tear, in succession, of radiocapitate ligaments, radiotriquetral ligaments, and, finally, dorsal radiocarpal ligaments. The lunate follows the triquetrum into extension and a DISI deformity results [11].

Mechanical properties of the dorsal ligaments of the wrist have been reported. The strongest ligaments are the palmar radiotriquetral ligament and the dorsal radiocapitate (DRC) ligament [12]. A study by Viegas et al. demonstrated that the dorsal intercarpal ligaments and dorsal scapholunate interosseous ligaments combined have a mechanical strength (162.4 +/- 64.7 N) that is comparable to that of the DRC ligament (143.3 +/- 41.5 N) [13]. The force generated by a log splitter is more than enough to cause rupture of these ligaments.

In summary, we present the case of an unusual log-splitter injury that resulted in thrombosis of the radial artery and avulsion laceration of the ulnar artery leading to acute hand ischemia, in addition to scapholunate ligament disruption leading to a DISI deformity. In this case, thrombolytic therapy was contraindicated, and surgical revascularization was the best possible treatment option. Our case illustrates the pitfalls of using this modality in a crush injury, since the use of thrombolytics in this instance would have resulted in severe hemorrhage. An important clinical caveat is the potentially misleading arteriographic diagnosis of thrombosis and or spasm. Clinicians, therefore, should be cautious about accepting a diagnosis of spasm or thrombosis and using thrombolytics in their approach to these unusual injuries.

REFERENCES

1. Kristiansen TK, Seligson D. Log splitter injuries to the hand. Journal of Occupational Medicine. 1981;23(6):400-2.
2. Carter PR. Crush injury of the upper limb. Early and late management. Orthop Clin North Am. 1983;14(4):719-47.
3. Entin MA. Crushing and Avulsing Injuries of the Hand. Surg Clin North Am. 1964;44:1009-18.
4. Del Pinal F, Herrero F, Jado E, et al. Acute hand compartment syndromes after closed crush: a reappraisal. Plast Reconstr Surg. 2002;110(5):1232-9.
5. Garcia-Elias M, Dobyns JH, Cooney III WP, Linscheid RL. Traumatic axial dislocations of the carpus. J Hand Surg. 1989;14(3):446-57.
6. May JW Jr., Hansen R. Log-splitter injuries. N Engl J Med. 1980;303(19):1127.
7. Kartchner MM, Wilcox WC. Thrombolysis of palmar and digital arterial thrombosis by intra-arterial Thrombolysin. J Hand Surg. 1976;1(1):67-74.
8. Lambiase RE, Paolella LP, Haas RA, Dorfman GS. Extensive thromboembolic disease of the hand and forearm: treatment with thrombolytic therapy. J Vasc Interv Radiol. 1991;2(2):201-8.
9. Wheatley MJ, Marx MV. The use of intra-arterial urokinase in the management of hand ischemia secondary to palmar and digital arterial occlusion. Ann Plast Surg. 1996;37(4):356-63.
10. Wheatley MJ, Swift R. Successful hand revascularization with urokinase following a crush injury. Ann Plast Surg. 1997;39(1):94-6.
11. Mayfield JK. Mechanism of carpal injuries. Clin Orthop. 1980;149:45-54.
12. Savelberg HH, Kooloos JG, Huiskes R, Kauer JM. Stiffness of the ligaments of the human wrist joint. J Biomech. 1992;25(4):369-76.
13. Viegas SF, Yamaguchi S, Boyd NL, Patterson RM. The dorsal ligaments of the wrist: anatomy, mechanical properties, and function. J Hand Surg. 1999;24(3):456-68.