FULL PAPER *Pathology*

# Deposition Process of Eosinophilic Substance in Mouse Nasal Septum

Takuya DOI[1)]*, Yuri KOTANI[1)], Hiroko KOKOSHIMA[1)], Takeshi KANNO[1)], Yumi WAKO[1)], Minoru TSUCHITANI[1)] and Takane MATSUI[2)]

[1)]*Mitsubishi Chemical Safety Institute Ltd., Sunayama 14, Kamisu-shi, Ibaraki, 314–0255 and* [2)]*Department of Pathobiological Science, Obihiro University of Agriculture and Veterinary Medicine, Inada-cho, Obihiro-shi, Hokkaido, 080–8555, Japan*

(Received 4 February 2009/Accepted 27 February 2009)

ABSTRACT. An eosinophilic substance is usually observed in the mouse nasal septum, and its volume increases with age. In contrast to descriptions in textbooks defining the eosinophilic substance as amyloid, our previous report revealed that the observed eosinophilic substance is not amyloid, but consisted of collagen and an amorphous material. Furthermore, it was suggested that the amorphous material was produced by the clear hematoxylin and eosin (HE)-stained nasal gland epithelial cells. In this study, we investigated the deposition process of the amorphous material produced by nasal gland epithelial cells in the interstitium morphologically. In most cases, the amorphous materials in the clear HE-stained nasal gland epithelial cells accumulated at the basal portion. Collagen fibers surrounding the nasal glands partially disappeared, whereas the amorphous material in contact with the rough endoplasmic reticulum of the nasal gland epithelial cells continued to the amorphous material in the interstitium. These findings suggested that the amorphous material produced by the clear HE-stained nasal gland epithelial cells migrated to the interstitium through the partial opening of the basement membrane.
KEY WORDS: amorphous material, basement membrane, eosinophilic substance, mouse, nasal cavity.

*J. Vet. Med. Sci.* 71(7): 931–935, 2009

An eosinophilic substance (ES) is usually observed in the mouse nasal septum, and its volume increases with age. ES has been described as amyloid in textbooks [5, 7], but there are a few descriptions that ES is not amyloid [4, 8]. Our previous report revealed that ES is not amyloid because it reacted negatively to Congo red and there were no non-branching fibrils in the electron microscope examination [1]. Moreover, ES consisted of collagen and an amorphous material (AM), suggesting that AM is a complex carbohydrate except for the osteoglycan, because ES reacted positively with periodic acid Schiff reaction with prior diastase treatment, and negatively with toluidine blue and alcian blue [1].

In the previous study, two kinds of glands were observed in the nasal septum in mice [1]. One of them stained clear with hematoxylin and eosin (HE), the other stained dark with HE. ES deposited at the interstitium of the clear HE-stained nasal glands only. Electron microscopically, AM was observed in the clear HE-stained nasal gland epithelial cells as well as in the interstitium [1]. Glands composed of nasal gland epithelial cells holding AM were also observed in areas without interstitial AM nearby. Furthermore, AM was not only very similar to the material in the rough endoplasmic reticulum of the clear HE-stained nasal gland epithelial cells, it was also connected to it. These findings suggested that the clear HE-stained nasal gland epithelial cells produced AM [1].

It is not clear how AM produced by clear HE-stained nasal gland epithelial cells deposits in the interstitium. In this study, we investigated the deposition process histopathologically and electron microscopically.

* CORRESPONDENCE TO: DOI, T., Mitsubishi Chemical Medience Corporation, Sunayama 14, Kamisu-shi, Ibaraki, 314–0255, Japan.
e-mail: Doi.Takuya@mx.medience.co.jp

## MATERIALS AND METHODS

The animals were 5-, 42-, and 110-week-old B6C3F1/Crlj mice purchased from Charles River Laboratories Japan Inc. (Kanagawa, Japan) used in a study to collect house data. Their microbial levels were SPF (specific pathogen free). They were housed individually in cages in animal rooms maintained at a temperature of 22 ± 3°C, humidity of 55% ± 20%, with 6 to 20 air changes per hr, and a 12-hr light and 12-hr dark cycle. They were given a commercial diet (CE-2, CLEA Japan Inc.) and tap water *ad libitum*. Their health status was normal during the observation period. The antibody test results for *Clostridium piliforme*, Ectromelia virus, LCM virus, Mouse hepatitis virus, *Mycoplasma pulmonis*, and Sendai virus were negative in the monitor mice, which were housed in the same rooms as the investigated mice. Antibody tests for pathogens including Pneumonia virus of mice, Minute virus of mice, Mouse parvovirus, and *Helicobacter* spp. were not done.

Mice (5 males and 5 females each) were sacrificed at 5 or 110 weeks of age by exsanguination under anesthesia with intraperitoneal injection of sodium thiopental. Their nasal tissues were removed, fixed in 10% neutral phosphate-buffered formalin, decalcified with 10% formic acid formalin for ten days, embedded in paraffin, sectioned, and stained with hematoxylin and eosin (HE) and reticulin silver impregnation for microscopic examination. Their level II specimens (taken through the level of the incisive papilla) were used in this investigation, where ES and two kinds of glands were abundant. For electron microscopic observation, 42-week-old mice (2 females) were used. After exsanguination under anesthesia with intraperitoneal injection of

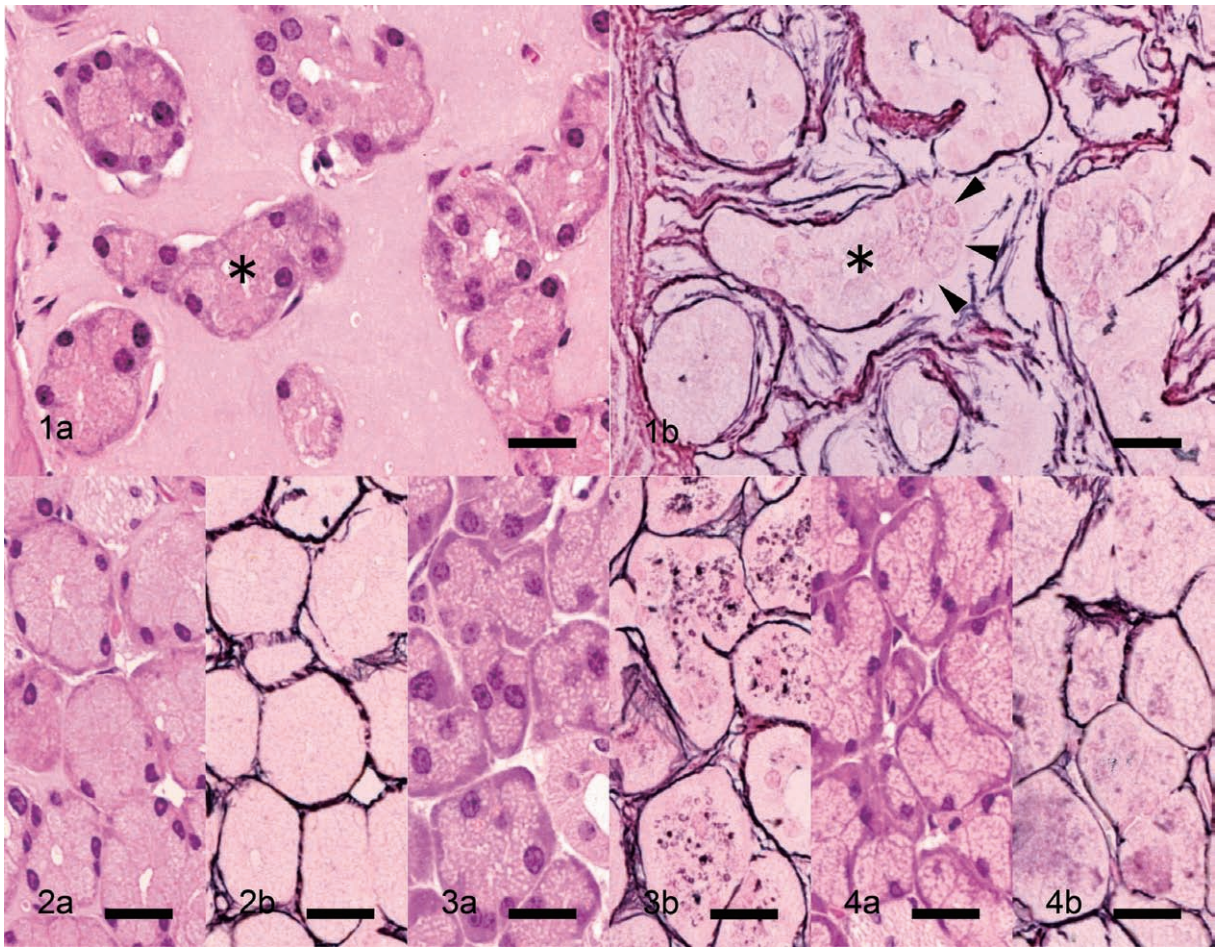


Figs. 1–4. Nasal cavity (level II); B6C3F1/Crlj mice. Figs. 1a-4a. HE. Figs. 1b–4b. Reticulin silver impregnation. Bar=18 $\mu$m.

Fig. 1. A clear HE-stained nasal gland area in a 110-week-old mouse. 1a. There is a large quantity of eosinophilic substance in the interstitium. 1b. The argyrophilic fibers surrounding the nasal glands partially disappear (arrowheads). The asterisk shows the corresponding same gland.

Fig. 2. A clear HE-stained nasal gland area in a 5-week-old mouse. 2a. A very small amount of eosinophilic substance is deposited. 2b. The nasal glands are almost completely surrounded by the argyrophilic fibers.

Figs. 3, 4. Dark HE-stained nasal gland areas in 110- (Fig. 3) and 5- (Fig. 4) week-old mice. 3a, 4a. No eosinophilic substance is deposited. 3b, 4b. The nasal glands are almost completely surrounded by the argyrophilic fibers.

sodium thiopental, small pieces of level II nasal septum tissues were fixed in 2.5% glutaraldehyde, postfixed in 1% osmium tetroxide, and embedded in epoxy resin. Ultrathin sections were stained with uranyl acetate and lead citrate. The clear HE-stained nasal gland areas were observed under an electron microscope (H-7600, Hitachi, Tokyo, Japan).

The animals were cared for according to the principles outlined in the guides for the care and use of laboratory animals prepared by the Japanese Association for Laboratory Animal Science and our institution.

## RESULTS

In the clear HE-stained nasal gland areas of 110-week-old mice, eosinophilic substance (ES) deposited markedly in the interstitium (Fig. 1a), and the argyrophilic fibers surrounding the nasal glands partially disappeared where the border between the nasal glands and the interstitium was indistinct (Fig. 1b). In the clear HE-stained nasal gland areas of 5-week-old mice, a very small amount of ES deposited (Fig. 2a), and the argyrophilic fibers surrounded the nasal glands almost completely (Fig. 2b). There was no ES in the dark HE-stained nasal gland areas of either the 5- or 110-week-old mice (Figs. 3a, 4a), and the argyrophilic fibers almost completely surrounded the nasal glands (Figs. 3b, 4b).

In the electron microscopic observation of the clear HE-stained nasal gland areas of 42-week-old mice, an amorphous material (AM) was observed in the interstitium and the nasal gland epithelial cells, but not in the fibroblasts (Fig. 5). Areas of the epithelial cells with AM in the cyto-

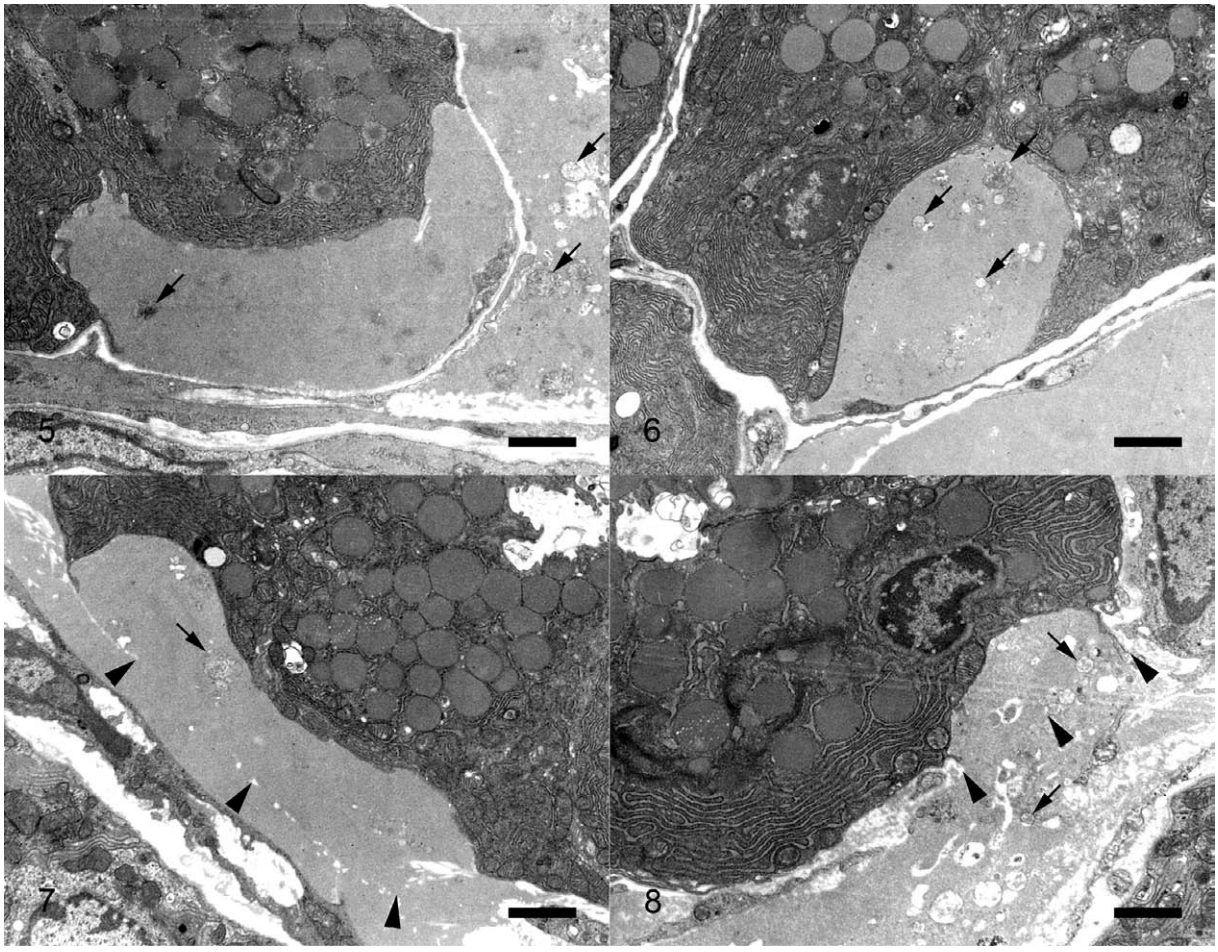


Figs. 5–8. Nasal cavity (clear HE-stained nasal gland area); 42-week-old B6C3F1/Crlj mice. Electron micrographs. Bar=1.5 $\mu$m.

Fig. 5. The amorphous material containing free organelles is observed in the cytoplasm of the nasal gland epithelial cell and the interstitium (arrows). The amorphous material in the nasal gland epithelial cell accumulates at the basal portion.

Fig. 6. The amorphous material with free organelles (arrows) is present in the nasal gland epithelial cell, but not in the nearby interstitium. The material accumulates at the basal portion of the nasal gland cell.

Figs. 7, 8. The collagen fibers surrounding the nasal gland partially disappear (arrowheads), where the amorphous material in contact with the rER of the nasal gland epithelial cells continues to that in the interstitium. The amorphous material contains some free organelles (arrows). No degenerative findings are observed in the nasal gland epithelial cells. Collagen is observed as a clear space because of its low density.

plasm and without AM at the nearby interstitium were also observed (Fig. 6). Most AM contained free organelles in the interstitium as well as in the cytoplasm of the nasal gland epithelial cells (Figs. 5, 6). AM accumulated at the basal portion and contacted with the rough endoplasmic reticulum (rER) in most of nasal gland epithelial cells with AM (Figs. 5, 6). In the interstitium, AM was distributed homogeneously without displacing the interstitial components. In some nasal glands, collagen fibers surrounding the nasal glands partially disappeared and AM in contact with the rER of the nasal gland epithelial cells continued to AM in the interstitium (Figs. 7, 8). In these areas, AM in both the nasal gland epithelial cells and interstitium also contained some free organelles (Figs. 7, 8). There was no degeneration or necrosis of the nasal gland epithelial cells even in the nasal glands where the surrounding collagen fibers partially disappeared (Figs. 7, 8).

## DISCUSSION

Our previous report revealed that eosinophilic substance (ES) in the mouse nasal septum is not amyloid, in contrast to descriptions in textbooks [5, 7], and consists of collagen and an amorphous material (AM), suggesting that AM is a complex carbohydrate and is produced by clear HE-stained nasal gland epithelial cells [1]. Moreover, the free organelles observed in AM in the nasal gland cells and the interstitium were similar, and no free organelles in the fibroblasts supported our prediction.

In this study, there was a partial disappearance of argyro-

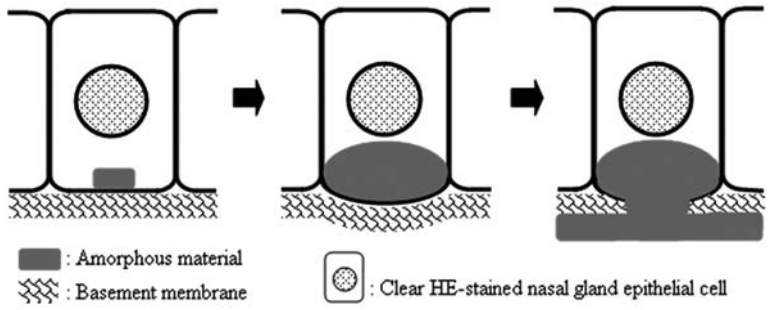


Fig. 9. Deposition process of eosinophilic substance in the mouse nasal septum. Amorphous material, a main component of ES, is produced in the clear HE-stained nasal gland epithelial cells and migrates to the interstitium through a partial opening of the basement membrane.

philic fibers surrounding the nasal glands in the clear HE-stained nasal gland areas with abundant ES in 110-week-old mice, but not in those with a very small amount of ES in 5-week-old mice. There was no disappearance of these fibers in the dark HE-stained nasal gland area without ES in either age group. These findings suggested that the basement membrane partially opened in the clear HE-stained nasal glands of the 110-week-old mice, which may have been related to the ES deposition. In the electron microscopic examination, most AM in the clear HE-stained nasal gland epithelial cells accumulated at the basal portion, and the collagen fibers surrounding the nasal glands partially disappeared, where AM in contact with the rough endoplasmic reticulum (rER) of the nasal gland epithelial cells continued to AM in the interstitium. These findings indicated that AM produced by the clear HE-stained nasal gland epithelial cells migrated to the interstitium through the partial opening of the basement membrane (Fig. 9). In the glandular cells where AM migrated to the interstitium, the cell membrane should have been opened as well as the basement membrane. In addition, there were some free organelles, i.e. exfoliative ones, in AM around the glandular cells, suggesting that the cells were damaged. In the holocrine glands such as the sebaceous glands, a secretion product is shed with the whole cell by a process involving destruction of the secretion-filled cells [6]. However, there was no destruction of the nasal gland epithelial cells even in the nasal glands where the basement membrane partially disappeared. Our previous report also revealed that neither nasal gland degeneration nor inflammation was histologically observed even if a large amount of ES was observed in the 110-week-old mice [1]. In addition, to our knowledge, there have been no reports describing a secretion product being shed through the partial opening of the basement membrane. Hence, it was suggested that ES in the mouse nasal septum was deposited by a novel process, and that AM insulated the clear HE-stained nasal gland cells.

A ground substance, physiologic extracellular amorphous matrix, is known as one of the main components of connective tissues (e.g. connective tissue proper, cartilage and bone), and contains proteoglycans, solutes, and water [3]. The homogenous distribution without displacing the interstitial components and the PAS positive property observed in this investigation strongly suggested that AM is a ground substance. To our knowledge, there have been no reports describing a ground substance being produced by epithelial cells. It was also suggested that AM is a component of the basal lamina, because materials making up the epithelial basal lamina are synthesized by epithelial cells [3]. However, AM did not form a layer structure and deposited homogeneously in the interstitium, which were not characteristic of the basal lamina.

It is not clear how the basement membrane and the cell membrane of the clear HE-stained nasal gland epithelial cells opened, although there are three possibilities. The first is that the cell membrane and the basement membrane may have been broken by mechanical pressure of AM accumulated at the basal portion of the glandular epithelial cells. However, the distention of the epithelial cells by the accumulated AM was slight and partial. This result suggests that mechanical pressure of AM is not enough to break the cell membrane or basement membrane. The second is that AM may have included some enzymes (e.g. matrix metalloproteinase [2]) degrading the cell membrane and basement membrane. However, there is a question as to why it was necessary for AM to accumulate at the basal portion of the epithelial cells before migration to the interstitium. The third is that the basement membrane may have opened autonomously in response to certain stimulation (e.g. AM accumulation). However, there were no findings in this study to support this hypothesis.

In conclusion, it was suggested that AM, a main component of ES, was produced in the clear HE-stained nasal gland epithelial cells and migrated to the interstitium through a partial opening of the basement membrane. AM may have more significances than just insulating clear HE-stained nasal gland cells, because AM purposely migrated and deposited in the interstitium. The clear HE-stained nasal gland areas, ES deposited in the interstitium, presented at the ventral nasal septum only, just dorsal to the vomeronasal organ [1, 7]. Hence, AM may have some physiological significances relating to the vomeronasal organ besides

insulating clear HE-stained nasal gland cells.

ACKNOWLEDGEMENTS. We thank Mr. Takayoshi Ito and Mr. Yuki Ikeda for their excellent technical assistance. We also thank Mr. Steve Yamakami and Ms. Ai Ishii for language editing.

REFERENCES

1. Doi, T., Kotani, Y., Kokoshima, H., Kanno, T., Wako, Y. and Tsuchitani, M. 2007. Eosinophilic Substance is "Not Amyloid" in the Mouse Nasal Septum. *Vet. Pathol.* **44**: 796–802.
2. Furness, P. N. 1997. Basement membrane synthesis and degradation. *J. Pathol.* **183**: 1–3.
3. Ghadially, F. N. 1988. Ultrastructural pathology of the cell and matrix, 3rd ed., Butterworths, London.
4. Haines, D. C., Chattopadhyay, S. and Ward, J. M. 2001. Pathology of aging B6;129 mice. *Toxicol. Pathol.* **29**: 653–661.
5. Herbert, R. A. and Leininger, J.R. 1999. Nose, Larynx, and Trachea. pp. 259–292. *In*: Pathology of the Mouse (Maronpot, R. R. ed.), Cache River Press, Vienna, IL.
6. Junqueira, L. C. and Carneiro, J. 2002. Basic Histology, 10th ed., Appleton and Lange.
7. Leininger, J. R., Herbert, R. A. and Morgan, K. T. 1996. Aging change in the upper respiratory tract. pp. 247–260. *In*: Pathobiology of the Aging Mouse, vol. 1 (Mohr, U., Dungworth, D. L., Capen, C. C., Carlton, W. W., Sundberg, J. P. and Ward, J. M. eds.), ILSI Press, Washington, D.C.
8. Monticello, T. M., Morgan, K. T. and Uraih, L. 1990. Nonneoplastic nasal lesions in rats and mice. *Environ. Health. Perspect.* **85**: 249–274.