

## Case Report

# Isolated Abducens Palsy as the First Presenting Sign of Multiple Sclerosis

Sargon Bet-Shlimon Mill Etienne

New York Medical College, New York, NY, USA

## Keywords

Multiple sclerosis · Abducens palsy · Cranial nerve · MRI · Brain stem

## Abstract

While brain stem involvement in multiple sclerosis (MS) is relatively common, isolated cranial nerve palsies are rare, especially when they represent the initial presenting sign of a new diagnosis of MS. This report describes a patient with no prior history of MS whose sole presenting sign was an isolated abducens palsy. An enhancing pontine lesion was found on MRI which correlated with his abducens palsy, and additional nonactive lesions on MRI led to a diagnosis of MS. This case demonstrates the importance of considering MS as part of the differential diagnosis of patients with isolated cranial nerve palsies.

© 2016 The Author(s)  
Published by S. Karger AG, Basel

## Introduction

Multiple sclerosis (MS) is a chronic, autoimmune, demyelinating disease of the central nervous system (CNS). Presenting symptoms can vary greatly, but most commonly involve weakness, paresthesia, gait difficulty, or visual deficits [1]. Virtually any area of the CNS white matter can be involved, though this most classically involves the periventricular white matter. Brain stem involvement is common, though isolated cranial nerve palsies are rare signs in MS. Previous studies have suggested that isolated cranial nerve palsies in MS are

more commonly found as presenting symptoms than as relapsing symptoms [2]. Among isolated cranial nerve palsies in MS, the fifth nerve is most commonly involved (4.8%), followed by the seventh nerve (3.7%), and the sixth nerve (1.0%) [3]. Thus, abducens palsy is a rare isolated MS finding, either as a presenting sign or during disease exacerbation. Patients with abducens palsy typically present with diplopia upon horizontal gaze, and examination can reveal a slow ipsilateral lateral rectus movement [4, 5]. MS has been implicated as the cause of unilateral abducens palsy in 4–9% of cases [4], though MRI may not detect brain stem lesions in all cases [6]. One 2002 study investigating nontraumatic causes of sixth nerve palsies in patients 20–50 years of age found MS to be the cause in 24% of cases [7]. In addition to MS, the differential diagnosis for an abducens nerve palsy includes mass lesions, Lyme disease, viral infection, syphilis, sarcoidosis, and vascular disease [7].

Here, we report a patient who presented with a unilateral isolated abducens palsy as the initial sign of MS.

### Case Description

A 28-year-old man with a past medical history of hypertension and obesity presented to the emergency department with a 1-day history of double vision, most prominent upon left lateral gaze. The double vision resolved with covering either eye. In addition, he had a 1–2-week history of paresthesia of the distal right hand and forearm, and the fifth digit of the right foot. Physical examination was significant only for left lateral rectus palsy. All other cranial nerves were intact and no other neurological abnormalities were noted. Initial laboratory findings revealed only a mild leukocytosis ( $11.3 \times 10^9/L$ ) and no other hematologic or electrolyte abnormalities. A noncontrast CT scan of the brain showed no abnormalities. MRI of the brain and spinal cord was performed with and without gadolinium contrast. Several focal areas of increased T2 signal intensity were noted within the periventricular white matter of the frontal and parietal lobes, subcortical white matter of the left temporal lobe, and the left pons. The pontine lesion was enhancing (Fig. 1). Within the spinal cord, the left side of the C5–C6 spinal cord demonstrated a T2 hyperintensity. These findings likely represented multiple lesions distributed in both time and space, and, along with the patient's clinical history and examination, were suggestive of a diagnosis of MS.

The patient was admitted and started on intravenous methylprednisolone. Further workup to rule out other etiological causes of illness revealed an elevated ESR of 25 mm/h, negative viral and Lyme serologies, NMO IgG negative and a negative ANA. He was treated with methylprednisolone 500 mg intravenously for 3 days and then discharged home. He had resolution of the paresthesia 1 day after starting the steroids. He was re-evaluated in the office 2 days after hospital discharge and had complete resolution of the CN VI palsy.

### Discussion

Brain stem involvement in MS is common, though isolated nerve palsies are not. Isolated nerve palsies occur in only 10.4% of patients with MS, with abducens palsy as the third most common isolated nerve palsy, occurring in 1.0% of patients with MS, behind trigeminal (4.8%) and facial (3.7%) [3]. These palsies occur most commonly at disease onset, though they can also occur during the course of the disease [2].

Our patient presented with left abducens palsy and right distal limb paresthesia. The lesion in the medial pons was enhancing and thus consistent with an active lesion, and the location was consistent with his CN VI palsy. The sixth nerve nucleus is located in the pontine tegmentum, and a compact fiber tract bundle containing motor neurons from this nucleus runs medially towards the ventral region, where the cranial nerve exits the pons [3, 8]. Our patient's pontine lesion appeared to be located along the fiber tract emerging from the sixth nerve nucleus, and correlates with his diplopia. While an MRI lesion was detected clearly in this case, it should be noted that previous authors have found that MRI does not always detect brain stem lesions accounting for these palsies in MS patients [4, 6].

In any patient presenting with isolated cranial nerve palsies, MS must be considered within the differential diagnosis. In patients younger than 50 years of age (as with our patient), infectious causes (Lyme disease, viral infections, syphilis), sarcoidosis, and autoimmune vasculitis should also be considered on the differential diagnosis, whereas for older patients small vessel vascular disease should be considered as well [7, 8]. The presence of multiple presenting neurological deficits including cranial nerve palsies is suspicious for MS and should be investigated with MRI. Though MRI may not always detect brain stem lesions responsible for cranial nerve palsies, it can reveal other white matter lesions of the CNS that can aid in the diagnosis of MS, as was the case with our patient.

### Statement of Ethics

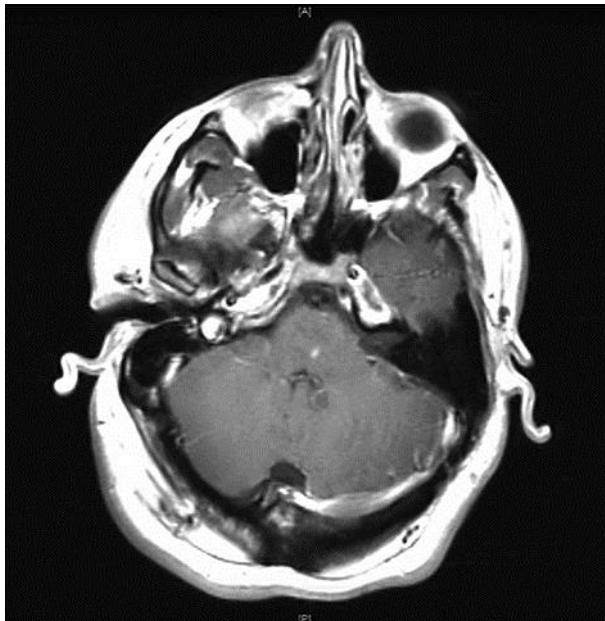
Informed consent was obtained from the patient for his participation in this case report.

### Disclosure Statement

The authors have no conflicts of interest to disclose. This case report was not funded.

### References

- 1 Swanson JW: Multiple sclerosis: update in diagnosis and review of prognostic factors. *Mayo Clin Proc* 1989;64:577–586.
- 2 Zadro I, Barun B, Habek M, Brinar VV: Isolated cranial nerve palsies in multiple sclerosis. *Clin Neurol Neurosurg* 2008;110:886–888.
- 3 Uzawa A, Mori M, Ito S, Kuwabara S: Isolated abducens and facial nerve palsies due to a facial collicular plaque in multiple sclerosis. *J Neurol Neurosurg Psychiatr* 2011;82:85–86.
- 4 Barr D, Kupersmith MJ, Turbin R, Bose S, Roth R: Isolated sixth nerve palsy: an uncommon presenting sign of multiple sclerosis. *J Neurol* 2000;247:701–704.
- 5 Muhammed K, Ball J: Multiple sclerosis causing a partial sixth nerve palsy. *BMJ Case Rep* 2014;2014. pii: bcr2013201239.
- 6 Thömke F, Lensch E, Ringel K, Hopf HC: Isolated cranial nerve palsies in multiple sclerosis. *J Neurol Neurosurg Psychiatr* 1997;63:682–685.
- 7 Peters GB, Bakri SJ, Krohel GB: Cause and prognosis of nontraumatic sixth nerve palsies in young adults. *Ophthalmology* 2002;109:1925–1928.
- 8 Mitchell JP, Beer J, Yancy A, Saint-Louis LA, Rosberger DF: Lateral rectus muscle palsy, facial numbness and ataxia as the initial manifestation of multiple sclerosis. *J Natl Med Assoc* 2008;100:572–574.



**Fig. 1.** T1 postcontrast MRI showing left pontine enhancing lesion.