

# Robotic and video-assisted thoracic surgery lung segmentectomy for malignant and benign lesions<sup>†</sup>

Adalet Demir<sup>a,\*</sup>, Kemal Ayalp<sup>b</sup>, Berker Ozkan<sup>a</sup>, Erkan Kaba<sup>b</sup> and Alper Toker<sup>a,b</sup>

<sup>a</sup> Thoracic Surgery Department, Istanbul University, Istanbul School of Medicine, Istanbul, Turkey

<sup>b</sup> Thoracic Surgery Department, Group Florence Nightingale Istanbul Hospital, Istanbul, Turkey

\* Corresponding author. Department of Thoracic Surgery, Istanbul University, Istanbul School of Medicine, 34093 Fatih, Istanbul, Turkey. Tel: +90-212-4142200; e-mail: dradalet@hotmail.com (A. Demir).

Received 18 August 2014; received in revised form 17 October 2014; accepted 3 November 2014

## Abstract

**OBJECTIVES:** The experience with robotic techniques (RATS) and video-assisted thoracic surgery (VATS) in pulmonary segmentectomy is still limited. We evaluated our prospectively recorded database to compare two different minimally invasive techniques.

**METHODS:** Between May 2007 and July 2014, a total of 99 patients underwent RATS ( $n = 34$ ) and VATS ( $n = 65$ ) pulmonary segmentectomies at two institutions. The median age of patients was  $59 \pm 15$  (16–84) years, and 61% were male. Seventy-six patients were operated on for malignancy and 23 for benign diseases.

**RESULTS:** The major morbidity and mortality rates were 24–23% and 0–1.5% for RATS and VATS ( $P = 0.57$ ) and ( $P = 0.66$ ), respectively. The mean console time for RATS was longer than the mean operation time for VATS [ $76 \pm 23$  (40–150) vs  $65 \pm 22$  (30–120) min ( $P = 0.018$ )]. The mean duration of drainage was similar for RATS and VATS [ $3.53 \pm 2.3$  (1–10) days vs  $3.98 \pm 3.6$  (1–21) ( $P = 0.90$ )], respectively. The duration of postoperative stay for RATS was  $4.65 \pm 1.94$  (2–10) days and for VATS was  $6.16 \pm 4.7$  (2–24) days ( $P = 0.39$ ).

**CONCLUSIONS:** Both RATS and VATS pulmonary segmentectomy operations are performed with similar morbidity and mortality rates. Although the duration of operation is longer in RATS when compared with an established VATS programme, there is a tendency towards a shorter postoperative stay.

**Keywords:** Lung resection • Robotic surgery • Video-assisted thoracic surgery • Segmentectomy • Lung cancer

## INTRODUCTION

Anatomical segmentectomy of the lung is the removal of a segment of the lobe. For many decades pulmonary segmentectomy has been used for the treatment of bronchiectasis and tuberculosis via thoracotomy. Recently, with developments in video instrumentation and refinements in surgical techniques, video-assisted thoracic surgery (VATS) has been a popular approach for segmentectomy. It has been preferred for tumours <2 cm and negative lymph nodes [1, 2] and for larger tumours in patients with poor pulmonary function, especially those who cannot tolerate lobectomy and who do not have visceral pleural invasion [2, 3]. Although VATS has been used for segmentectomy for the past 5 years, robotic anatomical lung segmentectomy has been reported rarely in the pubmed search [4–9].

As academic thoracic surgery centres performing minimally invasive anatomical lung resections with VATS for 8 years, we have recently developed a robotic surgery programme with the da Vinci Robotic System (Intuitive Surgical, Inc., Mountain View, CA, USA) which started in October 2011.

We evaluated our database of complete minimally invasive segmentectomies to compare the two different minimally invasive surgical techniques.

## PATIENTS AND METHODS

This is a retrospective study using a prospective database of a consecutive series of patients who underwent anatomical segmentectomy. Between May 2007 and July 2014, a total of 314 consecutive patients underwent robotic techniques-assisted thoracic surgery (RATS) ( $n = 72$ ) or VATS ( $n = 242$ ) anatomical lung resections at two institutions. RATS pneumonectomy, lobectomy and segmentectomy operations were performed in 2, 36 and 34 patients, respectively. Also, VATS pneumonectomy, lobectomy and segmentectomy operations were performed in 2, 175 and 65 patients, respectively.

In this study, we reviewed the outcomes of 99 patients who underwent VATS ( $n = 65$ ) and RATS ( $n = 34$ ) segmentectomies. The data of anatomical segmentectomy patients were retrieved from the prospectively recorded database. The median age of patients was  $59 \pm 15$  (16–84) years, and 60% ( $n = 61$ ) were male. Resections were performed primarily for clinical stage I bronchogenic carcinoma ( $n = 55$ ), solitary pulmonary metastases ( $n = 21$ ) and benign lung conditions ( $n = 23$ ). In RATS segmentectomy 1 patient was

<sup>†</sup>Presented at the 22th European Conference on General Thoracic Surgery, Copenhagen, Denmark, 15–18 June 2014.

converted to open surgery in order to repair trachea due to the laceration of the membranous trachea during intubation; in VATS segmentectomy 3 patients were converted due to bleeding ( $n = 1$ ) and technical difficulties ( $n = 2$ ). These patients were excluded from the study.

In general, patients with (i) positron emission tomography/computed tomography (PET-CT) verified pulmonary nodules that were clinically suspected of a primary lung malignancy, (ii) a single pulmonary nodule with a history of previous extrapulmonary malignancy and (iii) clinically resectable non-small cell lung cancer (NSCLC) were selected as candidates. Particularly, an anatomical segmental lung resection for suspicious lung cancer was performed based on the following criteria: (i) a suspicious lesion (with PET-CT findings)  $<2.0$  cm in diameter located in close proximity to segmentary bronchial structures, (ii) clinical stage IA NSCLC with station 11 and 12 negative lymph nodes with frozen section analysis, (iii) any size of lung cancer in a patient with poor cardiopulmonary functional reserve with technical suitability.

For metastasectomies, only single-lung lesions close to the segmentary bronchus were selected among the gastrointestinal, renal, soft tissue and breast cancer metastases.

The patients with other pathological benign lung conditions such as bronchiectasis and localized fungal infections were selected. Operations for indeterminate nodules were performed either after localization of the nodule with operative view (retraction of visceral pleura), after digital palpation or evaluation by 3D images of chest tomography.

### Mediastinal lymph node evaluation prior to operation

When there was a suspicious lymph node in the mediastinum with PET-CT evaluation in a preoperatively diagnosed lung cancer patient, we preferred to perform a cervical mediastinoscopy. If the primary lung lesion did not have a preoperative histopathological diagnosis, we performed a cervical mediastinoscopy in left-sided lesions; we started with VATS or RATS in right-sided lesions, did a mediastinal lymph node dissection and performed segmentectomy if the nodes were clear. Also, hilar and peribronchiolar lymph nodes were dissected and suspicious nodes were examined with frozen section analyses. In case of hilar or peribronchiolar lymph node positivity, we converted the resection to a lobectomy operation.

Patients who underwent segmentectomy for metastatic disease had mediastinal lymph node dissections for renal and gastrointestinal tumours. For others, only suspicious lymph nodes were resected.

### Surgical technique

In general, segmentectomy is performed by separately ligating and dividing the vein, artery and bronchus of single or more segments. We isolate the boundaries of the segments by inflating and deflating the lung. We separate the segment from the remnant lobe with endostaplers. All RATS operations are performed by single console (AT) surgeon. RATS operations are performed with da Vinci S (First 10 cases) and SI (24 cases).

### Docking of the robot and port selections

The patient is positioned on the lateral decubitus position. The table is tilted either anteriorly or posteriorly depending on the

type of segmentectomy operation to be performed. For anteriorly located segments—lingula, lingula-sparing upper lobe, common basal segments of the left lower lobe and common basal segment of the right lower lobe—the posterior tilt is preferred. For superior segments of both the lower lobes and posterior segment of the right upper lobe the anterior tilt is preferred. Three ports are opened while trying to keep a distance of 10 cm between each port and 10–15 cm from the target, which is the hilum of the lobe containing the segment to be resected (Fig. 1a–c). The camera is placed in the middle port. The robot is docked at the posterior of the patient with 30–45° between the vertebral column of the patient and the transverse axis of the cart. With the robotic camera in the up position, the ports and instruments are placed and the pleural symphysis is divided. The service port is opened at the 10th–11th intercostal space at the posterior part of the thoracic wall (Fig. 2a and b). The rest of the operation is done with the camera in the down position. Maryland or curved bipolar forceps for the right arm and prograsper for left arm are used and swapped between arms when needed.

### Video-assisted thoracic surgery port selections

The VATS segmentectomy is performed by introducing a 10-mm, 30-degree thoracoscope through a thoracoscopic port placed in the anterior axillary line in the seventh intercostal space. Two additional access incisions, one in the anterior and one in the posterior chest wall, were made until 2012. From then on we did biportal segmentectomy operations.

### Segmentectomy technique

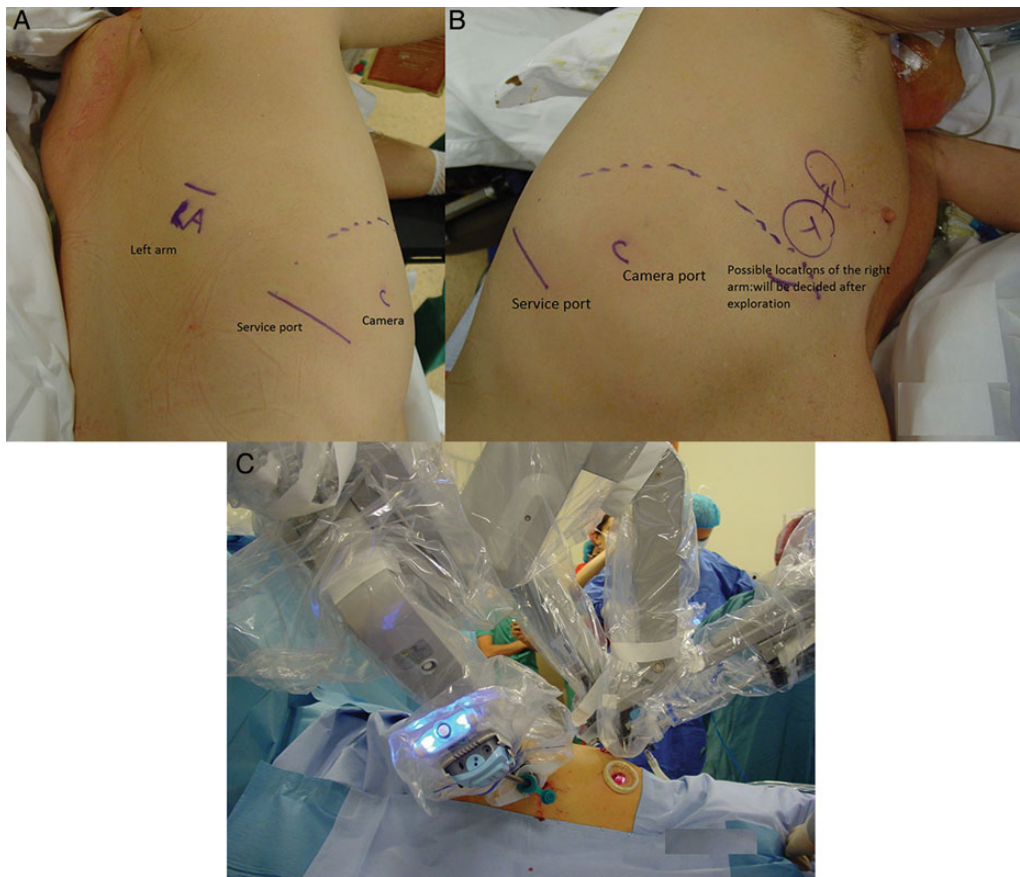
In both techniques, we use similar intraoperative approaches. Segmentectomies are performed by dissecting the fissure and removing the nodes around the segmentary artery and bronchus. Arteries and veins are clipped with a Hem-o-Lok (Teleflex Medical, Research Triangle Park, NC, USA) or are stapled. The bronchi are always stapled. The imaginary inter-segmental plane is stapled after ventilating and deflating the remnant lung. Glues or sealants are never used in any of the patients. The chest is closed by placing a single 28-F chest tube from the camera port.

**Adhesion score.** The interior part of the hemithoracic cavity is divided into five imaginary equal parts and the major fissure constitutes the fifth part. The area of the pleural adhesion is recorded and scored from 0 to 5 by the operating surgeon after each operation.

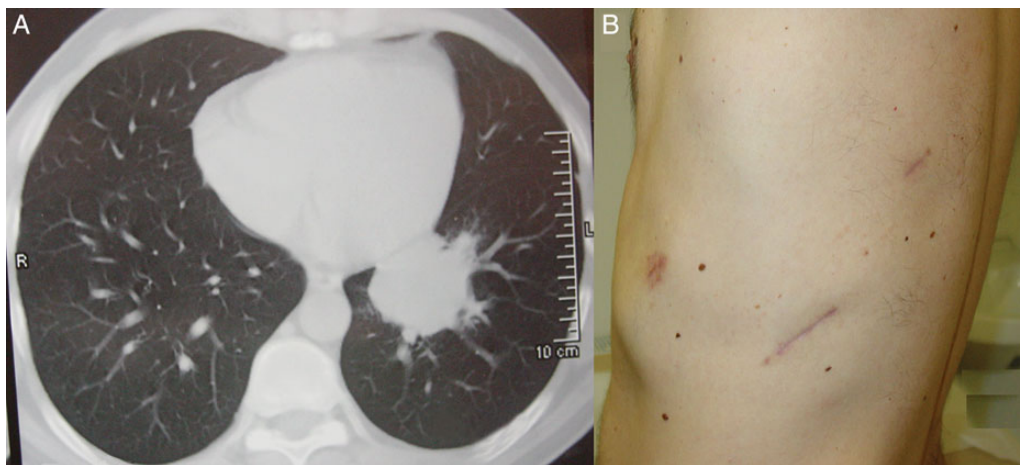
**Pain management.** Routine pain management is with intercostal block—not more than 20 ml Marcain (Astra Zeneca, Istanbul)—around the ports, paracetamol intravenous infusion every 6 h and anti-inflammatory intramuscular injections. After the discharge of the patient, oral medication with paracetamol and anti-inflammatory drugs are given.

### Discharge protocol

Chest tubes are removed during the hospital stay if the length of stay is shorter than 5 days. If the drainage lasts longer and the patients do not have any other additional problems, then the



**Figure 1:** (A) Planning of incisions for a right lower lobe common basal robotic segmentectomy candidate (posterior view). (B) Anterior view. (C) Operative view. Please note the soft tissue retractor placed at the service port.



**Figure 2:** (A) An undiagnosed mass at the left lower lobe in a 37-year old male. After a left lower lobe common basal segmentectomy operation, the diagnosis was established as *Echinococcus alveolaris*. (B) Postoperative view of incisions used during robotic left lower lobe common basal segmentectomy.

patients are discharged with chest tubes attached to the Heimlich valve. The chest tubes are removed later on an out-patient basis.

## RESULTS

Thirty-four patients had segmentectomies with RATS with the following indications: 19 (56%) patients for primary lung cancer, 5

(15%) patients for single pulmonary metastases (4 patients for colon carcinoma and 1 patient for uterus leiomyoma), 10 (29%) patients were operated on for benign diseases (granuloma in 4 patients, bronchiectasis in 1 patient and *Echinococcus alveolaris* in 1 patient).

VATS segmentectomies were performed with the following indications: 36 (55%) patients for primary lung cancer, 16 (25%) patients for single pulmonary metastases (6 patients for colon carcinoma, 4 patients for osteosarcoma metastases, 3 patients for residual germ



cell tumours, 1 patient for bladder carcinoma and 1 patient with ovarian carcinoma). Thirteen (20%) patients were operated on for benign diseases (granuloma in 6 patients, hamartoma in 5 patients, bronchiectasis in 1 patient and aspergilloma in 1 patient).

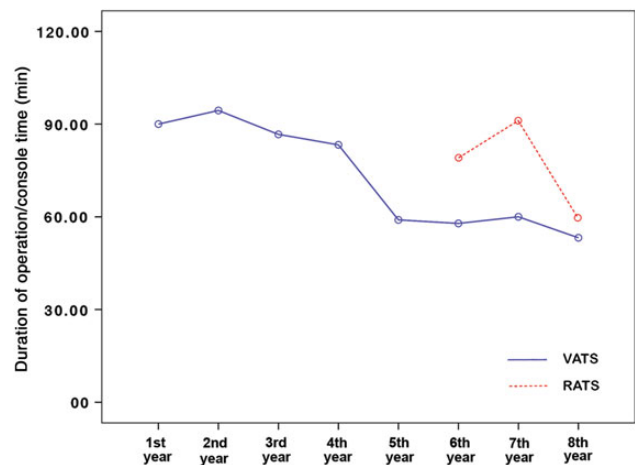
In the RATS segmentectomy group, 34 segmentectomies were performed: 18 from the right lung and 16 from the left lung. Common basal segmentectomy (11 patients), superior segmentectomy of the lower lobes (9 patients), lingula-sparing lobectomy (7 patients), apicoposterior segmentectomy (4 patients) and lingulectomy (3 patients) of the upper lobes were the types of segmentectomies performed. In the VATS segmentectomy group, 65 segmentectomies were performed: 31 from the right lung and 34 from the left lung. Lingula-sparing lobectomy (13 patients), lingulectomy (13 patients), common basal segmentectomy (13 patients), superior segmentectomy of the lower lobes (12 patients), apical segmentectomy (7 patients) and apicoposterior segmentectomy (7 patients) were the types of segmentectomies performed.

In the RATS and VATS groups, the mean diameters of the malignant lesions were 1.8 (1–4.3) cm and 2.6 (1.3–4.3) cm, respectively. The morbidity and mortality rates for the RATS and VATS groups were 24–23% and 0–1.5%, respectively ( $P = 0.57$  and  $P = 0.66$ ). One patient died in the VATS group after the lingula-sparing left upper lobectomy due to pneumonia that may have resulted from an underlying immunodeficiency. The mean force expiratory volumes in 1 s (FEV<sub>1</sub>) were  $2226 \pm 609$  ml in the RATS group and  $2310 \pm 767$  in the VATS group ( $P = 0.41$ ) (Table 1).

The mean console time for RATS was longer than the mean operation time for VATS [ $76 \pm 23$  (40–150) vs  $65 \pm 22$  (30–120) min ( $P = 0.018$ )]. The yearly change in the mean duration of operations are demonstrated in Fig. 3. The mean duration of drainage was similar for RATS and VATS [ $3.53 \pm 2.3$  (1–10) days vs  $3.98 \pm 3.6$  (1–21) ( $P = 0.90$ ), respectively]. The duration of postoperative stay for RATS was  $4.65 \pm 1.9$  (2–10) days and for VATS was  $6.16 \pm 4.7$  (2–24) days ( $P = 0.39$ ). Adhesion scores were similar in both groups [ $0.62 \pm 1.15$  (0–4) for RATS and  $0.94 \pm 1.36$  (0–5) for VATS ( $P = 0.15$ )] (Table 1).

## DISCUSSION

While lobectomy is the gold standard procedure for early-stage lung cancer, the role of sublobar resection is currently under investigation for selected patients with small tumours. Basically, for a segmentectomy operation for a lung cancer patient, there are two major concerns: oncological satisfaction of a segmentectomy operation and the place of minimally invasive surgery. Segmentectomy results in a greater preservation of lung function and exercise capacity than lobectomy does. It appears reasonable to consider segmentectomy for patients with stage I lung cancer (particularly in air-containing tumours with ground-glass opacities) where tumours are <2 cm in diameter and acceptable segmental margins are



**Figure 3:** This figure demonstrates yearly changes in the mean duration of VATS and console time of RATS segmentectomy operations. With increasing experience both groups showed a decrease in duration of operations. This change seems to be sharper in robotic segmentectomy operations bringing both lines to almost similar levels. But the RATS console time is significantly longer than the VATS segmentectomy operation duration. VATS: video-assisted thoracic surgery; RATS: robotic techniques-assisted thoracic surgery ( $P = 0.018$ ).

**Table 1:** Demographics of the anatomical segmentectomies with RATS and VATS

	Total (n = 99)	RATS (n = 34)	VATS (n = 65)	P-value
Age	59 ± 15 (16–84)	61 ± 15 (16–84)	57 ± 14 (18–82)	0.16
Gender				0.52
Female	39 (39%)	13 (38%)	21 (40%)	
Male	60 (61%)	26 (62%)	39 (60%)	
Side				0.39
Right	49 (49.5%)	18 (53%)	31 (48%)	
Left	50 (50.5%)	16 (47%)	34 (52%)	
Mean FEV <sub>1</sub> (ml)	2280 ± 713 (1300–4500)	2226 ± 609 (1300–4500)	2310 ± 767 (1030–4160)	0.41
Conversion to thoracotomy	4 (4%)	1 (2.9%)	3 (4.6%)	0.66
Duration of surgery (min)	69 ± 23 (30–150)	76 ± 23 (40–150)	65 ± 22 (30–120)	0.018
Mean duration of drainage (days)	3.8 ± 3.2 (1–21)	3.53 ± 2.3 (1–10)	3.98 ± 3.6 (1–21)	0.90
Mean duration of postoperative stay (days)	5.6 ± 4 (2–24)	4.65 ± 1.9 (2–10)	6.16 ± 4.7 (2–24)	0.39
Adhesion score	0.8 ± 1.28 (0–5)	0.62 ± 1.15 (0–4)	0.94 ± 1.36 (0–5)	0.15
Morbidity rate	23 (23%)	8 (24%)	15 (23%)	0.57
Mortality rate	1 (1%)	0	1 (1.5%)	0.66
Pathology				0.32
Malignant	76 (77%)	24 (71%)	52 (80%)	
The others	23 (23%)	10 (29%)	13 (20%)	

FEV<sub>1</sub>: force expiratory volumes in 1 s; RATS: robotic techniques-assisted thoracic surgery; VATS: video-assisted thoracic surgery.

obtainable with negative N1 level lymph nodes, especially in patients with advanced age, poor performance status and/or poor cardiopulmonary reserve [10, 11]. Segmentectomy studies published in previous decades generally include patients with compromised pulmonary or cardiac functions. However, our study generally includes patients with a good performance status. Both the RATS and VATS groups clearly show a mean pulmonary forced expiratory volume in the first second higher than 2 l. In our series, there are few patients with compromised pulmonary functions or a tumour >2 cm. In our patients, instead of a single segment, we generally perform the resection of multiple segments such as a lingula-sparing upper lobectomy, lingulectomy or common basal segmentectomy operations.

Secondly, the place of minimally invasive surgery is still a matter of concern. VATS demonstrates to be minimally invasive by decreasing postoperative pain, providing shorter recovery, decreasing inflammatory response and improving tolerance to chemotherapy [12–15]. VATS segmentectomy proved to be a safe procedure with fewer complications and a lower hospital stay when compared with an open segmentectomy [16]. The perioperative outcomes—including the operative time, blood loss, duration of chest tube drainage and length of hospital stay—prove to be similar in another study comparing open and VATS segmentectomy operations [17]. This study also demonstrates that thoracoscopic segmentectomy is feasible with perioperative and oncological outcomes for stage IA NSCLC, especially T1a and a carefully selected T1b descriptor with suitable anatomical location [17]. Thoracoscopic segmentectomy is compared with thoracoscopic lobectomy when analysing oncological results in small ( $\leq 2$  cm) peripheral stage IA NSCLC patients [18]. Local recurrence rates with thoracoscopic segmentectomy (5.1%) are reported to be similar to those of thoracoscopic lobectomy (4.9%). No significant difference is observed in 5-year overall or disease-free survival [18]. Recent literature also demonstrates support for less invasive video-assisted thoracoscopic surgical techniques in pulmonary segmentectomy operations, such as uniportal and total thoracoscopic segmentectomies [19, 20].

Also, it is speculated that some indeterminate lesions without preoperative diagnosis may need a segmentectomy operation, just in case the lesion turns out to be a primary lung cancer, to have a complete resection. Such lesions may be technically resected with wedge resection. However, when the resection turns out to be a lung cancer, it may be technically unsound to complete this wedge resection with a segmentectomy operation. This may explain the reason for segmentectomy operations for benign conditions in our study groups.

Growing knowledge on robotic lobectomies for lung cancer would provide additional experience for performing segmentectomy operations for lung cancer. It is clear that, as lung screening programmes increase around the world, the need for minimally invasive segmentectomies also increases. Certainly, the promising results of the recently published robotic lung segmentectomies may open a new era in minimally invasive surgery [4–10].

In recently published articles about robotic surgery 35 segmentectomy patients [5] and 17 segmentectomy [4] patients from 2 centres are reported. The mean duration of surgery is 189 min with no major intraoperative complications or conversions to open procedure [4]. In this study, the postoperative morbidity rate is 17.6% with a median postoperative stay of 5 days (range, 2–14) and the postoperative mortality rate is 0 [4]. The final pathology is reported to be NSCLC in 8 patients, typical carcinoids in 2 and lung metastases in 7. As study [5] describes a robotic series of almost 200 patients with mainly lobectomies, we do not have

detailed data regarding segmentectomy operations. In the most recent published experience by Nasir *et al.* [7], out of 862 robotic operations 71 are reported to be segmentectomy operations. In this study, the authors conclude that the removal of lymph nodes with robotic operations is excellent with very low morbidity and mortality rates. The disadvantages are reported to be higher capital costs, a learning curve and a lack of palpation [7].

In our study, the duration of segmentectomy operations with VATS is significantly shorter than the duration of the console time of the RATS segmentectomy group. The duration of surgery, although given as a console time in the robotic group, would otherwise be the docking and closure times: we analyse the console time because the duration of docking time decreases with increasing experience. In our experience, we reduce the time from 45 min to <10 min. The shorter duration in VATS segmentectomy may be related to the experience of ~250 VATS anatomical resections performed in both departments. It may be seen from Fig. 3 that the duration of both operations reached similar levels as the maturity in robotic surgery increased. Actually, with increasing experience both groups showed a decrease in duration of operations. This change seems to be sharper in robotic segmentectomy operations (Fig. 3).

The duration of console time in our robotic surgery experience should not be considered as long when compared with recently published series; it is actually shorter than some of the experience with VATS [7, 18]. The mean console robotic operating time is 76 min, which is quite similar to that of Dylewski's robotic surgery experience [5]. Our VATS segmentectomy duration is even shorter (a mean of 65 min). We may suppose that the VATS experience reflects the robotic one.

Our indications, especially the rate of malignancy, and the perioperative and postoperative outcomes are quite similar to those of Pardolesi *et al.* [4]. Our only complication in the RATS group is prolonged air leaks that last longer than a week. The prolonged length of stay is mostly due to prolonged air leak. We generally wait until the cessation of the leak and generally hesitate to discharge patients with Heimlich valves. Volume of drainage is rarely a problem in our postoperative course.

The mean duration of chest tube drainage and postoperative hospital stay of the VATS group are  $3.98 \pm 3.6$  days and  $6.16 \pm 4.3$  days, respectively. Although the mean duration of postoperative stay is longer in the VATS group, it does not reach a statistically significant level.

We describe an adhesion scoring system, which has not been used previously according to the literature. Adhesions may not only cause a prolongation of the surgical period but also may affect the number of complications in patients. Our study demonstrates a score of 0.89 with a range of 0–5 in our patients totally, 0.62 for RATS and 0.94 for VATS. Although these show no statistical difference, it may explain the reason for the prolonged length of stay in VATS patients in our population.

We do not experience any major morbidity and mortality in the RATS group, although 5 of our patients are unsuitable candidates for lung resection due to their compromised pulmonary, renal and cardiac problems. However, 1 patient in the VATS group, who had been evaluated for immunocompromised conditions preoperatively and did not receive a diagnosis preoperatively, died due to pneumonia and multiorgan failure.

Our surgical techniques in robotic surgery demonstrate similarities with those of Pardolesi *et al.* [4]. Unlike his access port, albeit similar in size [4], our service port is located at the posterior thoracic cavity at the 10th–11th intercostal space. This port may allow greater movement of the equipment within the cavity and may

avoid injury of the mammary gland in female patients. In our experience, we used only 1 Maryland forceps and 1 Prograsper forceps for each patient. Expenditures for these including the drapes cost a total of 600 USD, excluding the maintenance and initial costs of the robot. VATS demonstrated to be a more economical and a less operation theatre-occupying procedure for robotic wedge and lobectomy cases [9, 21]. Our study supports these data.

The major difficulty in robotic segmentectomy operation is resection without palpation, as commented on by Nasir *et al.* [7]. This challenge is overcome by palpating and tattooing the lesion prior to the implementation of the robotic arms. 3D images are used to identify the lesion and the relation of it with the vessels and the bronchus. Segmentectomy operation with robotic surgery requires a good knowledge of the anatomy of pulmonary vessels and bronchi in each patient [11]. Prior knowledge of the anatomy of each patient contributes to the safety and accuracy of the operation [22]. It is reported that presurgical planning based on the patient's actual 3D pulmonary model is useful for patients with stage IA NSCLC  $\leq 2$  cm in diameter and for selecting an appropriate VATS lung resection for each patient [22]. Apparently, this may be a required preoperative evaluation in robotic segmentectomy as well. We always consult with experienced radiologists before each operation to delineate the borders of the resection from axial, coronal and sagittal tomographies. Especially for metastasectomies, CT image evaluation on monitors with a qualified radiologist ensures that the lesion is solitary.

The rate of nodal upstaging for robotic resection appears to be superior to VATS and similar to thoracotomy data when analysed by clinical T stage [23]. Developing a robotic programme requires preparation and patience to overcome the difficulties of correct docking and dissection techniques.

## LIMITATIONS

This is not a prospective randomized study. Patients are selected according to their preferences. Although the propensity score matching is not performed, the patients' preoperative data demonstrate to be comparable and similar. The early experiences of robotic cases are compared with the highly experienced VATS cases. These findings may change with increasing experience with the robotic surgery arm.

In conclusion, both RATS and VATS pulmonary segmentectomy operations are performed with similar morbidity and mortality rates. RATS seems to be a promising surgical technique that may provide longer duration of operations when compared with an established VATS programme and RATS has a tendency towards shorter hospital stay. Larger series of matched RATS, VATS and open approaches are necessary especially for segmentectomy patients.

**Conflict of interest:** none declared.

## REFERENCES

- Keenan RJ, Landreneau RJ, Maley RH Jr, Singh D, Macherey R, Bartley S *et al.* Segmental resection spares pulmonary function in patients with stage I lung cancer. *Ann Thorac Surg* 2004;78:228–33.
- Koike T, Yamato Y, Yoshiya K, Shimoyama T, Suzuki R. Intentional limited pulmonary resection for peripheral T1 N0 M0 small-sized lung cancer. *J Thorac Cardiovasc Surg* 2003;125:924–8.
- Wolf AS, Richards WG, Jaklitsch MT, Gill R, Chirieac LR, Colson YL *et al.* Lobectomy versus sublobar resection for small (2 cm or less) non-small cell lung cancers. *Ann Thorac Surg* 2011;95:1819–23.
- Pardolesi A, Park B, Petrella F, Borri A, Gasparri R, Veronesi G. Robotic anatomic segmentectomy of the lung: technical aspects and initial results. *Ann Thorac Surg* 2012;94:929–34.
- Dylewski MR, Ohaeto AC, Pereira JF. Pulmonary resection using a total endoscopic robotic video-assisted approach. *Semin Thorac Cardiovasc Surg* 2011;23:36–42.
- Toker A. Robotic thoracic surgery: from the perspectives of European chest surgeons. *J Thorac Dis* 2014;6:S211–6.
- Nasir BS, Bryant AS, Minnich DJ, Wei B, Cerfolio RJ. Performing robotic lobectomy and segmentectomy: cost, profitability, and outcomes. *Ann Thorac Surg* 2014;98:203–9.
- Pardolesi A, Veronesi G. Robot-assisted lung anatomic segmentectomy: technical aspects. *Thorac Surg Clin* 2014;24:163–8.
- Toker A, Ayalp K, Uyumaz E, Kaba E, Demirhan O, Erus S. Robotic lung segmentectomy for malignant and benign lesions. *J Thorac Dis* 2014;6:937–42.
- Yang CF, D'Amico TA. Open, thoracoscopic and robotic segmentectomy for lung cancer. *Ann Cardiothorac Surg* 2014;3:142–52.
- Yang CF, D'Amico TA. Thoracoscopic segmentectomy for lung cancer. *Ann Thorac Surg* 2012;94:668–81.
- El-Sherif A, Gooding WE, Santos R, Pettiford B, Ferson PF, Fernando HC *et al.* Outcomes of sublobar resection versus lobectomy for stage I non-small cell lung cancer: a 13-year analysis. *Ann Thorac Surg* 2006;82:408–156.
- Zhao X, Qian L, Luo Q, Huang J. Segmentectomy as a safe and equally effective surgical option under complete video-assisted thoracic surgery for patients of stage I non-small cell lung cancer. *J Cardiothorac Surg* 2013;8:116.
- Nicastro DG, Wisnivesky JP, Litle VR, Yun J, Chin C, Dembitzer FR *et al.* Thoracoscopic lobectomy: report on safety, discharge independence, pain, and chemotherapy tolerance. *J Thorac Cardiovasc Surg* 2008;135:642–7.
- Nagahiro I, Andou A, Aoe M, Sano Y, Date H, Shimizu N. Pulmonary function, postoperative pain, and serum cytokine level after lobectomy: a comparison of VATS and conventional procedure. *Ann Thorac Surg* 2001;72:362–5.
- Leshnowar BG, Miller DL, Fernandez FG, Pickens A, Force SD. Video-assisted thoracoscopic surgery segmentectomy: a safe and effective procedure. *Ann Thorac Surg* 2010;89:1571–6.
- Yamashita S, Tokushi K, Anami K, Moroga T, Miyawaki M, Chujo M *et al.* Thoracoscopic segmentectomy for T1 classification of non-small cell lung cancer: a single center experience. *Eur J Cardiothorac Surg* 2012;42:83–8.
- Zhong C, Fang W, Mao T, Yao F, Chen W, Hu D. Comparison of thoracoscopic segmentectomy and thoracoscopic lobectomy for small-sized stage IA lung cancer. *Ann Thorac Surg* 2012;94:362–7.
- Gonzalez-Rivas D, Fieira E, Mendez L, Garcia J. Single-port video-assisted thoracoscopic anatomic segmentectomy and right upper lobectomy. *Eur J Cardiothorac Surg* 2012;42:169–71.
- Ramos R, Girard P, Masuet C, Validire P, Gossot D. Mediastinal lymph node dissection in early-stage non-small cell lung cancer: totally thoracoscopic vs thoracotomy. *Eur J Cardiothorac Surg* 2012;41:1342–8.
- Swanson SJ, Miller DL, McKenna RJ Jr, Howington J, Marshall MB, Yoo AC *et al.* Comparing robot-assisted thoracic surgical lobectomy with conventional video-assisted thoracic surgical lobectomy and wedge resection: results from a multihospital database (Premier). *J Thorac Cardiovasc Surg* 2014;147:929–37.
- Ikedo N, Yoshimura A, Hagiwara M, Akata S, Saji H. Three dimensional computed tomography lung modeling is useful in simulation and navigation of lung cancer surgery. *Ann Thorac Cardiovasc Surg* 2013;19:1–5.
- Wilson JL, Louie BE, Cerfolio RJ, Park BJ, Vallières E, Aye RW *et al.* The prevalence of nodal upstaging during robotic lung resection in early stage non-small cell lung cancer. *Ann Thorac Surg* 2014;97:1901–7.
- Kanzaki M, Kikkawa T, Shimizu T, Maeda H, Wachi N, Isaka T *et al.* Presurgical planning using a three-dimensional pulmonary model of the actual anatomy of patient with primary lung cancer. *Thorac Cardiovasc Surg* 2013;61:144–50.