

THE MENISCO-FEMORAL LIGAMENTS OF THE HUMAN KNEE *

LEON HELLER and JAN LANGMAN, MONTREAL, CANADA

*From the Department of Orthopaedic Surgery, Jewish General Hospital
and the Department of Anatomy, McGill University, Montreal*

The menisco-femoral ligament is one of the most important accessory ligaments of the knee. It extends from the posterior horn of the lateral meniscus to the lateral aspect of the medial femoral condyle close to the femoral attachment of the posterior cruciate ligament. The accessory ligament may run behind or in front of the posterior cruciate ligament and is known either as the posterior menisco-femoral ligament of Wrisberg or the anterior menisco-femoral ligament of Humphrey. Both ligaments may be present in the same knee and are composed mainly of collagenous fibres (Candiollo and Gautero 1959). They vary in thickness from about five millimetres at the meniscal attachment to nine millimetres at the femoral attachment.

Poirier and Charpy (1892) were the first to describe the menisco-femoral ligament but defined it as the "third cruciate ligament." Hadjissélimovitch (1955) classified the accessory ligaments in a different manner, describing the anterior menisco-femoral ligament as arising from the anterior horn of the lateral meniscus. Kaplan (1956) wrote of a lateral menisco-femoral ligament having an anterior and posterior part.

Despite the lack of consistency in the terminology of the accessory ligaments it has become evident from a number of well verified reports that the incidence of the ligaments is quite high. When Radoïévitch (1931) examined 105 knees the menisco-femoral ligament was present in 94 per cent. Brantigan and Voshell (1941), studying fifty knees from thigh amputations and in cadavers, found the incidence to be 100 per cent. In a study of fifty knees by Candiollo and Gautero (1959), the anterior and posterior menisco-femoral ligaments were found to be present in 80 per cent of the specimens.

This report deals with the anatomical and functional significance of the menisco-femoral ligaments, their incidence and surgical importance.

MATERIALS AND METHODS

One hundred and forty knees from seventy cadavers were examined. After removal of the skin and the extensor musculature, the medial and lateral collateral ligaments were cut transversely. The tendon of the popliteus muscle was then freed from its femoral attachment and the knee was flexed, exposing the anterior and middle thirds of the menisci and the anterior cruciate ligament. This allowed examination of any accessory ligaments in the anterior compartment of the knee. The anterior cruciate ligament was then cut, exposing the anterior surface of the posterior cruciate ligament and the anterior menisco-femoral ligaments when present. With the knee completely flexed the tibia was then rotated medially which revealed the posterior horn of the lateral meniscus and the posterior menisco-femoral ligament when present.

RESULTS

Incidence of the menisco-femoral ligaments—Of the 140 knees examined, a menisco-femoral ligament was present in ninety-nine (71 per cent). In fifty cases (36 per cent) the ligament was an anterior one, and in the remaining forty-nine cases (35 per cent) it was identified as the posterior menisco-femoral ligament. Only eight knees (6 per cent) showed both an anterior

* Presented at the Canadian Orthopaedic Association meeting, June 1962.

and posterior menisco-femoral ligament. The anterior menisco-femoral ligament was found in both knees in seventeen cases (12 per cent), and the posterior one in twelve cases (8 per cent). In only two cadavers were both ligaments found in both knees. There was no difference in the incidence of the menisco-femoral ligaments between male and female bodies.

The anterior menisco-femoral ligament—This ligament formed a continuation of the posterior horn of the lateral meniscus and was always closely related to the anterior surface of the

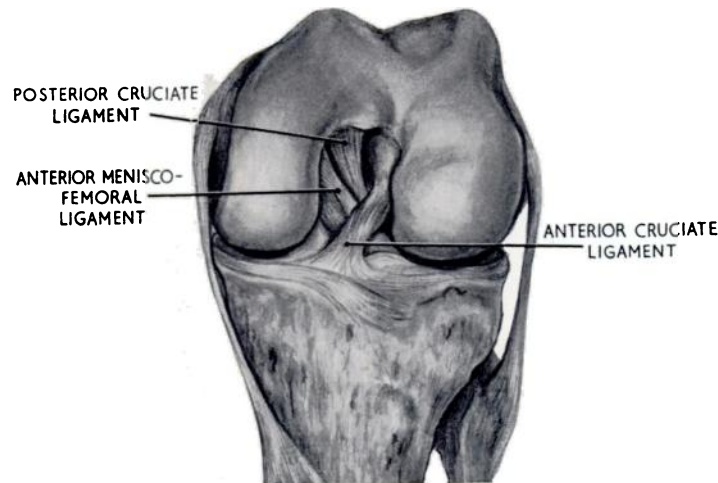


FIG. 1

Anterior view of the flexed left knee showing the anterior menisco-femoral ligament.

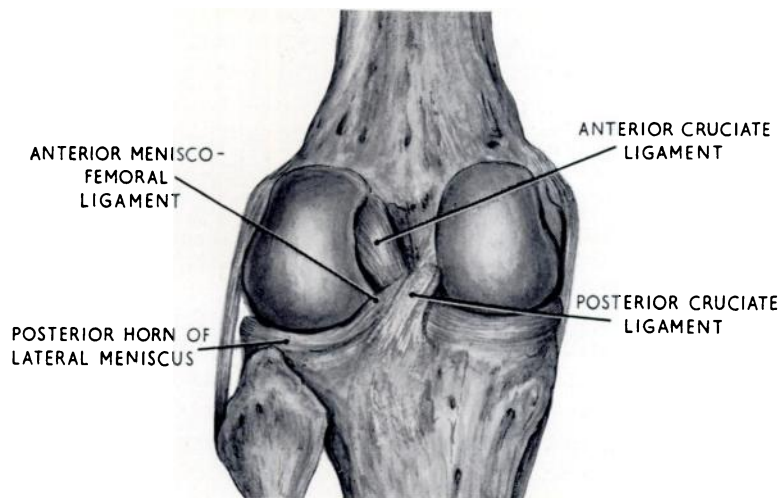


FIG. 2

Posterior view of the extended left knee showing the relation of the anterior menisco-femoral ligament to the posterior horn of the lateral meniscus and the posterior cruciate ligament.

posterior cruciate ligament (Fig. 1). It was never larger than one-third of the diameter of the adjacent cruciate ligament and a probe could usually separate the two except at the femoral attachment. The attachment of the anterior menisco-femoral ligament to the lateral meniscus could not be seen from in front. When the tibia was medially rotated on the femur the posterior horn of the lateral meniscus came into view, and the origin of the anterior menisco-femoral ligament could be seen posteriorly (Fig. 2).

The posterior menisco-femoral ligament—This ligament was a distinct structure continuous with the posterior horn of the lateral meniscus (Fig. 3). As fatty tissue is abundant in this area, it was necessary to trace any band of fibrous tissue to make sure that the ligament was in fact the posterior menisco-femoral one. Many bands were seen to arise from the tibia and not from the meniscus. In some specimens the posterior menisco-femoral ligament was half the diameter of the posterior cruciate ligament, to which it was always closely related. Once a

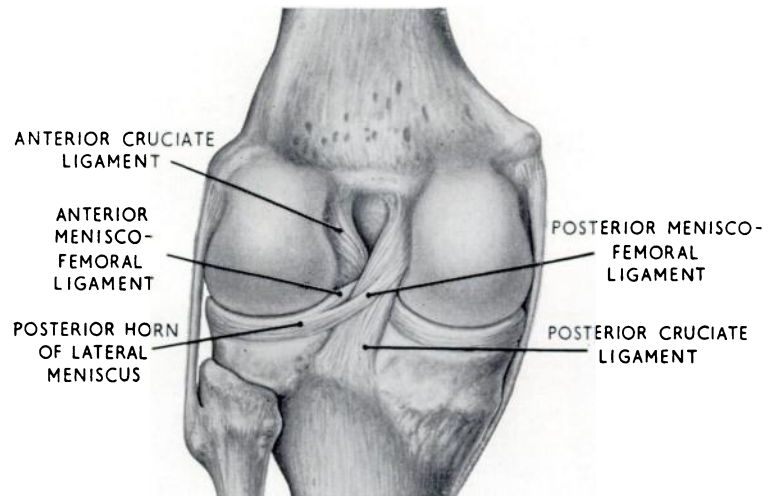


FIG. 3

Posterior view of the extended left knee showing both the anterior menisco-femoral and the posterior menisco-femoral ligament.

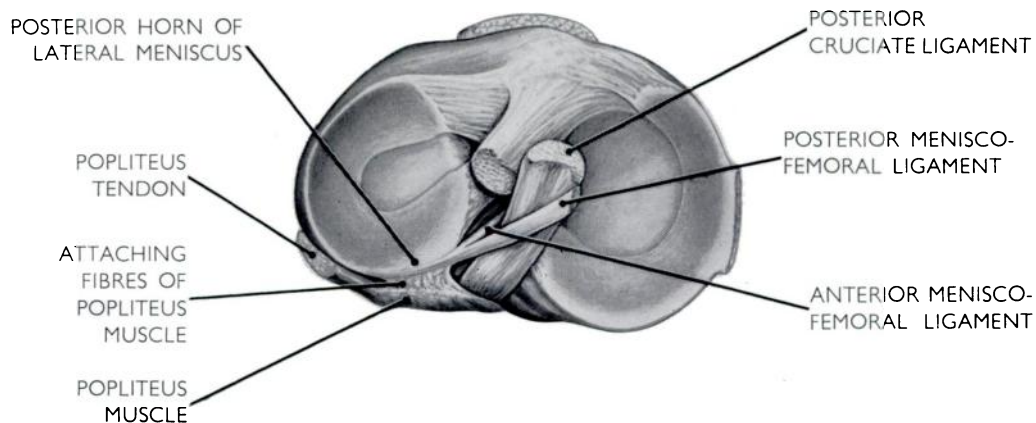


FIG. 4

The anterior and posterior menisco-femoral ligaments seen from above. The anterior portion of the posterior horn of the lateral meniscus is attached to the tibial eminence but only a small posterior portion is continued to be inserted into the femur.

probe was inserted between the two with the knee extended, tension on the posterior menisco-femoral ligament tended to displace the posterior horn of the lateral meniscus posteriorly.

The lateral meniscus—The anterior horn of the lateral meniscus was always inserted into the tibial intercondylar eminence whereas the posterior portion, in the majority of cases (70 per cent), was inserted into the femur by means of the menisco-femoral ligament. This ligament could not be cut by a Smillie knife used from the front. It was also noted that in all the cases

fibres of the popliteus muscle, reinforced by fibres of the capsule, were inserted into the posterior horn of the meniscus (Fig. 4). The connection between the meniscus and these fibres was so firm that it was possible to separate the two only by sharp dissection (Figs. 5 and 6).

Other accessory ligaments—Occasionally another accessory ligament was found. This ligament formed a continuation from the anterior horn of either the medial or lateral meniscus towards the medial or lateral femoral condyle. In one case it was found attached to both menisci (Fig. 7).

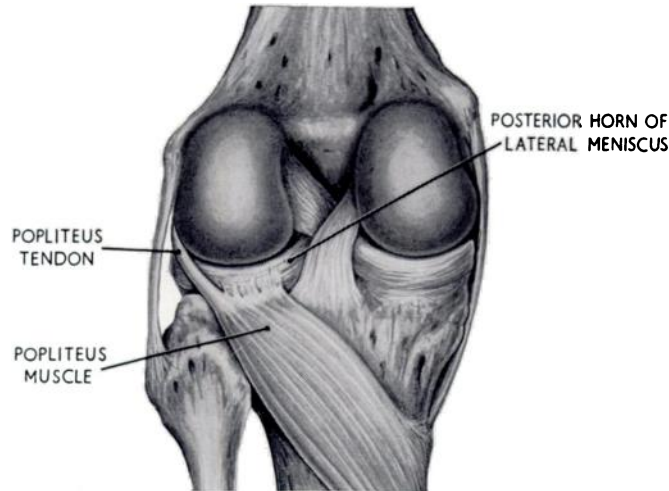


FIG. 5

Posterior view of the left knee showing the medial fibres of the popliteus muscle attached to the posterior horn of the lateral meniscus.

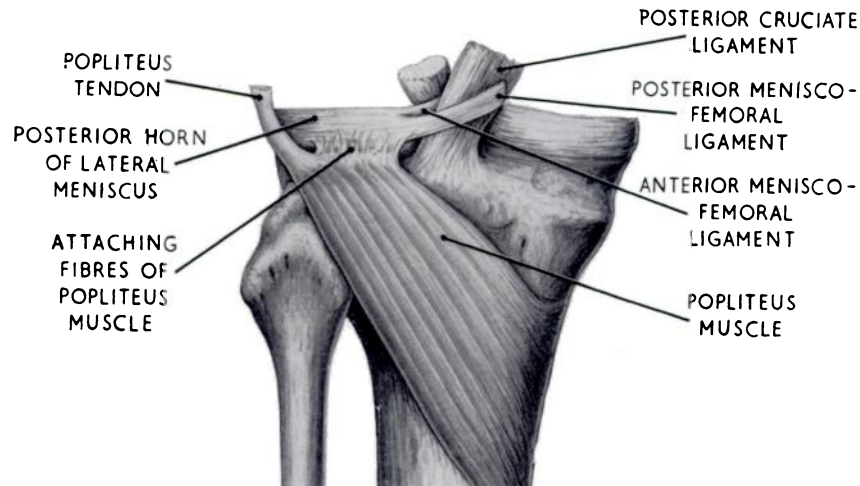


FIG. 6

Posterior view of the left knee after removal of the femur, showing the medial fibres of the popliteus muscle inserted into the lateral meniscus. The anterior and posterior menisco-femoral ligaments are also shown.

DISCUSSION

In most animals the posterior horn of the lateral meniscus does not have an attachment to the tibial intercondylar eminence but continues as a fibrous band along the posterior cruciate ligament and is inserted on the medial condyle of the femur in the intercondylar fossa. This particular form of attachment is thought to be of importance in sudden rotary

movements in the knee joint. In animals such as the fruitbat, in which rotation in the knee joint is impossible, the menisci, the menisco-femoral ligaments and the popliteus muscle are absent (Parsons 1900).

In the human the posterior horn of the lateral meniscus usually has a double attachment. The anterior portion is attached to the tibial intercondylar eminence while, in the majority of cases, the posterior portion is inserted into the femur via the menisco-femoral ligaments. In a standing position with the knees flexed and the feet fixed, as in ski-ing, hockey and other similar sports (that is, the weight-bearing position of the flexed knee) the femoral condyles tend to slide forwards over the tibial plateau under the influence of the body weight. As both the medial and lateral collateral ligaments are relaxed only the posterior cruciate ligament will prevent the forward sliding of the femur. For the same reason the anterior menisco-femoral ligament and, to a lesser extent, the posterior menisco-femoral ligament will become tight and pull the posterior horn of the lateral meniscus slightly medially and anteriorly.

Although, during flexion in the non-weight-bearing knee, the medial and lateral menisci move backward under the influence of muscular action and the rolling of the femoral condyles

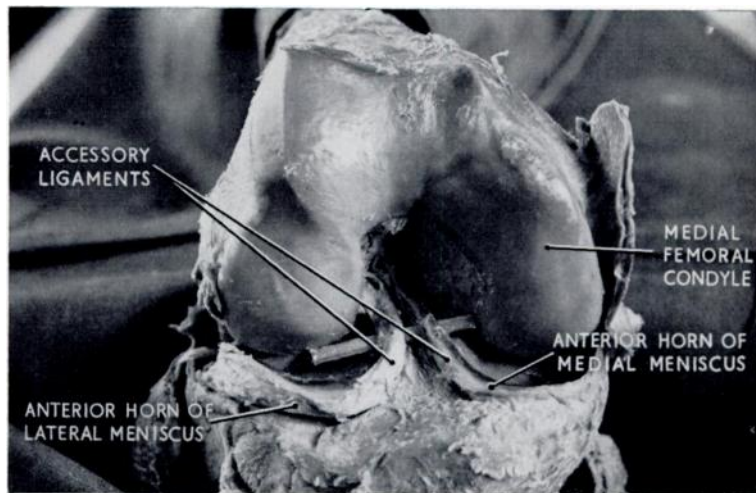


FIG. 7

Anterior view of the left knee showing the anterior accessory ligament of both menisci with a probe beneath them.

(Kaplan 1962), it is thought that in the weight-bearing flexed knee the pull of the menisco-femoral ligaments may slightly displace the lateral meniscus in an anterior direction. This movement will enhance the congruity of the menisco-tibial socket and the lateral femoral condyle. The forward movement of the medial meniscus is largely brought about by the pressure of the medial femoral condyle but it may also result from the forward pull of the deeper portion of the medial collateral ligament which, with the forward sliding of the femur, would tend to displace the medial meniscus slightly anteriorly. During extension of the knee from this position the menisco-femoral ligaments become relaxed, allowing the posterior horn of the lateral meniscus to move laterally and slightly posteriorly, in this way accommodating the broader surface of the femoral condyle in the tibio-meniscal socket.

During medial rotation of the femur with the knee flexed and the tibia fixed, the menisco-femoral ligaments become lax. During lateral rotation of the femur the origin and the insertion of the menisco-femoral ligaments move away from each other and the posterior horn of the lateral meniscus will be drawn medially and slightly anteriorly. As the slight anterior movement would increase the risk of the posterior horn being crushed by the posteriorly moving lateral

condyle an additional structure must be needed to prevent it. This structure is most likely to be the popliteus muscle. Half of the popliteus muscle is attached to the posterior arch of the lateral meniscus and the muscle fibres of this part are distinct from those which are inserted into the femur (Last 1950).

Electromyographic studies of the popliteus muscle showed some activity at the start of flexion but this activity invariably died out after a few degrees of movement (Barnett and Richardson 1953). No muscle activity was found during the middle range of flexion, even against resistance. The greatest electrical activity was recorded when the knee was flexed to a right angle. In our opinion it is likely that the first recorded activity of the popliteus muscle is caused by the action of its tibio-femoral portion which unlocks the knee and possibly accounts for the first few degrees of flexion. At the beginning of flexion, from the so-called "locked" position, it is the only muscle that has a rotation effect on the joint. As the tendon passes almost through the transverse axis of the joint its flexion action is restricted. As soon as flexion has been started the semimembranosus, semitendinosus and biceps femoris muscles take over and flex the knee completely. The second burst of muscular activity is most likely caused by contraction of the tibio-meniscal portion of the popliteus. When the lateral femoral condyle begins to impinge upon the posterior horn of the lateral meniscus during flexion, and particularly during lateral rotation of the femur with the knee flexed, the meniscal fibres of the popliteus pull the posterior horn backwards. This movement is facilitated by the rounded contour of the posterior margin of the lateral tibial plateau. Therefore, during lateral rotation of the femur with the knee flexed, the menisco-femoral ligaments pull the posterior horn of the lateral meniscus medially and slightly anteriorly, but the tibio-meniscal portion of the popliteus muscle pulls it posteriorly away from the lateral femoral condyle.

It appears that the mobility of the posterior horn of the lateral meniscus is controlled by the menisco-femoral ligaments as well as the popliteus muscle (Last 1948, 1954). This control is particularly important during rotatory movements when the knee is flexed and bearing weight. The medial meniscus, however, slides over the tibial plateau under the influence of the pressure of the medial femoral condyle and presumably to a small extent under the influence of the pull of the deeper portion of the tibial collateral ligament. It lacks, however, the "controlled" mobility of the lateral meniscus exerted by the menisco-femoral ligaments and the popliteus muscle. This lack of controlled mobility is thought to be the reason why the medial meniscus is injured more often than the lateral.

From this study, 71 per cent of knee joints that need lateral meniscectomy will have either an anterior or posterior menisco-femoral ligament connecting the posterior horn of the lateral meniscus with the femur. The firm attachment of these ligaments to the meniscus and their intimate relationship to the posterior cruciate ligament increases the likelihood of damage to the posterior cruciate when removing the posterior horn. In the approach to the posterior horn Bruser (1960) has described a transverse incision for lateral meniscectomy. Although this allows easy inspection of the posterior horn at its junction with the middle third, it does not reveal the medial segment of the meniscus where the anterior and posterior menisco-femoral ligaments arise. After medial rotation of the tibia, however, it is usually possible to separate the posterior margin of the lateral meniscus from the conjoint tendon, formed by the capsule and the popliteal fibres, and then to cut the menisco-femoral ligament. The meniscus may then be cut off, leaving only the most medial portion of the posterior horn attached to the tibial intercondylar eminence, which may then be removed under direct vision. If the posterior horn of the lateral meniscus is not separated from the menisco-femoral ligaments, the popliteal fibres and the capsule, damage could easily occur to structures in the posterior compartment of the knee. Therefore, when removing the lateral cartilage through an anterior incision, it must be remembered that in 71 per cent of cases an anterior or posterior menisco-femoral ligament may be holding the posterior horn. In such circumstances an additional incision should be used.

SUMMARY

1. The menisco-femoral ligaments, extending from the posterior horn of the lateral meniscus to the lateral aspect of the medial femoral condyle, were found in ninety-nine (71 per cent) of the 140 knees examined. Fifty per cent of the ligaments were identified as the anterior menisco-femoral ligament while the remaining 50 per cent were of the posterior type.
2. During flexion of the knee with the foot fixed the menisco-femoral ligaments pull the posterior horn medially and slightly anteriorly, increasing the congruity between the menisco-tibial socket and the lateral femoral condyle.
3. During lateral rotation of the femur with the knee flexed the menisco-femoral ligament pulls the posterior horn medially and slightly anteriorly, in this way increasing the risk of the posterior horn being crushed by the lateral femoral condyle. It is suggested that this is prevented by the contraction of the tibio-meniscal portion of the popliteus muscle which pulls the posterior horn of the lateral meniscus posteriorly.
4. When removing the lateral meniscus it may be advisable to make another incision in order to free the posterior horn from its attachment to the popliteus muscle and then to cut the menisco-femoral ligaments under direct vision.

This work was supported by a grant from the Medical Research Council of Canada. The authors also wish to express their sincere thanks for the illustrations prepared by Miss W. van Slooten, Department of Anatomy, Amsterdam, and Miss Jill Leland, Department of Anatomy, McGill University, Montreal, Canada.

REFERENCES

- BARNETT, C. H., and RICHARDSON, A. T. (1953): The Postural Function of the Popliteus Muscle. *Annals of Physical Medicine (London)*, **1**, 177.
- BRANTIGAN, O. C., and VOSHELL, A. F. (1941): The Mechanics of the Ligaments and Menisci of the Knee Joint. *Journal of Bone and Joint Surgery*, **23**, 44.
- BRUSER, D. M. (1960): A Direct Lateral Approach to the Lateral Compartment of the Knee Joint. *Journal of Bone and Joint Surgery*, **42-B**, 348.
- CANDIOLLO, L., and GAUTERO, G. (1959): Morphologie et fonction des ligaments menisco-femoraux de l'articulation du genou chez l'homme. *Acta Anatomica*, **38**, 304.
- HADJISSÉLIMOVITCH, H. (1955): Contribution à l'étude des liaisons du ménisque externe de l'articulation du genou. *Comptes Rendus de l'Association des Anatomistes*, **42**, 699.
- KAPLAN, E. B. (1956): The Lateral Menisco-Femoral Ligament of the Knee Joint. *Bulletin of the Hospital for Joint Diseases*, **17**, 176.
- KAPLAN, E. B. (1962): Some Aspects of Functional Anatomy of the Human Knee Joint. *Clinical Orthopaedics*, **23**, 18.
- LAST, R. J. (1948): Some Anatomical Details of the Knee Joint. *Journal of Bone and Joint Surgery*, **30-B**, 683.
- LAST, R. J. (1950): The Popliteus Muscle and the Lateral Meniscus. *Journal of Bone and Joint Surgery*, **32-B**, 93.
- LAST, R. J. (1954): *Anatomy, Regional and Applied*. London: J. and A. Churchill Limited.
- PARSONS, F. G. (1900): The Joints of Mammals Compared with Those of Man. *Journal of Anatomy and Physiology*, **34**, 301.
- POIRIER, P., and CHARPY, A. (1892-1904): *Traité d'Anatomie Humaine*. Paris: Masson et Cie.
- RADOÏÉVITCH, S. (1931): Les ligaments des ménisques interarticulaires du genou. *Annales d'Anatomie Pathologique*, **8**, 400.