

## Case Report

# Fixed Drug Eruption Caused by Carbamazepine in a Patient with Lafora Body Disease

Sghaier Naima<sup>1\*</sup>, Machraoui Rafik<sup>1</sup>, Haj Kacem Hanene, Bel-Hadj Ali Hichem<sup>2</sup>, Chadly Zohra<sup>3</sup>, Aissi Mouna<sup>4</sup>, Frih Mahbouba<sup>4</sup>, Younes Samia<sup>1</sup>, and Hbib Sfar Mohamed<sup>1</sup>

<sup>1</sup>Department of Internal Medicine and Endocrinology, University of Monastir, Tunisia

<sup>2</sup>Department of Dermatology, University of Monastir, Tunisia

<sup>3</sup>Department of Pharmacology, University of Monastir, Tunisia

<sup>4</sup>Department of Neurology, Fattouma Bourguiba University Hospital, University of Monastir, Tunisia

**\*Corresponding author**

Sghaier Naima, Department of Internal Medicine and Endocrinology, Taher Sfar University Hospital, University of Monastir, Mahdia 5111. Tunisia, Tel: 641-681-042; Email: naimasghaier@yahoo.fr

Submitted: 20 December 2016

Accepted: 16 January 2017

Published: 20 January 2017

ISSN: 2333-7079

**Copyright**

© 2017 Naima et al.

**OPEN ACCESS****Keywords**

- Carbamazepine
- Fixed drug eruptions
- Lafora body disease
- Epilepsy

**Abstract**

Carbamazepine (CBZ) is a drug widely used especially in epilepsy and trigeminal neuralgia. It has been associated with several skin eruptions. Carbamazepine is not well discussed in the reviews of fixed drug eruptions (FDE), and we have found very few cases of CBZ-induced FDE. The drugs such as analgesics and some antibiotics are commonly implicated in FDE. However, CBZ causes a FDE by distinct immunological mechanisms and different clinical features. Here we present a case report of a FDE caused by CBZ in a patient with Lafora disease, a rare autosomal recessive disease. The case is reported for its rarity of occurrence and also emphasizes the need for pharmacogenetic and haplotype testing before drug administration, so that individualization of therapy will become the gold standard of treatment in the future.

**ABBREVIATIONS**

CBZ: Carbamazepine; FDE: Fixed Drug Eruptions; NSAIDs: Steroidal Anti-inflammatory Drugs; SJS: Steven Johnson's Syndrome; TEN: Toxic Epidermal Necrolysis.

**INTRODUCTION**

Fixed drug eruption present as pruritic, well-circumscribed and erythematous macules that arise after exposure to specific medication. Lesions recur at the same site with each administration of the causative drug and evolve into hyperpigmented plaques [1]. Typically, patients have multiple recurrences over an extended duration before diagnosis. The immunological pattern is a delayed hypersensitivity reaction which is associated with multiple agents like antibiotics and non steroidal anti-inflammatory drugs (NSAIDs) [1,2]. Carbamazepine is an iminostilbene derivative with potent anti seizure activity. It was commonly involved in the occurrence of Steven Johnson's Syndrome (SJS)/ toxic epidermal necrolysis (TEN) [3,4]. We have found only few cases of CBZ-induced FDE in a review of the literature [5-8]. Here we present a case of a FDE caused by CBZ in a patient with Lafora body disease which is a fatal and rare autosomal recessive genetic disorder [9].

Through this case we aim to analyse clinical features of

FDE caused by CBZ and to identify the appropriate methods for the causality assessment. Moreover, we emphasize further understanding of its pathogenesis in order to prevent and treat the condition more efficiently.

**CASE PRESENTATION**

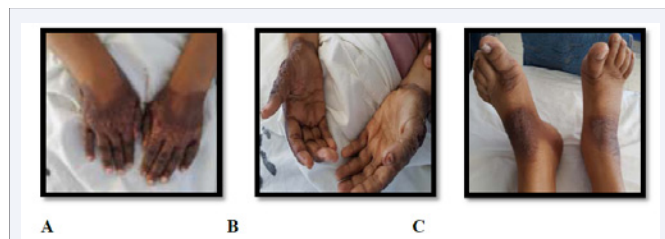
We report the case of a 24-year-old woman, who is diagnosed with Lafora disease since the age of 20. She had also a sister who had the same disease and who died at the age of 40. The clinical features consist of progressive myoclonic epilepsy, visual hallucinations and cerebellar ataxia. The diagnosis was confirmed by the demonstration of a glycoprotein overload in the form of Lafora body. The patient was treated by Sodium Valproate, levomepromazine, lorazepam and CBZ since 4 years. She had a two weeks history of hyperpigmented lesions over her two hands and feet (Figure 1) and mild erosive lesions on the lower lip mucosa (Figure 2). She complained of itching and a burning sensation on the lesions. Her general condition was good. Cutaneous examination showed demarcated, symmetric, hyperpigmented plaques on her Palma and dorsa of two hands and dorsa of feet. The blood cell count was normal. Blood level of CBZ was 7.3 microg x mL (-1), which was within the therapeutic range [4-12] microg x mL (-1). A biopsy specimen showed an epidermis with slight hyperkeratosis without parakeratosis, focal

spongiosis, and some basal necrotic keratinocytes, along with minor interstitial mixed infiltrate with erythrocyte extravasation. Due to the fact that CBZ was incriminated in many skin lesions, it was withdrawn thereafter and she was treated with emollients. The lesions improved in 2 weeks, leaving faded plaques (Figure 3).

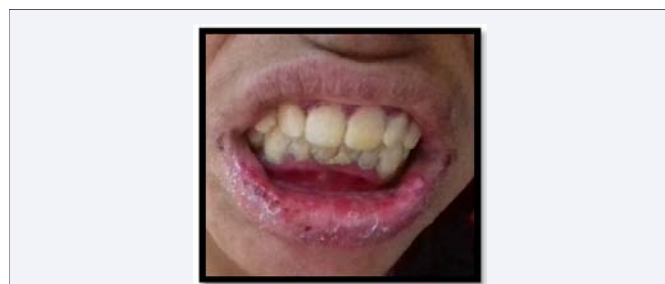The causality assessment was done using WHO and Naranjo scoring system (Table 1) [7-10], and was found to have a possible association between the administration of the drug and the adverse drug reaction. For the other drugs, their responsibility is discarded in front of the clear regression of the cutaneous lesions despite their continuation.

## DISCUSSION

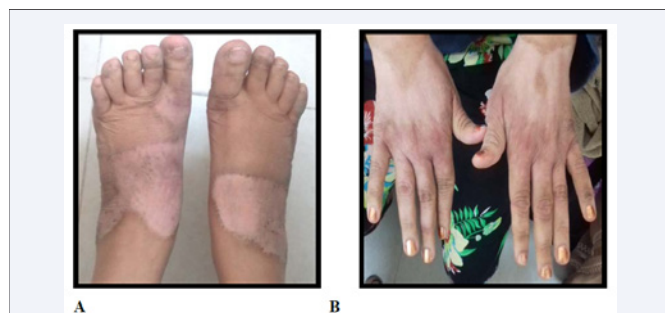Lafora disease is a fatal and rare autosomal recessive genetic disorder. Clinically it is characterised by generalised tonic-clonic seizures, myoclonias, progressive mental decline, and pyramidal, extrapyramidal and cerebellar signs. Generally, it starts at the end of childhood or during adolescence (6 to 20 years). The disease is



**Figure 1** Fixed drug eruption due to Carbamazepine: (A) hyperpigmentation over dorsal and (B) palmar faces of two hands and (C) dorsal faces of feet.



**Figure 2** Oral mucosal fixed drug eruption with mild erosive lesions on the lower lip mucosa.



**Figure 3** Faded plaques after two weeks of stopping carbamazepine.

**Table 1:** Assessment of the adverse drug reaction using Naranjo Adverse Drug Reaction Probability Scale.

| Questions  | Yes | No | Do not know  | Score    |
|--|-----|----|--------------|----------|
| 1. Are there previous <i>conclusive</i> reports on this reaction?  | +1  | 0  | 0            | +1       |
| 2. Did the adverse event occur after the suspected drug was administered?  | +2  | -1 | 0            | +2       |
| 3. Did the adverse reaction improve when the drug was discontinued or a <i>specific</i> antagonist was administered? | +1  | 0  | 0            | +1       |
| 4. Did the adverse reaction reappear when the drug was readministered?   | +2  | -1 | 0            | 0        |
| 6. Did the reaction reappear when a placebo was given?   | -1  | +1 | 0            | 0        |
| 7. Was the blood detected in the blood (or other fluids) in concentrations known to be toxic?                        | +1  | 0  | 0            | 0        |
| 8. Was the reaction more severe when the dose was increased or less severe when the dose was decreased?              | +1  | 0  | 0            | 0        |
| 9. Did the patient have a similar reaction to the same or similar drugs in <i>any</i> previous exposure?             | +1  | 0  | 0            | 0        |
| 10. Was the adverse event confirmed by any objective evidence?   | +1  | 0  | 0            | 0        |
|  |     |    | <b>Total</b> | <b>3</b> |
| Scoring  |     |    |              |          |
| ≥ 9 = definite ADR      1-4 = possible ADR   |     |    |              |          |
| 5-8 = probable ADR      0 = doubtful ADR   |     |    |              |          |

associated with poor evolution, with multiple generalised tonic-clonic, myoclonic, and partial seizures accompanied by visual symptoms that persist in spite of treatment with several drug combinations. Diagnosis relies upon the discovery of specific inclusion bodies in some organs [8]. We present a case of Lafora disease diagnosed by axillary skin biopsy.

Fixed drug eruption is characterized by recurrent site-specific lesions on the skin and/or mucosa each time the responsible drug is taken. Oral mucosal lesions often accompany the characteristic skin lesions. These reactions normally resolve with hyperpigmentation and may recur at the same site when retaking the drug. Repeated exposure to responsible drug may cause new lesions to develop in addition to “lighting up” the older hyperpigmented lesions. Several variants of FDE have been described, based on their clinical features and the distribution of the lesions [7]. Our case corresponds to the Pigmenting FDE which is a frequent variant [7]. Fixed drug eruption usually develops at 0.5 to 8 hours after administration of a causative drug, with a mean onset time of 2 hours [1]. To our knowledge most of cases which reported the association of carbamazepine use and FDE in the literature develops at few hours after administration of CBZ [5-7]. A case reported in 2006 developed this side effect after six months of treatment of CBZ [8]. In our patient, the FDE appeared 4 years after the beginning of CBZ treatment. In fact, the period required for sensitization is variable depending on patients. It ranges from few weeks to several years.

Common drugs implicated in the occurrence of fixed drug

eruption include antibiotics and NSAIDs [1,2]. Carbamazepine was commonly involved in the appearance of skin lesions such as SJS/TEN [3]. However, few publications in the literature report that carbamazepine is a cause for FDE [5-8]. In fact, rash is the most frequent cutaneous manifestation of carbamazepine toxicity [11]. Carbamazepine was also involved in the genesis of drug induced Systemic Lupus Erythematosus [12]. Haplotype like HLA-B1502 seems to be associated with carbamazepine induced SJS/TEN. Therefore Screening for HLA-B 1502 before using CBZ can prevent SJS/TEN in certain populations [13]. A protective effect of HLA-B/0702 against CBZ-induced severe cutaneous reactions was found in a study with Caucasian patients [14]. To our knowledge no specific HLA genotypes have been associated with carbamazepine use and FDE in the literature.

The pathogenesis of carbamazepine induced FDE is poorly understood and the exact mechanism is still unclear [7-13]. Further elucidation of Carbamazepine induced FDE's underlying pathogenesis will help us treat the condition more efficiently and prevent mortality and morbidity.

Currently, the tests available for investigating the pathogenesis of the FDE don't have a great scientific value. Often, per oral provocation is the only reliable diagnostic method. Sometimes, as in our patient, the provocation accidentally occurs. The causality assessment was done using WHO and Naranjo scoring system (Table 1) [7-10] and was found to have a possible association between the administration of the drug and the adverse drug reaction. For the other drugs, their responsibility is discarded in front of the clear regression of the cutaneous lesions despite their continuation. Moreover sodium valproate, levomepromazine and lorazepam are relatively free from skin allergy [15].

Epicutaneous testing with CBZ is a diagnostic method that leads to a wide range of positivities [16]. Patch test reactions with this drug are seen especially in patients with exfoliative dermatitis and maculopapular exanthema [5]. For the time being, the appropriate method has not been yet elucidated.

Carbamazepine induced FDE is a rare cutaneous complication and is particular for its extensive involvement. Our case is one of the rare cases of FDE caused by carbamazepine worldwide. We would like to alert that the use of Carbamazepine should be supervised. A better understanding of its pathogenesis and genetics will enable us to better take care of the patients.

## REFERENCES

1. Jung JW, Cho SH, Kim KH, Min KU, Kang HR. Clinical Features of Fixed Drug Eruption at a Tertiary Hospital in Korea. *AAIR*. 2014; 6: 415-420.
2. Shukla SR. Drugs causing fixed drug eruptions. *Dermatologica*. 1981; 163: 160-163.
3. Devi K, George S, Criton S, Suja V, Sridevi PK. Carbamazepine - The commonest cause of toxic epidermal necrolysis and Stevens - Johnson syndrome: A study of 7 years. *Indian J Dermatol Venereol Leprol*. 2005; 71: 325-328.
4. Ding WY, Lee CK, Choon SE. Cutaneous adverse drug reactions seen in a tertiary hospital in Johor, Malaysia. *Int J Dermatol*. 2010; 49: 834-841.
5. Alanko K. Patch testing in cutaneous reactions caused by carbamazepine. *Contact Dermatitis*. 1993; 29: 254-257.
6. De Angola D, Angeles Gonzala M, Rovina I. Carbamazepine induced fixed drug eruption. *Allergy*. 1997; 52: 1039.
7. Nivethitha T. Fixed Drug Eruption with Exacerbation of Bullous Pemphigoid due to Carbamazepine: A Case Report. *IJTPR*. 2014; 6: 57-59.
8. Alvarez VJ, Picón JE, Morales AR, Goncalves ET, Luna JR. Fixed pigmented erythema related to the oral administration of carbamazepine: report of one case. *Invest Clin*. 2006; 47: 65-69.
9. Acharya NJ, Satishchandra P, Asha T, Shankar SK. Lafora disease in south India: a clinical and electrophysiologic study. *Epilepsia*. 2012; 34: 476-487.
10. Naranjo C, Busto U, Sellers EM, Sandor P, Ruiz I, Roberts EA, et al. A method for estimating the probability of adverse drug reactions. *Clin Pharmacol Ther*. 1981; 30: 239-245.
11. Alvestad S, Lydersen S, Brodtkorb E. Rash from antiepileptic drugs: influence by gender, age, and learning disability. *Epilepsia*. 2007; 48: 1360-1365.
12. Drory VE, Korczyn AD. Hypersensitivity vasculitis and systemic lupus erythematosus induced by anticonvulsants. *Clin Neuropharmacol*. 1993; 16: 19-29.
13. Locharernkul C, Shotelersuk V, Hirankarn N. Pharmacogenetic screening of carbamazepine-induced severe cutaneous allergic reactions. *J Clin Neurosci*. 2011; 18: 1289-1294.
14. Alfirevic A, Jorgensen AL, Williamson PR, Chadwick DW, Park BK, Pirmohamed M. HLA-B locus in Caucasian patients with carbamazepine hypersensitivity. *Pharmacogenomics*. 2006; 7: 813-818.
15. Roy S, Goel D. Unusual cutaneous reaction with sodium valproate. *Neurol India*. 2009; 57: 216-217.
16. Jones M, Fernandez-Herrera J, Dorado JM, Sols M, Ruiz M, García-Díez A. Epicutaneous Test in Carbamazepine Cutaneous Reactions. *Dermatology*. 1994; 188: 18-20.

### Cite this article

Naima S, Rafik M, Hanene HK, Ali Hichem BH, Zohra C, et al. (2017) Fixed Drug Eruption Caused by Carbamazepine in a Patient with Lafora Body Disease. *J Pharmacol Clin Toxicol* 5(1):1064.