

Hepatocellular carcinoma treated with anti-epidermal growth factor receptor antibody nimotuzumab

A case report

Peng Song, MD^a, Jing Yang, MD^a, Xiaomei Li, MD^a, Haili Huang, MD^a, Xueguang Guo, MD^a, Gang Zhou, MD^a, Xian Xu, MD^b, Yi Cai, MD^a, Min Zhu, MD^a, Peng Wang, MD^a, Shu Zhao, MD^a, Dong Zhang, MD^{a,*}

Abstract

Rationale: Molecular targeted therapy provides new ideas and hope for the treatment of hepatocellular cancer. Epidermal growth factor receptor (EGFR) is closely related to tumor cell proliferation, apoptosis, invasion, and metastasis.

Patient concerns: Several reports indicate that the EGFR is expressed frequently in hepatocellular carcinoma (HCC), thus targeting EGFR research has become a hot topic to explore the treatment of HCC patient.

Diagnoses: Anti-EGFR might serve as a potential therapeutic agent, especially for patients with HCC who are unable to tolerate chemotherapy and surgery.

Interventions: Although phase II open-label study of cetuximab in unresectable HCC was negative, the clinical relevance of this report by Song et al which is based on a single patient is questionable.

Outcomes: We for the first time report that nimotuzumab (an anti-EGFR mAb) resulted in a complete remission (CR) in an 87-year-old patient with HCC. The patient was in B stage according to Barcelona center staging criteria and his liver function was Child-Pugh B grade.

Lessons: Our case suggested that anti-EGFR mAbs might be potential therapeutic options for HCC.

Abbreviations: AFP = alpha fetal protein, AUC = area under the curve, CR = complete remission, DCE = dynamic contrast enhancement, DWI = diffusion weighted imaging, EGFR = epidermal growth factor receptor, GEMOX = gemcitabine plus oxaliplatin, HCC = hepatocellular carcinoma, MRI = magnetic resonance imaging, T1WI = T1-weighted image, T2WI = T2-weighted image, TACE = transhepatic arterial chemotherapy and embolization.

Keywords: complete remission, epidermal growth factor receptor, hepatocellular carcinoma, nimotuzumab

Editor: Muhammed Mubarak.

PS and JY have contributed equally to the manuscript and should be considered co-first authors.

Ethical review: All procedures performed in this case report were approved by the institutional ethics committee: "Research Ethics Committee, The General Hospital of Chinese People's liberation Army" and were in accordance with the ethical standards of the 1964 Helsinki Declaration. The patient provided written informed consent to participate in this case report.

Consent for publication: The patient provided written informed consent for publication of this case report and any accompanying images.

Funding: This work was partially supported by grants from the Health Care Special Project (15BJZ43).

The authors have no conflicts of interest to disclose.

^a Department of Geriatric Oncology, ^b Department of Geriatric Radiology, The General Hospital of Chinese People's liberation Army, Beijing, China.

* Correspondence: Dong Zhang, Department of Geriatric Oncology, The General Hospital of Chinese People's liberation Army, 28 Fuxing Road, Haidian District, Beijing City, 100853, China (e-mail: zhangdongjfyzy@sina.com).

Copyright © 2017 the Author(s). Published by Wolters Kluwer Health, Inc. This is an open access article distributed under the terms of the Creative Commons Attribution-Non Commercial License 4.0 (CCBY-NC), where it is permissible to download, share, remix, transform, and buildup the work provided it is properly cited. The work cannot be used commercially without permission from the journal.

Medicine (2017) 96:39(e8122)

Received: 4 May 2017 / Received in final form: 20 August 2017 / Accepted: 1 September 2017

<http://dx.doi.org/10.1097/MD.00000000000008122>

1. Introduction

Standard treatment strategies for advanced hepatocellular carcinoma (HCC) remain unavailable. Although chemotherapeutic drugs and sorafenib have been shown to exhibit some effectiveness in prolonging median time to progression in patients with advanced HCC, the adverse event profile is not generally tolerated, especially among elderly patients. Thus, new treatment strategies with reduced toxicity and increased efficiency are urgently required. In recent years, molecular-targeted therapies have demonstrated promising anticancer activities in a variety of tumors, including HCC. Ito et al^[1] examined 4 key members of the epidermal growth factor receptor family and found that EGFR was expressed in 68% of the HCCs examined and correlated with proliferation, intrahepatic metastasis, and carcinoma differentiation. Unfortunately, in HCC patients, monotherapy using the monoclonal antibody cetuximab has provided disappointing results to date. However, due to the limited number of elderly patients participating in such clinical trials and the lack of hierarchical analysis, the data did not completely reflect the efficacy in elderly patients. Moreover, given the different sites of action of the anti-EGFR mAbs, which lead to different efficacies, anti-EGFR might serve as a potential therapeutic agent, especially for patients who are unable to tolerate chemotherapy and surgery. Nimotuzumab is a humanized anti-EGFR IgG1 mAb that is currently widely used in various tumors. In a preclinical study, nimotuzumab exhibited a longer half-life and a greater area under the curve (AUC) compared with other anti-EGFR antibodies. Nimotuzumab enhances the antitumor efficacy of radiation in non-small cell lung cancer cell lines.^[2] Men et al^[3] reported a combination of

nimotuzumab with chemotherapy that resulted in a partial response in a penile squamous cell carcinoma patient. Given that the exact function of nimotuzumab in HCC is unknown, here, we report, for the first time, a case of an aged patient with hepatocellular carcinoma who was treated with nimotuzumab alone.

2. Case report

On 21 April 2014, an 85-year-old man was diagnosed with HCC by liver dynamic contrast-enhanced magnetic resonance imaging and liver ultrasound imaging in the course of a physical examination. He had a 56-year history of chronic B-related

hepatitis and liver cirrhosis. Dynamic contrast-enhanced magnetic resonance imaging revealed lesions in the superior segment of the right lobe and lateral segment of the left lobe on a background of liver cirrhosis. Hepatic biopsy revealed middle differentiation of HCC, and immunohistochemistry revealed that the lesions were EGFR positive and Braf negative. The diameter of the biggest lesion was approximately 4 cm. Both lesions exhibited low signal intensity on T1-weighted image (T1WI) and high signal intensity on T2-weighted image (T2WI), and diffusion weighted imaging (DWI). The lesion in the right lobe exhibited a “nodule in nodule” sign on T2WI (Fig. 1A, arrow). After contrast-media agent

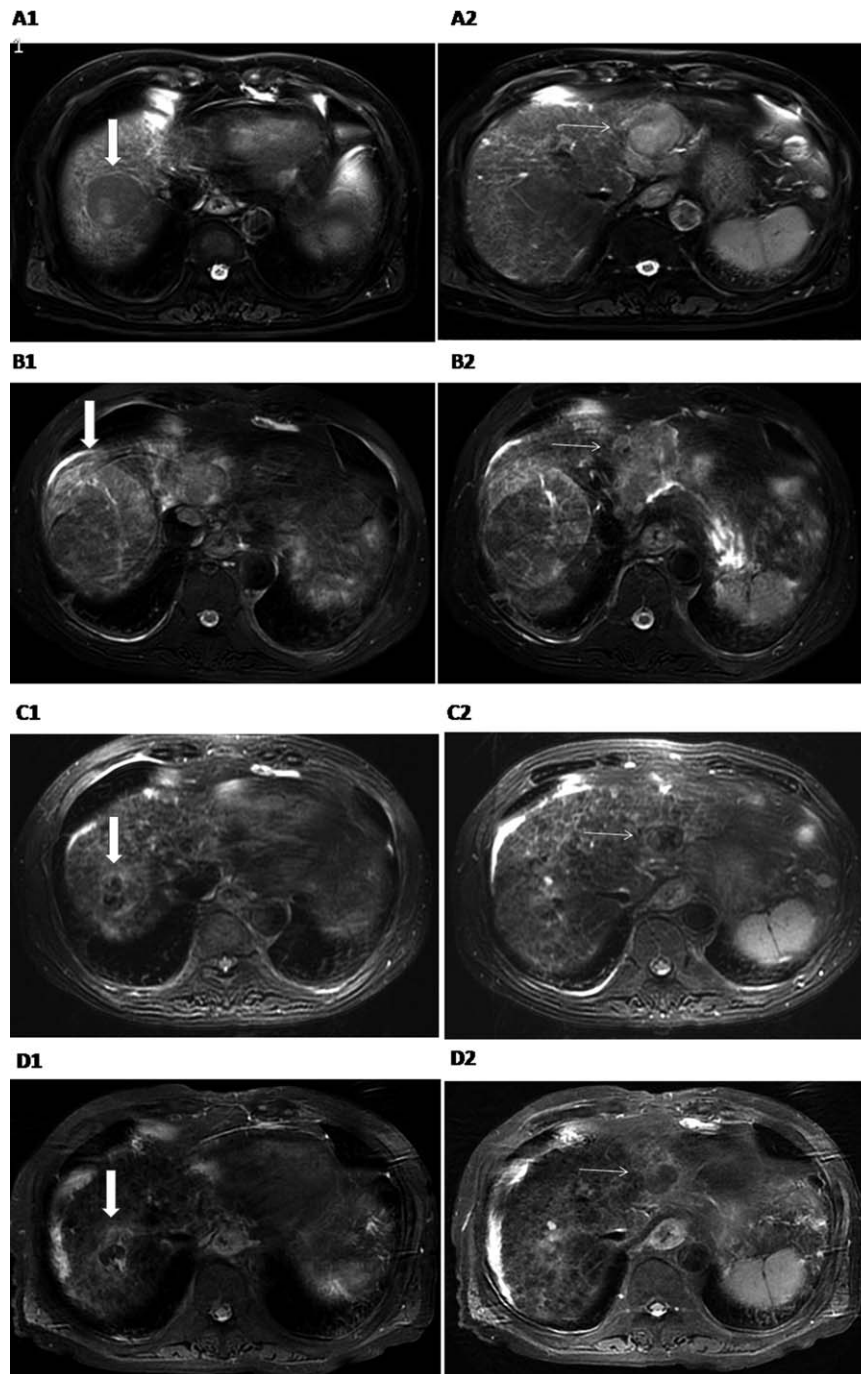


Figure 1. Magnetic resonance imaging scans (T2WI) depicting lesions in the right liver lobe (A1, B1, C1, and D1, thick arrow) and the left liver lobe (A2, B2, C2, and D2, thin arrow). Magnetic resonance imaging scan showing diagnosis (A), pretreatment (B), posttreatment (C), and present state (D). A significant reduction in the lesions was noted from B to D. CR was achieved. CR=complete remission, T2WI=T2-weighted image.

injection, the lesions exhibited moderate inhomogeneous enhancement on the arterial phase and “wash-out” on the portal vein phase, which was consistent with the imaging features of primary HCC (Fig. A1 and A2).

All lesions and alpha fetal protein (AFP) values regressed, and necrosis was noted in response to transhepatic arterial chemotherapy and embolization (TACE) therapy. However, the lesions gradually increased due to local tumor recurrence. Furthermore, intermittent sorafenib treatment was administered 1 year and 3 months after diagnosis and later withdrawn due to 3 incidences of thrombocytopenia (degree II bone marrow depression). Unfortunately, the lesions did not change significantly. By July 2015, the lesion in the right lobe had increased to 8.7 cm and the lesion in the left lobe had increased to 6.5 cm (Fig. B1 and B2).

After written informed consent was obtained from the patient, 100 mg nimotuzumab was administered every 2 weeks. Seven rounds of nimotuzumab treatment were administered within 5 months. Magnetic resonance imaging (MRI) scanning revealed that the lesion in the right lobe decreased to 2.4 cm, and the lesion in the left lobe decreased to 2.0 cm (Fig. C1 and C2). The main side effect was thrombocytopenia (degree III bone marrow depression) in the course of therapy. Although the patient did not receive additional nimotuzumab treatment after January 2016, MRI scanning indicated that the lesions continued to regress in the subsequent 5 months. At present, all of the lesions are necrotic, achieving CR standards (Fig. D1 and D2). The general condition of the patient is acceptable.

A more important index for HCC is AFP. The patient’s AFP value decreased from its peak twice: first after TACE treatment and then after nimotuzumab treatment (Fig. 2). The current value remains normal.

3. Discussion

HCC is one of the most deadly cancers worldwide. At present, HCC is the second cause of death in China; only lung cancer exhibits higher mortality. Due to excessive expression of multiple drug resistance genes involved in the resistance to chemotherapeutic drugs, chemotherapy is not highly effective. However, at present, molecular targeted therapy is a heavily researched topic in cancer therapy.

EGFR overexpression and the EGFR signaling pathway are often associated with cancer characteristics, such as cell proliferation, immune escape, metastasis, recurrence, tumor angiogenesis, chemotherapy resistance, and poor prognosis.^[4,5] Several reports indicate that the epidermal growth factor receptor (EGFR) is frequently expressed in HCC,^[6,7] most likely contributing to the aggressive growth characteristics of these tumors.

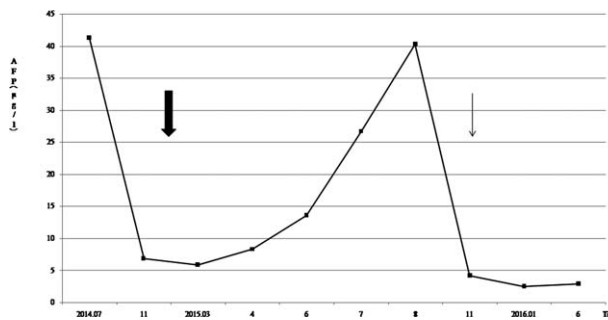


Figure 2. AFP value fell below its peak value on 2 occasions: after TACE treatment (thick arrow) and after nimotuzumab treatment (thin arrow). AFP= alpha fetal protein, TACE= transhepatic arterial chemotherapy and embolization.

Studies regarding targeting the EGFR monoclonal antibody cetuximab have achieved encouraging results in a variety of malignant tumors, such as head and neck squamous cell carcinoma and colorectal cancer, but its effects in HCC remain unknown. Cetuximab demonstrated no antitumor activity in HCC when applied as a single agent^[8-10] but elicited some activity in combination with chemotherapy in patients with a poor prognosis. Geng et al^[11] reported that a combination of cetuximab and rapamycin treatment significantly suppressed HCC development in HepG2 cell xenografts in mice and improved the survival. Huether et al^[12] reported that combining cetuximab with erlotinib resulted in synergistic antiproliferative effects. These in vitro and animal studies provide a rationale for future clinical investigations of cetuximab combination therapy for growth control of hepatocellular cancer. Poggi et al^[13] demonstrated that hepatic intra-arterial chemotherapy with cetuximab is a safe and feasible treatment for advanced hepatocellular carcinoma, and promising results were noted in patients who initially had a poor prognosis. Moreover, Asnacios et al^[14] reported that a combination of gemcitabine plus oxaliplatin (GEMOX) and cetuximab appeared to be active with manageable toxicity in patients with documented progressive HCC in a multicenter phase 2 study.

Our present case is an elderly patient who cannot tolerate the skin rashes and the other side effects of cetuximab. Thus, we selected another EGFR monoclonal antibody, nimotuzumab, for treatment. There are no reports on the effect of nimotuzumab alone in the treatment of HCC to date. Nimotuzumab is a humanized anti-EGFR monoclonal antibody that inhibits tumor cell proliferation, invasion, and metastasis. Similarly, several reports have also demonstrated that nimotuzumab has significant effects on various epithelial tumors, such as head and neck carcinoma, nasopharyngeal carcinoma, pancreatic carcinoma, and penile squamous cell carcinoma.^[3,15,16] In the present case, the treatment of nimotuzumab resulted in CR.

There are many possible explanations for the successful treatment. First, EGFR expression is not only restricted to tumor cells but has also been demonstrated to be expressed in sinusoidal endothelial cells, Kupffer cells, and liver macrophages. Previous findings demonstrate that genetic deletion of EGFR in macrophages is sufficient to inhibit HCC development.^[17] Therefore, targeting anti-EGFR therapies specifically to macrophages may result in positive effects. Second, numerous other growth factors and their receptors are deregulated in human HCC and directly or indirectly influence EGFR signaling.

To the best of our knowledge, this report is the first to describe the use of nimotuzumab to treat HCC. The good clinical response observed in this case suggested that anti-EGFR mAbs might be potential therapeutic options for HCC.

In elderly HCC patients, surgery and chemotherapy are not selected given the high risk of morbidity and severe side effects. Genome-based targeted therapy for aged HCC is an option in terms of its promising clinical response and hence deserves further investigation in a prospective clinical trial.

References

- [1] Ito Y, Takeda T, Sakon M, et al. Expression and clinical significance of erb-B receptor family in hepatocellular carcinoma. *Br J Cancer* 2001;84:1377-83.
- [2] Akashi Y, Okamoto I, Iwasa T, et al. Enhancement of the antitumor activity of ionising radiation by nimotuzumab, a humanised monoclonal antibody to the epidermal growth factor receptor, in non-small cell lung cancer cell lines of differing epidermal growth factor receptor status. *Br J Cancer* 2008;26:749-55.

- [3] Men HT, Gou HF, Qiu M, et al. A case of penile squamous cell carcinoma treated with a combination of anti-epidermal growth factor receptor antibody and chemotherapy. *Anticancer Drugs* 2014;25:123–5.
- [4] Berasain C, Avila MA. The EGFR signalling system in the liver: from hepatoprotection to hepatocarcinogenesis. *J Gastroenterol* 2014;49:9–23.
- [5] Huether A, Hopfner M, Sutter AP, et al. Erlotinib induces cell cycle arrest and apoptosis in hepatocellular cancer cells and enhances chemosensitivity towards cytostatics. *J Hepatol* 2005;43:661–9.
- [6] Kira S, Nakanishi T, Suemori S, et al. Expression of transforming growth factor and epidermal growth factor receptor in human hepatocellular carcinoma. *Liver* 1997;17:177–82.
- [7] Daveau M, Scotte M, Francois A, et al. Hepatocyte growth factor, transforming growth factor and their receptors as combined markers of prognosis in hepatocellular carcinoma. *Mol Carcinogenes* 2003;36:130–41.
- [8] Llovet JM, Bruix J. Molecular targeted therapies in hepatocellular carcinoma. *Hepatology* 2008;48:1312–27.
- [9] Zhu AX, Stuart K, Blaszkowsky LS, et al. Phase 2 study of cetuximab in patients with advanced hepatocellular carcinoma. *Cancer* 2007;110:581–9.
- [10] Gruenewald V, Wilkens L, Gebel M, et al. A phase II open-label study of cetuximab in unresectable hepatocellular carcinoma: final results. *J Clin Oncol* 2007;25:4598.
- [11] Geng J, Li X, Lang X, et al. Combination of cetuximab and rapamycin enhances the therapeutic efficacy in hepatocellular carcinoma. *Technol Cancer Res Treat* 2014;13:377–85.
- [12] Huether A, Höpfner M, Baradari V, et al. EGFR blockade by cetuximab alone or as combination therapy for growth control of hepatocellular cancer. *Biochem Pharmacol* 2005;70:1568–78.
- [13] Poggi G, Montagna B, Melchiorre F, et al. Hepatic intra-arterial cetuximab in combination with 5-Fluorouracil and cisplatin as salvage treatment for sorafenib-refractory hepatocellular carcinoma. *Anticancer Res* 2011;31:3927–34.
- [14] Asnacios A, Fartoux L, Romano O, et al. Gemcitabine plus oxaliplatin (GEMOX) combined with cetuximab in patients with progressive advanced stage hepatocellular carcinoma: results of a multicenter phase 2 study. *Cancer* 2008;112:2733–9.
- [15] Basavaraj C, Sierra P, Shivu J, et al. Nimotuzumab with chemoradiation confers a survival advantage in treatment-naïve head and neck tumors over expressing EGFR. *Cancer Biol Ther* 2010;10:673–81.
- [16] Liu ZG, Zhao Y, Tang J, et al. Nimotuzumab combined with concurrent chemoradiotherapy in locally advanced nasopharyngeal carcinoma: a retrospective analysis. *Oncotarget* 2016;7:24429–35.
- [17] Komposch K, Sibilina M. EGFR signaling in liver diseases. *Int J Mol Sci* 2015;17:1–31.