THE

GLASGOW MEDICAL JOURNAL

No. I. JULY, 1931

ORIGINAL ARTICLES

THE PLACE OF PERI-ARTERIAL SYMPATHECTOMY AND OF GANGLIONECTOMY AND SYMPATHETIC TRUNK RESECTION IN THE TREATMENT OF CERTAIN VASCULAR DISEASES AND OTHER CONDITIONS.

BY ARCHIBALD YOUNG, M.B., C.M.; B.Sc.; F.R.F.P.S.G.; F.A.C.S.(Hon.); &c.,
Regius Professor of Surgery, University of Glasgow.

(*Continued from* p. 321, vol. cxv.)

GANGLIONECTOMY AND TRUNK RESECTION.

In the course of this paper I have quoted, from time to time, the view of Leriche that, in certain conditions, where the simple peri-arterial sympathectomy operation is insufficient or is contra-indicated, a beneficial result may be obtained by operating at a higher level, say by doing a ramicotomy or ramisection; *i.e.*, by dividing white and grey rami communicantes at particular levels, according to the purpose which it is desired to achieve.

The operation of ramisection as a specific procedure was introduced by the late Dr. J. I. Hunter and by Dr. N. D. Royle, for the relief of certain spastic conditions.[39, 40] The operation suggested by them was based on a concept of the physiological working of the sympathetic system which was in great measure new, and which is perhaps to-day less generally accepted than it was at first. These writers ascribed to the sympathetic a rôle in the preservation of muscular tone

which probably few physiologists are now prepared to accept, and there is still widespread difference of opinion, both as to the physiology and as to the proved value of their procedure. Be that as it may, there is no doubt that the work of Hunter and Royle formed a definite and important mile-stone in the development of the surgery of the sympathetic system.

No very great further step was necessary to reach the stage of ganglion resection. If the rami communicantes could be cut with safety, and with beneficial effect, why not excise the ganglia? If the rami communicantes could be cut, why not separate one ganglion from those above and below it; why not take it away altogether? And if one ganglion, why not several?

I think it is certainly true that it was the incidental observation of Royle and others, in cases of ramisection, that patients who were submitted to these operations showed a definite and substantial rise in temperature in the limb on the affected side, that led to the purposeful concentration of attention upon this aspect of the clinical picture, and ultimately to its application in certain conditions previously regarded as practically beyond the reach of treatment.

Royle, in 1924,[41] had described how, six hours after the operation of ramisection, in a case of spastic paralysis, the leg on the side operated upon was better coloured than the other, and felt warmer. The difference in warmth was not actually estimated by the thermometer.

In the same year, Adson and Brown[42] had observed the same phenomenon, in a case of spastic paralysis in which a transperitoneal lumbar sympathetic ganglionectomy had been done. They checked the degree of rise in temperature both by thermo-couple and by calorimeter. Further, they found that the rise in surface temperature was not an evanescent phenomenon, but that it was maintained for months, and showed every sign of being permanent. Out of this observation have come many developments of great importance in the more recent surgery of the sympathetic system. First of all, it led Adson and Brown to apply the same procedure of lumbar sympathetic ganglionectomy to a case of severe Raynaud's disease. The first case was operated on in March, 1925, and a preliminary report of it was issued a few months later. Adson and Brown have described how the relief of symptoms

in that first patient was so dramatic that they were almost afraid to believe their eyes.

Other patients were dealt with in the same way, and a somewhat similar procedure was devised for application to the upper limb. So that now it is possible to say that, by such a procedure, in severe cases of Raynaud's disease, the painful spasms of the peripheral vessels can be entirely prevented, or substantially relieved, and normal colour returns to the part. Both objectively and subjectively, the surface temperature is improved, and ceases to be subject to the fluctuations which formerly affected it. The patient no longer has occasion to dread exposure to cold. The increase in surface temperature may be anything from 2° or 3°C. up to 12° or 15°C.

Royle and others have continued to favour ramisection, whether lumbar or cervico-thoracic, in place of the more extensive ganglionectomy or trunk resection advocated by Adson, Loyal Davis, Kanavel, and others, but at present it seems likely that the more extensive procedures of the latter group of workers will continue to hold their ground, at least until our knowledge of the sympathetic system has become more exactly stabilized.

It is interesting to recall the fact that, of all the possible types of operation upon the sympathetic, those upon certain of the ganglia have been longest in use, notably those upon the cervical ganglia. The operations upon pre-ganglionic and post-ganglionic fibres, and those upon the peripheral vascular prolongations, are of much more recent development. It might be thought, therefore, that by this time some reliable estimate might have been arrived at regarding any possible ill-effects that might follow upon excision of ganglia. And yet such unfavourable reports are singularly wanting.

Leriche, it is true, holds very strongly the opinion that operations upon the ganglia are seldom justified, either in theory or in practice, and he believes that most of the beneficial effects which ganglionectomy and trunk resection may bring about can equally well be obtained by ramicotomies or by peri-arterial sympathectomy. He holds that ganglionectomies are anti-physiological, unnecessarily radical, and "blind." He gives three reasons for this point of view[43] :—(1) Because the resection of ganglionic chains exceeds the desired end, and may have real disadvantages, perhaps not immediate, but none the

less definite. He points to the degeneration of the myocardium which may follow upon removal of the stellate ganglion; to the disturbances of phonation and of swallowing which may occur after the superior cervical ganglion has been excised, in cases where the vagus is closely related to it; (2) Because peri-arterial sympathectomy, properly applied, may cure many cases of genuine Raynaud's disease just as effectively as an extensive ganglionectomy; and (3) Because, in those irregular cases of Raynaud's disease where there are vaso-dilatation and cyanosis, ramisection will generally be successful, even where a peri-arterial sympathectomy is ineffective.

Leriche would prohibit all extensive ganglionic resections, and he states that he is "unable to understand how any one can venture lightly to sacrifice the entire lumbar chain on one or both sides, merely in order to obtain a vaso-dilator effect which is produced by any sympathetic operation."

With reference to the first and most important of these reasons, namely that referring to possible ill-effects of ganglion resection, one must admit a certain cogency in the argument; but it is very easy to stress it too much.

In his Linacre Lecture at Cambridge last May, Walter B. Cannon, Professor of Physiology at Harvard, dealt very fully with many of the known facts regarding the removal of varying amounts of the sympathetic chain.[44] Some of these may be referred to here. Cannon and his co-workers have made careful experimental investigation into the effects produced by extensive sympathetic excisions in cats, dogs, and monkeys. They excised the cervical, thoracic, and abdominal portions at first separately. Later, however, they removed the ganglionic chains of the thoracic and abdominal portions, from stellate ganglia down to the brim of the pelvis, in an unbroken condition. In so doing, they eliminated sympathetic control of the viscera completely, yet the animals lived without apparent difficulty. Numbers of these animals lived for many months, even a year, before being sacrificed. One animal was still alive after two and a half years. It is true that certain previous workers on similar lines had reported serious general effects, such as general depression, wasting, lowering of body temperature, and severe lesions of the gastro-intestinal tract. Yet Cannon reports having removed the abdominal sympathetic chains and the splanchnic nerves from more than 100 cats,

and from some of them the semilunar ganglia and nerve strands from cœliac axis and from the superior mesenteric artery, without in any case observing any serious symptoms following the procedure. Further, he has found that extensive unilateral sympathetic ganglionectomy in young kittens seemed to interfere in no way with their growth in size and weight. He believes, therefore, that the sympathetic system is not concerned with growth of the skeleton or of the internal organs. Even the basal metabolism, after removal of each of the three portions of the sympathetic chains, was not found to be very much affected. There was usually a slight fall in the metabolic rate, most persistently observed after excision of the cervical portion; but even this was not more than 10 per cent, and might be regarded as negligible.

Nevertheless, certain defects undoubtedly followed. An animal might be totally sympathectomized, and continue to live, apparently in good health, but it was easy to show that its ability for work was greatly reduced—even as much as 35 per cent. There was an obvious defect in its capacity for adaptive change in its circulatory system, and there was a total paralysis of the mechanism for liberating sugar from the liver. The usual increase in the number of red blood corpuscles following upon excitement did not occur. Further, sympathectomized animals suffered more from exposure to cold. The usual contraction of peripheral arterioles and capillaries produced by exposure to cold—so important a factor in checking the loss of heat—did not occur; while the acceleration of heat production, through the action of an increased secretion of adrenalin in response to a falling body temperature, did not occur.

Cannon reports that "the sympathectomized animal, when confronted by the problem of maintaining a normal temperature when this tends to fall, is physiologically inefficient." He also reports a corresponding inability in the sympathectomized animal to accommodate itself to heat. He concludes, therefore, that though the sympathectomized animals continue to live fairly satisfactorily within the protective confines of the laboratory, where there are no marked temperature changes, no necessity for struggle for food, no requirement of escape from enemies, &c., yet it would be wrong to infer from this that the sympathetic system is of only minor importance for the proper functioning of the body. He believes that such

an inference would certainly be wrong. "If these animals were free in the outer world, and had to meet its requirements of struggle, there would be no delivery of sugar to the blood according to need, no polycythæmia, no splanchnic vaso-constriction, with consequent rise of blood pressure and faster blood flow, no great acceleration of the heart, no shifting of the circulation to benefit the contracting muscles, no secretion of adrenalin to hasten coagulation and to abolish the effects of fatigue. The deficiencies of the sympathectomized animal are clearly revealed when it is exposed to cold or heat. If exigencies arise it is unable to preserve the constancy of its internal environment."

Such physiological evidence would seem, in some measure, to support Leriche's view; but it is necessary to remember that these experimental results refer to the most extensive, indeed, to almost total, resections of the sympathetic system, and to almost equally extensive resections of its para-sympathetic complement; *i.e.*, resections of almost the whole autonomic system: an altogether different proposition from that involved in the purely local and limited ganglionic resections with which we are here concerned—resections, too, which in no case involve interference with semi-lunar or cœliac ganglia, with the inter-mesenteric plexuses, or with the splanchnics; disturbance of any or all of which is probably the main factor in bringing about most of the defects in the adaptive capacity of the individual or animal in relation to its internal environment as well as in respect of its external relations.

OPERATIVE PROCEDURE FOR CERVICO-THORACIC GANGLIONECTOMY.

Cervico-thoracic ganglionectomy, for the treatment of angina pectoris, was carried out for the first time by Jonnesco in 1906, on the suggestion of François Frank. The success of the procedure led to the operation being performed by numerous other surgeons, with varying degrees of success. The same type of operation has been done also for various other conditions, such as epilepsy, exophthalmic goitre, &c. The operation has not been uniformly successful. In some cases, results have been favourable, while in others varying degrees of failure have been recorded; and, indeed, the operation has probably suffered

in credit by its indiscriminate application to varied conditions, for many of which there was no sufficient physiological reason to lead one to expect that it could afford substantial benefit. Leriche has been accustomed to recommend, instead of actual excision, section of certain of the communicating branches of the ganglion.

It is only within the last decade that the therapeutic effect of removal of the cervico-thoracic (stellate) ganglion, on one or both sides, has been tested in Raynaud's disease. Loyal Davis, Kanavel, Royle, Adson and others have, with varying success, carried out the operation. At first an anterior method of approach was employed. The actual method of exposure varied considerably.

Of the methods of approach from the *anterior* aspect, that of Royle, published in 1928,[45] is not substantially different from the method employed and described by Leriche. Both seem to give free exposure, but both have definite anatomical disadvantages and difficulties. Further, Leriche's operation did not really contemplate actual removal of the ganglion, but was a form of ramisection, or ramicotomy; while Royle's procedure, which began as a ramisection, was later amplified to resection of the ganglion and division of the thoracic trunk immediately below it.

Adson and his co-workers, being impressed by the frequently incomplete results of removal of the stellate ganglion by the anterior approach, even where it included, as in Royle's later operation, section of the trunk immediately below, were led to the conclusion that it was desirable to divide the trunk a little lower down, so as to include the second thoracic ganglion. Kuntz had shown that the second thoracic ganglion sends grey rami to the first thoracic spinal nerve as well as to the second, and even the latter frequently contributes to the formation of the brachial plexus. They found that, by this lower division and the slightly larger resection, they were able to obtain a much more complete and lasting result in the treatment of the vaso-motor disturbances associated with Raynaud's disease of the upper extremity.

Recognizing this fact, they came to the conclusion that the anterior method of approach did not provide the necessary freedom of access, and they have adopted a new technique which involves a *posterior* approach.[46] This is the procedure

which I have employed, and which was made use of in the case which I have been able to show this evening, particulars of which will be given later.

THE POSTERIOR APPROACH FOR CERVICO-THORACIC GANGLIONECTOMY.

The following is a short description of the operation by the posterior route. The patient is placed in the prone position, with the upper part of the trunk raised on pillows and the neck flexed, the head hanging somewhat forward. General anæsthesia is employed. An incision 4 or 5 inches long is made either in the middle line—if it is proposed to do both sides at the one sitting—or 1½ inches from the middle line—if only one side is to be done. In the former, once the skin and subcutaneous tissue have been divided, the edge of the wound must be strongly retracted towards the side on which the operation is being done, and then the deeper parts are incised further out. The incision extends from about the level of the sixth cervical spine as far down as the level of the fourth dorsal. The incision is deepened carefully and systematically, recognizing the successive muscular layers as they are divided, trapezius, rhomboids and serratus posticus, erector spinæ muscles, and the lower end of the splenius. The margins of the wound are separated by retractors and the bony relations are confirmed.

One considerable difficulty is the recognition of the actual level of the spinous processes. It is always somewhat difficult to be quite certain which spinous process is the seventh cervical and which the first dorsal. The important one, in that its level should correspond with the centre of the incision, is the spinous process of the second dorsal; for the actual exposure of the sympathetic trunk is supposed to be accomplished best after excision of the transverse process of that vertebra, and of the innermost three or four centimetres of the corresponding rib. In the patient to whose case I have already referred we had been fully alive to the difficulty of exactly locating the second dorsal spine, and had endeavoured to make certain of the level by previous *x*-ray films. Even with this preliminary precaution we actually made the mistake of centring the incision on the level of the third spinous process, and removing the inner end of the third rib instead of the second.

Having cleared the bony surfaces at the proper level, and having identified the proper vertebral processes, the periosteum over the rib is incised, and cleared from the surface of the bone; whereafter the posterior and inner 3 cms. of the rib are excised, the corresponding transverse process of the rib being simultaneously divided and removed. There ought not to be any special bleeding. If the intercostal artery is injured, it is easily ligated. Injury to the first and second intercostal nerves should be avoided. When the portion of rib has been excised, the chest cavity is open, and the surface of the pleura, which ought to escape injury if ordinary care is taken, becomes at once apparent. It is carefully separated from the side of the vertebral column and retracted outwards and forwards. The sympathetic trunk then becomes visible between the second thoracic ganglion and the cervico-thoracic ganglion above. The latter is not at first visible. (In our case, the trunk was exposed below the third ganglion.)

Following exposure of the sympathetic trunk, the latter is divided well below the second ganglion (in our case it was divided below the third), and is carefully lifted upwards; the rami of communication with the second and third thoracic nerves are divided, and by gentle traction on the upper segment of the ganglionic trunk the lower portion at least of the cervico-thoracic ganglion is brought into view. Rami to the subclavian are divided, and part or the whole of the cervico-thoracic ganglion is taken away, after division of ascending and other branches. This completes the operation. (In our case there was no bleeding to speak of, and no difficulty in hæmostasis.) The wound is closed with care, successive muscular layers being sutured in turn.

Following operation, it is probably best to keep the patient in the prone position during the first few days, whereafter the dorsal decubitus may safely be adopted.

Note (23rd March, 1931).—The method of approach described above is well illustrated in Figs. 3, 4, 5, 6, 7, and 8 in the article by Adson and Brown in *Surgery, Gynecology, and Obstetrics*, May, 1929, and for the purpose of this paper I sought permission from Dr. Adson, and from the Editors of *Surgery, Gynecology, and Obstetrics*, to make use of these figures.

In a letter in reply, of date 4th March, however, Adson informed me that he has now modified his method of posterior approach in the operation of cervico-thoracic ganglionectomy, and that he finds it more convenient to enter the thoracic cavity through the first rib rather than through the second.

He believes that, in this way, he is able to ensure a more complete removal of the lower cervical and first thoracic ganglia, and to carry out a more careful ramisection of any ascending fibres to the two lower roots of the brachial plexus.

He has been good enough to send me prints of new figures to take the place of those referred to above, and with these, appropriate descriptions, or legends.

I desire to express my sincere appreciation of his courtesy in allowing me to reproduce these new prints in this paper (Figs. 7, 8, 9, 10, 11, 12, 13).

A. Y.

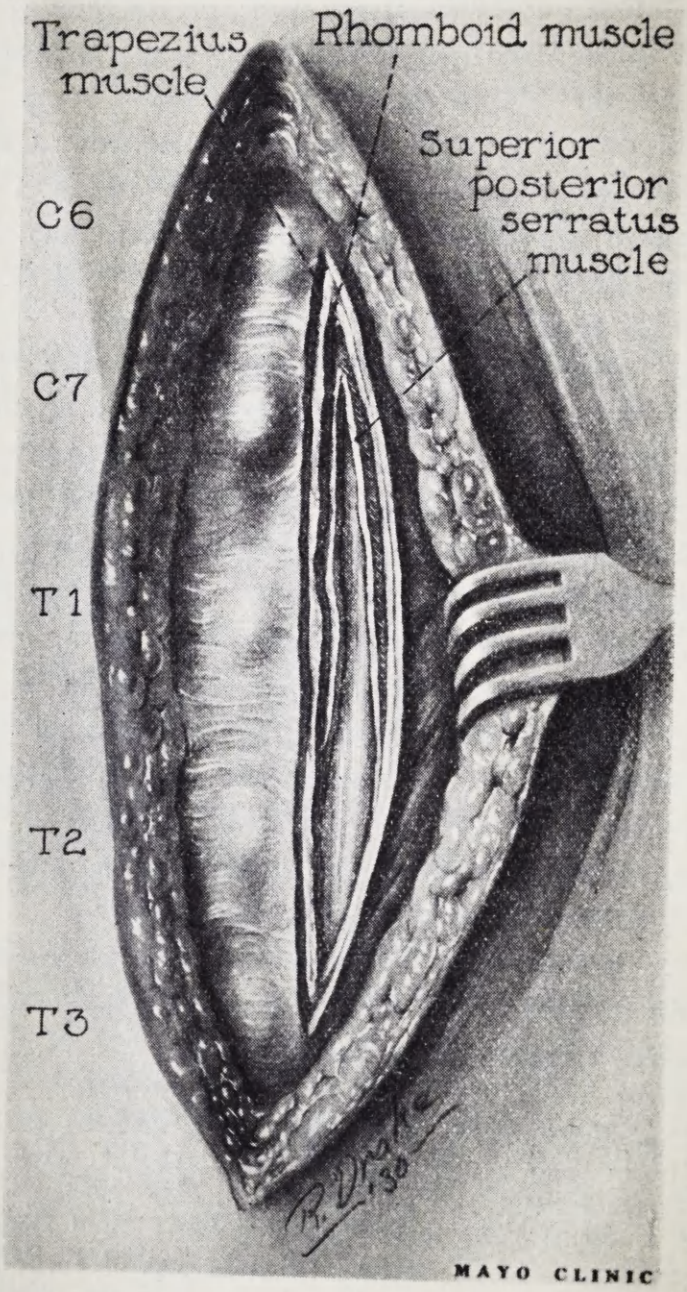

CERVICO-THORACIC GANGLIONECTOMY, POSTERIOR APPROACH—RIGHT SIDE (ADSON).

FIG. 7.—Incision through skin, aponeurotic structures, and superficial muscles. (By courtesy of Dr. Adson.)

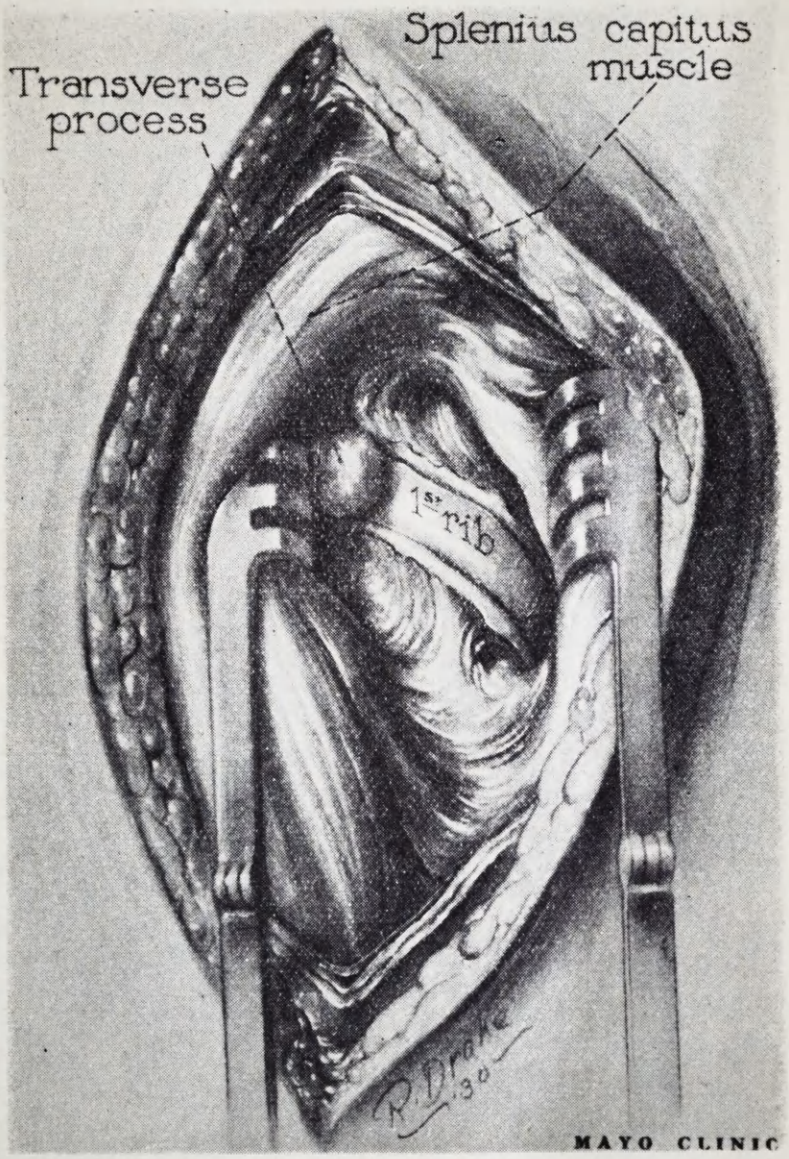

CERVICO-THORACIC GANGLIONECTOMY, POSTERIOR APPROACH—RIGHT SIDE (ADSON).

FIG. 8.—Exposure of first rib and transverse process of first dorsal vertebra. (By courtesy of Dr. Adson.)

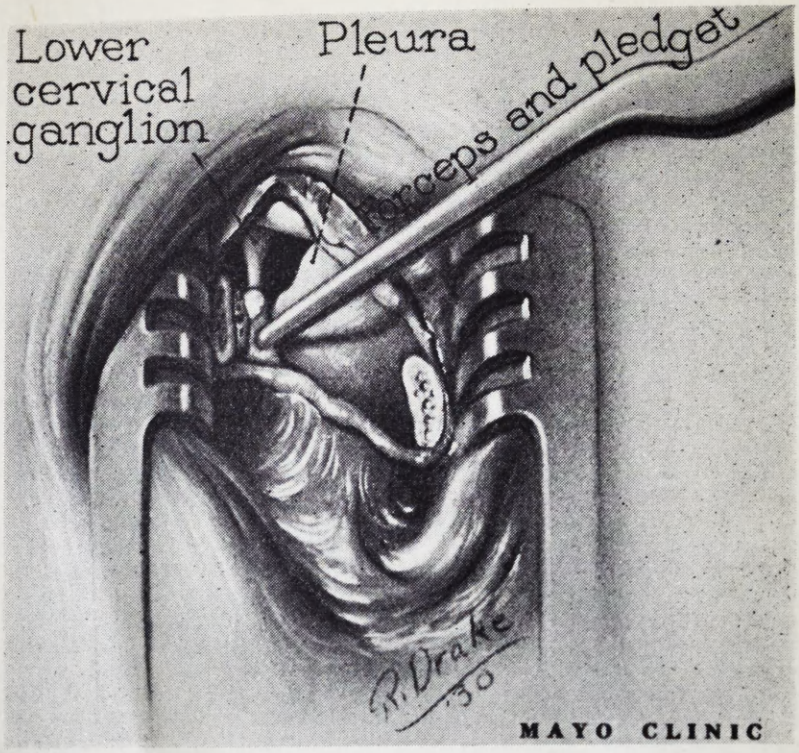

CERVICO-THORACIC GANGLIONECTOMY, POSTERIOR APPROACH—RIGHT SIDE (ADSON).

FIG. 9.—Dissection exposing thoracic trunk, following resection of first rib and transverse process. (By courtesy of Dr. Adson.)

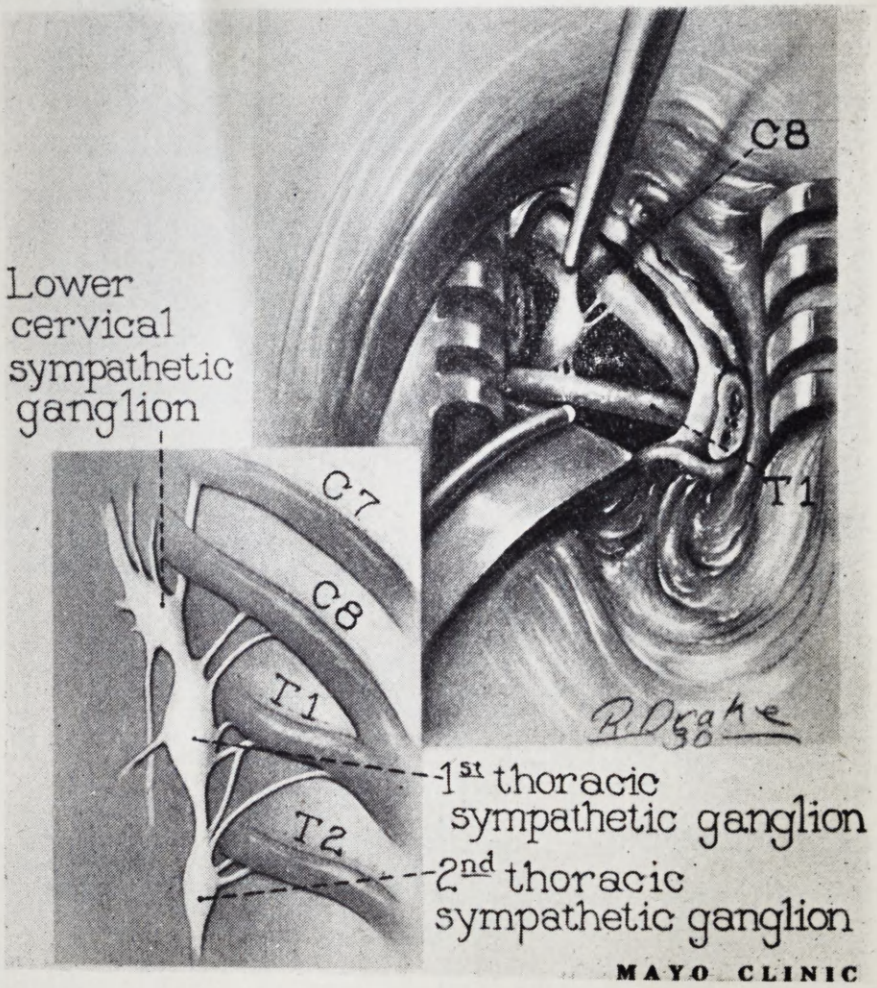

CERVICO-THORACIC GANGLIONECTOMY, POSTERIOR APPROACH—RIGHT SIDE (ADSON).

FIG. 10.—Delivery of lower cervical and first thoracic sympathetic ganglia into wound, between eighth cervical and first thoracic nerves. (With schematic drawing illustrating relationship between cervico-thoracic ganglion and the brachial plexus.) (By courtesy of Dr. Adson.)

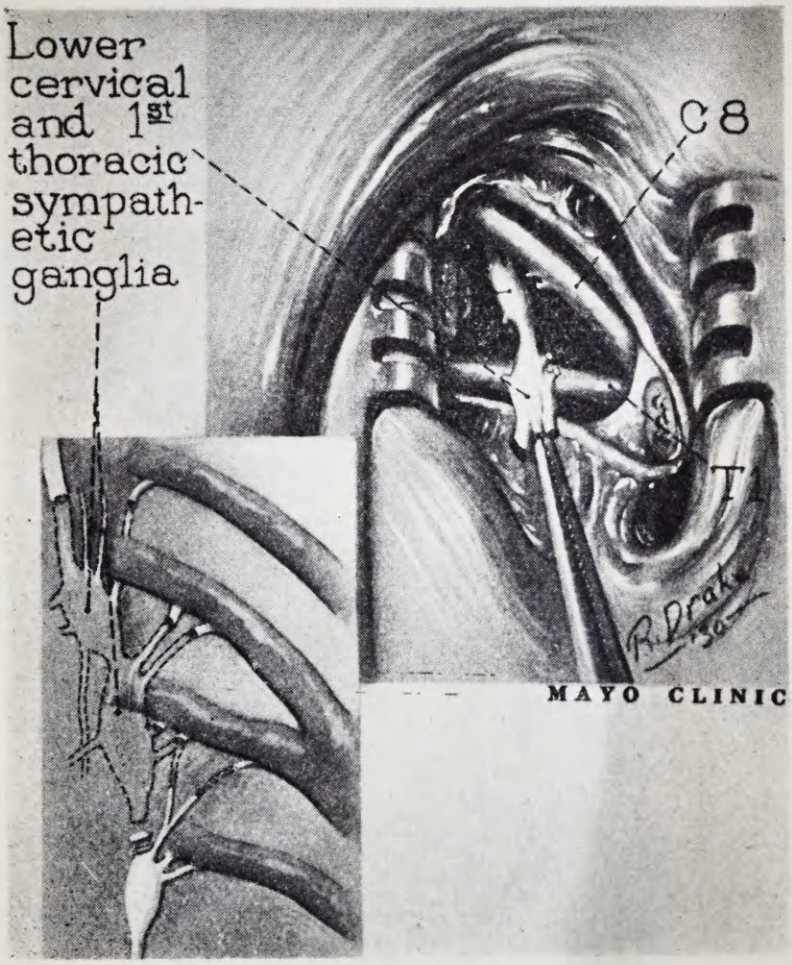

CERVICO-THORACIC GANGLIONECTOMY, POSTERIOR APPROACH—RIGHT SIDE (ADSON).

FIG. 11.—Resection of lower cervical and first thoracic sympathetic ganglia with the trunk, in conjunction with ramisectomy of fibres extending from the second thoracic ganglion to the first thoracic nerve. (By courtesy of Dr. Adson.)

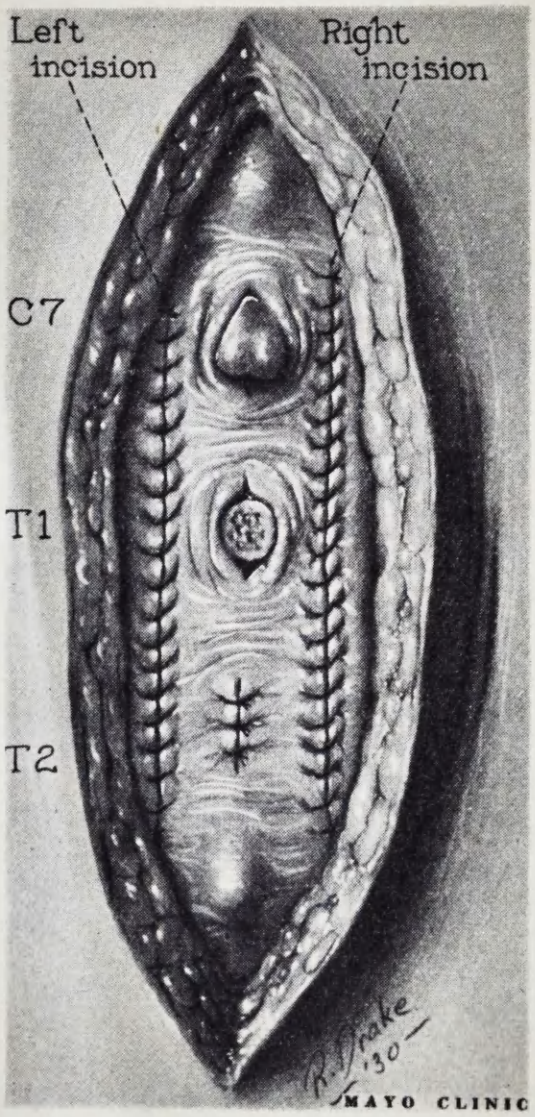

CERVICO-THORACIC GANGLIONECTOMY, POSTERIOR APPROACH—RIGHT SIDE (ADSON).

FIG. 12.—Partial resection of prominent cervical and thoracic spines during closure of wound. (By courtesy of Dr. Adson.)

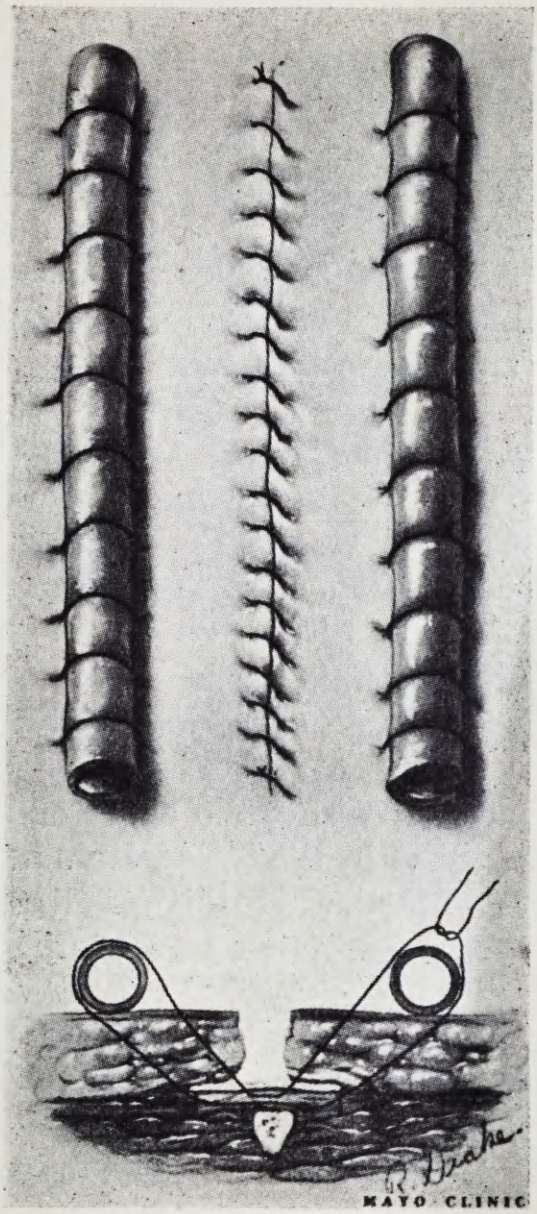

CERVICO-THORACIC GANGLIONECTOMY, POSTERIOR APPROACH—RIGHT SIDE (ADSON).

FIG. 13.—Closure of skin and fascial planes, with dermal and tension sutures. (By courtesy of Dr. Adson.)

OPERATIVE PROCEDURE FOR LUMBAR GANGLIONECTOMY AND TRUNK RESECTION.

The lumbar ganglionic chain, on one or both sides, may be reached either by an operation which is entirely extra-peritoneal, or by a transperitoneal operation. The former procedure can have little advantage over the latter, and in my view will always have very substantial disadvantages, by reason of the extensive wound which must be made, in order to obtain a sufficiently wide displacement of abdominal viscera to give effective and safe access to the side of the vertebral column.

The transperitoneal operation advocated by Adson,[47] on the other hand, even in a very stout subject, presents no special difficulties, though it may require the making of a pretty long abdominal wound. I have chosen the transperitoneal method of approach, therefore, in all my cases.

A long vertical incision is made, either medial or para-medial, and it should extend from close to the pubis as far up as may be necessary to afford free access, and without limiting freedom of manipulation within the abdomen. It is desirable to have the patient fixed in the Trendelenburg position before the peritoneum is opened, and this position is maintained throughout the special executive part of the operation. It allows of the intestines being packed upwards out of the way, and renders access to the special operative field to either side of the lumbar spine much easier (Fig. 14).

For exposure of the right lumbar chain, an incision is made close to the right lateral border of the vena cava, across the root of the mesentery of the small intestine, and downwards into the pelvis, crossing the right common iliac vein and artery. This incision, which may be from 15 to 20 cms. in length, and may be extended upwards if desired, divides the parietal peritoneum and opens up the loose subperitoneal tissue (Fig. 15). The cæcum, small intestine, and ureter are displaced outwards, and the edge of the vena cava, which bulges somewhat to the right of the aorta, is carefully drawn inwards. In this way, the surface of the psoas muscle is uncovered and

several of the downward descending nerves become visible. Of these, the most important as a guide to the sympathetic chain is the genito-femoral, which is usually easily recognized, being the innermost of all. The sympathetic trunk lies close behind

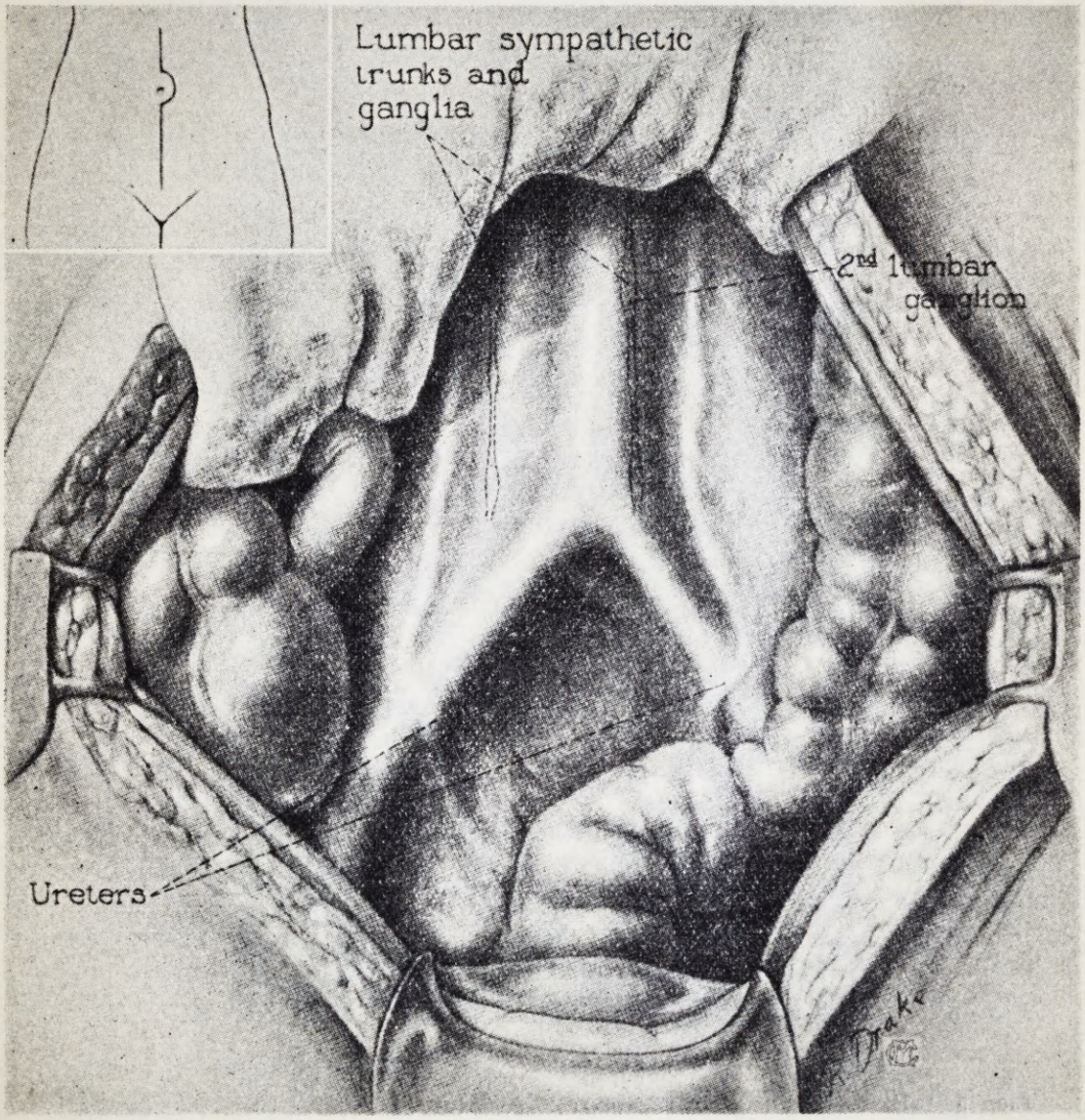

LUMBAR GANGLIONECTOMY, TRANSPERITONEAL APPROACH (ADSON).

FIG. 14.—General topography of the lumbar area, showing the relations between the vessels and the sympathetic trunks, as seen through the posterior parietal peritoneum after displacement of the intestine upwards and to either side. (By courtesy of Dr. Adson and the Editors of *Surgery, Gynecology and Obstetrics.*)

and under cover of the vena cava, and at its lower end passes behind the right common iliac vessels (Fig. 16). The fourth lumbar ganglion is situated just about the brim of the pelvis, and the trunk is divided immediately below this ganglion.

Rami of communication with successive spinal nerves, with the hypogastric plexus, and with the inter-mesenteric and aortic plexuses, are divided systematically from below upwards, and the cord is raised from its bed gradually until the second lumbar ganglion is reached. Above this it is divided, and the whole trunk is removed between the two levels named (Fig. 17). The only difficulty of note that may be encountered is in the

LUMBAR GANGLIONECTOMY, TRANSPERITONEAL APPROACH (ADSON).

FIG. 15.—Right lumbar ganglionectomy. The incision through the posterior parietal peritoneum on the right side. By courtesy of Dr. Adson and the Editors of *Surgery, Gynecology and Obstetrics.*)

avoidance of several small inter-vertebral veins, which cross the trunk at several places. With care, however, they can be avoided, and, even if one or more are accidentally injured, the bleeding can readily be checked, the small bleeding vessel being at once picked up and ligated. In our cases these small veins have caused no difficulty.

The exposure of the trunk on the left side ought to be even

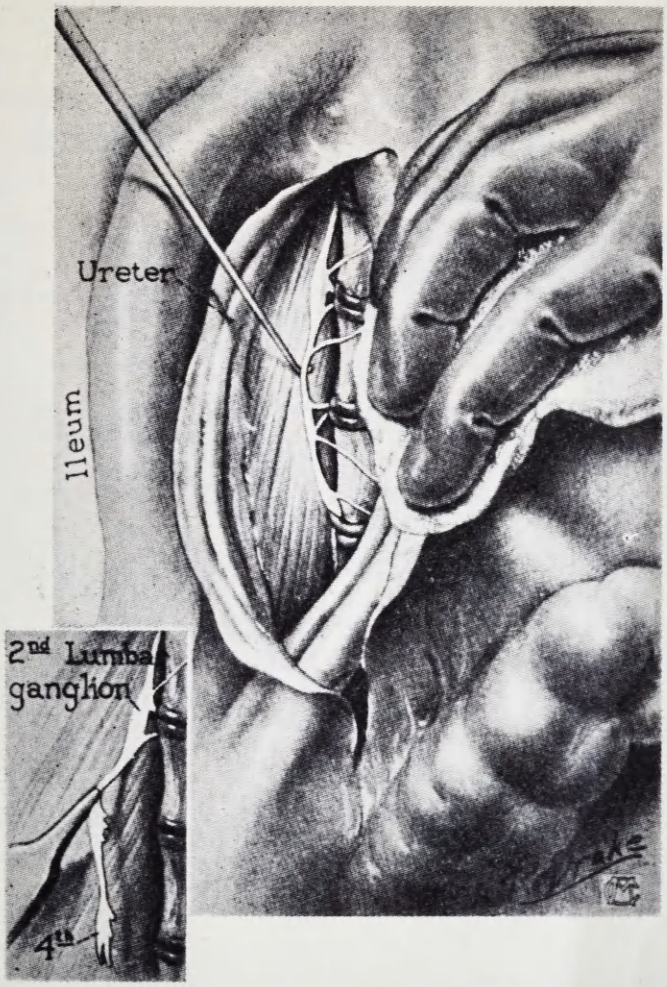

LUMBAR GANGLIONECTOMY, TRANSPERITONEAL APPROACH (ADSON).

FIG. 16.—Right lumbar ganglionectomy. Exposure and resection on the right side. Note the vena cava displaced slightly to the left, and the lumbar sympathetic trunk and inter-vertebral veins freely exposed. (By courtesy of Dr. Adson and the Editors of *Surgery, Gynecology and Obstetrics.*)

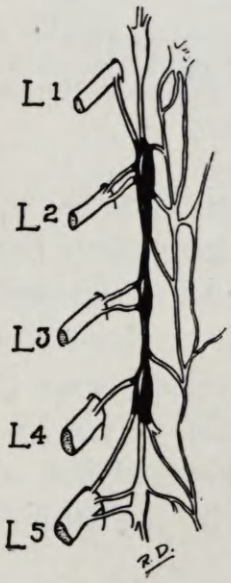

LUMBAR GANGLIONECTOMY, TRANSPERITONEAL APPROACH (ADSON).

FIG. 17.—Diagrammatic representation of the section of the lumbar trunk and the ganglia that are removed. (By courtesy of Dr. Adson and the Editors of *Surgery, Gynecology and Obstetrics.*)

easier than on the right, firstly because the vena cava is further out of the way, being more to the right, and secondly because the sympathetic trunk is slightly under cover of the left side of the aorta, which is readily and safely displaced a little to the right in order to expose it. On this side, the parietal peritoneum is incised lateral to the root of the sigmoid and to the attachment of the lower part of descending colon (Fig. 18). The sigmoid and descending colon are displaced well to the

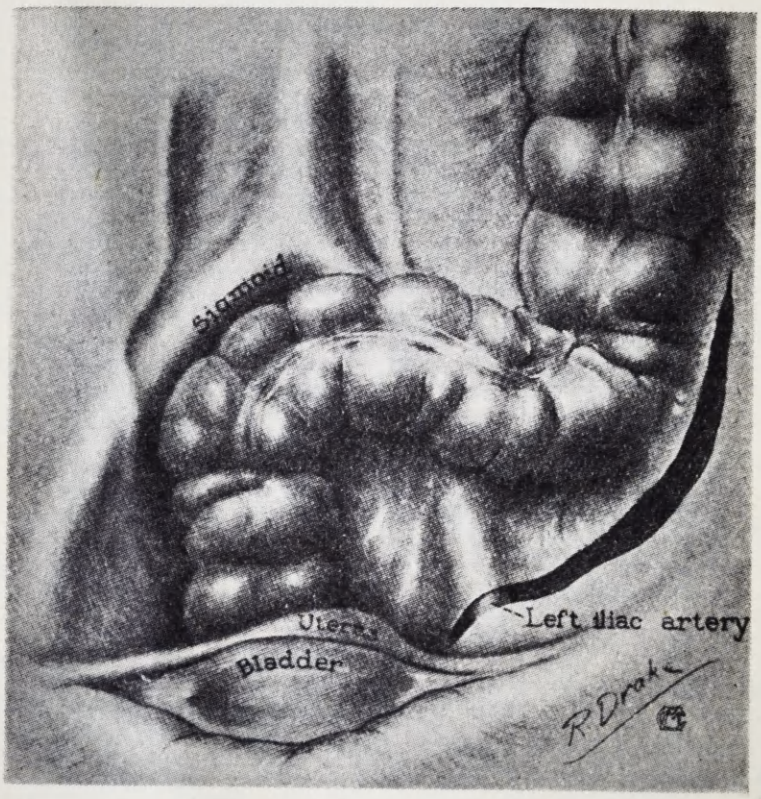

LUMBAR GANGLIONECTOMY, TRANSPERITONEAL APPROACH (ADSON).

FIG. 18.—Left lumbar ganglionectomy. The incision through the posterior parietal peritoneum on the left side, permitting elevation and retraction inwards of the sigmoid and descending colon. (By courtesy of Dr. Adson and the Editors of *Surgery, Gynecology and Obstetrics.*)

right along with the ureter until the psoas muscle, the aorta and its bifurcation, and the left common iliac vessels have been freely exposed (Fig. 19). The genito-femoral nerve perforating the muscle is recognized, and internal to it, under cover of the aorta, the sympathetic nerve trunk is exposed, from the level of the fourth ganglion at the brim of the pelvis up to the second ganglion, as on the other side. The segment of trunk, including these three ganglia, is excised in the same way as

on the other side, after systematic division of the various rami of communication (Fig. 20). The excision can be carried out either from below upwards or from above downwards, as seems to be most convenient. On this side there should be less risk

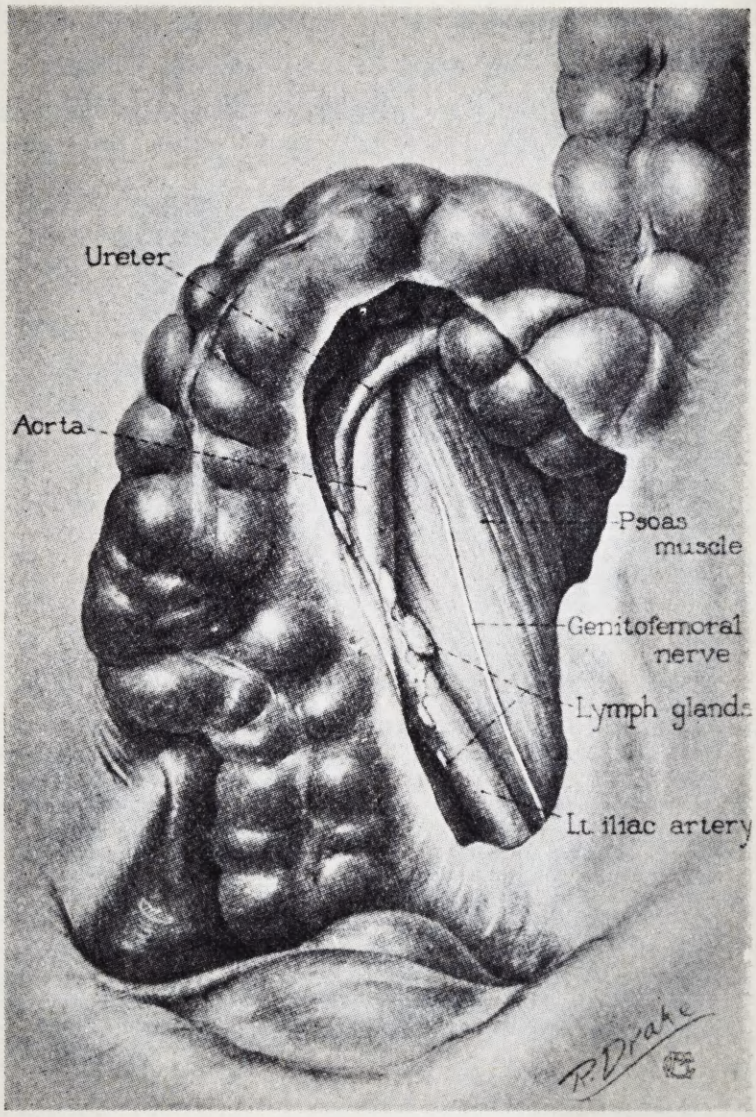

LUMBAR GANGLIONECTOMY, TRANSPERITONEAL APPROACH (ADSON).

FIG. 19.—Left lumbar ganglionectomy. Further elevation of the parietal peritoneum, retroperitoneal layers, and large bowel on the left side. Note the psoas muscle, the genito-femoral nerve, the left aspect of the abdominal aorta, and the common iliac artery, prior to exposure of the lumbar ganglia. (By courtesy of Dr. Adson and the Editors of *Surgery, Gynecology and Obstetrics.*)

of venous bleeding, as inter-vertebral venous branches of any consequence are generally absent.

It is of course hardly necessary to say that such displacement of small or large bowel, or of vena cava and aorta, or of ureter,

as is necessary in the adequate exposure of the ganglionic chain, should be carried out with care, in order to avoid unnecessary tearing of small venous branches, or injury to arterial or venous branches to the large bowel. It is well also to keep in mind the chain of lymph nodes to either side of the vertebral column, which occupies a position very closely related to that of the sympathetic chain. In one of our cases, indeed, I actually mistook it for the ganglionic chain at first, and excised it, under

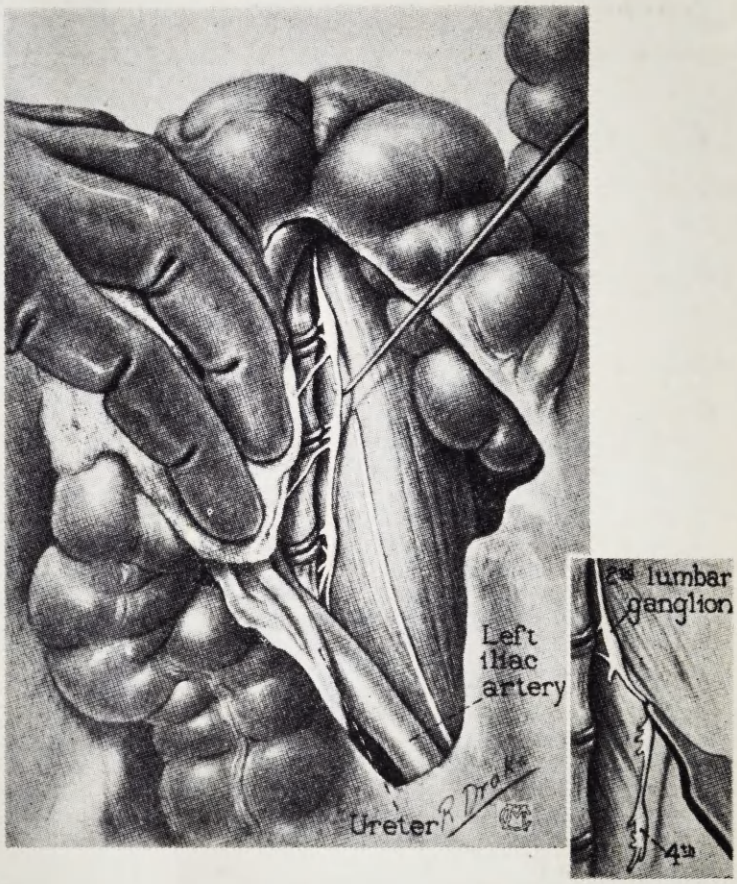

LUMBAR GANGLIONECTOMY, TRANSPERITONEAL APPROACH (ADSON).

FIG. 20.—Left lumbar ganglionectomy. Exposure and resection of the left lumbar sympathetic trunk, with the second, third and fourth lumbar ganglia. (By courtesy of Dr. Adson and the Editors of *Surgery, Gynecology and Obstetrics.*)

the impression that it was the ganglionic chain. Fortunately, however, I realized the mistake immediately after, and at once sought for and excised the sympathetic chain proper. One other point may be mentioned, namely, that the position of the second and third ganglia is liable to some variation. Sometimes the second ganglion is placed unusually high, and is only reached by extending the wound upwards sufficiently to

expose the lower border of the third part of duodenum. This applies on either side, but more particularly on the right.

Once the ganglionic chain or chains have been removed, and hæmostasis has been ensured, the retroperitoneal incision is sutured, the abdominal viscera are replaced in their normal relations, and the abdominal wound is closed in layers in the ordinary way. It is well to apply a copious abdominal dressing, and to give firm bandage support, at least during the few days immediately following operation, in order to help control of flatulent distension of the bowel, which sometimes follows the operation, but which, in our experience, yields readily to simple treatment.

As regards the immediate after-effects of the operation—apart from the beneficial vascular reactions which are the prime purpose of its performance—it has not been found that any serious results have followed. In our cases, there have been no special shock, no undue vomiting, no abnormal general temperature reaction; and the flatulent distension to which allusion has already been made has not given rise to special trouble, or to any particular anxiety.

CLINICAL APPLICATIONS OF THE OPERATIONS UPON GANGLIA.

In an earlier part of this paper I indicated that there were three main purposes envisaged in the case of both types of operative procedure, namely, peri-arterial sympathectomy and operations upon the ganglionic chain. These were (1) the augmentation, temporarily or permanently, of the blood supply to a particular part or region; (2) the abolition or modification of exaggerated or abnormal stimuli from the central nervous system to the peripheral vessels; and (3) the alleviation of certain painful phenomena related to certain diseased conditions of the vascular system.

In actual practice up to the present, the operations upon the ganglionic chain, which have just been described, have been applied with varying, but on the whole encouraging, success in three main groups of conditions. These are :—(1) The severer forms of Raynaud's disease; (2) general or localized obstructive conditions of the peripheral arterial system, such as arteriosclerosis, calcareous degeneration of the

vessel walls, or the special type of obstructive arteritis known as thrombo-angitis obliterans; and (3) certain chronic disabling conditions of the joints.

GANGLIONECTOMY IN THE TREATMENT OF RAYNAUD'S DISEASE.

The original theory of Raynaud, that the disease which goes by his name should be regarded as a vaso-motor neurosis, and that the clinical effects characteristic of the disease are due to a primary abnormality of the sympathetic nervous system, has been contested by Lewis and others,[48, 49] who have contended that a local fault in the peripheral arterioles is the fundamental cause of the clinical phenomena.

If the latter view be correct, it would seem to be improbable that operations upon the ganglionic chain could beneficially influence the disease or its characteristic manifestations. The results already published, however, show that, in a now quite considerable number of cases, results have been obtained of so favourable a character as to justify the appellation of cure; while in other cases, where the cure has been only partial, the probability is that the failure to obtain a complete cure has been due to a technical defect, or to want of completeness in the operative procedure carried out.

This applies more particularly to the cervico-thoracic operation, in which it is less easy to make certain of the complete interruption of nerve fibres to the upper limb. The operations on the lumbar ganglionic chain show a record of much more constant completeness, by reason of the greater certainty of interruption of all the nerve fibres to the lower limb. It seems likely that, if surgeons generally adopt the posterior route of approach to the cervico-thoracic ganglia, which gives freer access than the anterior operation, the results of that operation will come to be more uniform and complete.

The views put forward by Sir Thomas Lewis last year suggested to Brown and Adson the desirability of attempting to decide between the theory of vaso-motor neurosis, and that of Lewis, that the disease was local in the peripheral arteries. Accordingly, they suggested to S. L. Simpson, a Travelling Fellow on duty at the Mayo Clinic, to carry out a series of investigations to determine the essential primary mechanism. Simpson carried out a number of experimental observations,

both in simple, mild, uncomplicated cases of the disease, and in severe and complicated cases. The nature of these experiments need not be here detailed, but it may be said that they were carefully planned, and apparently accurately carried out, and judicially assessed. They are recorded in the " Proceedings of the Mayo Clinic " for October 15, 1930, and the conclusions based upon them are (1) that there was no evidence, in the early, mild cases, of any essential abnormality of the digital arteries; (2) that, in the severe and complicated cases, there existed both abnormality of the sympathetic nervous system and a local fault in the digital arteries; (3) that this local fault should be regarded as a complication, or late effect, of the disease, and not as an ætiologic agent.[50]

But, after all, controversy as to the primary ætiologic factor —however such controversy may be decided—cannot affect the conclusion, supported now by a considerable mass of clinical proof, that even advanced cases of Raynaud's disease have been substantially improved, and in many cases cured, by operations upon the ganglia.

The case of Raynaud's disease demonstrated this evening exemplifies the remedial effect of the operation in respect of one upper and one lower limb, and the result of the interesting physiological experiment which it represents is rendered all the more striking, in virtue of the contrast which these limbs exhibit to the condition still present in the other limbs. The following is a brief account of the case :—

CASE X.—*Raynaud's disease of a severe type in a young woman of* 27 *years of age, affecting both upper and lower extremities, and most markedly the right lower and the left upper. Peri-arterial sympathectomy of right femoral artery was performed in December,* 1928, *with some temporary relief of pain and healing of ulcers of the toes. Spasm, however, returned with great severity some months later, and gross gangrene of the right foot threatened. Lumbar ganglionectomy was accordingly done on the right side, in July,* 1929, *with resection of the sympathetic trunk. This gave immediate relief, and the right lower limb has ever since remained warm and free from spasm. During the following winter, the limb was never cold, though the other foot and leg were subject to the usual vaso-spastic phenomena. In the summer of* 1930, *the left upper limb gave much trouble, and ulcers appeared on the fingers. Ganglionectomy (cervico-thoracic) was accordingly carried out on 7th July,* 1930, *and was followed*

by a completely satisfactory result. The colour of the hand has remained normal since, and there has been no recurrence of spasm. The usual oculo-pupillary syndrome occurred. The patient now looks forward to similar treatment for the left lower and right upper limbs. (Patient exhibited at the meeting.) (Fig. 21.)

A. K., aged 27, came under my care, in the Western Infirmary, Glasgow, on 5th June, 1929, suffering from well-marked Raynaud's disease of a severe type. The condition only became particularly troublesome about two years before. It varied much from time to time, and the spasms of pain, and associated changes in colour of the extremities were observed first in the right foot. The other foot and the upper extremities, however, soon became definitely affected, and the periods of spasm became more frequent and severe. A year before her admission, she had appendicitis, and was operated upon for this condition. At the end of 1928, she was in hospital for the treatment of a painful condition of the right foot and toes, on several of which there were small superficial gangrenous patches.

The nature of the condition was not at first appreciated, but in December, 1928, a peri-arterial sympathectomy of the right femoral artery was done. There followed considerable relief of pain, and the ulcers on the toes healed. The relief, however, was only temporary, and, when the patient was admitted to hospital on 5th June, 1929, she was actually suffering from very severe vaso-motor spasm. The right foot and lower leg were greatly swollen, very dark in colour, and icy cold to the touch. It really seemed as if it were in a fair way to actual gangrene, and it was difficult to understand how even complete relief from spasm could induce return to anything like normal. The other foot and both hands also showed spasm, but to nothing like the same extent. There was some evidence of a similar vaso-spastic condition of the nose and ears.

In the course of 12 hours, the severity of the spasm had passed, and gradually the extremities returned to their normal colour, and became definitely warmer. Further attacks, however, followed, some severe, some more trivial; and their frequency increased during the next few weeks.

On the 3rd July, 1929, a resection of the 2nd, 3rd, and 4th right lumbar ganglia, with the connecting sympathetic trunk, and with division of associated rami of communication, was carried out. The method of approach was from in front, by the transperitoneal route. The steps of the operation were as has been already described. The excision was carried out from below upwards, after division of the trunk immediately below the 4th lumbar ganglion, the trunk being gently raised and its connexions systematically divided until the 2nd lumbar ganglion had been reached close to the duodenum. The abdominal wound was closed completely, in layers.

The immediate after-effect of the operation was to cause a perceptible increase in the surface temperature of the foot, an increase in temperature, as compared with the other foot, of between 8° and 9°F. The difference in temperature was no mere transient event, but was maintained—though not quite to the same degree—continuously thereafter. The patient was dismissed from hospital about a month later, greatly improved. The pain had entirely disappeared from the right foot and leg; the colour was a bright healthy pink. The circulation was obviously quite efficient and active, and there had been

FIG. 21 (Case X).—Colour drawing of the hands in Raynaud's disease, six months after cervico-thoracic ganglionectomy had been done on the left side.

Note.—1. *Right hand* (unoperated side), in condition of vaso-spasm, with marked asphyxia;
2. *Left hand* (operated side), showing normal rose-pink colour.

(Colour drawing by Mr. R. M. Buchanan, M.B.)

no periods of vaso-spasm in the right lower limb. In the case of the left foot and leg, however, attacks both of syncope and asphyxia had occurred with some frequency, and similar attacks had taken place in the case of both upper limbs.

During the following year the patient's general health varied considerably, and the vaso-spastic attacks in the left lower extremity and both upper extremities continued; but never, even during the coldest weather in winter, did the right foot and leg give any trouble. The patient had always the subjective sensation that the right foot was comfortably warm. She noticed that the right foot did not perspire. Even when the left foot was deeply cyanosed, icy cold to the touch, and acutely painful, the right maintained a normal healthy colour, and was comfortably warm.

In the following spring, *i.e.*, 1930, the condition of the left hand began to give so much trouble that the patient sought re-admission to hospital, with a view to further treatment. The fingers and hands were frequently deep blue, and even purple in colour, the fingers sometimes almost black. Frequent attacks of pain occurred in both hands; but both pain and discoloration were much more severe on the left, and there were the beginnings of a number of superficial gangrenous ulcers. She was readmitted to hospital on 25th June, with a view to operation upon the upper thoracic trunk. It was decided to operate only on the left side meantime.

On the 7th July, 1930, cervico-thoracic ganglionectomy was carried out, the posterior approach being used. The actual details of the operation were as have already been described. The only departure from the technique, as originally planned, was that the third rib was excised instead of the second rib (in error), and consequently the sympathetic trunk was divided below the third thoracic ganglion instead of the second. It was not, however, found difficult to so enlarge the wound as to give fair access to the upper part of the trunk, and, after the various rami had been divided, it was found possible, by firm, steady traction on the upper part, to pull it down sufficiently into the field of operation to permit of the removal of the greater part of the cervico-thoracic ganglion along with the second and third. There was no bleeding to speak of, nor was there any injury to pleura. The wound was closed in layers, and for a couple of days after operation the patient was kept in the prone position. Thereafter she was given freedom to lie on her back. Aseptic healing followed, and there were no obvious ill-effects from the operation.

The immediate beneficial after-effect was that, even before the patient got back to bed, the hand and fore-arm on the left side had entirely lost the former discoloration. The whole hand and fingers were of a healthy rose-pink colour, and felt comfortably warm. The skin of the left upper extremity was dry and had ceased to perspire. The same applied to the left side of the neck and face. The oculo-pupillary syndrome of Horner developed quite typically—contraction of the pupil, enophthalmos, and narrowing of the palpebral fissure.

Since this operation, the difference in surface temperature of the two hands has always been considerable. Immediately after operation, there was a difference of 8°F., but since then the difference has frequently been much greater, especially when the right hand has been in a state of vaso-spasm. The colour of the left hand has never varied materially, but has remained a healthy rose-pink, and, both subjectively and objectively, the hand has been comfortably warm (Fig. 21).

Viewed merely as an interesting physiological experiment, the results of the operations upon the left upper extremity and the right lower extremity have been of great interest. Viewed, however, as a test of the efficiency of the procedure employed, the results admit of no question. The patient and her friends, at any rate, are so convinced of the benefit which has been received, that they are anxious now to have the other two limbs dealt with in the same way.

Later note on this case (6th March, 1931).—Four days ago, the left lumbar sympathetic ganglionic chain was excised in the same manner as the right, and the immediate after-result has been completely satisfactory, the colour and surface temperature of the foot and toes on the left side being now in every way similar to the right; and vaso-spasm has ceased.

It is not suggested that similar favourable results will be obtained in all cases, however severe, of advanced Raynaud's disease. A stage may be reached, in which secondary changes in the peripheral arterioles, following upon the long continued attacks of spasm, may be of such a character and extent that no considerable vaso-motor relaxation is possible; or such degree of dilatation as is possible may be insufficient to establish a healthy circulation; and not only so, but, just as in thromboangitis obliterans, there may be a certain element of associated vaso-spasm, so also, in the more advanced cases of Raynaud's disease, arterial thrombosis is quite a possible occurrence; which would certainly complicate, and render difficult, the attainment of the satisfactory result hoped for as the result of ganglionectomy.

THE NON-SPECIFIC PROTEIN FEVER TEST AS AN INDEX TO SUITABILITY FOR OPERATIVE TREATMENT.

A similar test to the one devised by Brown and his co-workers,[51] in assessing the possibilities of benefit to be gained from ganglionectomy in obliterative arterial disease, and in the treatment of certain chronic joint conditions, may be employed also in doubtful cases of severe Raynaud's disease. The test involves the injection of non-specific protein—Brown uses triple typhoid vaccine injected intravenously, using an initial dose of from 20,000,000 to 50,000,000—in order to

produce a febrile reaction, and to observe whether and to what extent the rise of a few degrees in the general temperature is expressed also by a vaso-dilatation capable of thermometric measurement. The surface temperatures of the extremities are registered simultaneously with the blood temperature (say in the mouth). It is found that, whether or not vascular disease is present, both the blood temperature and surface temperature rise after the initial drop associated with the preliminary chill, the rise in the surface temperature being dependent upon (1) the initial temperature of the extremity; (2) the severity of the febrile reaction; and (3) the patency of the arteries. Where the extremities are cold, and vaso-spasm is considerable, the increase in surface temperature may be very great, and what Brown has termed "*the vaso-motor* or *vascular index*" is arrived at by subtracting the rise in blood temperature from the rise in surface temperature in degrees Centigrade. This is taken to represent a change in skin temperature due to the "shifting of blood that comes from vaso-motor changes." "This increase, divided by the number of degrees increase in the temperature of the blood, gives a figure which, in simple terms, indicates that for every degree rise in temperature of the blood there is in the temperature of the skin a certain number of degrees rise which is largely of vaso-motor origin."[52]

Brown has found that vascular indexes of from 5 to 14 are obtained in cases of Raynaud's disease, while, in cases of obstructive thrombo-angitis, with vaso-spastic disturbances, indexes of 2 to 6 have been found. The practical value of such an index in regard to the selection of cases suitable for operation is evident, seeing that the rise in surface temperature, which accompanies fever, corresponds in a general way with that which follows a sympathetic ganglionectomy. Brown has pointed out also that the estimation of this vascular index will aid the differential diagnosis between a pure vaso-motor disturbance and early organic arterial disease. In arterio-sclerotic disease, the vaso-motor or vascular indexes are low or zero, and the obtaining of such an index would therefore be a definite contra-indication to operation upon the sympathetic system in such conditions.

GANGLIONECTOMY IN ORGANIC DISEASE OF THE ARTERIES.

Reference may be made here to two main types of arterial disease in which the operation of ganglionectomy may prove of service. These are :—(1) A certain limited group of diseases affecting the arterial walls, such as *arterio-sclerosis and calcareous degeneration;* and (2) the special type of obstructive arteritis in which the lumina of the peripheral vessels are more or less extensively blocked by organized thrombus—the condition known as *thrombo-angitis obliterans,* or *Buerger's Disease.*

(1) ARTERIO-SCLEROSIS AND CALCAREOUS DEGENERATION.

In this first group, it can only occasionally happen that ganglionectomy will afford substantial promise of relief. Where the disease is widespread, and affects all the peripheral vessels uniformly, leading to a narrowing of lumina of widespread distribution, it is not likely either that a beneficial vasodilatation can be ensured by such an operation, or that any useful degree of collateral supply can be expected. In a few cases, where, perhaps, isolated vessels, affected by patchy calcareous degeneration, are involved, while many collateral branches have escaped, it may be possible to induce in these a useful augmentation of collateral supply, and incidentally to relieve the patient, in great measure, and even completely, from the distressing pains and the disabling effects of claudication.

The following is an illustrative case of this type in which a gratifying degree of success was achieved :—

CASE XI.—*Extreme calcification of the iliac arteries and of the arteries of the lower limbs, with disabling intermittent claudication, in a man of 59 years. Severe symptoms over a period of four years, leading ultimately to almost complete disablement for work. Right lumbar ganglionectomy and sympathetic trunk resection, on 7th March,* 1929, *was followed by immediate relief of symptoms, and the man was able to return to work. He has remained well since, and is on full employment. (Patient exhibited at the meeting.)*

A. T., aged 59, warehouseman, was admitted to the Western Infirmary, Glasgow, on 12th December, 1928, complaining of severe, disabling pains in the right lower limb, which interfered seriously with his getting about. The pains had begun four years previously, and came on whenever he began to

walk, so that ultimately walking was almost impossible. The pains originated about the hip, spreading down to the foot, where they became very severe, so that he would have to sit down. Often they would pass off in a few minutes, but at once returned whenever walking was resumed. About September, 1927, the symptoms, which had lessened for some time, gradually became more severe, and took longer to subside when he sat down. His previous health had been good. He was not in the habit of taking alcohol, but he smoked a good deal—as much as 4 ounces of thick black tobacco weekly. Examination of his chest, nervous system, and urine revealed no evidence of disease. Blood pressure was 120/90. The Wassermann reaction was negative. *X*-ray films showed advanced calcification of arteries in the upper and lower limbs and in the neck. He had varicose veins in the right leg. Treatment by iodide of potassium and diathermy gave no relief.

The patient was transferred to my ward upon 20th February, 1929, from the wards of Professor T. K. Monro (to whom I am indebted for the earlier notes of the case, and for valued advice in treatment). Apart from the very obvious calcification of the vessels, and the coldness of the extremities, the most notable feature was the painful, disabling, intermittent claudication, and my intention at first was to carry out a peri-arterial sympathectomy upon the femoral artery. On careful consideration, however, and in view of the risk attached to this operation in the case of a vessel with so marked calcareous change, I decided to perform instead the operation upon the lumbar ganglionic chain.

On the 7th March, 1929, right lumbar ganglionectomy was carried out by the transperitoneal route. There was no special difficulty in the operation. The sympathetic trunk was exposed as has already been described, and was excised from above the second lumbar ganglion to below the fourth. In the course of the operation, the iliac vessels were seen and palpated. They were extensively calcified.

The surface temperatures of the right and left feet on the day after operation showed a difference of 6°F. (Right 95°F., Left 89°F.). The leg surfaces showed a difference of 8°F. (Right 93·8°F., Left 85·3°F.). The temperatures of the thighs were identical (about 93°F.). The period immediately following operation—indeed the whole period of convalescence—was quite uneventful. The abdominal wound healed *per primam*, and the man left hospital about five weeks after his operation.

On the 2nd May, 1929, *i.e.*, about two months after operation, he reported at the Infirmary and was seen by Professor Monro, who found that he was able to walk for 80 minutes with a stick, and that his right lower limb felt much warmer than the left, both objectively and subjectively. Four weeks later he again reported. He was able to stand or walk for about three hours, without pain or special fatigue, and was about to return to his employment.

He has been seen at intervals since, the last occasion being about ten days ago, when he reported himself as quite well. He was doing a full day's work, and was on his feet all day in a warehouse. The right lower limb was still quite perceptibly warmer than the left and the surface was obviously drier. All pains had vanished.

Later note on this case (6th March, 1931).—In proof of the remarkable beneficial effect, the following quotation from a letter received from the patient dated 7th February, 1931, is of interest :—

" DEAR SIR,—I think it my duty to write thanking you and Dr. Monro

for the good you have done me after the suffering I had for four years previously. Last Sunday I had a walk, to see how my leg and foot are doing. I walked fully three miles out, and three in, and was not affected with any pain. I could have gone further. I did it in 2½ hours. I did not sit down during that time.

"A. T."

(2) THROMBO-ANGITIS* OBLITERANS, OR BUERGER'S DISEASE.

In this second group, in which the arterial block is due primarily not to contraction of the lumen by changes in the walls, but to a thrombotic process originating in the interior, the possibility of successful alleviation of symptoms will, as in the former group, depend very largely upon the extent of the arterial system which is involved, and the margin left for a collateral supply.

The typical form of disease which we know as thrombo-angitis obliterans or sometimes as Buerger's disease, has been confused with many conditions which do not conform with the pathological entity described by Leo Buerger, of New York, in 1908. The final phase, gangrene of variable extent, is a termination possible in quite a variety of vascular conditions, and the gangrene of Buerger's disease is not infrequently spoken of as pre-senile, infantile, or juvenile, to distinguish it from the well-recognized gangrene of later life due to arterio-sclerosis.

Up to the year 1879, little attempt had been made to differentiate between different types of gangrene of the limbs, according to their method of production, though a search of the earlier literature shows that there were many divergent views as to their pathology. In this year, von Winiwarter published a paper, entitled "On a Peculiar Form of Endarteritis and Endophlebitis, with Gangrene of the Foot,[53] in which he described the condition of the vessels in an amputated leg. The limb had been removed from a man of 57 years of age, who had had symptoms for 12 years, which ultimately ended in gangrene. Von Winiwarter's description and illustrative plates show that the condition which he described as endarteritis and endophlebitis corresponded pretty closely

* The spelling used here has been adopted deliberately, in preference to "thrombo-angeitis" or "thrombo-angeiitis," and in decided preference to "thrombo-angiitis," as employed by many American and British writers; for which there is no justification. It is in line with the common modern spelling in such a word as "lymphangitis," which has the same essential root—"ἀγγεῖον"—a vessel.

with the condition which we now know as thrombo-angitis obliterans. His observations dealt exclusively with one case.

In January, 1908,[54] Dr. Parkes Weber described a case of "Arteritis Obliterans of the Lower Extremity, with Intermittent Claudication," and in the same year appeared Buerger's contribution,[55] in which he introduced the term "thrombo-angitis obliterans." From that date, the pathological entity described by Buerger has been very widely discussed and investigated; but even to-day there continues to exist a good deal of confusion regarding the condition. Almost all the known abnormalities or diseases of the arterial vascular system have been confused with Buerger's disease, and Brown, Allen, and Mahorner,[56] in their recent treatise on thrombo-angitis obliterans, give a long list of names which, at different times, and by different schools, have been applied to thrombo-angitis obliterans. This varied nomenclature, which has been reproduced here from the list in their book, shows that there has been much confusion in the conception of the pathology of the disease, as well as a good deal of evidence of failure to differentiate between the disease as such and some of the more prominent symptoms.

VARIED NOMENCLATURE APPLIED TO THROMBO-ANGITIS OBLITERANS.[56]

Dysbasia angiosclerotica, erythromelalgia, crural angina, intermittent claudication, Gangstockung, juvenile gangrene, pre-senile gangrene, spontaneous gangrene, obliterating endarteritis, local asphyxia of the extremities, acrocyanosis, acroasphyxia, acrosphacelus, paralysie vasomotrice des extrémités, pseudo-erythromelalgia, non-syphilitic endarteritis obliterans, Raynaud's disease, Friedländer's disease, Russian, Jewish, or Yiddish disease, scleroderma, sclerodactylia, multiple neurotic gangrene, acroparesthesia, gangrän spontän, primary endarteritis obliterans, arteritis obliterans, obliterative arteritis of the young, arterio-phlebitis obliterans, endophlebitis and endarteritis, non-syphilitic obliterative arteritis of the Hebrews, and Tokuhatsu dasso gangraena spontanea (Japan).

Whatever possible overlapping there may be, in respect of

prominent symptoms and signs occurring in different vascular conditions, there is no doubt that the thrombo-angitis obliterans of Buerger is a very definite pathological condition, with a clinical picture which, in a certain number of its more characteristic features, is capable of being readily distinguished from other conditions.

THE BUERGER SYNDROME.

The disease, when well established, is generally characterized by a certain group of symptoms which, taken together, are sometimes spoken of as the Buerger syndrome. These include (1) disappearance of palpable pulse in such vessels as the dorsalis pedis, the posterior tibial at the ankle, the popliteal, the femoral, the radial, the ulnar; (2) pains of varying severity in the calf of the leg or in the foot in walking, or in the wrist, hand, or fingers, where the vessels of the upper limb are involved; (3) intermittent claudication, often experienced quite early in the disease. Sooner or later, vaso-motor phenomena develop (4)—rubor in the dependent position of the limb, alternating with pallor and syncope when the limb is elevated. Not infrequently there is an associated migrating phlebitis (5), affecting the territory of external or internal saphenous veins; less often of the larger veins of the upper limb. As a later development, there occur well-marked trophic disturbances (6), leading to degenerative changes in the skin and toe-nails, and ending ultimately in ulcer and local gangrene. The advance of the disease is usually slow, but it is progressive, and it does not necessarily have the symmetrical character of a primarily vaso-spastic disease such as Raynaud's disease.

PATHOLOGY AND INCIDENCE OF THROMBO-ANGITIS OBLITERANS.

The exact pathology of the condition is not even now definitely known. Race, sex, over-indulgence in tobacco, and other factors have been regarded by different writers as having a determining influence in its production. It appears to affect chiefly the male sex, though the other sex is by no means immune. The influence of race has perhaps been over-

emphasized, but it has long been recognized that it occurs with particular frequency amongst men of the Hebrew race.

Buerger's original statement, that thrombo-angitis obliterans was a disease almost peculiar to people of Semitic origin, obtained pretty general acceptance for a good many years. Buerger found that, in one series of 500 cases, there were only 7 in which the typical picture of the disease occurred in Gentiles. In a later series of 300 cases, the frequency had increased, there being 19 cases in Gentiles. As lately as 1925, Parkes Weber[57] stated that in London, as in New York, the disease was found almost exclusively in Hebrews of the male sex, who themselves, or whose parents, had emigrated from Central Europe. In more recent years, however, it has come to be recognized that the disease is much commoner among the Gentile peoples than used to be thought.

The only ætiologic factor which would seem to have withstood the test of investigation and of time is the one which Buerger himself particularly stressed in his original paper,[55] namely *the inflammatory factor.*

Buerger's paper was based on a study of the arteries and veins in 11 amputated limbs. As a result of his studies, both clinical and pathological, in these 11 cases, Buerger came definitely to the conclusion that the disease is inflammatory in origin. His original paper gives a full description of histological findings. He describes the manner in which the affected arterial trunks have their lumina occluded by thrombosis, and how the thrombus undergoes organization and canalization. In his sections of the vessels, he figures various foci strongly suggestive of the phenomena of an inflammatory process, with aggregations of leucocytes ("purulent foci"), or of endothelioid cells, and in many places giant cells. In some of the sections, these cell aggregates and associated giant cell foci had almost the characters of minute abscesses, while in others they had a superficial resemblance to miliary tubercles. In the later stages, when the more acute inflammatory condition was passing off, and healing was taking place, these cellular foci disappeared, and the thrombus was replaced by a fibrous mass, which more or less completely and permanently occluded the lumen of the affected vessel.

Until recently, there has been little or no satisfactory

evidence that the condition has a bacteriological origin, though there have been a number of reports by various workers on this aspect of the subject, the most recent perhaps being by Horton and Dorsey,[58] published in the "Proceedings of the Mayo Clinic," for 19th November, 1930.

The important point, however, to remember, in connexion with the typical form of thrombo-angitis obliterans, is that the disease in the acute stage frequently passes quite unnoticed. There is no constitutional reaction, or so slight that it is not observed. It is not until the occlusive process has extended so widely as to interfere substantially with the circulation of the affected limb, that the characteristic clinical manifestations of the disease disclose themselves. As Buerger has said, "It may be correctly said that patients afflicted with thrombo-angitis obliterans do not usually suffer directly from the disease itself, but from the disastrous occlusive thrombosis, which signalizes nature's method of healing a vascular lesion that has long since disappeared."

TREATMENT OF THROMBO-ANGITIS OBLITERANS.

This, then, is the condition in which, in a certain proportion of cases, the operation of ganglionectomy has been found to give remarkably satisfactory results. Apart from surgical treatment of this kind, the outlook for the patient, in well-marked cases of the disease, is unfavourable indeed.

Many forms of non-surgical treatment, such as warmth, diathermy, different types of bath, regulated massage, systematic postural adjustments, and various forms of internal medication, have been tried, but with very little beneficial effect. Injections of non-specific protein, from which, on theoretical grounds, some benefit might have been looked for, have met with very little success. In a few cases there has been a limited degree of temporary benefit, but practically no permanent improvement has resulted.

Even the possibility of relief by ganglionectomy probably depends on the persistence of a fair number of patent collateral trunks and branches, without which no useful vaso-dilatation or augmentation of arterial supply can be expected. Adson and Brown, in cases of this kind, make use of the estimation of the *vaso-motor or vascular index*, already alluded to, as an

indicator to the probable success or failure of the procedure. Some test of this kind, if it can be relied upon, must be of considerable value, because it is often by no means easy to form a really reliable estimate of the extent of vascular occlusion, where the pulse in most of the normally accessible arteries can not be palpated. One can only guess at the condition of vessels which are beyond the reach of palpation.

The following case, though perhaps not conforming exactly with either the pathological entity, or the typical clinical concept, of Buerger's disease, was characterized by the most extensive obliteration of arterial trunks in both upper and both lower limbs, and was treated, for the relief of the condition in the right lower limb, first of all by peri-arterial sympathectomy, and a year later by lumbar ganglionectomy.

CASE XII.—*Extreme widespread thrombo-angitis obliterans, in a young middle-aged woman, with recurring local lymphatic œdema of the left upper extremity, and sub-acute cutaneous pyogenic lesions, extending over many areas, and dating back to extensive tuberculous lymphadenitis in childhood. Buerger syndrome well marked, particularly in lower limbs, and especially in the right foot and leg, with agonizing pains and local gangrene of the toes. Dramatic immediate relief of pain, and healing of gangrenous patches, following upon peri-arterial sympathectomy of the femoral artery in the right lower limb. Recrudescence of local symptoms after some months, and again dramatic relief of pain, and substantial local improvement, following upon right lumbar ganglionectomy and trunk resection.*

Miss M., a young middle-aged woman, consulted me on 1st June, 1928, on the recommendation of Dr. MacDonald, of Girvan. She had suffered for many years from a chronic lymphatic œdema of the left upper extremity, with recurring acute cutaneous pyogenic lesions of a pustular character affecting this limb, and varying febrile disturbance. She also suffered, from time to time, from somewhat acute inflammatory lesions of the toes and nail-beds of the right foot, and all the toes were the seat of superficial ulcers and little local areas of gangrene. The condition subsided from time to time to a partial extent, but never cleared up completely. There was constant pain, in both feet, and in the calves of the legs, but always more severe in the right foot. The pain was widely distributed over the dorsal and plantar aspects of the foot and toes. Ulcers had occasionally formed also on the calf of the leg. The pain resembled, in its intensity, and in its resistance to ordinary remedies, the pain of a severe causalgia.

The patient had had a long history of surgical illnesses. In 1909, a very extensive excision of glands was carried out on both sides of the neck. Again, in 1910, additional glands were removed, and in 1913 a large mass

of glands was removed from the left axilla. These operations were performed by Sir Kennedy Dalziel. It is presumed that the glands were tuberculous. In 1918, the left wrist and forearm became swollen and painful, and from that period the swelling gradually increased, until ultimately the limb acquired the appearance which it now has—like an elephantiasis. In January, 1920, when returning from a walk, the patient developed extreme pain in the left foot, and this continued for some weeks very severe. A week later, acute pain was felt in the left elbow, and, in addition to an aggravation of the swelling, an acute pyogenic cutaneous reaction developed all over the limb, and spread over the surface of the left side of the chest. This attack was associated with marked febrile disturbance, and continued for several days. Further surgical treatment of the left axilla had to be carried out in June, 1920, but the condition of the left upper limb did not improve, and the left foot continued to give trouble. There was pain in the heel, and there were superficial septic foci on all the toes. In 1925, there was an abscess in the region of the left heel, and many pyogenic lesions were present on the left foot, which took long to clear up. The right foot became seriously involved in the spring of 1926. It became numb. The toes became septic, and severe pain developed, particularly about the ankle and toes. In August, 1926, she consulted Dr. Ness, and was for some months under treatment in a nursing home, when various methods of treatment were employed, including violet rays, but without much success. From that time until June, 1928, there had been little improvement, and the patient's life latterly became almost unendurable. Severe pain in the toes of the right foot, and extending up to the ankle, prevented rest or sleep. The numerous ulcerated patches on the toes were exceedingly sensitive, and latterly the patient was almost completely incapacitated. She hardly ever rested at all. She could not bear a shoe on the right foot, and even the simplest dressing, or changes of dressings, were almost unbearable. She sat up in bed, or on a couch, grasping the calf of the right leg firmly in both hands, and feared any sort of manipulation or movement. Various remedies, such as lactate of calcium and thyroid tabloids, were tried, without effect. As a child she had suffered from chilblains, and occasionally ulcers of both legs, round the back of the ankles.

Her condition, when I saw her in June, 1928, was pretty much as has just been described. There was the great brawny swelling of the left forearm and arm, which had just partially recovered from one of the frequent superficial inflammatory reactions. The right foot, ankle, and toes were swollen, and marked by a superficial vascular injection. All the toes were swollen and inflamed. The tip of the fourth was definitely gangrenous, and the others were superficially ulcerated. They were all exceedingly tender to touch, and there was much subjective and objective pain. No pulse could be felt in the following arteries :—the dorsalis pedis, the posterior tibial, and the popliteal in both lower limbs, the radial and ulnar in both upper limbs.

It was obvious that, whatever the explanation of the recurring inflammatory attacks, the patient was suffering from some generalized obliterative arterial condition, and the pain element in the case was so severe as to warrant the adoption of any form of surgical treatment which might offer some degree of relief. A peri-arterial sympathectomy of the right femoral artery was suggested, and agreed to.

On 3rd September, 1928, accordingly, the femoral artery was exposed at the apex of Scarpa's triangle, with a view to carrying out this operation.

The artery was found completely blocked, and converted into a solid cord. The adventitia was, however, stripped for a distance of 2 cms., and alcohol was injected between the coats above and below. Thereafter, the common femoral artery was exposed just below Poupart's ligament, and the same operation was repeated there. The common femoral seemed to be narrowed, but was not thrombosed. After the wounds in the thigh had been sutured and covered up, attention was given to the toes; loose skin and débris about the ulcerated patches were removed; loose nails were taken away, as well as the gangrenous tip of the fourth toe.

The immediate result of the operation was almost dramatic. Whereas, for weeks before, the patient had hardly ever got any rest, and was continuously in pain, she slept soundly all night after the operation, and for many weeks there was no recurrence of pain at all. Further, within a day or two, all the toes had healed except the tip of the toe which had been gangrenous. This healed more slowly. The patient went home at the end of about three weeks, with all but the fourth toe quite healed. She was able to walk about with fair comfort.

In November, 1928, however, she returned to the nursing home, because the fourth toe continued to give trouble and refused to heal. It was accordingly amputated through the metatarsal-phalangeal joint. There had been a certain amount of recurrence of pains in the other toes, but there had been so far no fresh ulceration. She was under treatment in the nursing home for about a couple of months, being dismissed on 2nd January, 1929.

In July, 1929, she was again seen. Her general condition was satisfactory. She had had further trouble in the left upper limb, but the toes were well. She had, however, developed a small ulcer on the back of the right calf. During the year that followed, the patient was able to get about with fair freedom, but the ulcer of the right calf healed very slowly, and broke down quite a number of times, and pain in the left foot and calf had again been experienced, as well as some recurrence of pain in the right foot.

About the middle of June, 1930, the patient came to see me again. There had developed a new condition—a large swelling in the right axilla, extending down to the outer and upper quadrant of the right breast. This had appeared about the end of May. At first I was uncertain whether the swelling actually involved the breast primarily, or whether it had an axillary origin and no primary connexion with the breast. On the 20th June, 1930, the swelling, which by this time had become distinctly fluctuant, was operated upon. A large deep-seated abscess, obviously of glandular origin, was evacuated, and a large mass of glands was removed from the axilla. They were found to be tuberculous. The axillary condition healed up quickly, and gave no further trouble.

The condition of the toes of the right foot, and the intractable ulcer on the back of the calf, however, indicated the necessity for further surgical treatment, all the more that pain in the right leg, foot, and toes had become considerably aggravated, and there was marked *rubor* of the toes and dorsum of the foot. It was resolved to try the effect of a right lumbar ganglionectomy. This operation was accordingly carried out on 8th July, 1930. The operation was not specially difficult, but it is worthy of mention that, at first, a fine cord, with small nodular enlargements in its course, and occupying a position corresponding closely to that of the sympathetic cord, was taken for the latter, and was removed. Fortunately, however, the error was at once

recognized, and the sympathetic trunk was then sought for, found without difficulty, and removed. This possible source of error in the ganglionectomy operation is worth recording.

There followed the usual vaso-dilatory reaction in the leg and foot, though it was by no means so striking as in the other cases which have been described; but, both subjectively and objectively, the right foot and toes became warmer than those on the corresponding limb, and this increased vascularity and improved temperature were maintained. The ulcer on the back of the calf, however, though it was grafted at the same time with fresh skin, was slow in healing, and the patient was not dismissed before two months had elapsed. She has not since been seen, but on the 1st November, when she reported herself to be pretty well so far as the right foot was concerned, she was beginning to have a little trouble again with the left foot. What the ultimate issue in this case is going to be, it is difficult to forecast; but, at any rate, both after the original peri-arterial sympathectomy, and after the later ganglionectomy, there followed—especially in the case of the former—a vaso-dilatory reaction and associated banishment of pain of a most dramatic character.

GANGLIONECTOMY IN THE TREATMENT OF CERTAIN CHRONIC JOINT CONDITIONS.

As regards this particular application of the ganglion operation, I can say little from personal experience; but Adson and his co-workers report a now considerable number of cases in which a substantial degree of benefit has been obtained. What the exact rationale of the therapeutic process may be cannot be stated with any certainty. It is possible that the physiological reaction which produces the therapeutic effect may be, at least in part, of a nervous character; but the simplest explanation would seem to be that the augmentation of the blood supply to the limb plays the chief part in determining the remedial effect. This is rendered all the more probable by the observation that the cases which do not respond to the treatment are those in which the protein shock test fails to produce a favourable *vaso-motor* or *vascular index*. Much further investigation will be necessary before any definite finding can be arrived at on the subject. All that can meantime be said is that, in a certain number of carefully selected cases of chronic joint disease, results of a somewhat remarkable character have already been achieved by means of ganglionectomy.

A paper published jointly, in September last, by Hench, Henderson, Rowntree, and Adson, of the Mayo Clinic,[59] may

be consulted for the latest and most authoritative information on this subject.

GANGLIONECTOMY, OR SECTION OF THE SYMPATHETIC TRUNK, IN THE TREATMENT OF RETINIS PIGMENTOSA.

Within the last year, an attempt has been made by Royle to apply the knowledge gained, regarding the effects of sympathectomy upon the ocular blood-vessels, to the treatment of that intractable condition, retinitis pigmentosa. Whatever the actual pathology of this condition may be, it is one in which, along with the actual degeneration of retinal tissue, and the accumulation of pigment, there is an apparent constriction of the retinal vessels. The ultimate clinical effects of the textural and vascular changes in the retina are well known, and the condition inevitably leads to a great and increasing loss of vision, and ultimately to complete blindness.

It occurred to Royle that the permanent vaso-dilatation of the ocular vessels produced by division of the sympathetic supply of the eye—as in the original Claude Bernard experiment—would so alter the conditions underlying the disease that some substantial benefit might be obtained. Accordingly, he tested the matter experimentally in a number of patients. A preliminary report upon the results in five cases was presented by him to the Surgical Section, at the annual meeting of the British Medical Association at Winnipeg, in August, 1930.[60]

In one of the five cases, operated upon on 29th May, 1930, there had been, at the time of report, already a substantial improvement in vision. In the other four cases, although there had been some improvement in the visual acuity, and some enlargement of the fields of vision, there had not yet been sufficient time to permit of any reliable estimate of the ultimate results.

The operation which Royle employed was simple section of the thoracic sympathetic trunk, about the level of the second thoracic ganglion.

It would seem that a similar effect might be obtained by an operation higher up—in the neck. All that would appear to be necessary is the division of the sympathetic trunk at some level in the neck, and it would hardly seem justifiable

to employ the more difficult procedure of thoracic section, when the sympathetic trunk higher up in the neck can be so much more easily and readily exposed. The actual procedure of the original Claude Bernard experiment might quite well be followed. This is, of course, a purely theoretical suggestion, for I have not, up to the present, put the matter to the test.

RESECTION OF SYMPATHETIC NERVES IN THE TREATMENT OF TWO OTHER CONDITIONS.

Though not strictly germane to the main theme of this paper, reference may appropriately be made here to recent work which has been done along similar lines, in the effort to find a remedy for two troublesome and intractable conditions, which have so far defied other forms of treatment.

There is the additional justification, and to myself the additional pleasure, in making this reference, in virtue of the fact that my former student and assistant, Mr. James R. Learmonth—now on the staff of the Mayo Clinic—has been closely concerned with the work in both cases. The two conditions which have thus been brought within the sphere of the Surgery of the Sympathetic System are : (1) Idiopathic dilatation of the colon (Hirschsprung's disease), and certain types of constipation ; (2) the condition known as " Cord Bladder."

THE SURGICAL TREATMENT OF HIRSCHSPRUNG'S DISEASE AND CERTAIN TYPES OF CONSTIPATION BY SECTION OF THE SYMPATHETIC NERVES OF THE DISTAL PART OF THE COLON AND RECTUM.

Hitherto the surgical treatment of idiopathic dilatation of the colon and allied conditions has been very unsatisfactory —involving such procedures as intestinal anastomosis ; resection of a portion, or even the whole, of the large bowel ; colopexy ; ileo-sigmoidostomy, with or without a preliminary artificial anus ; or ileo-sigmoidostomy plus resection of the affected gut (Finney).

Within the last few years, however, Wade, Judd, Adson, and others have attempted to treat these conditions by ramisectomy, or by lumbar sympathetic ganglionectomy, with

results, in a number of cases, which have been generally favourable, though not uniformly satisfactory.[61, 62, 63]

More recently still, Rankin and Learmonth (both of the Mayo Clinic) have recommended a novel procedure. Recognizing that interruption of the sympathetic supply to the large bowel has proved beneficial in a certain proportion of cases of idiopathic dilatation of the colon, as proved by the reported results, they set themselves to study more closely the anatomy and physiology of the nerves passing to the distal portion of the large bowel, in the hope that they might be able so to simplify the operative procedure, that only the actual nerve fibres immediately concerned should be interrupted. As the result of a series of very carefully conducted investigations, they have been able to accomplish the simplification of the procedure which they sought, and yet to ensure the interruption of all the fibres reaching the distal part of the colon through the thoracico-lumbar sympathetic outflow. The results of their investigations, and the new procedure devised by them, are carefully described and illustrated in the paper which they contributed to the Jubilee Meeting of the American Surgical Association at Philadelphia, in May, 1930.[64]

RATIONALE OF THE RANKIN-LEARMONTH OPERATION.

The authors are of the opinion that probably neuro-muscular dysfunction is the root cause of idiopathic dilatation of the colon. They point out that the colon is dilated most markedly in its distal part, and that dilatation extends frequently as far as the internal sphincter; but that the muscular coat, though hypertrophied, is unable to transmit the intestinal contents. They suggest that there are, therefore, three possible directions of relief :—(1) Diminution of the dilatation of the colon; (2) relief of its motor function by cutting out inhibiting fibres; and (3) removal of opposition to the intestinal onflow offered by the contracted internal sphincter.

These three purposes, they believe, are achieved by the operation which they have devised—as to (1) and (2), by division of the inferior mesenteric sympathetic nerves, which are responsible for the maintenance of a continuous inhibitory influence on the tonus of this portion of the bowel; and as to

(3) by cutting out the motor control of the sphincter, by section of the pre-sacral nerve.

The *inferior mesenteric nerves* are derived from the inter-mesenteric plexuses, from semi-lunar ganglia and cœliac plexus above, from the front of the aorta, and from the renal plexus. They receive branches also from the first and second lumbar ganglia. The fibres which form the inter-mesenteric plexuses are thus derived from two sources—their original fibres from that part of the abdominal sympathetic system connected with the thoracic splanchnic nerves, and the subsidiary fibres from the lumbar ganglia or trunks.

The *pre-sacral nerve* is formed by two lateral roots from the lumbar ganglionic chain on each side, and a middle root from the internal part of the inter-mesenteric plexus—at the level of the first sacral vertebra divided into two hypogastric nerves which join the hypogastric ganglia. From these, post-ganglionic fibres pass to the pelvic viscera, including the lower rectum and internal sphincter.

TECHNIQUE OF THE RANKIN-LEARMONTH OPERATION.

The abdomen is opened through a long para-median incision centred on the umbilicus. A self-retaining retractor is employed, and the Trendelenburg position is adopted from the first. The small bowel is packed upward and to the right, in order to permit of free exposure, and to allow the root of the mesentery to be drawn upwards. The sigmoid colon is displaced to the left and slightly downwards, to expose the bifurcation of the aorta. The promontory of the sacrum is identified, and in most cases the strands of the pre-sacral nerve can be seen through the posterior parietal peritoneum as they descend in the middle line. The peritoneum is picked up in the middle line, and is incised vertically from the sacral promontory to the origin of the inferior mesenteric artery (Fig. 22).

The two edges of the incision are raised, and displaced to either side. The strands of the pre-sacral nerve are not adherent to the membrane, and they are easily separable from the great vessels. The pre-sacral nerve is divided below at the right border of the left common iliac vein, and it is advised that a ligature should be placed on its distal end, on account of a small artery which accompanies it. The proximal end of the

divided pre-sacral nerve is raised by gentle dissection, and the branches reaching it from the fourth lumbar ganglia are divided on each side. Similarly, the branches from the third lumbar ganglia immediately below the bifurcation of the aorta are divided. When the nerve has been raised still further, its

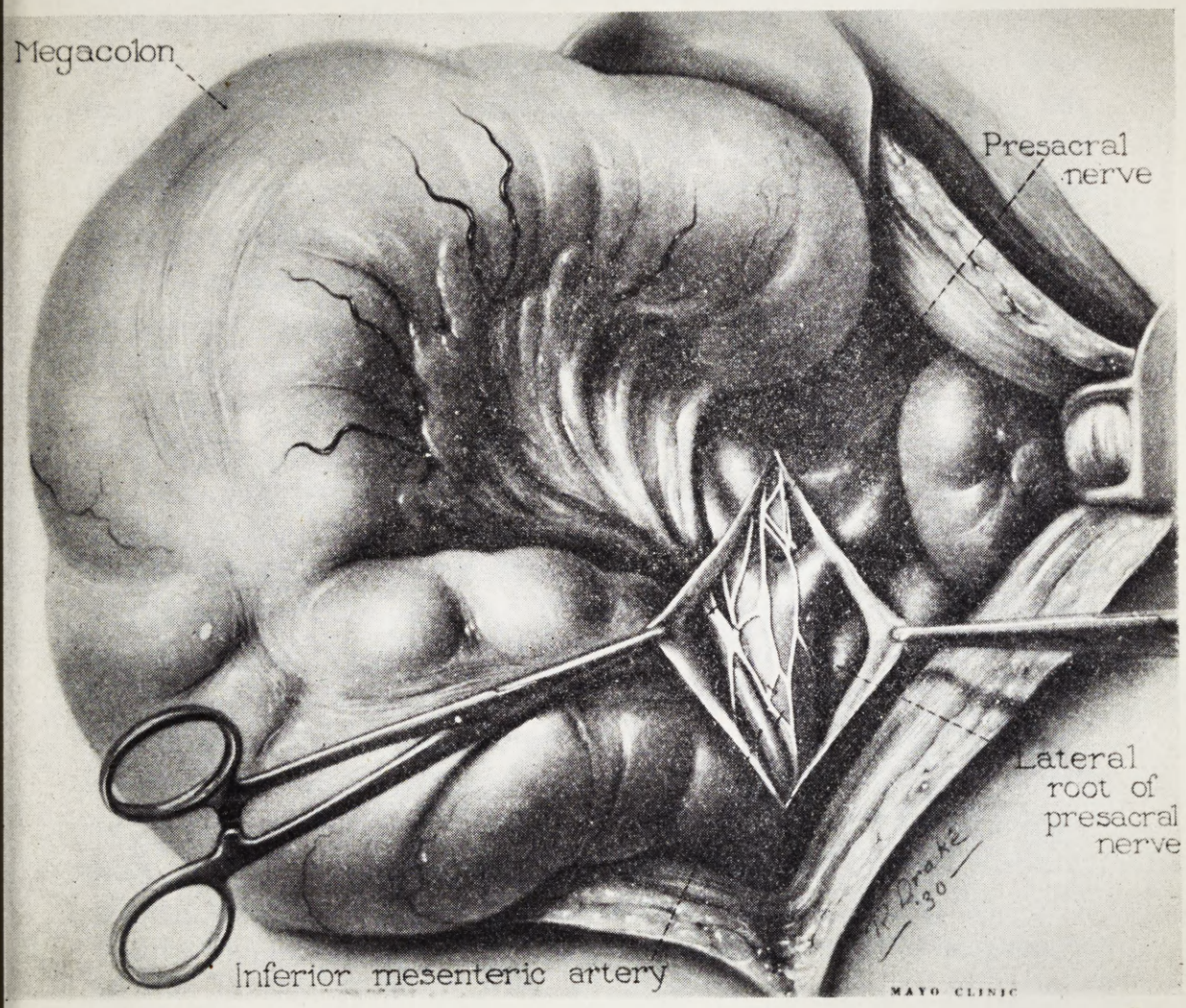

RANKIN-LEARMONTH OPERATION.

FIG. 22.—Field of operation, and incision through the posterior parietal peritoneum. *Note.*—(1) The sigmoid displaced to the left, and the bifurcation of aorta exposed by retraction of the peritoneal edges; (2) The pre-sacral nerve, and the inferior mesenteric nerves. (By courtesy of Drs. Rankin and Learmonth, and the Editors and Publishers of the *Annals of Surgery.*)

lateral roots, formed by union of branches from the first and second lumbar ganglia, are severed, the middle root, however, being temporarily preserved if possible, to be used as a guide to the inter-mesenteric plexus. The trunk of the inferior mesenteric artery is now identified, and, by tracing the middle

root of the pre-sacral nerve upwards, the operator reaches the two large principal roots of the inferior mesenteric plexus (from the inter-mesenteric plexus), one on each side of the vessel, and joining it 1·5 cms. below its origin.

The authors advise that, if the middle root of the pre-sacral nerve cannot be used as a guide, the main trunks of the inferior mesenteric plexus will be found at the positions of 5 o'clock and 7 o'clock, with reference to the origin of the artery. They are large and easily isolated. About 2·5 cms. of each are resected, and if any ganglionic mass is present on either, it is included in the resected portion. Any subsidiary peri-arterial strands are divided. If the manipulation is carefully carried out, there should be no bleeding of any consequence. The incision in the posterior peritoneum is closed by a continuous suture of catgut, and the abdomen is closed in the usual manner. The operation, as described, may seem a somewhat formidable one, but, in fact, it is very simple, and, in suitable cases, can be carried out within a very few minutes.

In the paper by Rankin and Learmonth, there are described two cases, one a case of actual Hirschsprung's disease, in a young man of 17 years, and the other a case which the writers regarded as a rectal type of obstipation, in a young woman of 23 years. In both cases, the operative procedure gave a satisfactory result, though in the second case it seemed probable that a long course of after-treatment might be necessary to so re-educate the rectal musculature that it might be expected to contract in response to the appropriate stimulus. This is only what one would expect, because, in cases of rectal obstipation of considerable standing, one has to deal with a distended bowel, in which the muscular coat is atonic, and in which there is no hypertrophy, but rather atrophy, of the musculature. In typical cases of Hirschsprung's disease, on the other hand, more immediate benefit may be looked for, seeing that, as the authors put it, " the hypertrophied musculature of the colon is immediately available for effective peristalsis."

I had the pleasure of seeing Learmonth do this operation, by invitation, in Frazier's Clinic in Philadelphia. The patient was a young boy with typical Hirschsprung's disease, and the procedure in this case seemed very simple, and was easily carried out. Everything worked out satisfactorily, and the operation did not occupy very long in its execution. I have

heard since from Learmonth that the immediate functional result was favourable, and that the ultimate result promised to be equally satisfactory. Further, in a letter from Learmonth, of date 22nd November, 1930, I have learned that, up to that time, he had operated on 6 cases in all—3 for Hirschsprung's disease and 3 for dyschezia. His opinion remains favourable.

I have carried out the operation in only one case, and with a result which gives considerable promise, though the case was primarily a much less favourable one than any of those which have been referred to. The following is a summary of the case in question :—

CASE XIII.—*Case of Hirschsprung's disease or rectal obstipation (dyschezia) in a young female. Chronic partial obstruction, and fæcal impaction in the large bowel, ending in complete obstruction. Emergency laparotomy, for relief of obstruction. Sigmoidostomy, followed by relief of obstruction and temporary improvement in general condition. Recurrence of colon block. Treated ultimately by resection of the sympathetic nerves to the distal part of the colon and rectum (inferior mesenteric and pre-sacral—operation of Rankin and Learmonth). Satisfactory result. Result after six months. (Patient exhibited at meeting.)*

Miss C., aged 20, was admitted to my ward in the Western Infirmary on the 9th November, 1929, acutely ill, with extreme distension of the abdomen and persistent sickness and vomiting. There was a history of long-continued difficulty with the bowels, but the more acute symptoms had developed only a few hours before admission to hospital. The whole lower abdomen was tender to palpation, particularly in the region of the umbilicus. There was no palpable localized tumour, but general rigidity and marked tympanites were present.

The patient was obviously very ill, and a laparotomy was performed somewhat hurriedly by one of my assistants (Mr. McGregor Robertson). The abdomen was opened by right para-median incision. The whole large bowel was found enormously dilated, and all that it was possible to do at the time was to make an artificial anus. This was done—so it was thought—at the cæcum. Substantial relief was at once obtained through a Paul's tube. It was thought at the time that a cæcostomy had been performed, and indeed this was the view which obtained until July, 1930, when the Rankin-Learmonth operation was carried out. It was then found that the sigmoid, and not the cæcum, had been opened.

The immediate result, as has been said, was satisfactory, and, both by colostomy tube and by repeated enemata, efficient evacuation of the bowel was obtained, so that ultimately the abdomen was reduced within normal limits. The case was recognized, however, as akin to the Hirschsprung type

of condition, and by internal medication and systematic enemata an effort was made to improve the peristaltic balance, and keep the bowel acting properly.

On the 30th December, 1929, the anal sphincter was paralysed by stretching, under a general anæsthetic, and this was repeated on 31st January, 1930. Sphincter spasm was well marked, and even under deep anæsthesia it did not readily give way.

The patient was dismissed on 6th January, 1930, but returned on 30th January for further stretching of the sphincter. She was re-admitted on 13th June, complaining of recurring pain in the right side of the abdomen, accompanied by sickness and vomiting after almost every meal. The patient had returned to work after her dismissal from hospital, and remained apparently in good health for about a month. She then noticed that the abdomen had again become distended, and she had repeated attacks of sickness and vomiting. She lost considerable weight, and, two weeks before her re-admission, constipation became extreme, and pain in the right abdomen developed. When she was admitted, the abdomen was greatly distended, and the whole right abdomen was rigid. The umbilical region, and the region of the right iliac fossa, were very tender to palpation. Obstruction of the bowel was not absolute, but it required a whole succession of enemata to give real relief, though each successive enema produced a large fæcal evacuation. There had been, obviously, enormous distension of the whole large bowel.

A complete *x*-ray examination was carried out, both by barium meal and by barium enema. So far as the upper part of the gastro-intestinal tract was concerned, no abnormality was disclosed after the barium meal, but the barium enema disclosed an enormous dilatation of the lower bowel, particularly of the sigmoid. Seven pints of the enema were easily retained, and apparently much more could have been introduced without causing any particular discomfort. The case was regarded, therefore, as of the type of Hirschsprung's disease. It was decided to carry out the Rankin-Learmonth operation.

On 16th July, 1930, under a general anæsthetic (chloroform and ether), this operation was carried out. The abdomen was opened by left paramedian incision. The enormously distended sigmoid was found closely adherent to the anterior abdominal wall over a considerable area, and its separation was a very laborious process. In the course of this separation, the previously existing stoma attachment to the anterior wall had to be cut through, and was at once closed. (*Note.*—As indicated above, the supposed cæcostomy was really a sigmoidostomy.)

There was also extensive adhesion between the distended sigmoid and the pelvic viscera, and the pelvis was filled out by an enormously distended pelvic colon packed with inspissated fæces. (*Note.*—This, in spite of repeated enemata given prior to operation, with the special object of clearing the lower bowel.)

The exposure of the aorta bifurcation and the root of the inferior mesenteric artery was rendered extraordinarily difficult by reason of this extreme retroperitoneal dilatation and extension downwards of the sigmoid and descending colon, and, for the same reason, exposure and recognition of the pre-sacral nerve presented considerable difficulty. Ultimately, however, the inferior

mesenteric artery was located, and the appropriate sympathetic trunk related to it was defined and excised, along with the related pre-sacral nerve. The exact extent of both elements (inferior mesenteric and pre-sacral) which was excised could only be roughly judged, because of the difficulties above mentioned. It was noted that the aorta and iliac vessels seemed to be displaced somewhat upwards, and to be rather ill-developed. The retro-peritoneal wound was sutured, and the abdominal wall was closed in layers. The operation was, indeed, a very difficult one by reason (1) of the extensive sigmoidostomy attachment to the anterior wall; and (2) of the extensive retro-peritoneal intestinal pouch packed with fæcal matter.

The immediate after-result was satisfactory. The patient reacted well to the somewhat prolonged operation, and gave very little trouble after the first 24 hours. She was dismissed from hospital on 16th August, 1930. It was found possible to keep the bowels acting fairly satisfactorily, by means of Alophen pills and liquid paraffin, with an occasional enema. She was seen again on 10th September, when there was some fæcal accumulation in the lower bowel, and it was arranged that she should attend hospital twice a week for the purpose of having an efficiently administered enema.

At this date, 23rd January, 1931, the patient's general condition is satisfactory. She looks well, and feels well, but she still requires to have the lower bowel systematically and regularly unloaded by enemata; and, at the same time, peristalsis requires to be encouraged by administration of tincture of nux vomica, or similar drugs. It is probable that such simple treatment will be necessary for a long time, in view of the extreme dilatation, and almost complete abolition of tonus, of the large bowel, and the entire absence of any muscular hypertrophy.

THE SURGICAL TREATMENT OF "CORD BLADDER" BY RESECTION OF THE PRE-SACRAL NERVE.

In certain cases of defective, and perhaps painful, micturition, associated with myelitis of the sacral cord, and certain allied lesions affecting the lower portion of the para-sympathetic system, the distressing condition known as "Cord Bladder" occurs, and up till recently no effective means of relief has been discovered.

Learmonth and Braasch, of the Mayo Clinic, however, have made a fresh study of the nervous control of the act of micturition, and, as the result of their study, they have suggested that, in a certain group of cases at any rate, a substantial degree of relief may be obtained by resection of the pre-sacral nerve. In a paper published in *Surgery, Gynecology, and Obstetrics*, in October, 1930,[65] they give an account of their study, and also describe a case of cord bladder which they had dealt with in this manner, with satisfactory result.

RATIONALE OF THE PROCEDURE.

The musculature of the bladder is controlled by a rich ganglionated network of nerves distributed over its surface, and the intricate reflex controlling the act of micturition depends on the correct balance of nerve influences passing from three sources :—(1) From the sacral autonomic system, by the *pelvic nerves;* (2) from the thoracico-lumbar outflow of the sympathetic system, by the *hypogastric nerves;* and (3) from somatic centres in the sacral part of the spinal cord, by the *pudic nerves.* Each of these three pathways contains both afferent and efferent fibres.

The fibres of the *pelvic nerves* pass directly to the bladder to synapse with nerve cells in the general surface ganglionic network, and, before reaching this plexus, they traverse the hypogastric ganglia. The fibres of the pelvic nerves are pre-ganglionic, and therefore medullated, and they arise from the anterior primary divisions of the 2nd and 3rd, or 3rd and 4th sacral nerves.

The pre-ganglionic fibres of the *hypogastric nerves,* on the other hand, form their synapses in the hypogastric ganglia, from which new post-ganglionic fibres pass to the bladder through the vesical branches of the ganglia (Fig. 23).

The deep perineal branch of the *pudic nerve*—from the 3rd and 4th sacral segments of the cord—supplies motor fibres to the compressor urethræ muscle, and sensory fibres to the posterior urethra and internal sphincter.

The *purpose of the suggested operation, namely, division of the pre-sacral nerve,* is to annul inhibitory influences carried to the bladder by it. Resection of the pre-sacral nerve, in fact, means interruption of the thoracico-lumbar pathway along the hypogastric nerves.

The authors believe that the success of the operation in appropriate cases depends on the fact that the hypogastric nerves, in man, carry inhibitory impulses to the bladder, which may be sufficient to prevent the complete emptying of the bladder when the hypogastric nerves are intact, even although the pelvic nerves are injured. Further, they believe that the outpouring of inhibitory influences by way of the hypogastric

nerves is probably independent of the outpouring of motor impulses to the internal sphincter in the region of the trigone.

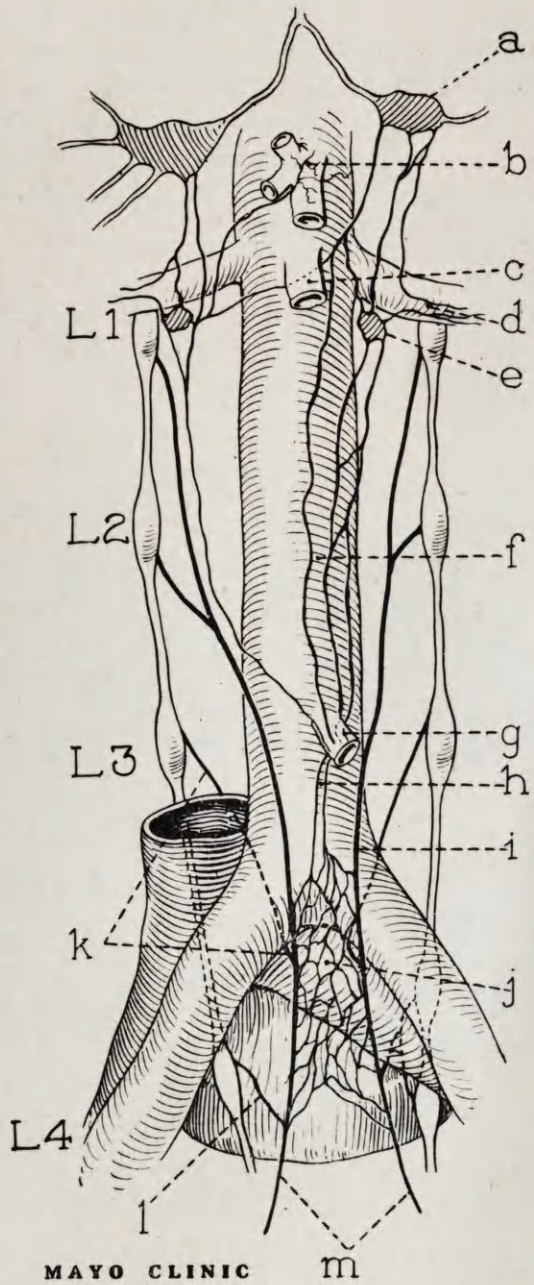

FIG. 23.—Connections of the pre-sacral nerve:—(*a*) Semilunar ganglion; (*b*) cœliac plexus; (*c*) superior mesenteric artery; (*d*) renal plexus; (*e*) renal ganglion; (*f*) intermesenteric plexus; (*g*) inferior mesenteric artery; (*h*) middle root of pre-sacral nerve; (*i*) left lateral root of pre-sacral nerve; (*j*) pre-sacral nerve; (*k*) branch from third lumbar ganglion; (*l*) branch from fourth lumbar ganglion; and (*m*) hypogastric nerves (after Laux). (By courtesy of Drs. Learmonth and Braasch, and the Editors of *Surgery, Gynecology and Obstetrics.*)

They emphasize their view that in selecting cases for such an operation there are certain definite requirements for success;

"The clinical data must point to reduction of the function of the pelvic nerves (aptly called by Rose the ' emptying ' nerves of the bladder), while the hypogastric nerves are uninjured; in other words, the balance of vesical innervation is disturbed, and injured pelvic nerves are handicapped in their task by the ' brake ' action of intact hypogastric nerves. As a corollary, there must not be total paralysis of the pelvic nerves, in order that, after removal of the brake, the residual expulsive power of the detrusor muscle may be more equal to emptying the bladder. Again, the patient must be continent, through the action of the compressor urethræ muscle, for the hypogastric nerves are the motor nerves to the internal sphincter. Finally, there must be satisfactory renal function."

In the case described by the writers, very substantial relief had been obtained, and it had been found possible almost entirely to eliminate residual urine.

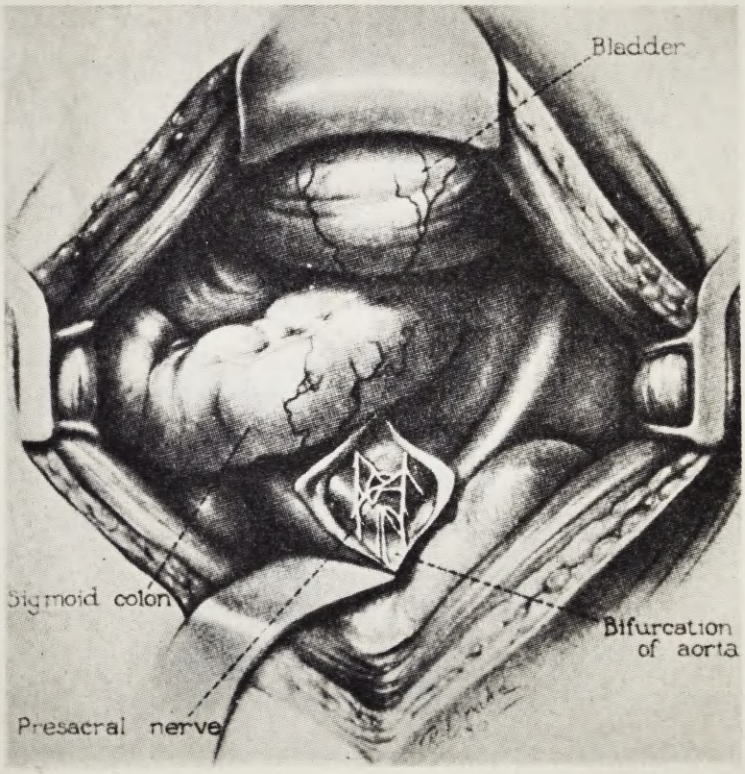

LEARMONTH-BRAASCH OPERATION.

FIG. 24.—Incision through the posterior parietal peritoneum, over the fifth lumbar vertebra, in the middle line, exposing the pre-sacral nerve. Note the plexiform arrangement of the nerve—this arrangement having been found by the authors in 80 per cent of cases. (By courtesy of Drs. Learmonth and Braasch, and the Editors of *Surgery, Gynecology and Obstetrics.*)

TECHNIQUE OF THE OPERATION.

The abdomen is opened through a median, or paramedian, incision. The cæcum and small intestine are packed upward

and to the right, and the sigmoid is drawn firmly over to the left. The peritoneum over the fifth lumbar vertebra is opened in the middle line, and this incision can be extended upwards and downwards for several centimetres, as may be necessary (Fig. 24). The pre-sacral nerve is isolated, first at its lower end, and the branches joining it from the fourth lumbar ganglia are divided. The nerve is cut across just beyond the origin of the two hypogastric nerves, and ligatures are placed on the distal ends of the divided nerve to control bleeding from the vasa nervorum. The proximal end of the nerve is drawn upwards, and branches joining it from the third lumbar ganglia are then put on the stretch, and are easily recognized and divided. Finally, the lateral roots are severed on each side. The segment of nerve removed measures, say, 5 cms. The wound in the posterior peritoneum is then closed, and the abdominal incision is sutured in layers.

In a letter dated 22nd November, 1930, Learmonth tells me that he has now carried out this operation eleven times, three times for paralysis, and eight times for painful types of cystitis and for inoperable carcinoma. He believes that there is a very definite future for the operation, although the indications will probably require revision, as more is learned about them.

AFTER-TREATMENT.

One can well imagine that, in cases submitted to this operation, the after-treatment will be of great importance, and probably of some difficulty.

In the case described by the writers, the bladder was allowed to drain continuously for some days by means of an indwelling catheter, and during this period an attempt was made to stimulate the bladder musculature by intra-muscular administration of acecholine—a proprietary preparation which is supposed to be a specific stimulant of those structures innervated by the sacral autonomic outflow.

Later, intermittent catheterization was resorted to, but it was some considerable time before substantial improvement was obtained. Seven months after the operation, however, the patient reported that he was able to urinate easily in any position, and that repeatedly catherization had shown no residual urine.

ACKNOWLEDGMENTS.

I wish to thank my friend, Dr. René Leriche, Professor of Clinical Surgery in the University of Strasbourg, for his courtesy in permitting me to use, for the purpose of this paper, the illustrations of his operation of peri-arterial sympathectomy, from his article on the subject in the *Nelson Living Surgery* (Figs. 1 and 2).

I am grateful also to my friend, Mr. Sampson Handley, for permission to reproduce the photographs of the colour drawings from the case of gangrene of the foot described in his "Preliminary Communication" on "The Peri-arterial Injection of Alcohol in the Treatment of Senile Gangrene" in the *Lancet*, 1929 (Fig. 6).

My friend, Dr. Alfred W. Adson, of the Mayo Clinic, deserves my particular gratitude, not only for his ready agreement to the reproduction of the plates in *Surgery, Gynecology and Obstetrics*, May, 1929, illustrating his method of transperitoneal lumbar ganglionectomy, but very specially for permitting me to use, for the purpose of this paper, the fresh illustrations of his new method of approach in the operation of cervico-thoracic ganglionectomy (Figs. 7, 8, 9, 10, 11, 12, 13, 14, 15, 16, 17, 18, 19, 20). I desire to express my deep sense of indebtedness to him.

To Drs. Rankine and Learmonth I am indebted for permission to use the illustration from their article on "The Treatment of Hirschsprung's Disease" in the *Annals of Surgery*, October, 1930 (Fig. 22); and to Drs. Learmonth and Braasch for permission to use two of the illustrations from their article on "Cord Bladder" in *Surgery, Gynecology and Obstetrics*, October, 1930 (Figs. 23 and 24).

I desire, of course, to thank the editors and publishers of *Surgery, Gynecology and Obstetrics*, and of the *Annals of Surgery*, for their agreement to the use of these illustrations. And I would particularly thank Dr. Franklin Martin, the editor of *Surgery, Gynecology and Obstetrics*, for the cordiality with which his consent was given.

To my former student and assistant, Dr. J. R. Learmonth, my special thanks are due, not merely for the use of his illustrations, but for the considerable assistance received from

him with regard to references in the already somewhat voluminous literature on the subject.

I am indebted to Mr. R. M. Buchanan, M.B., presently Hall Fellow attached to my Department, for the admirable colour drawing illustration from the case of Raynaud's disease (Fig. 21).

I must not omit acknowledgment of the valuable assistance which I have received, at all times, from Mr. Andrew J. Hutton, M.B., Senior Assistant in Surgery at this University. I am indebted to him in particular for his report on the series of cases of gangrene treated by peri-arterial sympathectomy, and for the tabular statement with regard to them. It is due to him also to state that Mr. Hutton has assisted me in the great majority of the operations.

Last, but not least, I would like to acknowledge the assistance which has been given me by my secretary, Miss A. M. Kelly, particularly in looking up and verifying references.

REFERENCES.

39 Hunter, J. I., "The influence of the sympathetic nervous system in the genesis of the rigidity of striated muscle in spastic paralysis," *Surg. Gyn. and Obst.*, 1924, vol. xxxix, pp. 721-743.

40 Royle, N. D., "The treatment of spastic paralysis by sympathetic ramisection," *Surg. Gyn. and Obst.*, 1924, vol. xxxix, pp. 701-720.

41 *idem*, *idem.*

42 Adson and Brown, "Treatment of Raynaud's disease by lumbar ramisection and ganglionectomy and perivascular sympathetic neurectomy of the common iliacs," *Journal of Amer. Med. Assoc.*, 1925, vol. lxxxiv, pp. 1908-1910.

43 Leriche, R., "Conditions dependent upon vaso-motor changes in blood-vessels," *Nelson Living Surgery*, vol. iii, pp. 779 and 799.

44 Cannon, Walter B., "The autonomic nervous system : an interpretation," Linacre Lecture, *Lancet*, 24th May, 1930, p. 1109.

45 Royle, N. D., "Sympathetic trunk section : a new operation for Raynaud's disease and spastic paralysis of the upper limb," *Med. Jour. Australia*, 1928, vol. ii, pp. 436-438.

46 Adson and Brown, "The treatment of Raynaud's disease by resection of the upper thoracic and lumbar sympathetic ganglia and trunks," *Surg. Gyn. and Obst.*, May, 1929, p. 594.

47 *idem*, *idem.*

48 Lewis, Sir Thomas, "Experiments relating to the peripheral mechanism involved in spasmodic arrest of the circulation in the fingers; a variety of Raynaud's disease," *Heart*, 1929, vol. xv, No. 1, p. 7.

49 Lewis, Sir Thomas, and Landis, E. M., "Some physiological effects of sympathetic ganglionectomy in the human being, and its effect in a case of Raynaud's malady," *Heart*, 1930, vol. xv, No. 2, p. 151.

[50] Simpson, Brown, and Adson, "Observations on the etiologic mechanism in Raynaud's disease," *Proceedings of the Staff Meetings of the Mayo Clinic*, 15th Oct., 1930, p. 295.

[51] Brown, Allen, and Mahorner, *Thrombo-Angitis Obliterans*, 1928, p. 182.

[52] Adson and Brown, "The treatment of Raynaud's disease by resection of the upper thoracic and lumbar sympathetic ganglia and trunks," *Surg. Gyn. and Obst.*, May, 1929, p. 582.

[53] Winiwarter, Felix, "Ueber eine eigenthümliche Form von Endarteritis und Endophlebitis, mit Gangrän des Fusses," *Arch. f. klin. Chir.*, 1879, Heft xxiii, SS. 202-226.

[54] Weber, F. Parkes, "Arteritis obliterans of the lower extremity, with intermittent claudication ('Angina Cruris'),'' *Lancet*, Jan., 1908, vol. i, p. 152.

[55] Buerger, Leo, "Thrombo-angitis obliterans: a study of the vascular lesions leading to pre-senile spontaneous gangrene," *Amer. Jour. Med. Sc.*, 1908, vol. cxxxvi, pp. 567-580.

[56] Brown, Allen, and Mahorner, *Thrombo-Angitis Obliterans*, 1928, pp. 19-20.

[57] Weber, F. Parkes, "A case of thrombo-angitis obliterans of 22 years' duration," *Lancet*, 4th July, 1925, p. 21.

[58] Horton, V. T., and Dorsey, A. H. E., "Bacteriologic studies in thrombo-angitis obliterans," *Proceedings of the Mayo Clinic*, 19th Nov., 1930, p. 337.

[59] Hench, Henderson, Rowntree, and Adson, "Treatment of chronic 'infectious' arthritis by sympathetic ganglionectomy and trunk resection," *Jour. Lab. and Clin. Med.*, Sept., 1930, vol. xv, No. 12, p. 1247.

[60] Royle, N. D., "The clinical results following the operation of sympathetic ramisection," *British Medical Journal*, 18th Oct., 1930, p. 631.

[61] Wade, R. B., and Royle, N. D., "Operative treatment of Hirschsprung's disease—new method: with explanation of the technique and results of operation," *Med. Jour. Australia*, 29th Jan., 1927, vol. i, pp. 137-141.

[62] Judd, E. S., and Adson, A. W., "Lumbar sympathetic ganglionectomy and ramisectomy for congenital idiopathic dilatation of the colon," *Annals of Surgery*, Sept., 1928, vol. lxxxviii, pp. 479-498.

[63] Wade, R. B., "Left lumbar ramisection in Hirschsprung's disease," *Lancet*, 18th Jan., 1930, vol. ccxviii, pp. 136-137.

[64] Rankin, F. W., and Learmonth, J. R., "Section of the sympathetic nerves of the distal part of the colon and the rectum in the treatment of Hirschsprung's disease and certain types of constipation," *Annals of Surgery*, Oct., 1930, pp. 710-720.

[65] Learmonth, J. R., and Braasch, W. F., "Resection of the presacral nerve in the treatment of cord bladder," *Surg. Gyn. and Obst.*, Oct., 1930, vol. li, pp. 494-499.