

Case for diagnosis. Erythroderma as manifestation of hypereosinophilic syndrome*

Maira Renata Merlotto¹
Delmo Sakabe³

Lucas Oliveira Cantadori²
Hélio Amante Miot¹

DOI: <http://dx.doi.org/10.1590/abd1806-4841.20187419>

CASE REPORT

Patient was a 36-year-old Brazilian male physician of Japanese descent with no comorbidities or atypical signs. Six years previously he presented intermittent erythematous papules on the trunk and face, in addition to pruritus aggravated by heat or alcohol intake. Six months previously he evolved with erythroderma, treated with cyclosporine (3mg/kg/d), hydration, and topical corticosteroids, with partial improvement. On physical examination: erythroderma, facial infiltration, and infiltrated erythematous plaques (mainly cubital and popliteal), xeroderma, thickening of the greater

auricular, fibular, radial, and ulnar nerves with reduced strength in hands (Figure 1). Anatomical pathology of the skin revealed acanthosis, spongiosis, and superficial lymphocytic infiltrate with eosinophils (Figure 2). Complete blood count: eosinophilia 2,812U/ μ L; IgE 1,164 kU/L (ULN 114kU/L), and DHL 596U/L (ULN 225U/L). Ultrasound of the wrists showed thickening of the median nerve with normal morphology of the carpal tunnel. Normal echocardiogram, and abdominal tomography showed periaortic lymph nodes slightly increased in number.

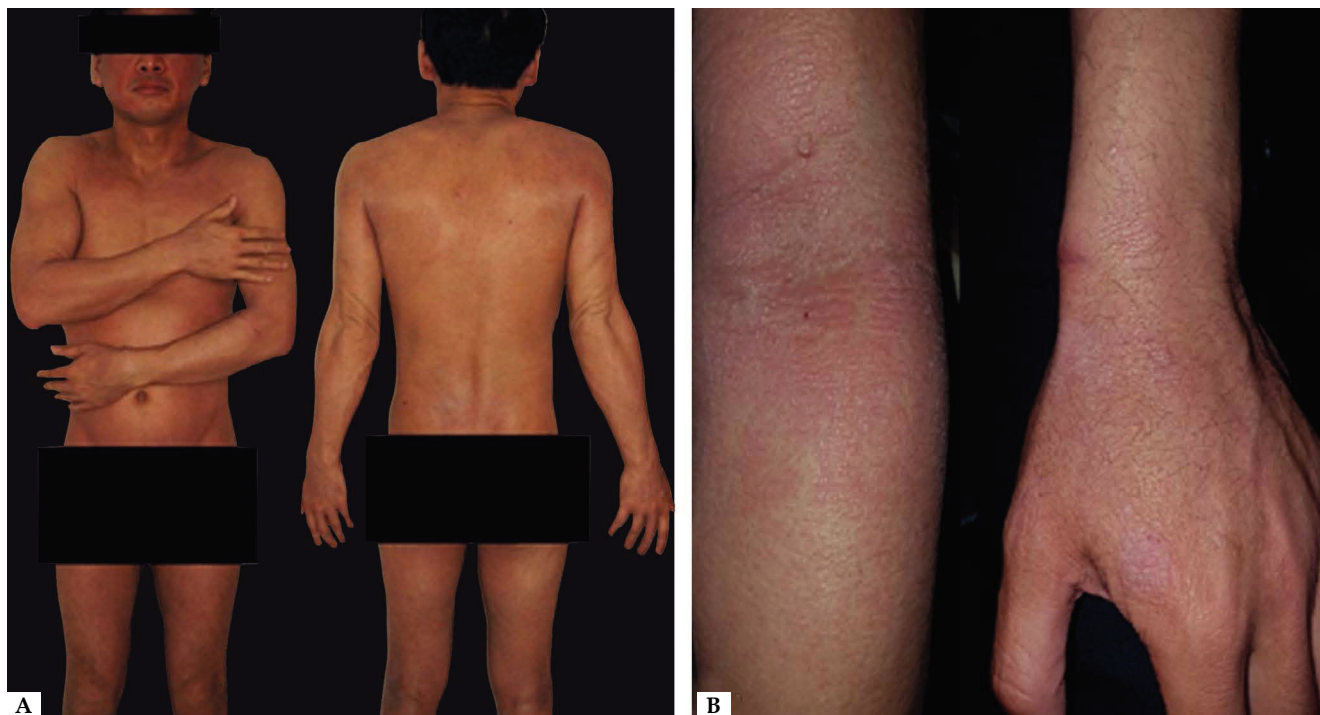


FIGURE 1: A. Erythroderma with facial infiltration. B. Detail of infiltrated plaques on limbs and antecubital region

Received 10 July 2017.

Accepted 07 December 2017.

* Work conducted at Hospital das Clínicas da Faculdade de Medicina de Botucatu, Universidade Estadual Paulista (FMB-Unesp), Botucatu (SP), Brazil.

Financial support: None.

Conflict of interest: None.

¹ Department of Dermatology, Faculdade de Medicina de Botucatu, Universidade Estadual Paulista (FMB-Unesp), Botucatu (SP), Brazil.

² Discipline of Hematology, Department of Clinical Medicine, Faculdade de Medicina de Botucatu, Universidade Estadual Paulista (FMB-Unesp), Botucatu (SP), Brazil.

³ Department of Surgery, Pontifícia Universidade Católica de São Paulo (PUC-Sorocaba), Sorocaba (SP), Brazil.

MAILING ADDRESS:

Hélio Amante Miot

E-mail: heliomiot@fmb.unesp.br

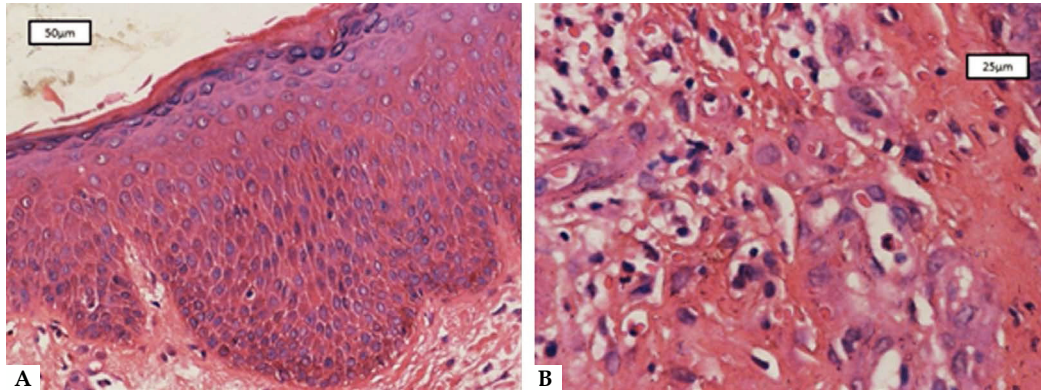


FIGURE 2: Histopathology (Hematoxylin & eosin). **A.** Mild acanthosis and spongiosis (X20). **B.** Edema of the upper dermis and lymphocytic infiltration with eosinophils (X40)

CHART 1: Diagnostic criteria for hypereosinophilic syndrome (HES)		
Original diagnostic criteria, Chusid <i>et al.</i> ¹	Modification to diagnostic criteria for HES by Simon <i>et al.</i> ¹	Comments
1. Peripheral eosinophilia > 1500/ μ L persisting for more than six consecutive months.	Persistent eosinophilia. Arbitrary value of 1500/ μ L is not mandatory	Presence of tissue infiltration with eosinophils leading to tissue damage is more important than setting a laboratory value
2. Rule out secondary causes of hypereosinophilia after extensive clinical workup	Peripheral eosinophilia should be confirmed, but its persistence for more than six months is no longer mandatory	In symptomatic patients with confirmed eosinophilia and organ involvement, proceed to treatment to prevent organ damage; any duration is significant, even less than six months
3. Symptomatic organ involvement secondary to hypereosinophilia	Signs and/or symptoms of organ involvement are not mandatory	At the time of diagnosis, it is very difficult to predict evolution in asymptomatic patients. Some may be asymptomatic at first evaluation and either remain asymptomatic or evolve due to tissue damage or organ involvement

CHART 2: Main features of hypereosinophilic syndrome (HES)			
Subtypes	Characteristics	Treatment	Prognosis
Myeloproliferative (HES-M)	Tyrosine kinase activation by FIP1L1 and PDGFRA gene fusion, eosinophilia due to clonal proliferation of myeloid precursors	Little response to systemic corticosteroids. More response to hydroxyurea, interferon, and chemotherapy - busulfan, chlorambucil, and vincristine. Imatinib is the drug of choice for patients with positive F/P mutation	Survival depends on severity of tissue injury, especially the degree of cardiac involvement. Risk of development of malign myeloproliferative disease
Idiopathic (HES-I)	T-cell polyclonal expansion unregulated production of Th2 cytokines (IL-5 and/or IL-3)	Good response to systemic corticosteroids alone or in combination with hydroxyurea, mepolizumab, interferon- α , or tofacitinib	Chronic, benign condition with indolent clinical course. Occasional development of lymphoma
Lymphocytic/Secondary (HES-L)	Polyclonal expansion of anomalous T-cells (CD3-CD4+) and unregulated production of Th2 cytokines (especially IL-5)	Adequate control with systemic corticosteroids alone or in combination with hydroxyurea, mepolizumab, or tocilizumab	Chronic recurrent. Occasional development of lymphoma

DISCUSSION

Hypereosinophilic syndrome (HES) is characterized by persistently elevated peripheral eosinophil count (> 1,500/ μ L) associated with symptomatic organ involvement, excluding secondary causes of eosinophilia (Chart 1).¹ It is classified as myeloproliferative (HES-M), secondary or reactive (HES-L), and idiopathic (HES-I) (Chart 2)²

HES is a rare disease (5,000 cases/year in the United States of America), potentially fatal, and the organs most frequently in-

involved are skin, lungs, intestine, heart, kidneys, eyes, and peripheral nervous system. The most serious complication is cardiac, which should be investigated in all cases. In adults, the syndrome is more common in males (ratio 9:1), and mean age at onset is 50 years. Investigation of organ involvement and sub-classification are decisive for treatment and prognosis.^{3,4}

Cutaneous manifestations of HES require differential diagnosis with urticaria, pruritus *sine materia*, mycosis fungoides, cutaneous adverse drug reactions, contact dermatitis, and atopic dermatitis. Dermatologists should be alert to pruritic erythematous papules, urticaria, angioedema, dermatographism, oral and genital ulcers, centrifugal annular erythema, acral bullae, and erythroderma. Histopathologic examination of the skin lesion is usually nonspecific, with viable eosinophilic infiltration.^{4,7}

In an endemic country like Brazil, a presentation with polyneuropathy requires ruling out leprosy, which is unlikely in this case because of the pruritus and histology.

In this case, treatment began with prednisone 1mg/kg/day, with important improvement in the skin lesions, eosinophilia (580/ μ L), and pruritus after 30 days. Bone marrow biopsy did not show neoplastic infiltration, FISH cytogenetic test did not reveal deletion or translocation of the FIP1L1 and PDGFRA genes, JAK2 muta-

tion was negative, and immunophenotyping did not show clonal lymphocyte populations. Adjuvant therapy with hydroxyurea was scheduled in conjunction with the Department of Hematology.

The case was classified as HES-I based on the absence of lymphocytic phenotypical abnormalities or genetic alterations. Presence of peripheral neuropathy, absence of atopic signs, and worsening of the clinical picture with alcohol intake were characteristic. High IgE levels, good response to corticosteroid therapy, and low serum tryptase level and eosinophil count < 100,000/ μ L are associated with better prognosis. Therapeutic success in HES-I has been reported with tofacitinib and mepolizumab.^{4,8-10}

Diagnosis of HES is often delayed due to its pleomorphic dermatological manifestations and insidious evolution. It is thus crucial that in all cases of erythroderma, HES should be considered as a differential diagnosis.^{6,7} □

Abstract: Hypereosinophilic syndrome is defined as persistent eosinophilia (>1500/ μ L for more than six months) associated with organ involvement, excluding secondary causes. It is a rare, potentially lethal disease that should be considered in cutaneous conditions associated with hypereosinophilia. We report a case of erythroderma as a manifestation of hypereosinophilic syndrome. A 36-year-old male with no comorbidities presented progressive erythroderma, pruritus, peripheral neuropathy, and eosinophilia in the previous seven months. No mutations were found in FIP1L1/PDGFRA. Patient experienced rapid remission in response to oral prednisone and hydroxyurea. Cutaneous manifestations may be the only evidence of hypereosinophilic syndrome. Genotyping excludes myeloproliferative disease, thereby orienting treatment and prognosis.

Keywords: Eosinophilia; Polyneuropathies; Dermatitis, Exfoliative


REFERENCES

- Simon HU, Rothenberg ME, Bochner BS, Weller PF, Wardlaw AJ, Wechsler ME, et al. Refining the definition of hypereosinophilic syndrome. *J Allergy Clin Immunol*. 2010;126:45-9.
- Valent P, Klion AD, Horny HP, Roufosse F, Gotlib J, Weller PF, et al. Contemporary consensus proposal on criteria and classification of eosinophilic disorders and related syndromes. *J Allergy Clin Immunol*. 2012;130:607-612.e9.
- Hsieh FH. Hypereosinophilic syndrome. *Ann Allergy Asthma Immunol*. 2014;112:484-8.
- Plötz SG, Hüttig B, Aigner B, Merkel C, Brockow K, Akdis C, et al. Clinical overview of cutaneous features in hypereosinophilic syndrome. *Curr Allergy Asthma Rep*. 2012;12:85-98.
- Kazmierowski JA, Chusid MJ, Parrillo JE, Fauci AS, Wolff SM. Dermatologic manifestations of the hypereosinophilic syndrome. *Arch Dermatol*. 1978;114:531-5.
- Mahajan VK, Singh R, Mehta KS, Chauhan PS, Sharma S, Gupta M, et al. Idiopathic hypereosinophilic syndrome: a rare cause of erythroderma. *J Dermatol Case Rep*. 2014;8:108-14.
- Abdulsalam MS, Ghanta HC, Pandurangan P, Menon M, Jacob SS. A Case of Erythroderma Secondary to Hypereosinophilia. *J Clin Diagn Res*. 2016;10:OD15-6.
- King B, Lee AI, Choi J. Treatment of Hypereosinophilic Syndrome with Cutaneous Involvement with the JAK Inhibitors Tofacitinib and Ruxolitinib. *J Invest Dermatol*. 2017;137:951-954.
- Schwartz LB, Sheikh J, Singh A. Current strategies in the management of hypereosinophilic syndrome, including mepolizumab. *Curr Med Res Opin*. 2010;26:1933-46.
- Noh HR, Magpantay GG. Hypereosinophilic syndrome. *Allergy Asthma Proc*. 2017;38:78-81.


Maira Renata Merlotto

 ORCID 0000-0002-8918-5640


Lucas Oliveira Cantadori

 ORCID 0000-0003-0436-1842

Delmo Sakabe

 ORCID 0000-0003-0181-0905

Hélio Amante Miot

 ORCID 0000-0002-2596-9294

How to cite this article: Merlotto MR, Cantadori LO, Sakabe D, Miot HA. Case for diagnosis. Erythroderma as manifestation of hypereosinophilic syndrome. *An Bras Dermatol*. 2018;93(3):451-3.