availability of the post mortems in Bombay have remained more or less the same as in the previous 50 years period. The writer has been intimately in contact with all post-mortem work during this period except from June 1941 to November 1945, when he was serving in the Army. During this period there occur 8 proven cases of primary carcinoma of liver in 4,000 and odd autopsies. The incidence of diseases as judged from autopsy records is better judged if data relating to total autopsies, deaths and admissions are made available.

The following details relate to the period 1926 to 1946 :—

Period from 1st January, 1926 to 31st December, 1946

Total admissions	154,742	Males	129,314
		Females	25,428
Total deaths ..	13,497		
Sex incidence available in	7,593	Males	5,962
		Females	1,901
Total autopsies ..	4,321	Males	3,546
		Females	775
Total tumours ..	131	Males	110
		Females	21
Primary liver ..	8	Males	7
		Female	1
Secondary liver ..	18		

The background of these data is valuable and the reader can draw his conclusions in a proper perspective. Similar has been the background of all former papers (Gharpure, 1927; Gharpure, 1928; Tilak, 1938; and Bhajekar, 1942) published from this institution relating to the incidence of diseases.

In the material now reported there occur 131 primary malignant tumours. Their distribution is detailed in the table below :—

The conclusion that the primary carcinoma of the liver is rare is confirmed. These conclusions are fairly parallel with those made by Khanolkar (1945).

Summary

1. Statements by Berman are discussed.
2. A paper published in 1927 is re-examined. Nine cases of probable primary carcinoma of liver in 6,000 and odd autopsies are reconsidered.
3. Fresh data from 4,000 and odd autopsies are presented in which 8 cases of primary carcinoma of the liver occur in a total of 131 primary malignant tumours of all organs.

REFERENCES

BERMAN, C. (1940) .. *South African J. Med. Sci.*, **5**, 54.
BHAJEKAR, M. V. (1942). *Indian Med. Gaz.*, **77**, 390.
GHARPURE, P. V. (1927). *Ibid.*, **62**, 315.
Idem (1928). *Ibid.*, **63**, 253.
KHANOLKAR, V. R. (1945). *Indian J. Med. Res.*, **33**, 299.
TILAK, P. V. (1938) .. *Med. Bull.*, **6**, 395, 672.
VISWA NATH and GREWAL, K. S. (1935). *Indian J. Med. Res.*, **23**, 149.

PELVIC FLOOR REPAIR UNDER PERINEO-PUDENDAL BLOCK ANÆSTHESIA

By MARY P. JOHN, M.B., B.S., M.R.C.S., M.R.C.O.G.
Gynæcological Surgeon
Hospital for Women, The Prince of Wales Medical College, Patna

IN gynæcological surgery general anæsthesia still enjoys universal popularity, a century after the introduction of inhalation anæsthesia. It is, however, felt that there are certain cases in which some other and safer method of anæsthesia would be desirable. In old patients

TABLE

Tumour	Total	Males	Females	Hindu	Muslim	Christian	Chinese	Unknown
Abdominal ..	5	5	..	4	..	1	..	..
Brain	2	2	..	1	..	..	1	..
Breast	*nil*	..	..	..	..	..	..	..
Chest	22	21	1	14	4	3	..	..
Duodenum ..	3	3	..	1	2	..	..	..
Face, cheek ..	6	5	1	4	..	2	..	..
Femur	1	1	..	1	..	..	..	..
Gall-bladder ..	2	1	1	1	..	1	..	..
Intestine	6	6	..	2	4	..	..	..
Kidney	5	3	2	3	2	..	..	..
Larynx	16	15	1	13	2	1	..	..
Œsophagus	7	4	3	5	1	1	..	..
Ovary	3	..	3	2	1	..	..	..
Pancreas	3	3	..	..	2	..	1	..
Parotid	3	3	..	2	1	..	..	..
Penis	5	5	..	4	..	1	..	..
Prostate	4	4	..	4	..	..	..	..
Rectum	2	2	..	2	..	..	..	..
Skin	1	1	..	..	1	..	..	..
Stomach	8	8	..	6	1	1	..	..
Suprarenal	1	1	..	1	..	..	..	..
Testis	3	3	..	2	..	1	..	..
Thyroid	2	..	2	1	..	..	..	1
Tongue	6	6	..	2	3	1	..	..
Tonsil	1	1	..	1	..	..	..	..
Urinary bladder ..	..	..	..	..	..	..	..	..
Uterus	6	..	6	4	1	..	..	1 Jew
Liver	8	7	1	5	1	..	..	2

and in those having associated complications like cardiovascular degeneration, renal disease, diabetes, bronchitis, hypertension, etc., general anæsthesia, particularly ether, is not suitable, although these complications by themselves are not sufficient to contra-indicate surgery.

A considerable proportion of gynæcological operations consist in plastic repair of the pelvic floor. The patients suffering from genital prolapse are mostly elderly and the use of ether alone or in combination with other anæsthetics makes them more prone to post-operative complications.

It was, therefore, decided to give a trial to perineo-pudendal block anæsthesia in selected cases who were judged not to be good subjects for general anæsthesia. The result of this anæsthesia was found so satisfactory that this method is now being used as a routine in all cases of pelvic floor repair by the author. The usual objections to local anæsthesia are increased time of operation and unsuitability in highly strung patients; these do not apply here as only about seven minutes are required to induce block anæsthesia and the patient usually sleeps throughout the operation. In this series no case was abandoned nor required any supplementary anæsthetic.

The following technique is used. Premedication is induced by morphine sulphate gr. $\frac{1}{4}$ and hyoscine hydrobromide gr. 1/150 (given subcutaneously 45 minutes before operation). Strict silence is enjoined and the patient instructed to sleep. When she is asleep the table is wheeled into the theatre and the operation commenced. The solution for block

CHART

Number	Age	Type of prolapse	Nature of operation	Result of anæsthesia	Recovery	REMARKS
1	50	Complete prolapse.	Manchester operation	Very satisfactory	Uneventful	Emphysema of lungs. BP 110/70.
2*	30	Do.	Do.	Satisfactory	Secondary hæmorrhage on 9th day; recovered.	BP 100/70. Hb. 55 per cent.
3	60	Do.	Do.	Very satisfactory	Uneventful	Large goitre. BP 195/95.
4	38	2nd degree prolapse. Cystocele. Hernia of pouch of Douglas.	Ant. colporrhaphy. Amputation of cervix. Repair of pouch of Douglas hernia. Post-colpoperineorrhaphy.	Do.	Inflammatory effusion left side, subsided rapidly with sulphonamides.	General condition before operation good.
5	40	2nd degree prolapse. Marked cystocele.	Ant. colporrhaphy. Post-colpoperineorrhaphy.	Do.	Uneventful	General health good.
6*	22	Marked cystocele. Cyst of post-vaginal wall.	Ant. colporrhaphy. Enucleation of vaginal cyst. Post-colpoperineorrhaphy.	Satisfactory	Do.	Do.
7	50	Complete prolapse.	Manchester operation	Very satisfactory	Do.	Do.
8	34	2nd degree prolapse.	Do.	Do.	Do.	Do.
9	40	Complete prolapse.	Do.	Do.	Do.	Do.
10†	48	Do.	Do.	Satisfactory	Do.	Do.
11	45	Cystocele. 1st degree prolapse.	Ant. colporrhaphy. Post-colpoperineorrhaphy.	Very satisfactory	Do.	Do.
12†	20	Marked cystocele. 2nd degree perineal tear.	Do.	Satisfactory	..	..
13	22	1st degree prolapse. Marked cystocele.	Do.	Very satisfactory	Uneventful	General health good.
14	22	Do.	Do.	Do.	Do.	BP 104/75. Hb. 50 per cent.
15*	26	Vesico-vaginal fistula.	Repaired	Satisfactory	Wound broke down.	General health good.
16	21	Do.	Do.	Very satisfactory	Cured	Do.

* Complained of backache towards the end of operation.
† Was not asleep at the beginning of the operation and hyoscine hydrobromide gr. 1/200 was repeated.

anæsthesia consists of 1 per cent novocaine with addition of 4 minims of adrenaline hydrochloride to an ounce. An intradermal wheal is raised on one side midway between the ischial tuberosity and the anus with a fine needle. A 10 cm. long needle is then passed through this and with the help of the left index finger in the vagina the needle is guided to the dorsal surface of the ischial spine where 15 c.c. of the solution is injected blocking the pudenal nerve as it courses over the ischial spine (*see* figure, plate I). Before injection the piston is withdrawn slightly to ensure that the needle is not in a blood vessel. The needle is then withdrawn until the point is in the subcutaneous tissue and is directed towards the ischial tuberosity. With the needle in constant motion about 12 c.c. of the solution is injected on the inner side of the tuberosity in a fan-shaped manner blocking the branches of the posterior femoral cutaneous nerve. The needle is then directed towards the midline of perineum and 10 c.c. of the solution injected blocking the muscular branches of the sacral plexus, then forward on the vulva as far as the level of the clitoris and more of the solution is injected while slowly withdrawing the needle blocking the branches of the ilio-inguinal nerve.

The results of the anæsthesia and the operations are appended in the table which includes repair of two cases of vesico-vaginal fistulæ under this method of anæsthesia.

Plastic operations for uterine prolapse have been performed under local anæsthesia with satisfactory results (Peham and Amreich, 1934; Griffin and Benson, 1941) though it appears that this method has not been given extended trial except in certain clinics. The advantages of local anæsthesia are too well known to need elaboration here. The particular advantages of this method in prolapse operations are absence of post-operative sickness, reduction of post-operative pulmonary complications, reduction of bleeding in the field of operation, and that the services of an anæsthetist are not required. Its another great advantage in the tropics is that fluids can be administered to the patient before, during and immediately after the operation : an important point in avoiding water and salt depletion during summer.

Summary

General anæsthesia is still widely used in gynæcological surgery. Genital prolapse usually occurs in the elderly and some of these patients are not suitable subjects for inhalation or spinal anæsthesia due to associated complications. Perineo-pudendal block anæsthesia with novocaine is a safe and satisfactory anæsthesia for routine use and has several advantages over inhalation anæsthesia.

REFERENCES

GRIFFIN, E. L., and BENSON, R. C. (1941). *Amer. J. Obstet. and Gyn.*, **42**, 862.

VON PEHAM, H., and AMREICH, I. (1934). *Operative Gynæcology*. J. B. Lippincott Co., Philadelphia.

OBSERVATIONS ON PNEUMOCOCCAL MENINGITIS AS A COMPLICATION OF KALA-AZAR

By P. C. SEN GUPTA, M.B.
K. N. BASU MALLIK, M.B.
and
N. K. CHAKRAVARTY, M.B.
(*From the Kala-azar Research Department, School of Tropical Medicine, Calcutta*)

KALA-AZAR is a disease that is not infrequently associated with many serious complications, the well-known examples of which are cancrum oris, dysentery, pneumonia and broncho-pneumonia, hæmorrhages, anæmia, generalized œdema, etc. Agranulocytosis is another relatively uncommon but grave complication. During the recent outbreak of kala-azar in Calcutta that commenced after the Bengal famine of 1943, increasing numbers of seriously complicated cases of kala-azar were seen (Sen Gupta, 1947) and one of the grave complications was pneumococcal meningitis. During the last two years, 1945 and 1946, four cases of kala-azar who had developed this complication were admitted under the care of the senior writer into the Carmichael Hospital for Tropical Diseases. (During this period 314 cases of kala-azar were admitted into the hospital.) Except for the mention of finding two cases of pneumococcal meningitis in the post-mortem examination of 40 cases of kala-azar by Rogers (1919), there is apparently no recent record of this complication in kala-azar in the available medical literature. The notes of these four cases, along with the post-mortem findings of one of the cases, are presented below and the findings discussed.

Case notes

Case 1.—A Nepali male, aged 14 years, was admitted on the 22nd September, 1945, for fever with splenic enlargement, duration uncertain; attacks of diarrhœa with occasional passage of blood and mucus for about five years; swelling of the legs and the abdomen for about four months; along with cough, malnutrition and anæmia. In 1944 he had been admitted into another hospital as a famine-stricken 'destitute'.

On admission the patient was found to be very weak, anæmic and emaciated. There was œdema of the legs up to the knees and ascites. Angular stomatitis was present. The lungs showed diminished breath sounds, vocal resonance and fremitus over both bases. The heart showed no abnormality except simple tachycardia. The liver was enlarged up to 1 inch below the costal margin and the spleen to the umbilicus.

Laboratory reports

Urine.—Albumin present, casts or RBC not present.

Fæces.—Ova of ascaris present, 1,000 per c.cm. of fæces.

PLATE I

PELVIC FLOOR REPAIR UNDER PERINEO-PUDENDAL BLOCK ANÆSTHESIA : MARY P. JOHN. (O. A.) PAGE 6

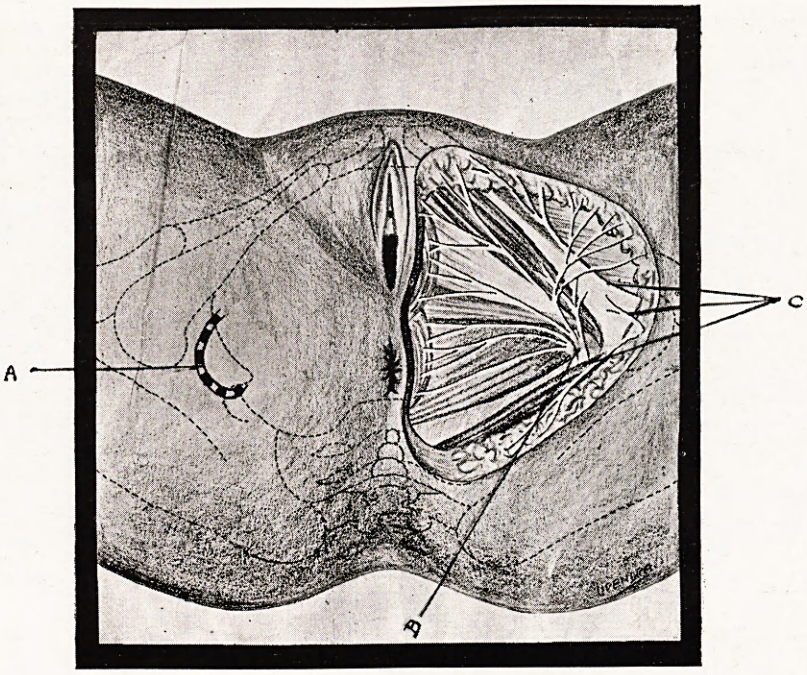

A—Course of internal pudendal nerve over ischial spine.
B—Branches of internal pudendal nerve.
C—Branches of posterior femoral cutaneous nerve.

OBSERVATIONS ON PNEUMOCOCCAL MENINGITIS AS A COMPLICATION OF KALA-AZAR : P. C. SEN GUPTA, K. N. BASU MALLIK & N. K. CHAKRAVARTY. (O. A.) PAGE 8

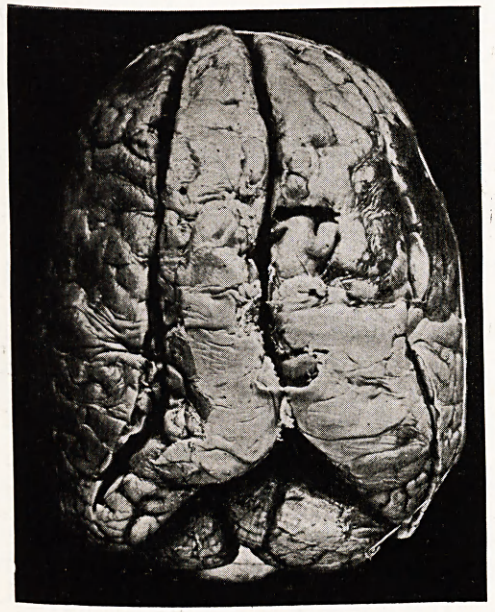

Fig. 1.

Fig. 2.