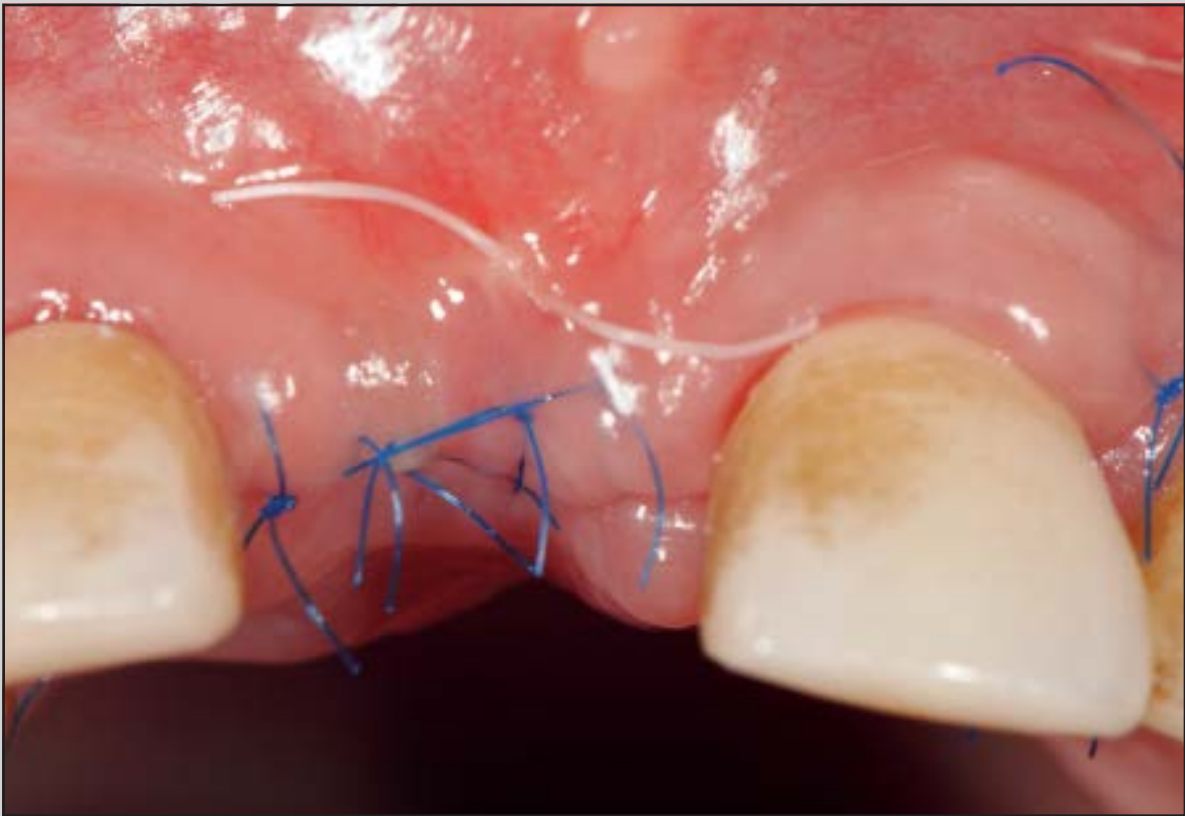
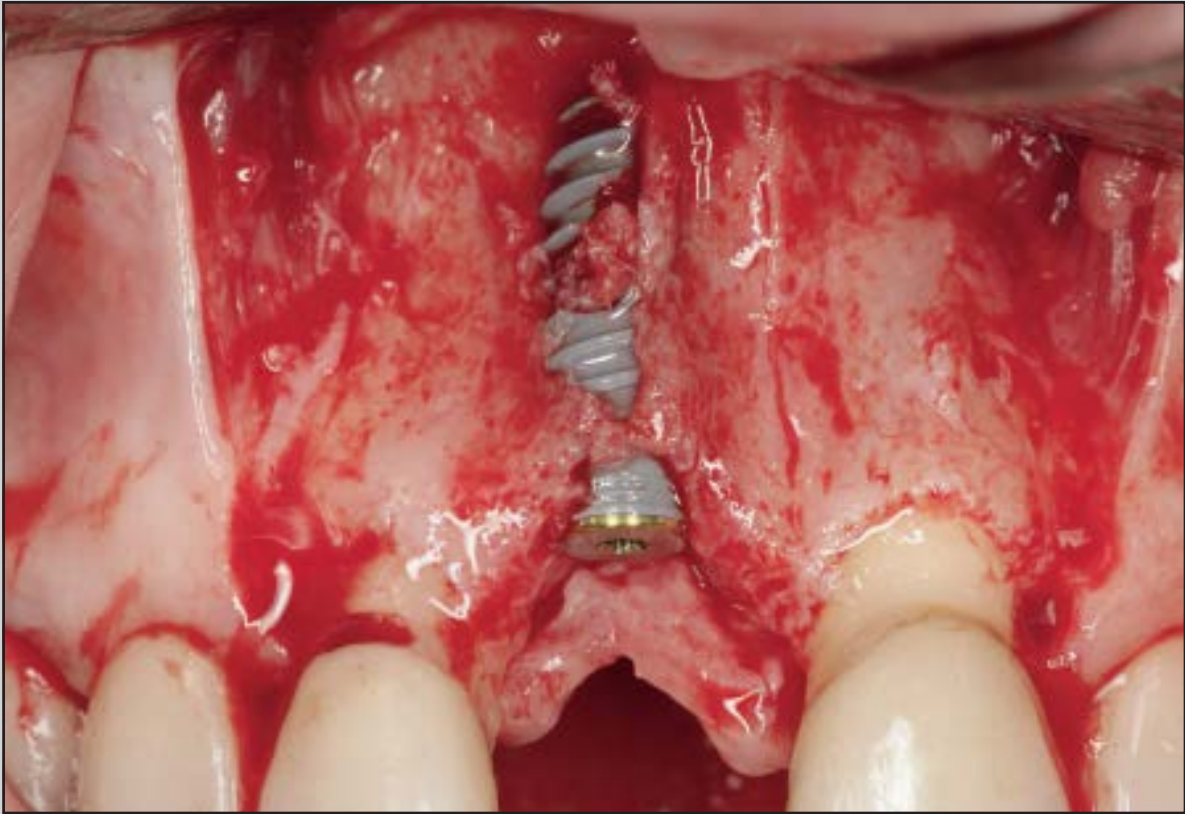
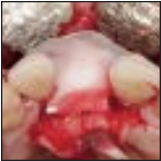Vertical Bone Grafting and Periosteal Vertical Mattress Suture for the Fixation of Resorbable Membranes and Stabilization of Particulate Grafts in Horizontal Guided Bone Regeneration to Achieve More Predictable Results: A Technical Report



Istvan A. Urban, DMD, MD, PhD¹

Jaime L. Lozada, DMD²

Bastian Wessing, Dr Med Dent³

Fernando Suárez-López del Amo, DDS⁴

Hom-Lay Wang, DDS, MSD, PhD⁵

Osteosynthesis screws and titanium or resorbable pins have been recommended for fixing guided bone regeneration (GBR) membranes and stabilizing the graft. However, the removal of fixation screws or pins often requires an additional surgical procedure. This article presents a periosteal suturing technique with resorbable sutures for the fixation of grafts and membranes in GBR in single implant sites. This technique avoids potential complications of using fixation screws or pins, such as perforation of the roots when inserting the pins, and eliminates the need for a second retrieval surgery.

Int J Periodontics Restorative Dent 2016;36:153–159. doi: 10.11607/prd.2627

Bone augmentation techniques using guided bone regeneration (GBR) have shown excellent and reproducible success rates for many years and have ensured a relatively low level of surgical invasiveness for patients.^{1–5} However, using GBR for large horizontal and vertical ridge defects is technique-sensitive and carries an increased rate of complications.¹ The principles of GBR require the use of resorbable or nonresorbable membranes for the creation of a space above a bony defect and under the periosteum, allowing osteoprogenitor cells the time to colonize this space rather than the faster-proliferating connective tissue cells and/or overlying epithelial cells.⁶ Studies have demonstrated excellent results with the use of nonresorbable membranes, especially when no exposure occurs during the healing phase.^{7–10} Nevertheless, removal of a nonresorbable membrane requires an extensive surgical reopening.^{11,12} Natural resorbable membranes provide good tissue and cell compatibility and lower dehiscence rates than nonresorbable membranes.^{13–16}

A common goal of resorbable and nonresorbable membranes is to not only create a defined space above the defect but also maintain the space during the bone regeneration period.^{17,18} Since the mid-1990s, resorbable materials, notably

¹Assistant Professor, Graduate Implant Dentistry, Loma Linda University, Loma Linda, California, USA; Urban Regeneration Institute, Budapest, Hungary.

²Professor, Department of Restorative Dentistry, Director of Graduate Implant Dentistry, Loma Linda University, Loma Linda, California, USA.

³Dental Practice Clinic, Luisenhospital, Aachen, Germany.

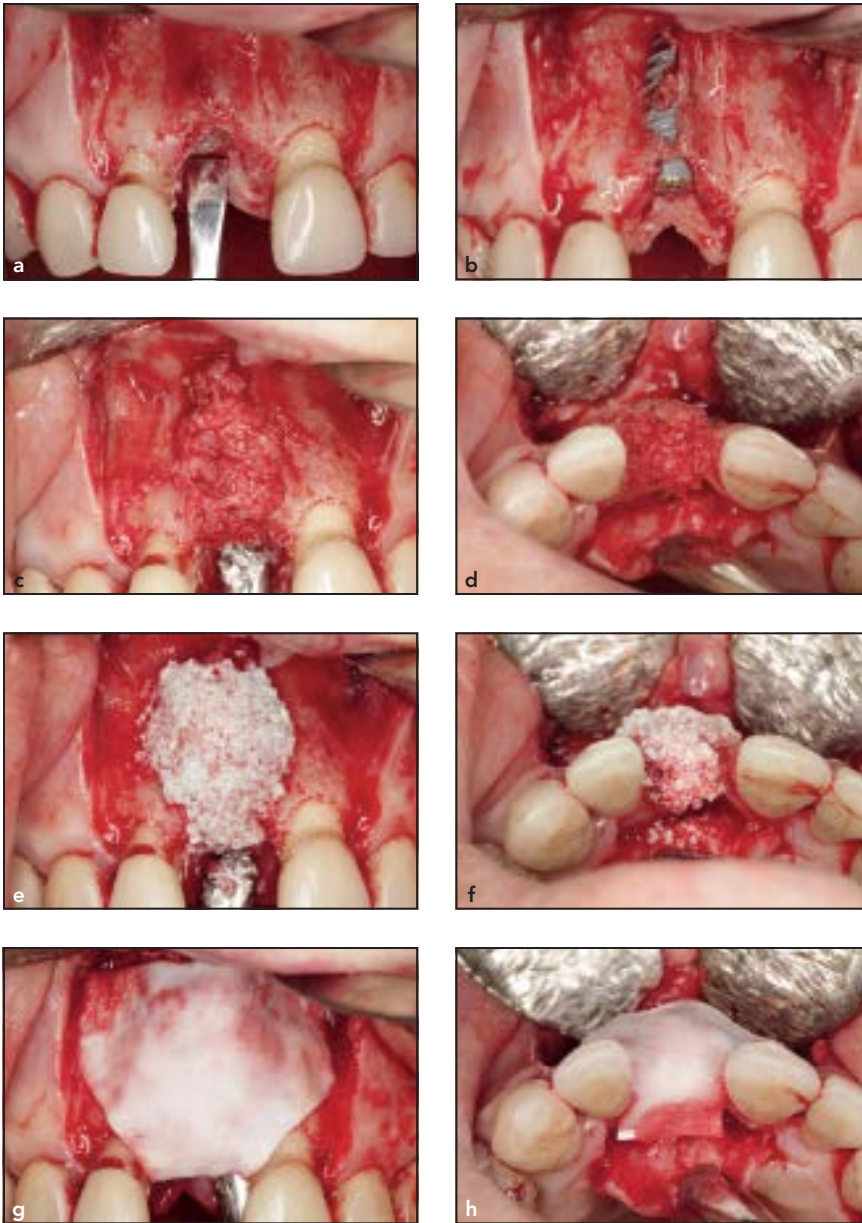
⁴Graduate Student, Department of Periodontics and Oral Medicine, University of Michigan School of Dentistry, Ann Arbor, Michigan, USA.

⁵Professor and Director of Graduate Periodontics, Department of Periodontics and Oral Medicine, University of Michigan School of Dentistry, Ann Arbor, Michigan, USA.

Correspondence to: Dr Istvan A. Urban, Sodras utca 9, 1026 Budapest, Hungary.

Fax: 0036-12004447. Email: istvan@implant.hu

©2016 by Quintessence Publishing Co Inc.



Figs 1a to 1h Representative case of the periosteal vertical mattress suturing (PVMS) technique. Buccal view of the defect before (a) and after (b) implant placement. Buccal (c) and occlusal (d) views of the autogenous bone placed on the buccal and occlusal surfaces of the implant. Buccal (e) and occlusal (f) views of the anorganic bovine bone mineral placed on the buccal and occlusal surface of the implant. Buccal (g) and occlusal (h) views of the native collagen membrane (BioGide, Geistlich) placed on the bone graft.

native collagen, have been used widely as an alternative to expanded polytetrafluoroethylene (ePTFE) membranes and provide equally good results for multiple indications,

including but not limited to GBR around dental implants, implant site development, and ridge augmentation procedures.^{9,19–23} Nonetheless, resorbable membranes lack form

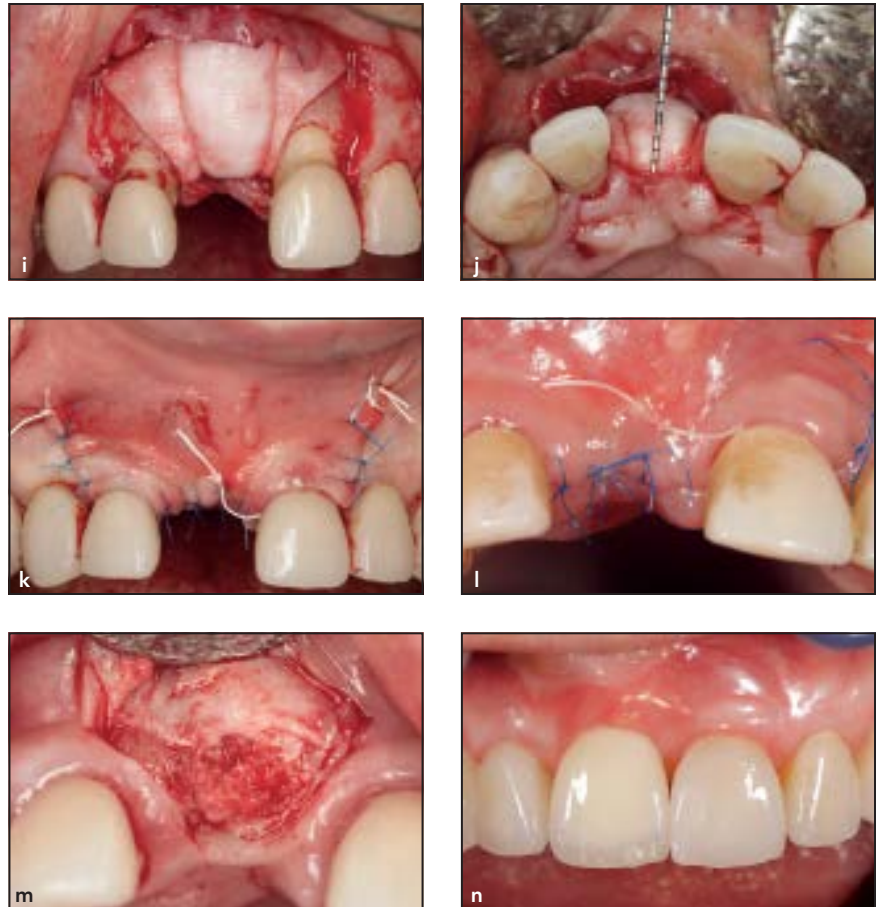stability, and this may lead to graft migration, membrane collapse, and insufficient bone formation.²⁴ In fact, when resorbable membranes and particulate grafts are used, the primary challenge is the correct positioning and fixation of the graft and membrane at the desired site since graft particles may migrate and the membrane may collapse under the flap. When performing GBR procedures, the PASS principle has to be followed.²⁵ A key factor of this principle is to secure and stabilize the wound, including the barrier membrane and bone grafts.²⁶ Although there is no evidence comparing bone augmentation procedures with or without tacks for membrane stabilization, clinicians have recommended the use of fixation pins/screws to fix resorbable membranes.

Resorbable and nonresorbable cortical bone pin systems have been used for the fixation of collagen membranes.^{15,16,20,21,26} However, regardless of the resorption properties of the tacking system, the use of such pins leads to a risk of perforating important anatomical structures, such as the inferior alveolar nerve, the maxillary sinus, or the roots of teeth adjacent to the surgical site. So far, there is no agreement on whether nonresorbable pins or osteosynthesis screws need to be removed post-healing. The removal of pins or screws presents risks such as bone loss, nerve lesions, scar formation, and surgical complications. However, leaving nonresorbable pins may result in dislocation and migration into adjacent tissues, potentially causing a rejection or sensitivity disorder.

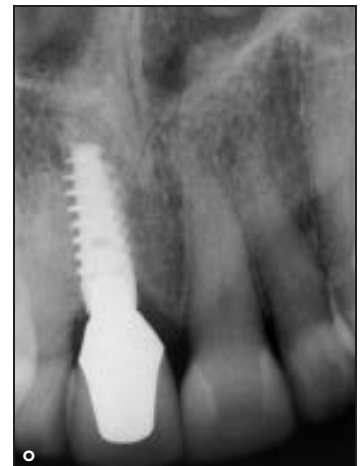The aim of this article is to introduce a new technique for fixation of resorbable membranes onto the underlying bone, potentially immobilizing particulate grafts using resorbable sutures in horizontal GBR procedures. Use of this suturing approach minimizes the need for second retrieval surgeries and avoids damage to adjacent vital anatomical structures while inserting the pins or screws.

Periosteal vertical mattress suture (PVMS) technique

To perform horizontal GBR procedures using this membrane fixation technique, a remote flap, consisting of crestal and vertical releasing incisions, should be used. A full-thickness midcrestal incision is typically used in the keratinized gingiva with a no. 15c surgical scalpel. For surgical access, the two divergent vertical incisions are placed one tooth away from the surgical site (Figs 1a, 1b, 2a, and 2b). If preferred, decortication holes (eg, using a 1-mm round metal bur) can be made in the area of the planned bone augmentation to access blood from the cancellous bone. The particulate graft is then placed in the desired area, either alone or with a simultaneous implant placement. In both cases shown, a so-called sandwich augmentation was used according to Wang et al, using autologous bone chips on the surface of a dental implant with buccal dehiscence and an anorganic bovine bone mineral (Bio-Oss, Geistlich) on top of the bone chips for slower resorption.²⁷ The



Figs 1i to 1o Representative case of the periosteal vertical mattress suturing (PVMS) technique. Buccal (i) and occlusal (j) views of the periosteal vertical mattress suture stabilizing the graft (6-0 monocryl, Ethicon). (k) Double layer suturing of the bone graft using 3-0 PTFE (Cytoplast) and 6-0 monofilament sutures (Prolene, Ethicon). (l) Uneventful healing 2 weeks after the bone graft. (m) Clinical view of the regenerated bone after 6 months of uneventful healing. Note that bone formation occurred even on top of the implant, resulting in complete bone formation. (n) Labial view of the final reconstruction in place. (o) Periapical radiograph demonstrates good bone-to-implant contact.



authors prefer to place graft material even on top of the cover screw of the implant. The goal of vertical bone grafting is to achieve more space in the occlusobuccal corner

of the implant (Figs 1c to 1f, and 2c). In the experience of the present authors, this aspect is critical because even with the suturing technique the pressure of the sutured flap can

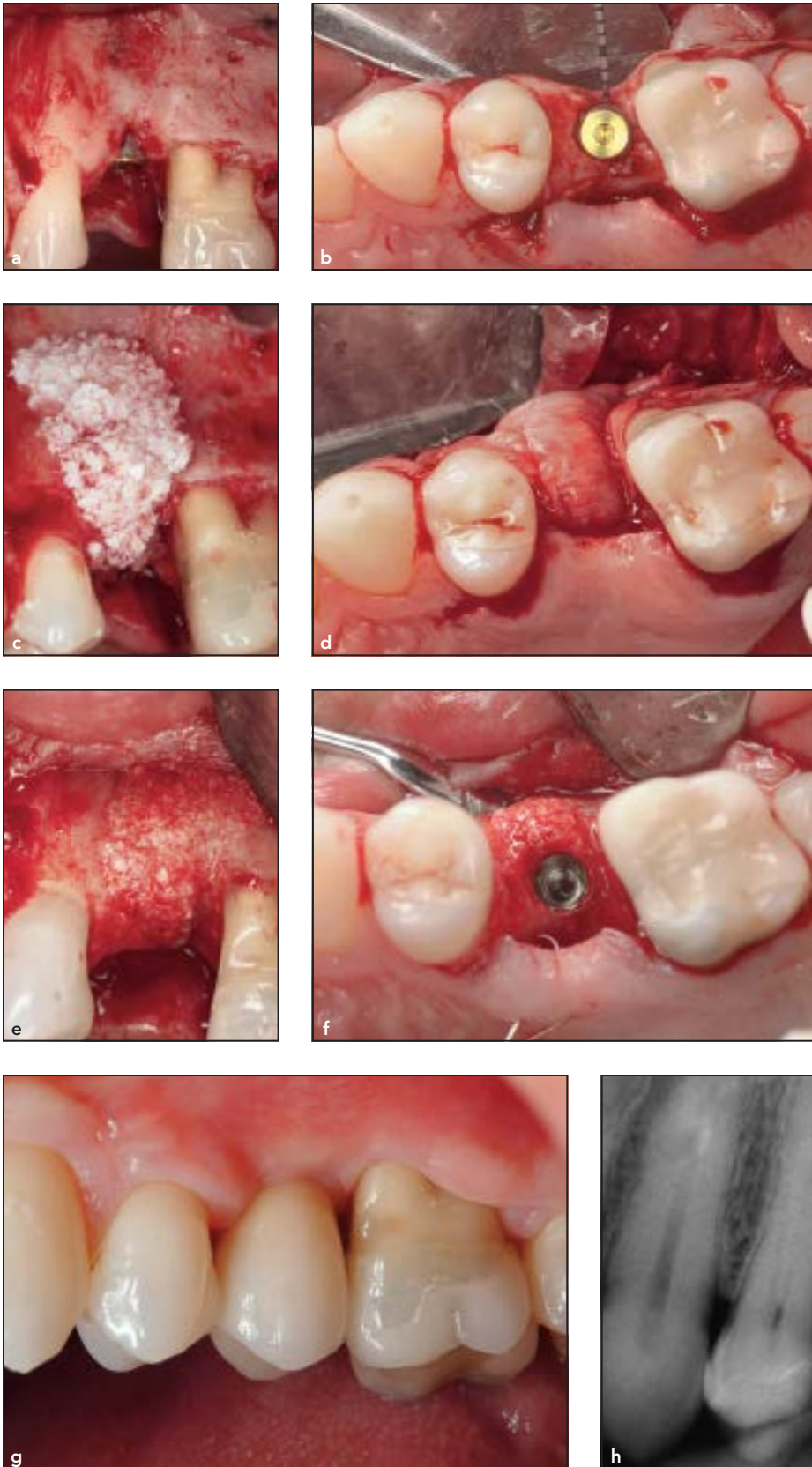
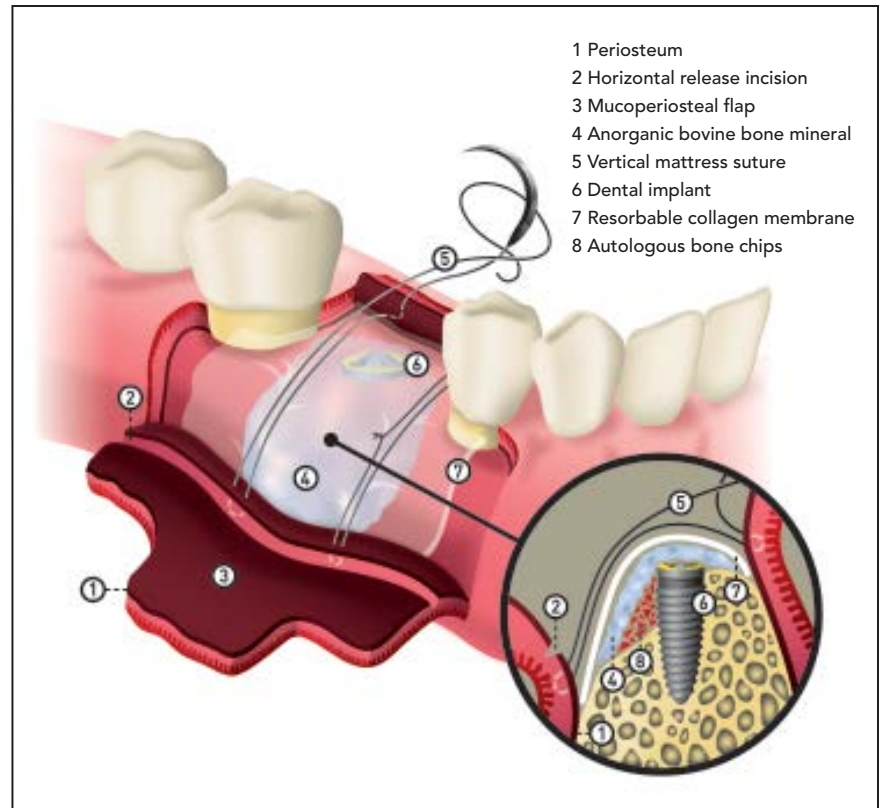


Fig 2 Representative case of posterior site using vertical grafting and PVMS suturing. Buccal (a) and occlusal (b) views of implants placed into deficient buccal bone crest. (c) Buccal view of sandwich bone graft placed on the facial and occlusal side of the implant. (d) Occlusal view of the membrane fixated with suturing. (e) Buccal view of the regenerated bone. Note that bone formation occurred even on top of the implant. (f) Occlusal view of the regenerated bone. Note the excellent contour of the regenerated bone even on the most coronal part of the implant. (g) Labial view of the final reconstruction in place. (h) Periapical radiograph demonstrates good bone-to-implant contact.

Fig 3 Fixation of the membrane using a periosteal vertical mattress suture.



press out some of the bone graft to the lateral areas, and this can result in incomplete bone regeneration.

With the particulate bone graft in place, the resorbable membrane should be trimmed, positioned, and rehydrated with a sterile saline solution for better adaptation to the augmented area. In this case, a resorbable bilayer collagen membrane was used (Bio-Gide, Geistlich) (Figs 1g and 1h).

Figure 3 illustrates the suturing technique. First, a periosteal release incision has to be made 3 to 4 mm beneath the planned apical position of the graft material and the overlapping resorbable membrane.

The first periosteal suture with resorbable material (thin suture, eg, 6-0) and a relatively small needle (eg, 10 to 13 mm 3/8 circle) is started by stitching through the periosteum apically from the periosteal release incision mesially and distally of the augmented area. At this point, it is important to suture that part of the periosteum apical to the horizontal release incision. This ensures that the tension of the vertical periosteal suture (and therefore the fixation of the membrane) is kept after closure of the mucoperiosteal flap. The suture is next laid over the distal extension of the membrane beside the augmented area; the suture is then con-

tinued as a mattress on the palatal/lingual section of the mucoperiosteal flap (Figs 1i, 1j, and 2d). The suture is closed and tightened over the membrane until the latter is fixed to the underlying bone. Next, the same procedure is repeated on the mesial side of the bone graft. After both sutures are closed, the rehydrated and fixed membrane can be stretched by gently pulling it with pliers from both sides (mesial and distal) away from the vertical sutures until the bone graft is completely immobilized and positioned correctly. The sutures can also be lifted and repositioned using a periodontal probe. Thus, the two internal vertical mattress sutures will

prevent potential movement and migration of the bone graft. Closure of the mucoperiosteal flap should be done in two layers. The first layer is closed with horizontal mattress sutures placed 4 mm from the incision line, and single interrupted sutures are used to close the edges of the flap. With this technique, the flap margins become averted, effectively abutting the 4-mm-wide inner connective tissue layers of the buccal and lingual flaps. Vertical incisions are closed using single interrupted sutures, which can be removed 10 to 14 days after surgery. The mattress suture should remain in place for at least 2 to 3 weeks (Figs 1k and 1l).

The remaining procedures can be performed according to standard clinical practice, and extensive surgical revision for the removal of titanium pins (or similar pins or tacks) is not necessary (Figs 1m, 2e, and 2f).

Discussion

Although there is no convincing evidence of any advantage, some authors recommend the fixation of resorbable membranes when performing GBR for the stabilization of particulate graft materials.^{20,21,26}

Evidence has shown a large volume of bone formation after performing GBR with fixed resorbable membranes using a cortical bone pin system.^{15,16,20,21,26} Despite these positive results, several potential risks have been documented: damage of the adjacent roots and underlying anatomical vital structures, and the need for an extensive reopening procedure to retrieve the nonresorbable

pins.^{11,12} The PVMS technique, primarily recommended for single implant sites, may lessen these risks while successfully fixing the membrane and immobilizing particulate bone graft materials at the desired position. A limitation to this technique resides in the tensile strength of the resorbable suture material, and consequently the resultant strength of the membrane fixation and graft stabilization. A further limitation on the shape of the bone graft arises since it is only possible to fix the membrane by means of a linear-guided suture, thus resulting in possible migration of the particulate graft material in an apicocoronal direction. Therefore, for multiple ridge defects the use of pins is still recommended, as the PVMS technique may not provide enough stability for grafts in defects from multiple missing teeth. The time of fixation is also limited by the biodegradation period of the resorbable suture material. The suture material used in the case shown is Monocryl (clear) 6-0 (Ethicon), a monofilament resorbable copolymer of glycolide and epsilon-caprolactone. According to the manufacturer, the time for complete resorption is between 91 and 119 days. However, the suture's tensile strength after 1 week is approximately 50 to 60% of its initial strength, and approximately 20 to 30% after 2 weeks in vivo, which means a loss of three-quarters of its tensile strength over the first 2 weeks. Even if there is no evidence in the literature for the amount of time required for membrane fixation, it may only be necessary for the initial weeks of healing until a preliminary bone matrix is established.

Conclusions

To perform a ridge augmentation using the GBR technique with particulate graft materials, there may be a preference for fixation of a resorbable collagen membrane and immobilization of the bone graft. However, for single implant sites with adjacent teeth the technique described herein provides an alternative to pin fixation. The authors' clinical experience with this technique has shown a low rate of dehiscence and good bone regeneration results. Nevertheless, further well-designed clinical studies are needed to prove that the technique described can produce comparable and reproducible results.

Acknowledgments

The authors would like to thank Miss Kebrina Urbaniak for the figure that illustrates this technique. The authors reported no conflicts of interest related to this study.

References

1. Aghaloo TL, Moy PK. Which hard tissue augmentation techniques are the most successful in furnishing bony support for implant placement? *Int J Oral Maxillofac Implants* 2007;22 (suppl):49–70.
2. Dahlin C, Linde A, Gottlow J, Nyman S. Healing of bone defects by guided tissue regeneration. *Plast Reconstr Surg* 1988;81:672–676.
3. Nyman S, Lang NP, Buser D, Brägger U. Bone regeneration adjacent to titanium dental implants using guided tissue regeneration: A report of two cases. *Int J Oral Maxillofac Implants* 1990;5:9–14.
4. Jovanovic SA, Spiekermann H, Richter EJ. Bone regeneration around titanium dental implants in dehiscence defect sites: A clinical study. *Int J Oral Maxillofac Implants* 1992;7:233–245.

5. Simion M, Baldoni M, Rossi P, Zaffe D. A comparative study of the effectiveness of e-PTFE membranes with and without early exposure during the healing period. *Int J Periodontics Restorative Dent* 1994;14:166–180.
6. Polimeni G, Xiropaidis AV, Wikesjö UM. Biology and principles of periodontal wound healing/regeneration. *Periodontol* 2000 2006;41:30–47.
7. Hämmerle CH, Brägger U, Schmid B, Lang NP. Successful bone formation at immediate transmucosal implants: A clinical report. *Int J Oral Maxillofac Implants* 1998;13:522–530.
8. Friedmann A, Strietzel FP, Marezki B, Pitaru S, Bernimoulin JP. Observations on a new collagen barrier membrane in 16 consecutively treated patients. Clinical and histological findings. *J Periodontol* 2001;72:1616–1623.
9. Jung RE, Hälgl GA, Thoma DS, Hämmerle CH. A randomized, controlled clinical trial to evaluate a new membrane for guided bone regeneration around dental implants. *Clin Oral Implants Res* 2009;20:162–168.
10. Machtei EE. The effect of membrane exposure on the outcome of regenerative procedures in humans: A meta-analysis. *J Periodontol* 2001;72:512–516.
11. Siar CH, Toh CG, Romanos G, Ng KH. Subcutaneous reactions and degradation characteristics of collagenous and non-collagenous membranes in a macaque model. *Clin Oral Implants Res* 2011;22: 113–120.
12. Lorenzoni M, Pertl C, Polansky RA, Jakse N, Wegscheider WA. Evaluation of implants placed with barrier membranes. A retrospective follow-up study up to five years. *Clin Oral Implants Res* 2002;13:274–280.
13. Bozkurt A, Apel C, Sellhaus B, et al. Differences in degradation behavior of two non-cross-linked collagen barrier membranes: An in vitro and in vivo study. *Clin Oral Implants Res* 2014;25:1403–1411.
14. Rothamel D, Schwarz F, Sculean A, Herten M, Scherbaum W, Becker J. Biocompatibility of various collagen membranes in cultures of human PDL fibroblasts and human osteoblast-like cells. *Clin Oral Implants Res* 2004;15:443–449.
15. Urban IA, Nagursky H, Lozada JL. Horizontal ridge augmentation with a resorbable membrane and particulated autogenous bone with or without anorganic bovine bone-derived mineral: A prospective case series in 22 patients. *Int J Oral Maxillofac Implants* 2011;26: 404–414.
16. Urban IA, Lozada JL, Jovanovic SA, Nagy K. Horizontal guided bone regeneration in the posterior maxilla using recombinant human platelet-derived growth factor: A case report. *Int J Periodontics Restorative Dent* 2013;33:421–425.
17. Chasioti E, Chiang TF, Drew HJ. Maintaining space in localized ridge augmentation using guided bone regeneration with tenting screw technology. *Quintessence Int* 2013;44:763–771.
18. Nevins ML, Reynolds MA, Camelo M, Schubach P, Kim DM, Nevins M. Recombinant human platelet-derived growth factor BB for reconstruction of human large extraction site defects. *Int J Periodontics Restorative Dent* 2014;34: 157–163.
19. Jung RE, Fenner N, Hämmerle CH, Zitzmann NU. Long-term outcome of implants placed with guided bone regeneration (GBR) using resorbable and non-resorbable membranes after 12-14 years. *Clin Oral Implants Res* 2013;24: 1065–1073.
20. Hämmerle CH, Lang NP. Single stage surgery combining transmucosal implant placement with guided bone regeneration and bioresorbable materials. *Clin Oral Implants Res* 2001;12:9–18.
21. Hämmerle CH, Jung RE, Yaman D, Lang NP. Ridge augmentation by applying bioresorbable membranes and deproteinized bovine bone mineral: A report of twelve consecutive cases. *Clin Oral Implants Res* 2008;19:19–25.
22. Schlegel AK, Möhler H, Busch F, Mehl A. Preclinical and clinical studies of a collagen membrane (Bio-Gide). *Biomaterials* 1997;18:535–538.
23. Zitzmann NU, Naef R, Schärer P. Resorbable versus nonresorbable membranes in combination with Bio-Oss for guided bone regeneration. *Int J Oral Maxillofac Implants* 1997;12:844–852.
24. McGinnis M, Larsen P, Miloro M, Beck FM. Comparison of resorbable and non-resorbable guided bone regeneration materials: A preliminary study. *Int J Oral Maxillofac Implants* 1998;13:30–35.
25. Wang HL, Boyapati L. "PASS" principles for predictable bone regeneration. *Implant Dent* 2006;15:8–17.
26. Carpio L, Loza J, Lynch S, Genco R. Guided bone regeneration around endosseous implants with anorganic bovine bone mineral. A randomized controlled trial comparing bioabsorbable versus non-resorbable barriers. *J Periodontol* 2000;71:1743–1749.
27. Wang HL, Misch C, Neiva RF. "Sandwich" bone augmentation technique: Rationale and report of pilot cases. *Int J Periodontics Restorative Dent* 2004; 24:232–245.