

Medullary Paracoccidioidomycosis Treated Successfully with Oral Itraconazole

Paracoccidioidomicose medular tratada com sucesso com Itraconazol oral

Timóteo A. de L. Almeida¹ Adroaldo B. Mallmann¹ Paulo S. Crusius¹ Charles A. Carazzo¹
 Marcelo U. Crusius¹ Pedro Biasi¹ Matheus P. Brunet¹ Rafael Espanhol¹ Eduardo F. M. Baldissera¹
 Wellington Souza¹

¹Department of Neurology and Neurosurgery, Hospital São Vicente de Paulo, Passo Fundo, Rio Grande do Sul, Brazil

Address for correspondence Timóteo A. de L. Almeida, MD, Rua Paissandu 1973, Ap 204, Passo Fundo – RS, Brazil (e-mail: timoteo@dr.com).

Arq Bras Neurocir 2016;35:352–356.

Abstract

Keywords

- ▶ medullary paracoccidioidomycosis
- ▶ central nervous system infection

Resumo

Palavras-chave

- ▶ paracoccidioidomicose medular
- ▶ infecção do sistema nervoso central

Paracoccidioidomycosis is the most prevalent endemic mycosis in Latin America, with a great incidence in Brazil. Although a common disease, its medullary form is rare. We present a case report of medullary paracoccidioidomycosis presenting with subacute, progressive, spinal cord symptoms, and with multiple expansive lesions into the cervical and thoracic spinal cord. The patient was treated with itraconazole and showed good clinical and radiologic recovery upon six months of follow-up.

Paracoccidioidomicose é a micose endêmica de maior prevalência na América Latina, com grande incidência no Brasil. Apesar de comum, sua forma medular é rara. Apresentamos um relato de caso de paracoccidioidomicose medular apresentando sintomas subagudos e progressivos na medula, com múltiplas lesões expansivas na medula, cervical e torácica. O paciente foi tratado com itraconazole e apresentou melhora clínica e recuperação radiológica após seis meses.

Introduction

Paracoccidioidomycosis is a chronic granulomatous infection caused by *Paracoccidioides brasiliensis* and *Paracoccidioides lutzii* (a round-to-oval, multibudding yeast form). It is believed that the incidence of Paracoccidioidomycosis ranges between 3 per million to 3 per 100,000 per year.¹ The disseminated form of the disease commonly affects men in rural areas, between 30 and 50 years of age, from lower social classes, and is the most prevalent endemic mycosis in South America, with its highest inci-

dence occurring in Brazil, followed by Colombia and Venezuela.^{2–4}

The central nervous system involvement appears as one of two forms: the meningeal form and the granulomatous or pseudotumoral form. The latter is present in more than 10% of cases, ranging from 1 to 27.7% in the Brazilian series.^{5,6} It was first described by Pereira and Jacobs in 1919. In turn, the medullary form was described by Braga and Okamura in 1973.^{7,8}

We present the case of a 41-year-old male patient diagnosed with paracoccidioidomycosis with the involvement of

received
 September 14, 2015
 accepted
 December 1, 2015
 published online
 March 2, 2016

DOI <http://dx.doi.org/10.1055/s-0035-1571267>.
 ISSN 0103-5355.

Copyright © 2016 by Thieme-Revinter Publicações Ltda, Rio de Janeiro, Brazil

License terms



the spinal cord, and treated with itraconazole showing a good outcome.

Case Report

A 41-year-old man, military police, presented to our service referring paresis of the left lower limb, crural paraparesis, as well as ataxia. He denied fever and had no other complaints. His medical history was marked by prior smoking (20 packs/year) but was currently abstinent, without other comorbidities. There was nothing noteworthy in his family history. Moreover, he denied contact with any suspected lung disease patient.

The patient was in a good general condition and his neurological exam showed a left lower limb paresis grade IV, crural paraparesis for light tactile stimulation, bilateral patellar hyperreflexia, Hoffmann sign in the left upper limb and sensory ataxia.

Cervical and thoracic spine magnetic resonance imaging (MRI) showed two isointense lesions on T1-weighted images,

with hyperintense perilesional halo and hyperintense spinal cord signal suggestive of myelopathy on T2-weighted images, and homogeneous enhancement after gadolinium administration (►Fig. 1). A chest radiography performed upon admission revealed diffuse micronodules of the bilateral lung parenchyma, while a tomographic scan of the chest showed diffuse bilateral micronodules and typical ground-glass attenuation, suggesting fungal infection (►Fig. 2). The study of cerebrospinal fluid and general serum tests were both nonspecific. The patient received dexamethasone, with partial recovery of his deficit.

The patient was then submitted to a bronchoscopic lung biopsy. Histological analysis of the lung tissue showed a “non-necrotizing granulomatous pneumonia,” with negative fungus and acid-fast bacilli research, putting in question the possibility of hypersensitivity or sarcoidosis. Due to the anatomopathological non-specificity and the radiological exams suggestive of fungal disease, the patient began drug treatment for paracoccidioidomycosis. Since he was in good overall condition, showing no weight loss or

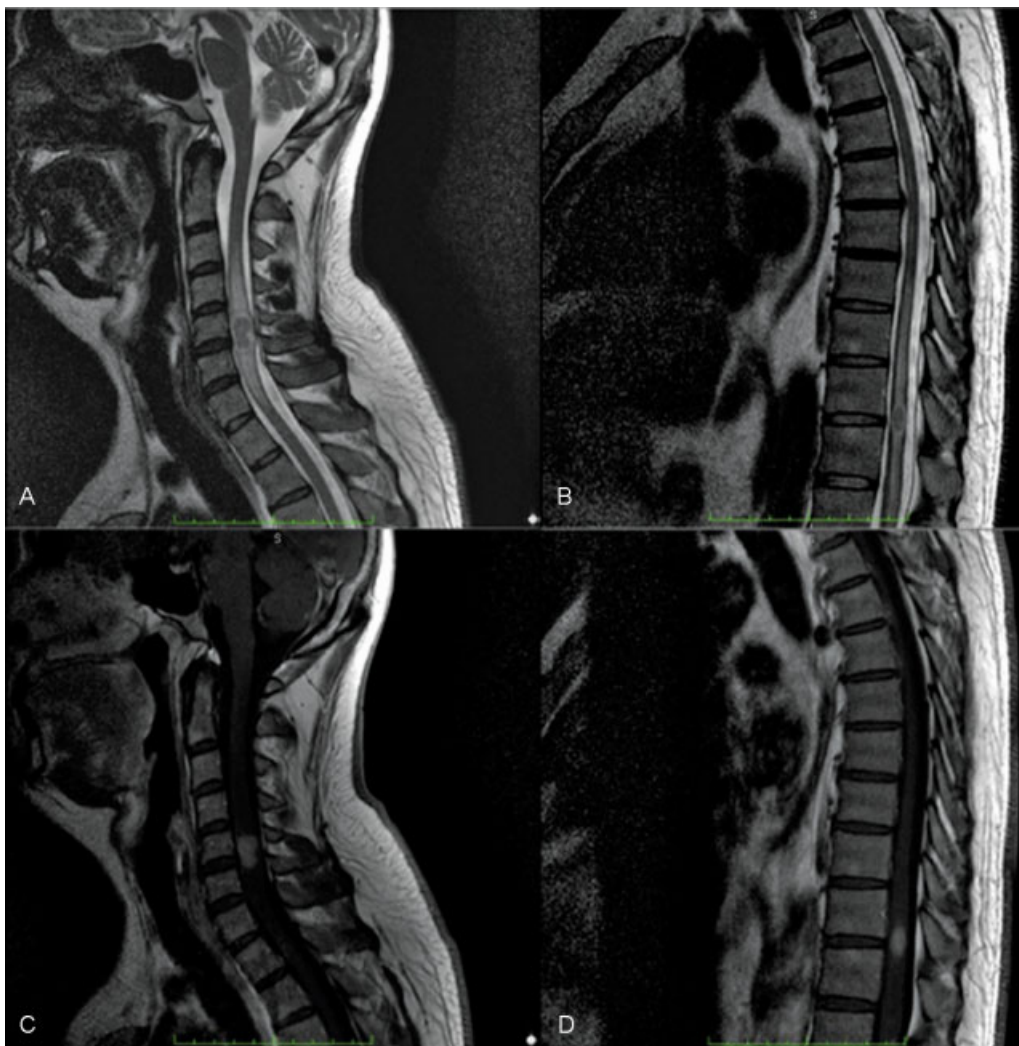


Fig. 1 MRI scan performed at admission shown an isointense lesion with a hyperintense halo and sign of myelopathy at T2-weighted sequence of the cervical (A) and thoracic (B) regions. After gadolinium administrations we observe homogeneous enhancement of both lesions (C and D).

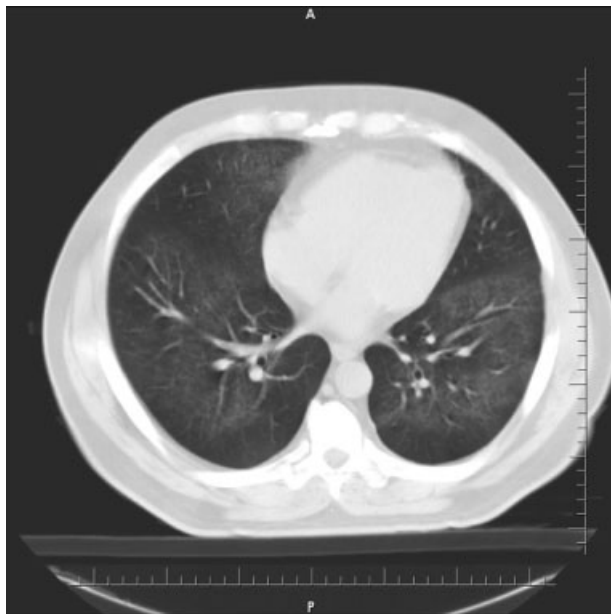

Fig. 2 Chest CT scan showing typical ground-glass attenuation of both lungs, suggestive of pulmonary paracoccidioidomycosis.

ventilatory distress, and his symptoms were less intense after corticosteroids, we decided to initiate treatment with itraconazole.

The patient gradually improved clinically, with improvement of strength in his left leg, and started walking with assistance by the end of a week of treatment. Chest radiography at the end of first week of treatment also showed improvement. After 13 days of treatment, we identified *P. brasiliensis* growth in the cultured lung tissue.

During the treatment, he developed a pain syndrome in his legs, being treated with amitriptyline and gabapentin. MRI scan of the cervical and the thoracic spine regions at two weeks and at one month after the start of treatment showed gradual improvement of the lesions.

We performed a control MRI scan six months after the treatment, which showed complete resolution of the lesions on T2-weighted images of the cervical and the thoracic spine regions, with small residual gliosis (► **Fig. 3**).

Discussion

Neuroparacoccidioidomycosis is a rare disease of difficult diagnosis, with a mortality rate greater than 50% in some studies, with almost all the reported cases consisting of surgical or autopsy findings.^{2,5} A recent study of 422 patients with paracoccidioidomycosis diagnosed between 1980 and 1999 presented six cases (1.4%) of central nervous system involvement, two of them in the spinal cord. Paniago et al reported a series of 13 cases of neuroparacoccidioidomycosis while spinal cord involvement was present in 4 patients (30.7%).⁹

In a systematic review from 2009, there were 257 cases in 81 studies (Medline / Lilacs) on neuroparacoccidioidomycosis.¹⁰ Out of these patients, 93% were men, with chronic granulomatous form being the most frequently encountered. Spinal cord involvement was reported in 9.2% of these cases, with predominance of the thoracic segment. The diagnosis was confirmed by biopsy in 57.2% and the cerebrospinal fluid (CSF) analysis contributed to the diagnosis in only 16.3% of such cases. The higher prevalence of disease in men could be explained by the inhibitory action of estrogens on the transformation of the conidia to the yeast form.¹¹

Neuroparacoccidioidomycosis diagnosis is difficult because of nonspecific changes in routine exams. CSF analysis may show mild pleocytosis or high protein concentration. The direct examination of the CSF rarely demonstrates *P. brasiliensis*.⁵ Studies with gp43 and gp70 antigen in serum or CSF showed high sensitivity in patients with neuroparacoccidioidomycosis. In our case, chest radiography helped us in achieving the correct diagnosis with demonstration of suggestive findings of fungal infection.³

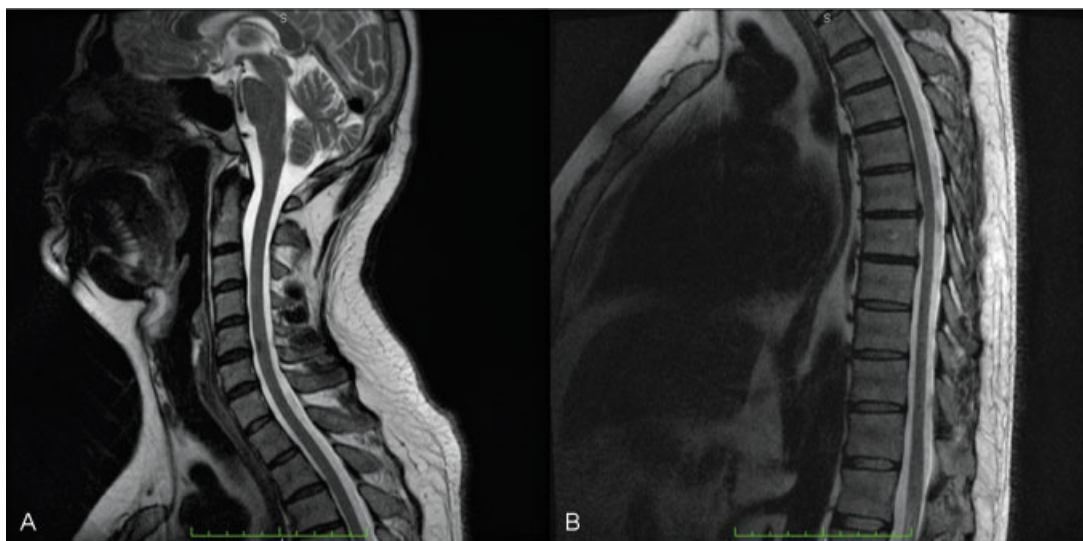


Fig. 3 MRI scan 6 months after treatment showing the complete remission of the lesions on T2-weighted images of the cervical and thoracic spinal cord.

The MRI scan is characterized by a variable signal on T1-weighted images and hypointense signal on T2-weighted images, with peripheral edema and nodular or ring enhancement after contrast administration.^{10,12} The main differential diagnosis is with intramedullary tumor which may present similar radiological patterns. In the patient described in this report, the shape and multiplicity of lesions helped in the diagnosis and therapeutic decision, which led us to think of an inflammatory or infectious disease as a possible diagnosis. Evolutive computed tomography (CT) scan in patients with neuroparacoccidioidomycosis showed disappearance of the lesions in 30.8%, reduction of lesions in 15.4%, and no change in 38.5%.² In addition to the standard neuroradiological scans, micronodules on chest radiography also suggested the hypothesis of fungal disease as a possible etiology.

In the Pubmed and LILACS databases we found thirteen reports describing eighteen cases of medullary paracoccidioidomycosis. We also found one case not indexed in the two databases, the first case being of medullary infection by *Paracoccidioides brasiliensis* described in the literature, and one case of extradural spinal cord compression.^{2,4,6-10,12-17} Of the nineteen cases described, the majority underwent laminectomy and approach to the expanding lesion. The medical treatment used anfotericin B in three cases, anfotericin plus sulfadiazine in one case, only sulfadiazin in two cases, sulfamethoxazole plus trimethoprim in two cases, sulfamethoxazole plus trimethoprim plus fluconazole in one case, only fluconazole in one case, and cetaconazole in one case. In eight cases, we could not find the drug of choice. Functional recovery was poor or unchanged in the majority of the cases described.

As we note in almost all the reports of medullary paracoccidioidomycosis, the majority of the patients undergo neurosurgical procedure, with the correct diagnosis appearing after the anatomopathological analysis. The outcome would probably be better if the correct diagnosis could be performed previously and the treatment started as soon as possible.

We found reports of pain during the drug treatment, similar to that presented by our patient, which was considered to be due to inflammatory reaction exacerbated by the death of the fungus.¹⁶ In the present case, we treated the patient with amitriptyline and gabapentin, also showing good result.

The treatment of systemic paracoccidioidomycosis is based on the severity of the disease. Itraconazole 200 mg per day for adults, for a period of 6 to 18 months or sulfamethoxazole plus trimethoprim 800/160 or 1200/240 mg twice a day for 12 to 24 months is recommended for mild to moderate cases, while anfotericin B or IV sulfamethoxazole plus trimethoprim is indicated for severe disease until clinical improvement. For central nervous system disease it is recommended to treat as a severe disease, without specifying intracranial or medullary cases. The serology analysis is highly recommended not only for diagnosis but also for follow-up, preferably at a level inferior to 1:2 of anti-*P. brasiliensis* antibodies after treatment.¹

Some authors advocate surgical treatment in neuroparacoccidioidomycosis for cases in which the granuloma is accessible, in which the symptoms do not show improve-

ment with medical treatment, or in which a quick solution to the problem becomes necessary with early surgical treatment being recommended in the case of progressive spinal cord compression.¹⁷ We also found a recent report of a patient with cerebral neuroparacoccidioidomycosis treated with intralesional therapy with amphotericin B for 4 weeks with satisfactory results.⁶

Conclusion

Medullary paracoccidioidomycosis is a rare condition, with only nineteen cases described in literature. It is difficult to diagnose with potentially high morbidity and mortality. As the literature review suggests, clinical suspicion is the most important point for the correct diagnosis and optimal therapeutic management in patients afflicted by the condition.

We presented a case of medullary paracoccidioidomycosis with good results after treatment with oral itraconazol, with evidence of functional and radiological recovery. In this report, the main differential diagnosis was with intramedullary tumor, which may present a similar clinical and radiological presentation, making it difficult to define the correct diagnosis.

Early diagnosis and appropriate treatment are critical for a functional recovery of these patients.

Disclosure

The authors report no conflict of interest concerning the materials or methods used in this study or the findings specified in this paper.

Author contributions to the study and manuscript preparation include the following. Conception and design: Almeida and Mallmann. Acquisition of data: Almeida. Analysis and interpretation of data: Almeida and Mallmann. Drafting the article: all authors. Critically revising the article: all authors. Reviewed submitted version of manuscript: all authors. Approved the final version of the manuscript on behalf of all authors: Almeida.

References

- Shikanai-Yasuda MA, Telles Filho FdeQ, Mendes RP, Colombo AL, Moretti ML. [Guidelines in paracoccidioidomycosis]. *Rev Soc Bras Med Trop* 2006;39(3):297-310
- Fagundes-Pereyra WJ, Carvalho GTC, Góes AM, das Chagas Lima e Silva F, de Sousa AA. [Central nervous system paracoccidioidomycosis: analysis of 13 cases]. *Arq Neuropsiquiatr* 2006;64(2A):269-276
- Minguetti G, Madalozzo LE. Paracoccidioidal granulomatosis of the brain. *Arch Neurol* 1983;40(2):100-102
- Paniago AMM. Paracoccidioidomycose: estudo clínico e epidemiológico de casos atendidos no HU-UFMS [dissertation]. Campo Grande (MS): Instituto Oswaldo Cruz/UFMS; 2000
- Lorenzoni PJ, Chang MR, Paniago AMM, Salgado PR. [Paracoccidioidomycosis meningitis: case report]. *Arq Neuropsiquiatr* 2002; 60(4):1015-1018
- Teixeira MJ, Fonoff ET, Machado LdosR, Nóbrega JPS, Sterman-Neto H, Amorim RL. Paracoccidioidomycosis: intralesional therapy. *Arq Neuropsiquiatr* 2010;68(3):458-459

- 7 Pereira JM, Jacobs F. Um caso de blastomicose com acessos epilepticos. *An Paul Med Cir* 1919;10:217-219
- 8 Braga FM, Okamura M. Blastomicose medular. *Seara Med Neurocir* 1973;1:435
- 9 Paniago AM, de Oliveira PA, Aguiar ES, et al. Neuroparacoccidioidomycosis: analysis of 13 cases observed in an endemic area in Brazil. *Trans R Soc Trop Med Hyg* 2007;101(4):414-420
- 10 Pedroso VSP, Vilela MdeC, Pedroso ERP, Teixeira AL. [Paracoccidioidomycosis compromising the central nervous system: a systematic review of the literature]. *Rev Soc Bras Med Trop* 2009;42(6):691-697
- 11 Sano A, Miyaji M, Nishimura K. Studies on the relationship between paracoccidioidomycosis in ddY mice and their estrous cycle. *Mycopathologia* 1991;115(2):73-81
- 12 Magalhães AC, Bacheschi LA, Caramelli P, et al. [Paracoccidioidomycosis of the central nervous system: study of 5 cases by magnetic resonance]. *Rev Hosp Clin Fac Med Sao Paulo* 1993;48(2):94-97
- 13 Lutz A. Uma micose pseudo-coccidea localizada na nuca e observada no Brasil: contribuição ao conhecimento das linfoblastomicoses americanas. *Bras Med* 1908;22:121-124
- 14 Francesconi F, da Silva MT, Costa RL, et al. Long-term outcome of neuroparacoccidioidomycosis treatment. *Rev Soc Bras Med Trop* 2011;44(1):22-25
- 15 Pacheco RAB, Arruda WO, Hunhevicz SC, Tsubouchi MH, Torres LFB. Thoracic intraspinal Paracoccidioidomycosis. Case report. *Arq Neuropsiquiatr* 1996;54(3):474-478
- 16 Moura LPM, Raffin CN, del Negro GMB, Ferreira MS. Paracoccidioidomycosis evidencing spinal cord involvement successfully treated by fluconazole. *Arq Neuropsiquiatr* 1994;52(1):82-86
- 17 Colli BOC, Assirati Júnior JA, Machado HR, et al. Intramedullary spinal cord paracoccidioidomycosis. Report of two cases. *Arq Neuropsiquiatr* 1996;54(3):466-473