

## REVIEW ARTICLE

**Colonoscopy: Art or science?**

Ian C Roberts-Thomson and Edward Teo

Department of Gastroenterology and Hepatology, The Queen Elizabeth Hospital, Woodville South, South Australia 5011 Australia

**Key words**

Colonoscopy, endoscopic techniques, cecal intubation, difficult procedures.

Accepted for publication 22 October 2008.

**Correspondence**

Professor IC Roberts-Thomson, Department of Gastroenterology and Hepatology, The Queen Elizabeth Hospital, 28 Woodville Road, Woodville South SA 5011, Australia. Email: ian.roberts-thomson@health.sa.gov.au

**Abstract**

The focus on colorectal neoplasia has led to an exponential increase in the use of colonoscopy in many countries. Although colonoscopy facilitates the diagnosis and treatment of colonic disease, there are public health issues that include access, training, diagnostic accuracy, complications and additions to health-care costs. Because of this, colonoscopists have a responsibility to ensure that the procedure is appropriate, safe and of high-quality. This article addresses the issue of variation in technical skills that is known to exist within the endoscopic community, even among individuals with similar experience. While some of this variation reflects innate manual dexterity, another aspect is variation in the adoption of technical manoeuvres that facilitate various aspects of the procedure including rates for cecal intubation. Although technical manoeuvres are difficult to evaluate in controlled trials, there is persuasive data that high cecal intubation rates can be achieved by minimizing inflation and looping in the sigmoid colon and by the appropriate use of positional changes and abdominal pressure. In difficult settings, there is also benefit from the use of non-standard endoscopes and various accessories including overtubes.

**Introduction**

Colonoscopy can be a challenging procedure for both the patient and the colonoscopist. For the patient, the procedure can be prolonged and painful and a minority have major concerns about potential complications such as perforation and bleeding. For the colonoscopist, difficult procedures can be stressful and may involve decisions that balance the risk of complications against the likelihood of successful completion of the procedure.

One important variable is the use of analgesia.<sup>1,2</sup> This issue will be addressed in a future review article in this Miniseries. In relation to colonoscopy, some centers use sedation in only a minority of patients. In other centers, sedation is used in most patients although this varies from moderate (conscious) sedation using midazolam and fentanyl (or meperidine) to unconscious sedation that often includes the use of propofol. These sedatives are usually given by the colonoscopist but, for unconscious sedation, some institutions have insisted on the use of anesthetists or anesthetic assistants. These additional personnel may well facilitate sedation in selected patients but also contribute to costs.

The use of analgesia can also influence the technical aspects of the procedure. For example, with unconscious sedation, endoscopists may be prepared to 'push through' sigmoid loops whereas alternative techniques may be examined when patients who are only mildly sedated complain of pain. Another effect of unconscious sedation is greater difficulty with changing the position of the patient. Although unconscious sedation may permit more forceful pushing during insertion of the colonoscope, there is

no clear evidence that this is associated with higher rates for perforation.

**Is there a problem?**

Although there are a number of indicators of competence, most attention has been directed to rates of intubation of the cecum. Targets established by the US Multidisciplinary Task Force on Colorectal Cancer include cecal intubation rates of 90% in symptomatic patients and 95% in asymptomatic (screening) individuals.<sup>3</sup> These different targets reflect the inclusion of more elderly patients with comorbidities within the symptomatic group. While many colonoscopists claim cecal intubation rates above these targets, there are real pathological and anatomical reasons why this cannot reach 100%. The pathological reasons include obstructing cancers and tight strictures associated with diverticulitis and Crohn's disease. Colonoscopy can also be risky in the presence of complex hernias<sup>4</sup> and is either difficult or impossible with anatomical variants such as the Chilaiditi syndrome or colonic malrotation.<sup>5</sup>

There are now several reports of cecal intubation rates in a variety of clinical settings. In a multicenter study in the USA, 45% of 69 colonoscopists had cecal intubation rates of less than 90% while 9% had cecal intubation rates of less than 80%.<sup>6</sup> In the UK, even lower cecal intubation rates (77%) were recorded among a group of colonoscopists that included gastroenterologists, training registrars, surgeons and radiologists.<sup>7</sup> In Canada, a large study reported an overall cecal intubation rate of 87% with lower

frequencies for low-volume endoscopists and for those procedures performed in community hospitals or private offices.<sup>8</sup> In the USA, however, community gastroenterologists had similar intubation rates to those in academic centers.<sup>9</sup> In Australia, intubation rates (self-reported) were 96% in procedures performed in a pilot study for the National Bowel Cancer Program.<sup>10</sup> However, these procedures were mostly performed by experienced colonoscopists in a limited number of centers.

On-going concerns about the quality of colonoscopy have led to national initiatives in some countries. In the UK, this includes the identification of training centers, publication of a curriculum and the identification of domains that are relevant to the development of endoscopic skills.<sup>11</sup>

### The difficult procedure

There is no satisfactory definition of the difficult procedure. Colonoscopy can be difficult for the endoscopist because the procedure is prolonged, difficult for the patient because of pain or difficult in both areas. Perhaps a practical but qualitative definition is a procedure where the endoscopist struggles or fails to reach the cecum.<sup>12</sup> For colonoscopists with average experience (e.g. 1000–5000 procedures), this will apply in 5–20% of cases.

Factors that influence the degree of difficulty of the procedure include the adequacy of bowel preparation, the training and experience of the operator and patient factors that include colonic angles and loops and the presence of colonic disease.<sup>13</sup> In a study that assessed difficulty by cecal intubation time, independent factors predicting prolonged times were advanced age, female gender, low body mass index, poor bowel preparation and higher pain scores.<sup>14</sup> In another study, failure to reach the cecum was more common in women, particularly those who had previously had an abdominal hysterectomy.<sup>15</sup> When the degree of difficulty is assessed by pain, higher scores are recorded in women<sup>16</sup> and some studies have shown additional independent risk factors including younger age, low body mass index, prolonged procedures and previous pelvic surgery.<sup>17</sup> Other studies have also shown a close relationship between higher pain scores and prolonged insertion times.<sup>18</sup>

Colonic features associated with difficult colonoscopy have been examined by subsequent barium enema studies. In one study that compared colonic measurements in those with and without difficult colonoscopy, the difficult procedures were associated with greater total colonic length (157 cm vs 140 cm) and greater rectosigmoid length (61 cm vs 54 cm). In addition, the difficult group had a more mobile transverse colon that was more likely to dip into the true pelvis on an erect film (65% vs 17%).<sup>19</sup> Comparisons of barium enema measurements between men and women have also shown that women have a longer colon as well as a longer transverse colon that is more likely to dip into the true pelvis.<sup>20</sup> The association with previous pelvic surgery has been attributed to pelvic adhesions, perhaps causing sharper angulation at the rectosigmoid junction and a higher frequency of sigmoid loops.

In contrast, rapid cecal intubation times by some Asian endoscopists have raised the possibility that the Oriental colon is easier to colonoscope than its Western counterpart. When measurements are taken at laparotomy, Oriental and Western patients have a similar colonic length but the latter have more sigmoid adhesions

and greater colonic mobility.<sup>21</sup> An additional difference is the prevalence and location of diverticulosis. This is focussed on the sigmoid colon in Western subjects but tends to occur in the right colon in at least some Oriental populations.<sup>22</sup>

### Levels of evidence

Theoretically, it should be possible to justify the use of a particular technique on the basis of randomized trials. In the case of the difficult colon, no such trials exist. This presumably reflects the complex nature of the difficult colon that is determined by a number of variables that apply to both the patient and the endoscopist. In addition, it is difficult to identify two or more specific technical manoeuvres that could be readily compared in randomized trials. Currently, levels of evidence are low and are based on cecal intubation rates with different endoscopes or accessories and individual success rates in patients in whom colonoscopy was previously incomplete.

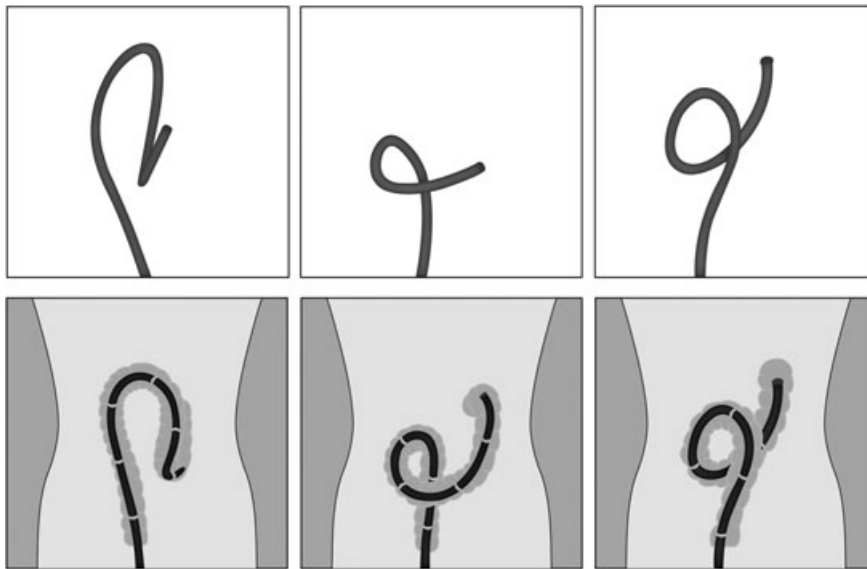
### Making the difficult colon easier

#### General principles

The length of the adult colon varies from 91 cm to 125 cm.<sup>23</sup> The colon is relatively fixed in the cecum, ascending colon, descending colon and rectum but both the transverse colon and sigmoid colon are much more mobile because of the presence of a mesentery (mesocolon). Because of this, the most common causes of incomplete colonoscopy are looping (largely in the sigmoid colon) and redundancy (largely in the transverse colon). The other major cause is sigmoid abnormalities including strictures, angulation and diverticulosis.<sup>12,13</sup> Many of these potential problems can be avoided by a sound technique that includes shortening the colon after negotiation of each curve and avoiding excessive inflation. This often includes the use of a rapid in and out motion (jiggle) and the application of a clockwise torque during shortening, particularly in the sigmoid colon. Advancement of the colonoscope using a blind, slide-by manoeuvre should be rare but is occasionally necessary for sharp angulation at either the rectosigmoid junction or the sigmoid-descending colon junction. The two most reliable criteria for intubation of the cecum are visualization of the ileocecal valve and visualization of the appendiceal orifice. When the colonoscope is withdrawn without loops, the cecum, hepatic flexure, splenic flexure, sigmoid-descending junction and rectosigmoid junction lie at approximately 70 cm, 50 cm, 40 cm, 30 cm and 15 cm from the anal verge, respectively.<sup>24</sup>

#### Colonic loops

The formation of loops during colonoscopy can be confirmed by either fluoroscopy or magnetic endoscope imaging. The most common sigmoid loops are the N loop, alpha loop and reverse alpha loop as illustrated in Fig. 1. Using magnetic endoscope imaging, a study from the United Kingdom reported the formation of N loops, alpha loops and reverse alpha loops in 79%, 12% and 11% of patients, respectively.<sup>25</sup> In a subsequent study from Japan, experienced endoscopists created N loops, alpha loops and reverse alpha loops in 47%, 12% and 6% of patients, respectively.<sup>26</sup> Pain scores were assessed in the absence of sedation and were higher in



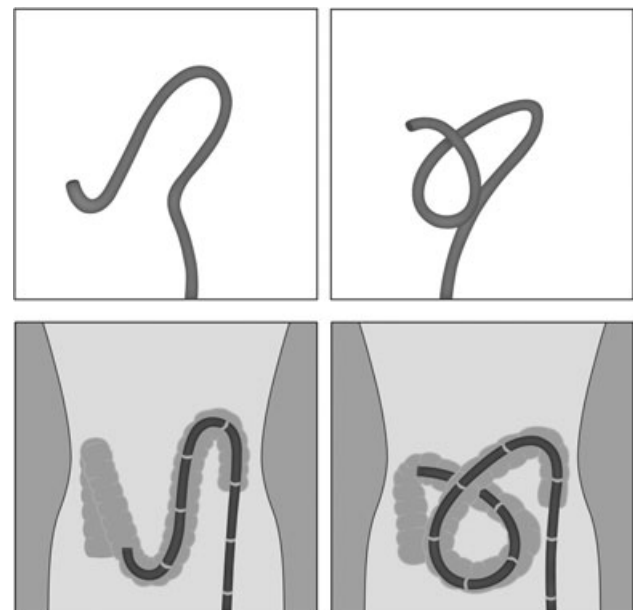
**Figure 1** Illustrations of the creation of an N loop (left), alpha loop (central) and reverse alpha loop (right) in the sigmoid colon. The upper panels show the magnetic imager view (antero-posterior) while the lower panels include an outline of the sigmoid colon.

those patients with loops, particularly the reverse alpha loop. However, the identification of loops did not necessarily result in a significant reduction in pain scores. In other studies in the difficult colon, only one of two studies showed that routine fluoroscopy facilitated cecal intubation and reduced the duration of the procedure.<sup>27,28</sup>

Various techniques have been adopted to correct loop formation. For N loops, shortening the colonoscope and aspirating excessive air is often sufficient. For alpha and reverse alpha loops, the recommendation is clockwise and anti-clockwise torque, respectively, during withdrawal of the endoscope. These manoeuvres may be best performed with the tip of the endoscope in the transverse colon and may involve withdrawal of the endoscope from the transverse colon into the descending colon. Interestingly, formal correction of an alpha loop may be uncommon if clockwise torque is applied during negotiation of the sigmoid colon.<sup>24</sup>

Another interesting option that may facilitate passage of the endoscope through the sigmoid colon is distension of the sigmoid with 200–300 ml of water rather than air.<sup>29,30</sup> This technique appears to minimize inflation of the sigmoid colon and stretching of the mesentery. In one study, time for cecal intubation and analgesic requirements were lower in the ‘water immersion’ group than in the ‘air’ group although the effect was largely restricted to trainees rather than consultants.<sup>30</sup>

In the transverse colon, colonoscopy can be difficult because of a redundant loop that dips into the pelvis or because of the creation of a gamma loop (Fig. 2). The effects of these loops can be either difficulty negotiating the transverse colon or, more commonly, an inability to reach the cecum despite insertion of the total length of the colonoscope. The latter is usually the result of a coexisting loop in the sigmoid colon that can often be corrected by rotation and withdrawal. Other helpful measures include the liberal use of suction, gentle pressure and maintaining position within the colon by ‘hooking’ the tip of the colonoscope into colonic folds.<sup>24</sup>



**Figure 2** Illustrations of a long transverse colon that clips into the pelvis (left), sometimes with the creation of a gamma loop (right). The upper panels show the magnetic imager view (antero-posterior) while the lower panels include an outline of the transverse colon.

**Positional changes**

There appears to be wide variation among colonoscopists in the use of positional changes to facilitate either intubation of the cecum or views of the colon during withdrawal. During insertion, a change from the left lateral position to the supine position appears to facilitate negotiation of a difficult hepatic flexure (especially when

accompanied by suction) while a change to the right lateral position may facilitate passage of the colonoscope from the ileocecal valve into the cecal pole.<sup>12,13</sup> During withdrawal, a blinded videotape study compared colonic distension in patients restricted to the left lateral position to that in patients where positions were changed to facilitate distension (left lateral for the cecum to hepatic flexure, supine for the transverse colon and right lateral for the splenic flexure and descending colon). Overall, patients whose positions were changed had fewer areas of poor distension in the transverse colon, splenic flexure and descending colon.<sup>31</sup> This is at least partly consistent with data from computed tomography (CT) colonography that showed superior distension of the ascending colon, hepatic flexure and transverse colon when patients were in the supine position rather than the prone position and vice versa for the descending colon and sigmoid colon.<sup>32</sup> However, although detection rates for adenomas can correlate with the quality of inspection, one study showed similar detection rates for adenomas when colonoscopy withdrawal was performed with patients in the prone position rather than the left lateral or supine position.<sup>33</sup>

### Abdominal pressure

There are even fewer data to support the beneficial effects of abdominal pressure in the difficult colon. However, abdominal pressure appears to be widely used for limiting loop formation in the sigmoid and transverse colons. For sigmoid loops, pressure can be applied over the left iliac fossa with the patient in either the left lateral or supine position although the latter may be preferred. For the redundant transverse colon, pressure is usually applied to the upper abdomen with the patient in a supine position or may be applied over both the upper abdomen and the left iliac fossa. Although there are no studies that have compared cecal intubation rates with and without the use of abdominal pressure, one study showed that positional changes were more helpful for advancement of the endoscope than the application of abdominal pressure.<sup>25</sup>

### Different endoscopes and accessories

There is persuasive evidence that success rates for cecal intubation in the difficult colon can be improved by non-standard endoscopes. If the problem appears to be a narrow or angulated sigmoid colon, the best approach is to use either an upper gastrointestinal endoscope (diameter 8.6–9.2 cm) or a pediatric colonoscope (diameter approximately 10 mm). The former is more likely to negotiate the sigmoid colon but, because of its shorter length, intubation of the cecum can only be achieved in 60–70% of patients.<sup>34</sup> Using a pediatric colonoscope in patients with a difficult sigmoid colon, one study showed a cecal intubation rate of 58%.<sup>35</sup> Another option is to use an upper gastrointestinal endoscope to negotiate the sigmoid colon followed by placement of a guide-wire in the transverse colon that may facilitate passage of a pediatric colonoscope.<sup>13</sup>

If the difficult colon appears to be related to a redundant transverse colon, options include the use of an enteroscope,<sup>36</sup> a variable-stiffness colonoscope<sup>37,38</sup> or perhaps a single or double-balloon enteroscope.<sup>39</sup> In one study, use of a push-enteroscope was successful in 69% of patients who failed with a standard procedure,<sup>36</sup> while in another study, single-balloon enteroscopy was helpful in 14 patients with incomplete colonoscopy using either a standard or a

pediatric colonoscope.<sup>39</sup> Other endoscopes are in various phases of development including self-propelling colonoscopes.<sup>12</sup>

Accessories that may facilitate difficult colonoscopy or improve adenoma detection rates include the use of overtubes, largely in the sigmoid colon,<sup>13</sup> and the use of transparent caps on the tips of colonoscopes.<sup>40</sup> The former will largely be restricted to dedicated experts but the latter could be widely applied to flatten folds and enhance mucosal visualization. Indeed, caps have now been reported to facilitate cecal intubation,<sup>41</sup> decrease procedural pain<sup>26</sup> and increase detection rates for adenomas.<sup>42</sup> However, non-retractable caps do increase the degree of difficulty of retroflexion of the colonoscope in the rectum.

### Different drugs

When colonoscopy is difficult because of pain, a common response is to increase the dose of sedatives or to change to propofol. While this is often appropriate, it should not be used as an alternative to a careful review of endoscopic techniques. An additional consideration is the use of antispasmodic drugs such as hyoscine butylbromide (Buscopan). Some colonoscopists routinely administer antispasmodic drugs at the start of the procedure<sup>43</sup> while others use them rarely if at all.<sup>13</sup> The potential benefits of antispasmodic drugs include better colonic distension and mucosal visualization but this may be offset by enhanced loop formation. At present, there are no data to support the use of antispasmodic drugs in the setting of a difficult procedure. Another option for the difficult or prolonged procedure is inflation of the colon with carbon dioxide rather than air.<sup>44</sup> This does not influence the degree of difficulty of the procedure but does minimize the risk of bloating and abdominal pain during the recovery period.

### Summary

Colonoscopy is a relatively demanding procedure for the patient and can be a demanding procedure for the endoscopist. As a profession, we have a responsibility to ensure that the procedures are appropriate, safe and of high-quality. These aims can usually be achieved by training programs that include good tuition and adequate experience. However, endoscopic skills vary widely between endoscopists, even among those with similar experience. This may be partly related to innate manipulative skills but also reflects variation in the technical response to particular endoscopic issues. This article attempts to highlight those manoeuvres that may make the difficult colonoscopy not only easier but safer. Levels of evidence for most of these manoeuvres, however, are low and there may be more than one solution to at least some endoscopic problems. Endoscopists also need to recognize those patients who are best referred to a more expert colleague and those who can be adequately investigated by other procedures such as barium enema or CT colonography.

### References

- 1 Lichtenstein DR, Jagannath S, Baron TH *et al*. Sedation and anesthesia in GI endoscopy. *Gastrointest. Endosc.* 2008; **68**: 205–16.
- 2 Lubarsky DA, Candiotti K, Harris E. Understanding modes of moderate sedation during gastrointestinal procedures: a current review of the literature. *J. Clin. Anesth.* 2007; **19**: 397–404.

- 3 Rex DK, Bond JH, Winawer S *et al.* Quality in the technical performance of colonoscopy and the continuous quality improvement process for colonoscopy: recommendations of the U.S. Multi-Society Task Force on Colorectal Cancer. *Am. J. Gastroenterol.* 2002; **97**: 1296–308.
- 4 Shudo R, Saito T, Takahashi K, Horita K, Waku K, Aoyanagi Y. What's in a hernia? *J. Gastroenterol. Hepatol.* 2000; **15**: 565.
- 5 Bassan MS, Thomson A. Chilaiditi syndrome. *J. Gastroenterol. Hepatol* 2008; **23**: 499.
- 6 Cotton PB, Connor P, McGee D *et al.* Colonoscopy: practice variation among 69 hospital-based endoscopists. *Gastrointest. Endosc.* 2003; **57**: 352–7.
- 7 Bowles CJ, Leicester R, Romaya C, Swarbrick E, Williams CB, Epstein O. A prospective study of colonoscopy practice in the UK today: are we adequately prepared for national colorectal cancer screening tomorrow? *Gut* 2004; **53**: 277–83.
- 8 Shah H, Paszat LF, Saskin R, Stukel TA, Rabeneck L. Factors associated with incomplete colonoscopy: a population-based study. *Gastroenterology* 2007; **132**: 2297–303.
- 9 Rathgeber SW, Wick TM. Colonoscopy completion and complication rates in a community gastroenterology practice. *Gastrointest. Endosc.* 2006; **64**: 556–62.
- 10 The Australian Bowel Cancer Screening Pilot Program and Beyond. Final Evaluation Report. Department of Health and Ageing, October 2005.
- 11 Barton R. Accrediting competence in colonoscopy: validity and reliability of the UK Joint Advisory Group/NHS Bowel Cancer Screening Programme Accreditation Assessment. *Gastrointest. Endosc.* 2008; **67**: AB77.
- 12 Witte TN, Enns R. The difficult colonoscopy. *Can. J. Gastroenterol.* 2007; **21**: 487–90.
- 13 Rex DK. Achieving cecal intubation in the very difficult colon. *Gastrointest. Endosc.* 2008; **67**: 938–44.
- 14 Oh SY, Sohn CI, Sung IK *et al.* Factors affecting the technical difficulty of colonoscopy. *Hepato-Gastroenterology* 2007; **54**: 1403–6.
- 15 Cirocco WC, Rusin LC. Factors that predict incomplete colonoscopy. *Dis. Colon Rectum* 1995; **38**: 964–8.
- 16 Kim WH, Cho YJ, Park JY, Min PK, Kang JK, Park IS. Factors affecting insertion time and patient discomfort during colonoscopy. *Gastrointest. Endosc.* 2000; **52**: 600–5.
- 17 Park DI, Kim HJ, Park JH *et al.* Factors affecting abdominal pain during colonoscopy. *Eur. J. Gastroenterol. Hepatol.* 2007; **19**: 695–9.
- 18 Schutz SM, Lee JG, Schmitt CM, Almon M, Baillie JB. Clues to patient dissatisfaction with conscious sedation for colonoscopy. *Am. J. Gastroenterol.* 1994; **89**: 1476–9.
- 19 Saunders BP, Halligan S, Jobling C *et al.* Can barium enema indicate when colonoscopy will be difficult? *Clin. Radiol.* 1995; **50**: 318–21.
- 20 Saunders BP, Fukumoto M, Halligan S *et al.* Why is colonoscopy more difficult in women?. *Gastrointest. Endosc.* 1996; **43**: 124–6.
- 21 Saunders BP, Masaki T, Sawada T *et al.* A peroperative comparison of Western and Oriental colonic anatomy and mesenteric attachments. *Int. J. Colorectal Dis.* 1995; **10**: 216–21.
- 22 Miura S, Kodaira S, Shatari T, Nishioka M, Hosoda Y, Hisa TK. Recent trends in diverticulosis of the right colon in Japan: retrospective review in a regional hospital. *Dis. Colon Rectum* 2000; **43**: 1383–9.
- 23 Blankenhorn DH, Hirsch J, Ahrens EH Jr. Transintestinal intubation: technic for measurement of gut length and physiologic sampling at known loci. *Proc. Soc. Exp. Biol. Med.* 1955; **88**: 356–62.
- 24 Webb WA. Colonoscopy of the 'difficult' colon. *Am Surg* 1991; **57**: 178–82.
- 25 Shah SG, Saunders BP, Brooker JC, Williams CB. Magnetic imaging of colonoscopy: an audit of looping, accuracy and ancillary maneuvers. *Gastrointest. Endosc.* 2000; **52**: 1–8.
- 26 Sato K, Hirahata K, Fujinuma S, Kakemura T, Maetani I. Evaluation of patient pain during colonoscopy for types of looping between hood attached group and non-hood attached group: an analysis using magnetic endoscope imaging (MEI). *Gastrointest. Endosc.* 2008; **67**: AB77.
- 27 Cirocco WC, Rusin LC. Fluoroscopy. A valuable ally during difficult colonoscopy. *Surg. Endosc.* 1996; **10**: 1080–4.
- 28 Dickey W. Does fluoroscopic imaging still have a role in colonoscopy? *J. Clin. Gastroenterol.* 2004; **38**: 676–9.
- 29 Baumann UA. Water intubation of the sigmoid colon: water instillation speeds up left-sided colonoscopy. *Endoscopy* 1999; **31**: 314–17.
- 30 Leung CW, Kaltenbach TR, Wu KK, Soetikno RM, Friedland S. Water immersion vs conventional insertion: a randomized controlled trial showing promise for minimal-sedation colonoscopy. *Gastrointest. Endosc.* 2008; **67**: AB106.
- 31 East JE, Suzuki N, Arebi N, Bassett P, Saunders BP. Position changes improve visibility during colonoscope withdrawal: a randomized, blinded, crossover trial. *Gastrointest. Endosc.* 2007; **65**: 263–9.
- 32 Yee J, Kumar NN, Hung RK *et al.* Comparison of supine and prone scanning separately and in combination at CT colonography. *Radiology* 2003; **226**: 653–61.
- 33 Rex D, Cutler C, Lemmel G *et al.* Colonoscopic miss rates of adenomas determined by back-to-back colonoscopies. *Gastroenterology* 1997; **112**: 24–8.
- 34 Kozarek RA, Botoman VA, Patterson DJ. Prospective evaluation of a small calibre upper endoscope for colonoscopy after unsuccessful standard examination. *Gastrointest. Endosc.* 1989; **35**: 333–5.
- 35 Marshall JB. Use of a pediatric colonoscope improves the success of total colonoscopy in selected adult patients. *Gastrointest. Endosc.* 1996; **44**: 675–8.
- 36 Lichtenstein GR, Park PD, Long WB, Ginsberg GG, Kochman ML. Use of a push enteroscope improves ability to perform total colonoscopy in previously unsuccessful attempts at colonoscopy in adult patients. *Am. J. Gastroenterol.* 1999; **94**: 187–90.
- 37 Brooker JC, Saunders BP, Shah SG, Williams CB. A new variable stiffness colonoscope makes colonoscopy easier: a randomized controlled trial. *Gut* 2000; **46**: 801–5.
- 38 Horiuchi A, Nakayama Y, Kajiyama M, Fujii H, Tanaka N. Usefulness of a small-caliber, variable-stiffness colonoscope as a backup in patients with difficult or incomplete colonoscopy. *Am. J. Gastroenterol.* 2004; **99**: 1936–40.
- 39 May A, Nachbar L, Ell C. Push-and-pull enteroscopy using a single-balloon technique for difficult colonoscopy. *Endoscopy* 2006; **38**: 395–8.
- 40 Matsushita M, Hajiro K, Okazaki K, Takakuwa H, Tominaga M. Efficacy of total colonoscopy with a transparent cap in comparison with colonoscopy without the cap. *Endoscopy* 1998; **30**: 444–7.
- 41 Lee YT, Hui AJ, Wong VWS, Hung LCT, Sung JY. Improved colonoscopy success rate with a distally attached mucosectomy cap. *Endoscopy* 2006; **38**: 739–42.
- 42 Horiuchi A, Nakayama Y. Improved colorectal adenoma detection with a transparent retractable extension device. *Am. J. Gastroenterol.* 2008; **103**: 341–5.
- 43 Saunders B, Williams C. Premedication with intravenous antispasmodic speeds colonoscope insertion. *Gastrointest. Endosc.* 1996; **43**: 209–11.
- 44 Sumanac K, Zealley I, Fox BM *et al.* Minimizing postcolonoscopy abdominal pain by using CO<sub>2</sub> insufflation: a prospective, randomized, double blind, controlled trial evaluating a new commercially available CO<sub>2</sub> delivery system. *Gastrointest. Endosc.* 2002; **56**: 190–4.