

# Chromoblastomycosis due to *Cladosporium carrionii*

Namratha N, Shobha Nadgir, Mamatha Kale, Ravi Rathod<sup>1</sup>

Departments of Microbiology and <sup>1</sup>Skin and Venereal Diseases, Karnataka Institute of Medical Sciences, Hubli-580 022, India

**Address for Correspondence:** Dr. Namratha N, E-mail: dr\_namrathamicro@rediffmail.com

## ABSTRACT

An 81-year-old male presented with irregular verrucous growth of 6 years duration over the right leg. KOH preparation of the scrapings and histopathology of the lesion showed “sclerotic” bodies diagnostic of chromoblastomycosis. Culture on Sabouraud’s dextrose agar yielded *Cladosporium carrionii*.

**Keywords:** Chromoblastomycosis, *Cladosporium carrionii*, verrucous growth

DOI: 10.4103/0974-2727.66704

www.jlponline.org

## INTRODUCTION

Chromoblastomycosis is a chronic fungal infection of the skin and subcutaneous tissues, caused by pigmented fungi which produce characteristic “sclerotic” bodies in clinical material. Diagnosis of chromoblastomycosis requires the demonstration of sclerotic or “muriform” bodies in the clinical material. However, identification of the specific etiologic agents requires culture studies.<sup>[1]</sup> Most of the agents causing chromoblastomycosis are usually localized in the skin and subcutaneous tissue.<sup>[2]</sup> However, certain uncommon agents of chromoblastomycosis, such as *Cladosporium* species, are important to recognize, as they are associated with bad prognosis.<sup>[3-9]</sup> Here we present a case of chromoblastomycosis due to *Cladosporium* species.

## CASE REPORT

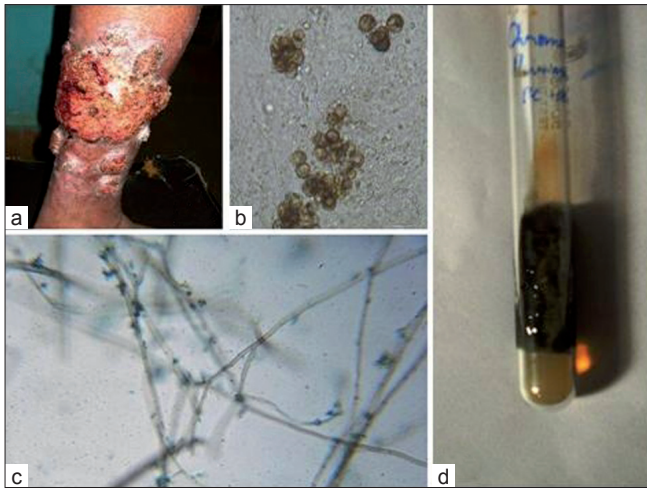
Eighty-one year old male patient, a priest by occupation and residing in a rural area, presented with large verrucous lesions over the lateral aspect of right leg since 6 years [Figure 1a] and smaller plaque of 1 year duration on the lower left leg. He complained of purulent and blood-stained discharge from the lesion, which was associated with pain and itching. To begin with, the lesion was small in size and gradually progressed to the present size. New crop of lesions occurred after 3 years. There was no history of trauma, and he appeared healthy with moderate built physique,

and there were no other associated illnesses. On local examination, there was a verrucous lesion measuring 15 × 10 cm with crusting, discharge and “satellite lesions” [Figure 1a]. On radiologic examination, the right leg did not reveal any bony involvement, but soft tissue irregularity was noted in lateral aspect of the leg.

His routine investigations were within normal limits. Direct microscopic examination of 10% KOH preparation of the scrapings and crusts from the lesions showed small, round, thick-walled, brownish septate sclerotic bodies measuring 6–12 μm [Figure 1b]. The specimen was inoculated on Sabouraud’s dextrose agar slant containing chloramphenicol and yielded small, smooth, folded olive black colonies after 2 weeks incubation at room temperature [Figure 1c]. The reverse side of the colony was jet black in color. Lactophenol cotton blue preparation of the colony revealed brown septate hyphae with lateral and terminal conidiophores of varying size, bearing ovoid, dark conidia in branching chain formation (*Cladosporium* type of sporulation) [Figure 1d]. The fungus was identified as *Cladosporium carrionii*. Histopathologic examination of the specimen revealed pseudoepitheliomatous hyperplasia, microabscesses with characteristic sclerotic bodies and giant cell response.

## DISCUSSION

The term “chromoblastomycosis” is exclusively used



**Figure 1:** (a) Showing verrucous lesion; (b) sclerotic bodies in KOH preparation ( $\times 40$ ); (c) Sabouraud's dextrose agar slant with small, smooth, folded olive black colonies and (d) lactophenol cotton blue preparation of the colony with brown septate hyphae and lateral and terminal conidiophores

for those fungal lesions which characteristically produce sclerotic bodies, are caused by dematiaceous fungi and belong to the group of "phaeohyphomycosis".<sup>[1]</sup> The etiologic agents include *Fonsecea pedrosoi*, *Fonsecea compacta*, *Phialophora verrucosa*, *C. carrionii* and *Cladosporium ajello*, *Botriomyces caespitosus* and *Rhinocladiella aquaspersa*. Newer agents include *Exophiala jeanselmei* and *Exophiala spinifera*. *F. pedrosoi* is the commonest agent of chromoblastomycosis and the uncommon agents are *Cladosporium* and *Rhinocladiella* species.<sup>[1]</sup> *C. carrionii*, though rare agents of chromoblastomycosis, are the frequently isolated agents in brain abscess syndrome usually caused by hematogenous dissemination.<sup>[3]</sup>

The fungus is ubiquitous, found everywhere in soil, on decaying vegetation and rotten wood; it gains entry into tissue through traumatic inoculation.<sup>[5]</sup> The disease is particularly highly prevalent in hot and humid climate of tropical and subtropical regions. Though the southern parts of India have a hot and humid climate, the disease is relatively uncommon, with only few published case reports.<sup>[5]</sup> The disease is more common in barefooted rural men involved in agriculture-related works and commonly involves the lower extremities.<sup>[1,3]</sup> The patient presented here was a priest by occupation and had a history of barefoot walking. The disease has a varied clinical presentation and may present at different stages of its evolution ranging from small ulcer, plaques, papulonodular lesion to cauliflower like warty masses and cicatricial forms.<sup>[6]</sup> Hence, this disease is confused for other clinical conditions such as tuberculosis verrucosa cutis and squamous cell carcinoma. The case presented here showed verrucous lesion and the associated satellite lesions could be explained by the lymphatic spread or autoinoculation of the agent or both.<sup>[1]</sup>

Chromoblastomycosis is a difficult to treat dermal mycosis and its diagnosis requires demonstration of sclerotic bodies in clinical material. Identification of specific etiologic agents requires mycological culture studies. Most of the etiologic agents produce only localized disease restricted to skin and subcutaneous tissue. However, despite many weeks or months following adequate surgical debridement and antifungal therapy for initial lesion, some agents such as *Cladosporium* species (*C. carrionii* and *Cladosporium trichoides*) are known to disseminate hematogenously to distant sites including brain to produce so called "brain abscess syndrome".<sup>[3,4]</sup> Many studies observed recurrence of brain abscess syndrome due to *Cladosporium* species, 15 months after initial surgical and medical therapy.<sup>[3,4,7-9]</sup> Hence, it is important to isolate the organism and to start aggressive antifungal therapy to prevent the above mentioned complications. In the present case, culture yielded *C. carrionii*. The patient was healthy, had no signs and symptoms attributable to brain abscess syndrome and the lesion was still localized to subcutaneous tissue. With aggressive antifungal therapy, latent potential dissemination and its complications can be prevented.

Our patient was treated with itraconazole orally for 6 months and has not shown any recurrences or complications.

High index of suspicion and prompt laboratory diagnosis will help in initiation of therapy at an early stage, and isolation of specific etiologic agent by culture may help prevent the latent complications.

## REFERENCES

- Rippon JW. Chromoblastomycosis. In: Wonsiewicz M, editor. Medical Mycology the pathogenic fungi and pathogenic Actinomycetes. 3<sup>rd</sup> ed. Philadelphia: W B Saunders Company; 1988. p. 276-96.
- Sharma NL, Sharma RC, Grover PS, Gupta ML, Sharma AK, Mahajan VK. Chromoblastomycosis in India. Int J Dermatol 1999;38:846-51.
- Fukushiro R. Chromoblastomycosis in Japan. Int J Dermatol 1983;22: 221-9.
- Diaz A, Pascal J, Monnin L, Bousquet C, Amat C, Michault A. Cerebral chromoblastomycosis. Neurochirurgie 1996;42:95-9.
- Yasmin AM, Raghuvanshi SR, Lanjewar DN. Cutaneous Chromoblastomycosis. Bombay Hosp J 2008;50:299-301.
- Carion A. Chromoblastomycosis. Ann N Y Acad Sci 1950;50:1255-81.
- Vyas MC, Joshi YR, Bhargava N, Joshi KR, Tanvar RK. Cerebral Chromoblastomycosis—a case report of cerebral abscess and brief review of literature. Indian J Pathol Microbiol 2000;43:81-5.
- Bagchi A, Aikat BK, Baura D. Granulomatous lesion of brain produced by *Cladosporium Trichoides*. J Indian Med Association 1962;38:602.
- Chandramukhi A, Ramadevi MG, Shankar SK. Cerebral *Cladosporiosis*- a neuropathological and microbiological study. Clin Neurol Neurosurg 1983;85:245-53.

Source of Support: Nil, Conflict of Interest: None declared.