

# Effect of Topical *Linum usitatissimum* on Full Thickness Excisional Skin Wounds

Shima Rafiee,<sup>1</sup> Noushin Nekouyan,<sup>1</sup> Sahar Hosseini,<sup>1</sup> Farhad Sarabandi,<sup>2</sup> Mehdi Chavoshi-Nejad,<sup>3</sup> Maryam Mohsenikia,<sup>4</sup> Soheila Yadollah-Damavandi,<sup>4</sup> Amin Seifae,<sup>1</sup> Ehsan Jangholi,<sup>4</sup> Dorna Eghtedari,<sup>1</sup> Hanieh Najafi,<sup>1</sup> and Soheil Ashkani-Esfahani<sup>1,\*</sup>

<sup>1</sup>Student Research Committee, Shiraz University of Medical Sciences, Shiraz, IR Iran

<sup>2</sup>Amiralmomenin Hospital, Islamic Azad University, Tehran, IR Iran

<sup>3</sup>Student Research Committee, Shahid Beheshti University of Medical Sciences, Tehran, IR Iran

<sup>4</sup>Young Researchers and Elite Club, Islamic Azad University, Tehran Medical Sciences Branch, Tehran, IR Iran

\*Corresponding author: Soheil Ashkani-Esfahani, Student Research Committee, Shiraz Medical School, Shiraz, IR Iran. Tel: +98-9173397040, E-mail: soashkani@gmail.com

Received 2016 May 12; Revised 2016 August 19; Accepted 2016 September 06.

## Abstract

**Background:** Wound healing includes processes such as cell migration, extracellular matrix deposition, remodeling, and angiogenesis. In addition, antioxidative and anti-inflammatory reactions play key roles in the process of wound healing. Previous studies showed that *Linum usitatissimum* (LU) had anti-inflammatory, antimicrobial, and antioxidant activities. LU also stimulates fibroblast proliferation in the skin tissue.

**Objectives:** Herein, we studied the effects of topical LU on the wound healing process in rat models, according to histomorphometrical and stereological parameters.

**Methods:** In this experimental study, 48 male rats (Wistar; 200 ± 20 grams) were randomly separated into four groups (n = 12): 5% LU gel-treated (E1), 10% LU gel-treated (E2), gel base-treated (C2), and the control group (C1), which received no treatment. A full thickness circular wound was created on the neck in each rat. At the end, the stereological evaluations, including wound closure rate, collagen, vascular and hair follicle density estimation, fibroblast proliferation, vascular length density, and mean diameter were performed. The data was analyzed, and P < 0.05 was considered statistically significant.

**Results:** The average of the wound areas, collagen bundle synthesis, vascularization, and hair follicles in the LU-treated groups were significantly higher than the control group (P < 0.05). According to the estimated parameters, the contrast between E1 and E2 was insignificant.

**Conclusions:** Overall, topical LU showed the potential to enhance the wound healing process and tissue regeneration. However, more studies, particularly clinical trials, are highly recommended on LU and its mixture with other healing agents to find more potent treatments.

**Keywords:** Wound Healing, Stereology, Histomorphometry, Herbal Medicine, *Linum usitatissimum*

## 1. Background

Wound repair is a complex and dynamic cascade of events involving various biochemical and cellular processes (1). Inflammation begins immediately after wound occurrence, by the release of leukotrienes, prostaglandins, and free radicals. Growth factors then regulate collagen deposition, epithelization, and angiogenesis in the cellular proliferation stage. Finally, tissue remodeling occurs and encompasses fibroblast proliferation and accumulation of collagen fibers (2-4). Anti-oxidative and anti-inflammatory reactions also play key roles in the progression of wound healing (2, 4).

One of the clinical impediments in the process of wound healing is infection (5). Studies on several plants

have confirmed that components such as phenolic compounds had potential antimicrobial and antiviral properties and also act as antioxidants to scavenge free radicals and inhibit lipid peroxidation (6, 7). On the other hand, herbal medicine has received much attention from researchers, due to its rare side effects and cost-effectiveness (8, 9).

Flax (*Linum usitatissimum*, LU), a member of the Linaceae family and a well-known, traditionally used herbal medicine, is an economically important oilseed crop cultivated worldwide. Many studies have shown the presence of biologically active compounds, such as  $\alpha$ -linolenic acid, unique proteins, lignans, flavonoids, and phenolic acids, which have many health benefits (10). This multitude of positive health benefits includes reducing

serum cholesterol level, decreasing the rate of tumor growth, and decreasing the incidence of prostate, breast, and colon cancers (11-14).

It has been demonstrated that omega 3 fatty acids and  $\alpha$ -linolenic acid have potential anti-inflammatory, antihistaminic, antimicrobial, and anti-bradykinin activities (15, 16). Other derivatives, such as phenylpropanoids and secoisolariciresinol diglucoside, have powerful antioxidant activities (17). In addition, linseed oil stimulates production of growth factors, fibroplasia, and neovascularization, that can affect the wound healing process (18-20).

## 2. Objectives

The current study was conducted to evaluate the healing effects of topical LU on full thickness skin wounds in rat models by using histomorphometrical and stereological methods.

## 3. Methods

### 3.1. Extraction of the Seeds and Preparation of LU Gel

LU seeds were obtained from the Medipress Herbarium of Shiraz, in southwest Iran (Code: 3101). Plant seeds were crushed and cold-macerated in petroleum ether (40 - 60°C; 7 days), which was then evaporated from the plant's extract. The oil was filtered until clarity and was stored at room temperature. The oil density was 0.931 g/mL, and the yield was 17.5% v/w of the fixed oils, with reference to dried seeds.

LU hydroalcoholic extract was produced. In order to facilitate the application, LU 5% and 10% gels were provided by dissolving 5 and 10 g LU in 2 cc distilled water, respectively. The solution was transferred into 2% carboxymethylcellulose (CMC; 2 g dissolved in 98 cc distilled water). The vehicle (gel base) was also supplied separately by the same method, but without the LU component. The concentrations of the herb were chosen according to a previously conducted pilot study in our center, by which the most effective dosages with the lowest concentrations were selected.

### 3.2. Animals and Excision of Wound Model

In this experiment, 48 female Wistar rats (200  $\pm$  20 g; 2 - 3 months old) were kept in standard cages with food and water ad libitum and randomly divided into four groups (n = 12): vehicle- (gel base) treated group, LU 5% gel-treated group, LU 10% gel-treated group, and the control group, which received no treatment.

On the first day, under general anesthesia induced by ether inhalation, a 1 cm<sup>2</sup> circular, full thickness skin wound

was made on the posterior surface of each rats's neck. The topical administration of gels was performed (gel base, LU 5%, and LU 10%) after creating the wounds and repeated every 24 hours, in a standard manner, until the last day of the study (day 15). The last day of the study was assigned as the day in which at least one of the wounds in any group was closed. The animals were sacrificed with a high dose of ether on day 15. Full thickness skin samples (1.5  $\times$  1.5 cm) were provided and fixed in buffered formaldehyde (pH = 7.2) for further evaluation.

The protocol of the study was approved by the medical ethics committee of Shiraz University of Medical Sciences, and the animal care was in accordance with the related guidelines.

### 3.3. Stereological Study

The area of the wound was measured every three days, starting from day 0, by using a digital photograph and a previously reported stereological method used by Ashkani-Esfahani et al. (21). For calibration of the magnification, in each photograph, a standard ruler was set at the level of the wound. All results were estimated by using stereology software composed of a point grid (Figure 1), and by using the following formula:  $\text{Area} = \sum P \times a/p$ ;  $\sum P$  were the total points laid on the wounded area, and  $a/p$  was the area surrounded by four crosses (area per point; mm<sup>2</sup>). Thereafter, the wound closure rate was calculated as wound closure rate (%) = ((area at visit 1 - area at each visit)/area at visit 1)  $\times$  100.

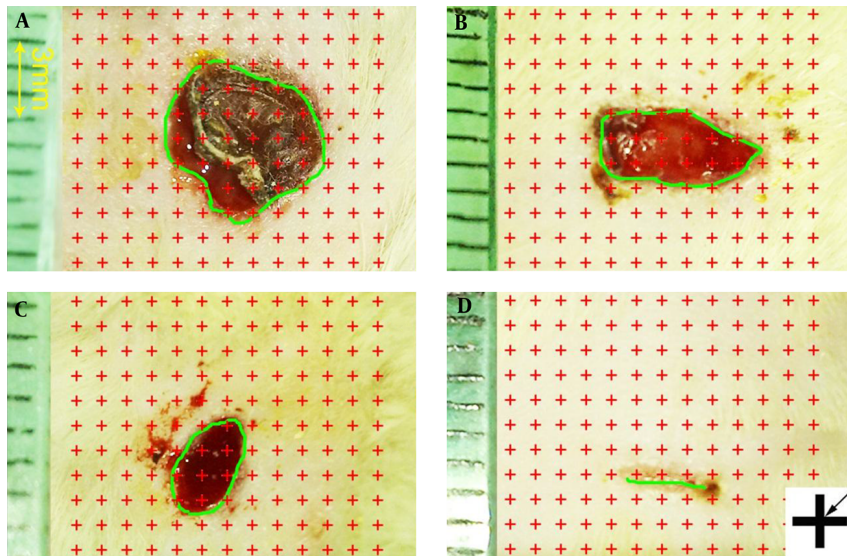
Nine random pieces of each skin sample, each about 1mm<sup>2</sup>, were cut and prepared for histomorphometrical analysis. The pieces of each sample were embedded in a paraffin block and sectioned by using the isotropic uniformly random sectioning (IUR) method, with 5 and 15  $\mu$ m thicknesses. All samples were stained with both H & E and Hedenhain's azan-trichrome stains for microscopic analysis.

The volume densities of the vessels, collagen bundles, and hair follicles ( $V_v$ ; fraction of the dermis which was occupied by the vessels, collagen bundles, or hair follicles) were estimated by using the stereological point counting method obtained from previously conducted research by Ashkani-Esfahani et al. (21).

The numerical density of the fibroblasts ( $N_v$ ; cell count per unit volume of the dermis) was estimated by using the 15  $\mu$ m slides and the "optical disector" method, which was acquired from research conducted by Khoshneviszadeh et al. (22).

### 3.4. Statistical Data Analysis

Results were reported as mean and standard deviation (mean  $\pm$  SD). SPSS statistical software (ver. 16.0) was used to



**Figure 1.** Stereological point counting method; samples of digital photographs were captured from the wound surfaces every other day to measure the wound area. The total number of points within the wound borders (green line) was counted. At the corner of this figure, a cross is present. The right upper corner of the cross is considered the point (arrow), and it is counted only if the right upper corner hits the wound surface. 1, day 1; 2, day 3; 3, day 4; 4, day 12.

perform the statistical comparisons between the groups. The statistical analyses were carried out by employing one-way ANOVA and Tukey's post hoc tests. Furthermore, a  $P$  value of  $\leq 0.05$  was noted as statistically significant.

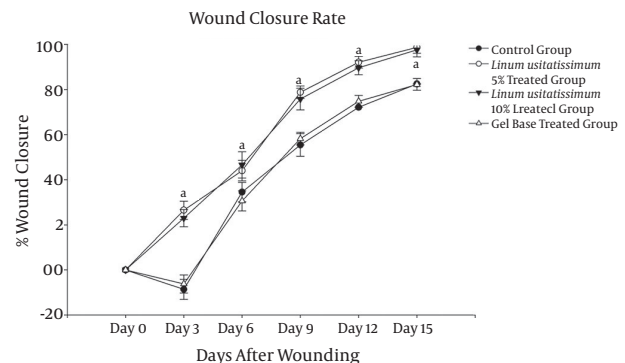
## 4. Results

### 4.1. Area of the Wounds

The initial mean wound area was  $103.73 \pm 5.21 \text{ mm}^2$  (range  $96.62 - 112.84 \text{ mm}^2$ ), with no significant difference among the four groups. However, the rate of wound closure in the LU 5% ( $9.43\%/ \text{day}$ ) and LU 10% ( $9.81\%/ \text{day}$ ) treated groups was significantly higher ( $P < 0.05$ ) in comparison to the base ( $4.93\%/ \text{day}$ ) and the control groups ( $4.43\%/ \text{day}$ ) (Figure 2). In addition, the group treated with the gel base revealed an insignificantly slower closure rate, compared to the control group. According to Figure 2, the wound areas in the gel base and control groups increased up to day 3, then decreased, with a slope almost similar to the LU-treated groups.

### 4.2. Fibroblast Population

The numerical densities of the fibroblasts in the dermis of the LU-treated groups were noticeably higher than those of the control and base groups. The numerical density of the fibroblasts in the LU 5%- and LU 10%-treated groups was  $56.8\%$  ( $P = 0.023$ ) and  $41.1\%$  ( $P < 0.034$ ) higher than the controls, respectively, and  $80.5\%$  ( $P = 0.009$ ) and



**Figure 2.** The effect of *Linum usitatissimum* (LU) on the wound closure rate. Groups consisted of the control, gel base-treated, and LU 5% and 10% concentrations gel-treated rats. Each point represents mean  $\pm$  SD of the 12 wounds. The letter "a" shows significant difference between LU 5%- or 10%-treated rats and the control or gel base-treated groups ( $P < 0.05$ ).

$62.29\%$  ( $P < 0.013$ ) higher than the base group, respectively (Table 1).

### 4.3. Volume Densities of the Collagen Bundles and Hair Follicles

The volume densities of the collagen bundles were significantly higher, by  $37.34\%$  ( $P = 0.001$ ) and  $39.94\%$  ( $P < 0.001$ ), in the LU 5%- and LU 10%-treated groups, in comparison to the control group (Table 1). In contrast with the gel-base group, the volume densities of the collagen bundles were significantly higher, by  $48.60\%$  and  $51.42\%$  ( $P < 0.001$ ),

**Table 1.** Mean + SD of the Fibroblasts' Numerical Density ( $\times 10^3$  per  $\text{mm}^3$ ), Volume Densities of the Hair Follicles (%), Collagen Bundles (%), and Vessels (%), Length Density ( $\text{mm}/\text{mm}^3$ ), and the Mean Diameter ( $\mu\text{m}$ ) of the Vessels in the Dermis of the Wounded Rats Treated With LU 5% and 10% Concentration Gels, Those Treated With Gel Base (Gel Base), and the Untreated Group (Control)

Groups	Fibroblasts	Collagen	Hair	Vessels		
	Numerical Density	% Volume Density	% Volume Density	% Volume Density	Length Density	Mean Diameter
Control	231.43 (19.12)	55.22 (2.45)	2.62 (1.42)	1.73 (0.98)	16.92 (9.03)	11.12 (1.78)
LU 5%	360.31 (113.16) <sup>a</sup>	72.88 (6.89) <sup>a</sup>	4.67 (2.12) <sup>a</sup>	2.21 (1.21)	38.28 (12.39) <sup>a</sup>	10.23 (2.59)
LU 10%	325.23 (89.44) <sup>a</sup>	75.31 (3.42) <sup>a</sup>	6.32 (2.13) <sup>a</sup>	2.33 (1.14)	38.89 (13.71) <sup>a</sup>	9.93 (4.12)
Gel base	202.42 (49.79)	48.33 (5.62)	2.78 (1.19)	1.82 (1.41)	16.92 (6.72)	11.31 (1.42)

<sup>a</sup>P < 0.05, versus control group and gel base group.

in LU 5% and LU 10%, respectively. The volume densities of the hair follicles in the LU 5%- and 10%-treated groups were significantly higher, in contrast with the gel base-treated group ( $P = 0.048$  and  $P = 0.033$ , respectively) and the control group ( $P = 0.034$  and  $P = 0.008$ , respectively).

#### 4.4. Volume Density, Length Density, and Diameter of the Vessels

The length densities of the vessels in the LU 5%- and 10%-treated groups were significantly higher, compared to the base group ( $P = 0.013$  and  $P = 0.007$ , respectively) and the control group ( $P = 0.015$  and  $P = 0.008$ , respectively). As shown in Table 1, there was no considerable contrast regarding the volume densities and mean diameters of the vessels between the LU-treated groups and control and gel base groups.

## 5. Discussion

The healing of skin wounds is a complicated process variety of cell types play roles during the proliferation process as well as migration, synthesis of the matrix, and wound contraction (10). Reduced cell and growth factor response, causing less peripheral blood flow and local angiogenesis, can lead to a delayed wound healing process in diabetics (23).

According to encompassing  $\alpha$ -linolenic acid and omega 3 fatty acid, LU has anti-inflammatory, antihistaminic, anti-bradykinin, antioxidant, and antimicrobial activities (24). de Souza Franco et al. (10) indicated LU's potential in repairing dermal wounds when it was used at low concentration by administering Line-seed oil (1%, 5%) in topical experimental excisional wounds. However, in our investigation, both 5% LU and 10% LU had equally significant effects. Albina et al. (25) found no significant differences in collagen deposition and the mechanical resistance of rat's skin to traction of the site of incision between the groups treated with line-seed oil and the

control group. Our results were similar to those of McDaniel et al. (26), whose study showed that, among many lipid inductors, PUFAs are the main principles engaged in the inflammatory response, which includes chemotaxis, vascular contraction, transmigration, adhesion, and cell activation, which are important functions in tissue repair.

The results of this study indicated that the LU can improve fibroblast proliferation, as well as collagen bundle synthesis and re-vascularization in excisional skin wounds. Considering the findings of the present study and previous reports on the effects of LU, this compound is assumed to have the ability to be introduced as a promising alternative treatment for full thickness skin wounds. However, we suggest more research, especially clinical trials, in order to compare this agent with other commonly occupied herbal and chemical medicines.

#### 5.1. Conclusions

According to our evaluations, topical LU showed the potential to enhance the wound healing process and tissue regeneration in the treatment of skin damage.

## Acknowledgments

The authors express their appreciation to M. Vahedi, Omid Koohi-Hosseinabadi, and all the personnel of the stem cell and transgenic technology research center, as well as Elham Nadimi and Ali Noorafshan for stereological and histomorphometrical studies.

## Footnote

**Funding/Support:** The research was supported by Islamic Azad University, Tehran medical branch, Tehran, Iran and Shiraz University of Medical Sciences, Shiraz, Iran.

## References

- Hosein Farzaei M, Abbasabadi Z, Reza Shams-Ardekani M, Abdollahi M, Rahimi R. A comprehensive review of plants and their active constituents with wound healing activity in traditional Iranian medicine. *Wounds*. 2014;**26**(7):197–206. [PubMed: 25856320].
- Sen CK, Roy S. Redox signals in wound healing. *Biochim Biophys Acta*. 2008;**1780**(11):1348–61. doi: 10.1016/j.bbagen.2008.01.006. [PubMed: 18249195].
- Fu X, Fang L, Li H, Li X, Cheng B, Sheng Z. Adipose tissue extract enhances skin wound healing. *Wound Repair Regen*. 2007;**15**(4):540–8. doi: 10.1111/j.1524-475X.2007.00262.x. [PubMed: 17650098].
- Süntar I, Akkol EK, Nahar L, Sarker SD. Wound healing and antioxidant properties: do they coexist in plants? *Free Radicals Antioxidants*. 2012;**2**(2):1–7.
- Barku VY, Opoku-Boahen Y, Owusu-Ansah E, Dayie N, Mensah FE. In-vitro assessment of antioxidant and antimicrobial activities of methanol extracts of six wound healing medicinal plants. *In Vitro*. 2013;**3**(1).
- Kumawat BK, Gupta M, Tarachand YS. Free radical scavenging effect of various extracts of leaves of *Balanites aegyptiaca* (L.) Delile by DPPH method. *Asian J Plant Sci Res*. 2012;**2**:323–9.
- Gandhiraja N, Sriram S, Meenaa V, Srilakshmi J, Sasikumar C, Rajeswari R. Phytochemical screening and antimicrobial activity of the plant extracts of *Mimosa pudica* L. against selected microbes. *Ethnobotanical leaflets*. 2009;**2009**(5):8.
- Rhoads DD, Cox SB, Rees EJ, Sun Y, Wolcott RD. Clinical identification of bacteria in human chronic wound infections: culturing vs. 16S ribosomal DNA sequencing. *BMC Infect Dis*. 2012;**12**:321. doi: 10.1186/1471-2334-12-321. [PubMed: 23176603].
- Kumar B, Vijayakumar M, Govindarajan R, Pushpangadan P. Ethnopharmacological approaches to wound healing–exploring medicinal plants of India. *J Ethnopharmacol*. 2007;**114**(2):103–13. doi: 10.1016/j.jep.2007.08.010. [PubMed: 17884316].
- de Souza Franco E, de Aquino CM, de Medeiros PL, Evencio LB, da Silva Goes AJ, de Souza Maia MB. Effect of a Semisolid Formulation of *Linum usitatissimum* L. (Linseed) Oil on the Repair of Skin Wounds. *Evid Based Complement Alternat Med*. 2012;**2012**:270752. doi: 10.1155/2012/270752. [PubMed: 21747895].
- Muir AD, Westcott ND. Flax: the genus *Linum*. CRC Press; 2003.
- Choo WS, Birch J, Dufour JP. Physicochemical and quality characteristics of cold-pressed flaxseed oils. *J Food Compos Analysis*. 2007;**20**(3):202–11.
- Hemmings SJ, Westcott N, Muir A, Czechowicz D. The effects of dietary flaxseed on the Fischer 344 rat: II. Liver gamma-glutamyltranspeptidase activity. *Cell Biochem Funct*. 2004;**22**(4):225–31. doi: 10.1002/cbf.1092. [PubMed: 15248182].
- Hosseini FS, Muir AD, Westcott ND, Krol ES. Antioxidant capacity of flaxseed lignans in two model systems. *J Am Oil Chem Soc*. 2006;**83**(10):835–40.
- Kaithwas G, Mukherjee A, Chaurasia AK, Majumdar DK. Anti-inflammatory, analgesic and antipyretic activities of *Linum usitatissimum* L. (flaxseed/linseed) fixed oil. *Indian J Exp Biol*. 2011;**49**(12):932–8. [PubMed: 22403867].
- Kaithwas G, Mukerjee A, Kumar P, Majumdar DK. *Linum usitatissimum* (linseed/flaxseed) fixed oil: antimicrobial activity and efficacy in bovine mastitis. *Inflammopharmacology*. 2011;**19**(1):45–52. doi: 10.1007/s10787-010-0047-3. [PubMed: 20602175].
- Czemplik M, Zuk M, Kulma A, Kuc S, Szopa J. GM flax as a source of effective antimicrobial compounds. *Sci Microb Pathog Commun Curr Res Technol Adv*. 2011;**76**:39–47.
- Datta HS, Mitra SK, Patwardhan B. Wound healing activity of topical application forms based on ayurveda. *Evid Based Complement Alternat Med*. 2011;**2011**:134378. doi: 10.1093/ecam/nep015. [PubMed: 19252191].
- Marques SR, Peixoto CA, Messias JB, Albuquerque AR, Silva Junior VA. The effects of topical application of sunflower-seed oil on open wound healing in lambs. *Acta Cirurgica Brasileira*. 2004;**19**(3):196–209.
- Hatanaka E, Curi R. Fatty acids and wound healing: a review. *Revista Brasileira de Farmacia*. 2007;**88**(2):53–8.
- Ashkani-Esfahani S, Imanieh MH, Khoshneviszadeh M, Meshksar A, Noorafshan A, Geramizadeh B, et al. The healing effect of arnebia euechroma in second degree burn wounds in rat as an animal model. *Iran Red Crescent Med J*. 2012;**14**(2):70–4. [PubMed: 22737558].
- Khoshneviszadeh M, Ashkani-Esfahani S, Namazi MR, Noorafshan A, Geramizadeh B, Miri R. Topical simvastatin enhances tissue regeneration in full-thickness skin wounds in rat models. *Iran J Pharm Res*. 2014;**13**(1):263–9. [PubMed: 24734079].
- Brem H, Tomic-Canic M. Cellular and molecular basis of wound healing in diabetes. *J Clin Invest*. 2007;**117**(5):1219–22. doi: 10.1172/JCI32169. [PubMed: 17476353].
- Martin P. Wound healing–aiming for perfect skin regeneration. *Science*. 1997;**276**(5309):75–81. [PubMed: 9082989].
- Albina JE, Gladden P, Walsh WR. Detrimental effects of an omega-3 fatty acid-enriched diet on wound healing. *JPEN J Parenter Enteral Nutr*. 1993;**17**(6):519–21. [PubMed: 8301804].
- McDaniel JC, Belury M, Ahijevych K, Blakely W. Omega-3 fatty acids effect on wound healing. *Wound Repair Regen*. 2008;**16**(3):337–45. doi: 10.1111/j.1524-475X.2008.00388.x. [PubMed: 18471252].