



PET/CT fusion in radiotherapy planning for lung cancer – Case reports

Fuzija PET/CT u planiranju radioterapije za karcinom pluća

Marko Dj Erak*[†], Milana Mitrić[†], Branislav Djuran*[†], Dušanka Tešanović[†],
Sanja Vasiljev[†]

*Faculty of Medicine, University of Novi Sad, Novi Sad, Serbia; [†]Oncology Institute of
Vojvodina, Sremska Kamenica, Serbia

Abstract

Introduction. Application of imaging methods, namely computed tomography (CT), magnetic resonance imaging (MRI) and in recent years positron emission tomography/computed tomography (PET/CT), and the progress of computer technology have allowed the construction of effective computed systems for treatment planning (TPS) and introducing the concept of virtual simulation in 3D conformal radiotherapy planning. **Case report.** We hereby presented two patients with the diagnosis of non-small cell lung cancer who did PET/CT examination. Both patients had surgery earlier and local recidives are diagnosed with PET/CT. PET/CT of the first patient described the focus of intense ¹⁸F-fluorodeoxyglucose (¹⁸FDG) accumulation 2.99 × 2.9 × 2.1 cm in diameter in the projection of soft-tissue volume in the left corner, at operating clips height, corresponding to metabolically active recurrence of the tumor. Mediastinum and right lung parenchyma were without focal accumulation of ¹⁸FDG. Control PET/CT after 3 months was without detectable focus of intense pathological ¹⁸FDG accumulation – good therapeutic response, (metabolic disease remission). On the other hand, in the second case PET/CT showed a focus of intense ¹⁸FDG accumulation screening in the scar tissue of the apical part of the right lung, 20 × 16 mm, corresponding to metabolically active tumor recurrence. In the lung parenchyma on the left and in the mediastinum no visible focus of intense ¹⁸FDG accumulation was described. Radiography included using 3D conformal radiotherapy with fusion PET/CT scan and CT simulations. **Conclusion.** PET/CT provides important information for planning conformal radiotherapy, especially in dose escalation, sparing of organ at risk and better locoregional control of the disease.

Key words:

carcinoma, non-small-cell lung; radiotherapy, conformal; positron-emission tomography.

Apstrakt

Uvod. Primena visokorezolutivnih metoda snimanja, npr. kompjuterizovane tomografije (CT), magnetno-rezonantnog snimanja (MRI) i, poslednjih godina, pozitron-emisiona tomografija-kompjuterizovana tomografija (PET-CT), kao i konstrukcija efikasnih kompjuterskih sistema za planiranje radioterapije (TPS) omogućili su uvođenje koncepta virtuelne simulacije u planiranju 3D konformalne radioterapije (3D CRT). **Prikaz bolesnika.** U radu su prikazana dva bolesnika sa nemikroćelijskim karcinomom bronha kod kojih je načinjen PET/CT pregled. Oba bolesnika ranije su operisana a lokalni recidiv je otkriven primenom PET/CT pregleda. Nalazom PET/CT kod prvog bolesnika ustanovljeno je nakupljanje ¹⁸F-fluorodeoksiglukoze (¹⁸FDG), prečnika 2,9 × 2,9 × 2,1 cm u projekciji mekih tkiva u levom uglu u predelu operativnih klipseva. Opisana promena odgovarala je metabolički aktivnom recidivu tumora. Mediastinum i plućni parenhim desno bili su bez fokalne akumulacije ¹⁸FDG. Kod drugog bolesnika ustanovljen je fokus intenzivnog nakupljanja u regiji ožiljka apikalnog segmenta desnog plućnog krila promera 20 × 16 mm, koji je prevashodno odgovarao metabolički aktivnom recidivu tumora. U parenhimu pluća sa leve strane i na mediastinumu sa leve strane nije ustanovljeno prisustvo aktivnih fokusa. Radioterapijski tretman planiran je 3D konformalnom tehnikom pomoću fuzije PET/CT nalaza i CT za planiranje radioterapije. **Zaključak.** PET/CT obezbeđuje važne informacije za planiranje radioterapije, posebno za eskalaciju doze, poštede rizičnih organa i bolje lokoregionalne kontrole bolesti.

Ključne reči:

pluća, nesitnoćelijski karcinom; radioterapija, konformalna; tomografija, pozitron-emisiona.

Introduction

Application of imaging methods, namely computed tomography (CT), magnetic resonance imaging (MRI) and, in recent years, positron emission tomography-computed tomography (PET-CT), and the progress of computer technology have allowed the construction of effective computerized systems for treatment planning (TPS) and introducing the concept of virtual simulation in 3D conformal radiotherapy planning^{1,2}.

The concept of 2D radiotherapy (defining the limits of the radiological fields according to bone structures) is now reserved for palliative radiotherapy. The golden standard for modern radiotherapy is 3D conformal radiotherapy. Planning 3D conformal radiotherapy based on CT simulation, which computer system makes into a 3D anatomical model reconstruction resulting in a virtual patient. The advantages of this method are complex analysis of the spatial relationship between the tumor and organs at risk, more precise definition of the tumor in all three dimensions, and air dose distribution whose shape corresponds to the form of tumor volume³.

Furthermore, 3D conformal planning allows individualization in modeling the shape of the radiation field. This can be done because of using cone beams with different spatial orientation angles so that their central axes are not in the same plane^{3,4}.

Isodose curves with high dose radiation are adjusted to the shape of the target volume which makes the best option of the dose distribution.

Application of conformal radiotherapy allows: dose escalation, better sparing of surrounding tissue, better locoregional control of the disease, lower rate of morbidity, i.e. complications in general. Imaging methods as CT and MRI have become the standard in the diagnosis, evaluation of the treatment answer, radiotherapy planning – target volume delineation. CT provides information about electronic density of the tissue, and they are used as the basis for calculating the tumor dose radiation in 3D RT^{4,5}.

Nonetheless, in 3D conformal radiotherapy planning problems are often present. For example, sometimes it is impossible to distinguish benign lymphadenomegaly, or a seemingly normal lymph node. The explanation is in the poor contrast between the tumor and the surrounding area. Furthermore, criteria for involvement of the lymph node – size, structure – have not yet been defined. Subclinical, microscopic tumor spread around the gross tumor volume, is still based on empirical experience. It should be noted that inadequate margins around the tumor cannot be compensated with escalation in exposure⁶.

The fusion of images in the system for planning with PET/CT is a new dimension in 3D radiotherapy planning. Image fusion of PET and CT results in the symbiosis between metabolically detected tumors (PET) and its anatomical and morphological boundaries (CT), and allows functional and biological evaluation of the tumor. The essential information for the definition of the target volume and organs at risk can be found on PET/CT images, but for delineation of the tumor this also must be projected to CT images.

Biological processes that could be used are glucose metabolism, cell proliferation and hypoxia^{7,8}.

There are various methods of PET and CT fusion. The most widely accepted is "visual fusion", where two scans are placed side by side, to compare and then integrate overlap⁶. This is performed by using hardware fusion and transport images in Focal Xi Over.4.6.

Case report

Case 1

A 74-year-old male patient had left pneumonectomy 15 months ago. Histopathological analysis confirmed that it was squamous cell carcinoma of the bronchus.

Control CT of the chest showed a tumor mass in the left tracheobronchial corner, described as a lymph node with perinodal growth (Figure 1).

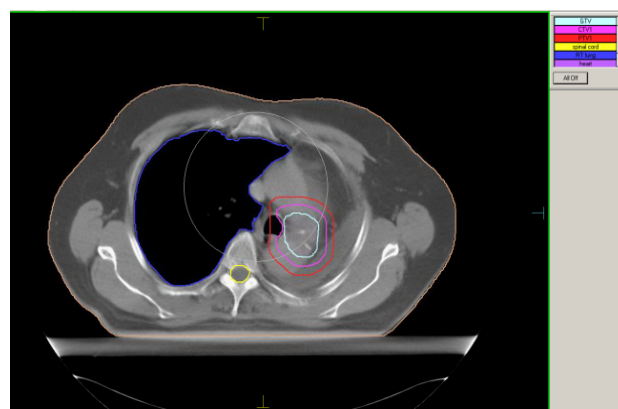


Fig. 1 – In the left corner the tracheobronchial tumor mass corresponding lymph node growth was seen.

PET/CT described the focus of intense ¹⁸F-fluorodeoxyglucose (¹⁸FDG) accumulation, 2.9 × 2.9 × 2.1 cm in diameter, in the projection of soft tissue volume in the left corner, at the operating clips height, corresponding to metabolically active recurrence of the tumor. The mediastinum and the right lung parenchyma were without focal accumulation of ¹⁸FDG (Dg: *Recidivum anguli reg. tracheobronchialis*) (Figure 2).

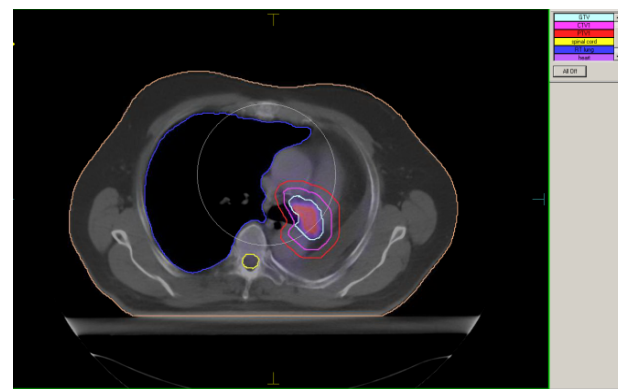


Fig. 2 – Positron emission tomography/computed tomography (PET/CT) – solitary focus of intense ¹⁸F-fluorodeoxyglucose (¹⁸FDG) accumulation.

We made a radiotherapy plan using 3D conformal radiotherapy with fusion PET/CT scan and CT simulations. The daily dose was 60 Gy/30 fractions with 2 Gy. Control PET/CT after 3 months was without detectable focus of intense pathological ^{18}F FDG accumulation – good therapeutic response – metabolic disease remission (Figure 3).

Case 2

A 53-year-old female patient in 2002 had right upper lobectomy with resection of the parietal pleura. Histopathological analysis confirmed adenocarcinoma. After receiving postoperative chemotherapy and radiotherapy the patient was monitored through regular controls.

CT of the chest done on March 16, 2012 described an oval soft tissue mass in the scar tissue of the apical part of the right lung, 20 × 16 mm, no signs of mediastinal and hilar lymphadenomegalia or increase in Igl axillary and infraclavicular gl. PET/CT done on March 28, 2012 showed a focus of intense ^{18}F FDG accumulation screening in the scar tissue of apical part of right lung, 20 × 16 mm, corresponding to metabolically active tumor recurrence. In the lung parenchyma on the left and in the mediastinum no visible focus of intense ^{18}F FDG accumulation was described (Figure 4). Control PET/CT done 3 months after the radiotherapy was described as a metabolic disease remission.

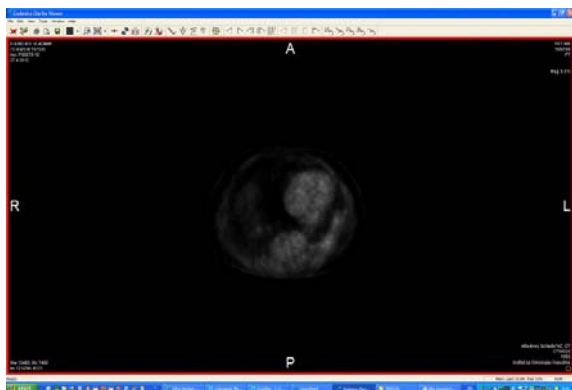


Fig. 3 – Control results of positron emission tomography/computed tomography (PET/CT) after 3 months without detectable focus of intensive pathological accumulation of ^{18}F -fluorodeoxyglucose (^{18}F FDG).

Discussion

Indications for using ^{18}F FDG PET/CT in lung tumor are evaluation of solitary lung nodules (sensitivity and specificity of the method is over 90%), determination of staging, determination of the status of mediastinal lymph nodes (the reliability of PET/CT is 92%, while of CT it is merely 75%), planning radiotherapy and evaluation of the therapeutic response^{6,9}. The advantage of PET/CT is that this imaging can determine the primary tumor close to the atelectatic lung

area. Data from the literature suggest that PET/CT provides high sensitivity and specificity and could be applied for early diagnosis of lung cancer and locale recurrence^{10,11}.

This improvement in diagnostic accuracy will have direct impact on designing therapeutic strategies and on radiation treatment planning¹². Some authors confirm in their retrospective studies that shortfall of CT alone in staging and guiding treatment decisions in patients with non-small cell lung carcinoma. It also strengthens the previously known better sensitivity and specificity of PET/CT as compared to conventional CT benefits^{5,13}.

Few studies on radiotherapy planning show that the addition of PET/CT information is associated with smaller size of gross tumour volume (GTV), clinical target volume (CTV), planning target volume (PTV) when compared with standard conformal 3D radiotherapy. In radiotherapy planning this allows dose escalation with slightly lower doses on organs at risk with promising high curability rates^{14,15}.

In both presented cases CT of the chest did not show recurrence, but PET/CT detected a metabolically active focus. This suggests that implementation of PET/CT as a result have a possibility for the earlier diagnosis. According to the data this is not only the advantage of PET/CT, the major one is maybe incorporation of PET/CT in radiotherapy planning.

Many studies show that when PET is used, radiotherapy

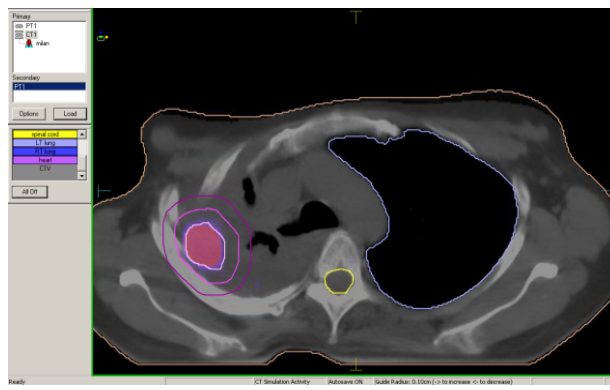


Fig. 4 – Positron emission tomography/computed tomography (PET/CT) findings (March 28, 2012) – the focus of intense ^{18}F -fluorodeoxyglucose (^{18}F FDG) accumulation in the projection described soft-tissue changes in the scar tissue of the lung top right.

fields or target volumes or estimates of GTV are different from the treatment fields or volumes that would have been drawn if PET had been unavailable^{11,16,17}.

Conclusion

PET/CT provides important information on planning conformal radiotherapy, evaluation of the effects of chemotherapy, in making decisions of the amount of therapy dose: lower dose, in cases of microscopic residue of the disease, higher doses, in cases of large residual tumor.

R E F E R E N C E S

1. *Nestle U, Kremp S, Grosu AL*. Practical integration of [18F]-FDG-PET and PET-CT in the planning of radiotherapy for non-small cell lung cancer (NSCLC): the technical basis, ICRU-target volumes, problems, perspectives. *Radiother Oncol* 2006; 81(2): 209–25.
2. *Mac Manus M, Hicks RJ*. The use of positron emission tomography (PET) in the staging/evaluation, treatment, and follow-up of patients with lung cancer: a critical review. *Int J Radiat Oncol Biol Phys* 2008; 72(5): 1298–306.
3. *Paulino A*. PET/CT in Radiotherapy Treatment Planning. 1st ed. Philadelphia, PA: Saunders/Elsevier; 2008.
4. *Zhao DS, Valdivia AY, Li Y, Blaufox MD*. 18F-fluorodeoxyglucose positron emission tomography in small-cell lung cancer. *Semin Nucl Med* 2002; 32(4): 272–5.
5. *Bradley J, Thorstad WL, Mutic S, Miller TR, Debdashti F, Siegel BA* et al. Impact of FDG/PET on radiation therapy volume delineation in non-small-cell lung cancer. *Int J Radiat Oncol Biol Phys* 2004; 59(1): 78–86.
6. IAEA-TECDOC-1603 The Role of PET/CT in Radiation Treatment Planning for Cancer Patient Treatment. Vienna, Austria: International Atomic Energy Agency; 2008.
7. *Chin R, McCain TW, Miller AA, Dunagan DP, Acostamadiedi J, Harkness AB* et al. Whole body FDG/PET for the evaluation and staging of small cell lung cancer: a preliminary study. *Lung Cancer* 2002; 37: 1–6.
8. *Pandit N, Gonen M, Krug L, Larson SM*. Prognostic value of [18F] FDG/PET imaging in small cell lung cancer. *Eur J Nucl Med Mol Imaging* 2002; 30: 78–84.
9. *Bradley JD, Debdashti F, Mintun MA, Govindan R, Trinkaus K, Siegel BA*. Positron emission tomography in limited-stage small-cell lung cancer: a prospective study. *J Clin Oncol* 2004; 22(16): 3248–54.
10. *Wang H, Zhao L, Zhao J, Wang Q*. Analysis on Early Detection of Lung Cancer by PET/CT Scan. *Asian Pac J Cancer Prev* 2015; 16(6): 2215–7.
11. *Huang W, Liu B, Min Fan M, Zhou T, Fu Z, Zhang Z*, et al. The early predictive value of a decrease of metabolic tumor volume in repeated 18F-FDG PET/CT for recurrence of locally advanced non-small cell lung cancer with concurrent radiochemotherapy. *Eur J Radiol* 2015; 84(3): 482–8.
12. *Brink I, Schumacher T, Mix M, Rubland S, Stoelben E, Digel W*, et al. Impact of [18F]FDG-PET on the primary staging of small-cell lung cancer. *Eur J Nucl Med Mol Imaging* 2004; 31(12): 1614–20.
13. *Mah K, Caldwell CB, Ung YC, Danjoux CE, Balogh JM, Ganguli SN* et al. The impact of (18)FDG/PET on target and critical organs in CT-based treatment planning of patients with poorly defined non-small-cell lung carcinoma: a prospective study. *Int J Radiat Oncol Biol Phys* 2002; 52(2): 339–5.
14. *Riegel AC, Bucci MK, Mawlawi OR, Ahmad M, Luo D, Chandler A*, et al. Defining internal target volume using positron emission tomography for radiation therapy planning of moving lung tumors. *J Appl Clin Med Phys* 2014; 15(1): 4600.
15. *Soykut ED, Ozabin EM, Tsoutou PG*. The use of PET/CT in radiotherapy planning: contribution of deformable registration. *Front Oncol* 2013; 3: 33.
16. *Vojtišek R, Mužjik J, Slampa P, Budíková M, Hejsek J, Smolák P*, et al. The impact of PET/CT scanning on the size of target volumes, radiation exposure of organs at risk, TCP and NTCP, in the radiotherapy planning of non-small cell lung cancer. *Rep Pract Oncol Radiother* 2013; 19(3): 182–90.
17. *Konert T, Vogel W, MacManus MP, Nestle U, Belderbos J, Grégoire V*, et al. PET/CT imaging for target volumedelineation in curative intent radiotherapy of non-small cell lung cancer: IAEA consensus report 2014. *Radiother Oncol* 2015; pii: S0167-8140(15)00153-X. (In Press)

Received on June 2, 2014.

Revised on May 2, 2015.

Accepted on May 13, 2015.

Online First March, 2016.