

To the editor:

Treatment of painful sickle cell leg ulcers with topical opioids

Leg ulceration is a common and painful complication of sickle cell anemia (SS). Leg ulcers tend to be indolent and intractable and heal slowly over months or years. The pain of these ulcers may be severe, excruciating, penetrating, sharp, and stinging in nature. In most patients, oral or parenteral opioid analgesics may be needed to achieve some pain relief. We wish to report our experience with 2 patients with SS and painful leg ulcers who achieved total pain relief with the applications of topical opioids, thus decreasing the amount of oral opioids taken to control the pain.

A 38-year-old African American woman with SS developed a painful 3.5 cm-by-3.5 cm ulcer on the medial aspect of the right ankle. The pain was excruciating, stinging, and sharp in nature with an intensity score of 10 on a 0 to 10 numerical verbal scale. The pain was worst at night, woke her up frequently, and required treatment with 5 mg oxycodone every 2 to 3 hours. She consumed 16 to 18 tablets of oxycodone per day, most of which were at night. The pain forced her to walk with a limp and interfered with her activities of daily living. In an effort to control the ulcer pain, one tablet of oxycodone was dissolved in 1 to 2 mL water and applied to the leg ulcer topically after mixing with the debridement ointment that she was using. This gave her almost immediate pain relief, decreased the intensity of the pain to 0, and reduced oxycodone consumption to 0 to 2 tablets per day.

The second patient was a 67-year-old African American woman with SS and chronic bilateral painful ulcers on both ankles for more than 20 years. The pain was stinging and sharp in nature and was managed with 100 mg meperidine orally every 2 hours as needed and topical xylocaine ointment, with some relief. Measures to treat

the ulcers including transfusion, grafting, debridement, hyperbaric oxygen, and growth factor therapy failed to induce healing. In an effort to achieve better pain relief, one 100 mg meperidine tablet was dissolved in water and applied to the ulcers with the xylocaine ointment. This gave her almost immediate pain relief, with a longer lasting effect than oral meperidine, and decreased the amount of meperidine consumed per day.

Our experience with these 2 patients indicate that topical opioids may be of value in relieving the pain of SS leg ulcers and decreasing the amount of oral opioids taken to achieve pain relief. These findings also indicate that peripheral opioid receptors do mediate peripheral analgesia.¹ Topical morphine has been reported to relieve the pain of decubitus skin ulcers in cancer patients.^{2,3} To the best of my knowledge, this report is the first to show the efficacy of topical opioids in sickle cell leg ulcers and that opioids other than morphine are also effective.

Samir K. Ballas

Correspondence: Cardeza Foundation, 1015 Walnut Street, Philadelphia, PA 19107; e-mail: samir.ballas@mail.tju.edu

References

1. Levine JD, Taiwo YO. Involvement of the mu-opiate receptor in peripheral analgesia. *Neuroscience*. 1989;32:571-575.
2. Krajnik M, Zyllicz Z, Finley I, Luczak J, Van Sorge AA. Potential uses of topical opioids in palliative care - report of 6 cases. *Pain*. 1999;80:121-125.
3. Twillman RK, Long TD, Cathers TA, Mueller DW. Treatment of painful skin ulcers with topical opioids. *J Pain Symptom Mgmt*. 1999;17:288-292.

To the editor:

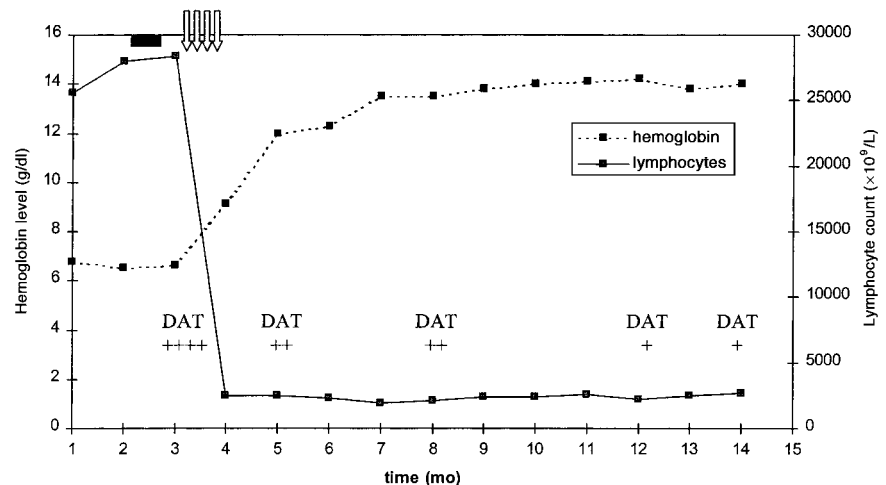
Sustained response of refractory chronic lymphocytic leukemia in progression complicated by acute hemolytic anemia to anti-CD20 monoclonal antibody

We have read with interest the paper of Huhn et al on rituximab therapy of patients with B-cell chronic lymphocytic leukemia (CLL).¹ Seven of 28 heavily pretreated patients showed a partial remission (NCI criteria), lasting for a median of 20 weeks. Huhn et al conclude that rituximab as a single agent might play a role in patients with poor marrow reserve for whom other options have failed. We would like to comment on the role of this therapy in refractory patients with concomitant acute hemolytic anemia (AHA). About 4% of CLL patients develop AHA,² mainly in those with active disease, and few data exist regarding the efficacy and safety of rituximab in this clinical setting.³

We recently employed rituximab as rescue therapy for a patient with resistant B-cell chronic lymphocytic leukemia (B-CLL) and secondary AHA. A 52-year-old patient, diagnosed in January 1996 as having stage Rai II classical B-CLL, was admitted to our department after 24 months in disease progression (huge splenomegaly, anemia, and lymphocyte count above 50 000/ μ L) complicated by AHA (warm antibody type). Thereafter, he was given the following therapy: chlorambucil and

prednisone, fludarabine + mitoxantrone + dexamethasone (FND), and cyclophosphamide + adriamycin + vincristine + prednisone (CHOP). After each line of therapy the patient attained only a short (less than 6 months') partial remission (PR), followed by tumor regrowth (splenomegaly, lymphocytosis, and anemia). In August 2000 he was admitted to our department again for disease progression. Physical examination revealed overt jaundice and hepato- and splenomegaly (15 cm below costal margin). Laboratory data were as follows: hematocrit, 21.3%; hemoglobin level, 6.6 g/dL; reticulocyte count, $320 \times 10^9/L$; mean corpuscular volume, 106 fL; platelet count, $166 \times 10^9/L$; white blood cell count, $32 \times 10^9/L$ with 38% lymphocytes, 50% polymorphocytes, and 12% neutrophils; bilirubin level, 35 μ M; lactate dehydrogenase level, 894 IU/L (normal is below 460 IU/L); and a direct antiglobulin test (DAT) positive for both complement (3+/4+) and IgG (4+/4+). The immunophenotype of peripheral blood lymphoid cells showed a typical B-CLL pattern (CD19⁺/CD5⁺/CD23⁺/CD10⁻) with unusual CD20 bright fluorescence intensity. He was naïve for hepatitis viruses and

Figure 1. Changes in hemoglobin level, lymphocyte count, and DAT score following rituximab therapy. The solid black rectangle indicates prednisone therapy; the vertical arrows, rituximab therapy; and DAT, direct antiglobulin test.



had an antibody pattern indicating a remote infection of Epstein Barr virus and cytomegalovirus. The patient did not respond to a 10-day course of 6-metilprednisolone IV (250 mg/d). Then, after obtaining the informed consent, we began a therapy with rituximab (Mabthera) at 375mg/m²/wk for 4 weeks, and tapered prednisone over 2 weeks. The follow-up is shown in Figure 1.

The first infusion of rituximab produced a marked reduction of the lymphocytosis, and after 5 days the hemoglobin level started to increase. No side effects related to rituximab infusion were recorded. At the end of week 8, the patient was re-evaluated. There were no signs of active AHA (reticulocyte count and hemoglobin, lactate dehydrogenase, and haptoglobin levels within range), and DAT was slightly positive (score +/4+). According to NCI criteria, the patient was judged to be in PR, because of the persistence of the splenomegaly, while having normal hemogram elements and a bone marrow interstitial lymphocyte infiltration of about 15%. After 12 months of follow-up the patient is still in PR, and this compares favorably to the median disease progression time of 20 weeks reported by Huhn et al.¹ The rapid response of AHA to rituximab markedly contrasts to the slow response to conventional

therapy (median, 4.5 months), as reported by Mauro et al.² The almost simultaneous response of CLL and AHA could be interpreted as due to the clearance of both the neoplastic and the autoreactive clones.³ Further studies are warranted to clarify the anti-CD20 role in the treatment of CLL in general and in patients with secondary AHA in particular.

Emilio Iannitto, Emanuele Ammatuna, Carla Marino, Sonia Cirrincione, Giacchino Greco, and Guglielmo Mariani

Correspondence: Emilio Iannitto, Haematology and Bone Marrow Transplantation Unit, University of Palermo, via del Vespro 129, 90127 Palermo, Italy; e-mail: eiannitto@tin.it

References

- Huhn D, von Shilling A, Wilhelm M, et al. Rituximab therapy of patients with B-cell chronic lymphocytic leukemia. *Blood*. 2001;98:1326-1331.
- Mauro FR, Foà R, Cerretti R, et al. Autoimmune hemolytic anemia in chronic lymphocytic leukemia: clinical, therapeutic, and prognostic features. *Blood*. 2000;95:2786-2792.
- Seipelt G, Bohme A, Koschmider S, Hoelzer D. Effective treatment with rituximab in a patient with refractory polymycytoid transformed B-chronic lymphocytic leukemia and Evans syndrome. *Ann Hematol*. 2001;80:170-173.

To the editor:

Recurrent coiled-coil motifs in NUP98 fusion partners provide a clue to leukemogenesis

The *NUP98* gene is the target of recurrent translocations in leukemia that fuse the 5' portion of *NUP98* with coding sequence from the partner gene.¹⁻⁸ Three of the known fusion partners, *HOXA9*, *HOXD13*, and *PMX1*, are homeobox genes. The other known fusion partners, *DDX10*, *RAP1GDS1*, *TOPI*, and *LEDGF*, are considered to share no common features. Recently *NSDI*, another nonhomeobox *NUP98* fusion partner, has been reported in this journal.⁸ We now report that the proteins coded for by the nonhomeobox genes all have regions with a significant probability of adopting a coiled-coil conformation.

Oligomerization via the coiled-coil domains has recently been shown to activate the oncogenic potential of RAR α and AML1 following fusion to partners with coiled-coil domains.⁹ It was shown that the PML-RAR α , PLZF-RAR α , NPM-RAR α , and AML1-ETO fusion proteins each exist in oligomeric complexes in vivo and that oligomerization causes abnormal recruitment of the

transcriptional corepressor N-CoR. Moreover, fusion of RAR α to the oligomerization domain of p53 showed that oligomerization alone is sufficient for transformation. Other leukemia fusion genes also involve the fusion of transcription factors with genes coding for coiled-coil domains. For example, the inv(16)(p13q22) fuses the N-terminus of CBF β with the C-terminus of the smooth muscle myosin heavy-chain gene.¹⁰ The coiled-coils of the myosin heavy-chain gene promote dimerization and are essential for the transforming properties of the fusion gene.¹¹

Coiled-coils are characterized by sequence patterns known as heptad repeats, which result in the formation of amphipathic alpha helices, the hydrophobic faces of which undergo what is known as "knobs-into-holes packing" as first proposed by Crick.¹² Potential coiled-coil forming sequences were sought using both algorithms in COILS 2.1 (http://www.ch.embnet.org/software/COILS_form.html). The original algorithm of Lupas et al gives equal weighting



blood[®]

2002 99: 1096-1097
doi:10.1182/blood.V99.3.1096a

Sustained response of refractory chronic lymphocytic leukemia in progression complicated by acute hemolytic anemia to anti-CD20 monoclonal antibody

Emilio Iannitto, Emanuele Ammatuna, Carla Marino, Sonia Cirrincione, Gioacchino Greco and Guglielmo Mariani

Updated information and services can be found at:

<http://www.bloodjournal.org/content/99/3/1096.2.full.html>

Articles on similar topics can be found in the following Blood collections

Information about reproducing this article in parts or in its entirety may be found online at:

http://www.bloodjournal.org/site/misc/rights.xhtml#repub_requests

Information about ordering reprints may be found online at:

<http://www.bloodjournal.org/site/misc/rights.xhtml#reprints>

Information about subscriptions and ASH membership may be found online at:

<http://www.bloodjournal.org/site/subscriptions/index.xhtml>